

Intestinal Ultrasound: Envisioning a New Future for Crohn's Disease Management

Amrik Randhawa, MD¹, and Tom Guzowski, MD, FRCPC¹

¹University of Saskatchewan, Saskatoon, Saskatchewan, Canada

ABSTRACT

The use of intestinal ultrasound (IUS) in the clinical assessment of intestinal disorders remains in its infancy in North America. We present a case in which IUS was used as a complement to Crohn's disease treatment in a 19-year-old man. After endoscopy and diagnosis, IUS was employed alongside other investigations to elucidate the extent of disease activity. It allowed identification and monitoring of complications such as free fluid and mucosal inflammation. IUS provided a marker of disease activity, even during apparent clinical remission. This case demonstrates that IUS can enhance disease monitoring and inform direction of therapy.

KEYWORDS: ultrasound; intestinal ultrasound; Crohn's disease

INTRODUCTION

Intestinal ultrasound (IUS) has been employed in Europe to assist in the clinical assessment of inflammatory bowel diseases.¹ However, in North America, this practice remains in its infancy. Despite limitations assessing the proximal small bowel and rectum, IUS is more sensitive and specific (85%, 91%) than magnetic resonance imaging (80%, 82%) and computed tomography (CT) (81%, 88%) in detecting Crohn's disease (CD) activity in more accessible areas.² It surpasses both in convenience, availability, safety, and cost-effectiveness.¹

IUS assessment of CD includes numerous disease markers. Thickening of the intestinal wall can indicate pathology, with abnormal measurements being >3 mm in either the small or large bowel.³ Loss of bowel wall stratification, mesenteric change (fat stranding), and lymphadenopathy are markers of local severity.^{1,3} Hypervascularity correlates to greater disease activity, scored with increasing severity from 0 to 3 on the modified Limberg scale.⁴ IUS can also evaluate submucosal disease complications including fistulas, strictures, and free fluid.^{3,5}

IUS provides real-time information regarding motility and luminal diameter.^{1,5} It assesses response to treatment not visible on just one endoscopy, such as transmural healing, determining disease recurrence or remission.⁶ This case provides an example of IUS complementing CD treatment to enhance disease monitoring and inform direction of therapy.

CASE REPORT

A 19-year-old man presented with a fecal calprotectin of 3,010 $\mu\text{g/g}$ (reference 0–100 $\mu\text{g/g}$), C-reactive protein of 19.7 mg/L (reference 0.0–7.0 mg/L), 6 months of 8 bloody bowel movements (BMs) per day, and significant weight loss. He had no findings on abdominal examination, nor extraintestinal manifestations of inflammatory bowel disease. Initial colonoscopy found aphthous ulcers throughout the sigmoid, descending, and transverse colon. The ascending colon and cecum demonstrated erythema, friability, nodularity, and thickened mucosa. He had severe terminal ileitis diagnostic of Crohn's ileocolitis (Figure 1).

Biopsies demonstrated noncaseating granulomas. With prednisone, his symptoms largely resolved by his 2-week follow-up. The patient also endorsed weight gain. He was tuberculosis negative, hepatitis C negative, and hepatitis B immune. Azathioprine

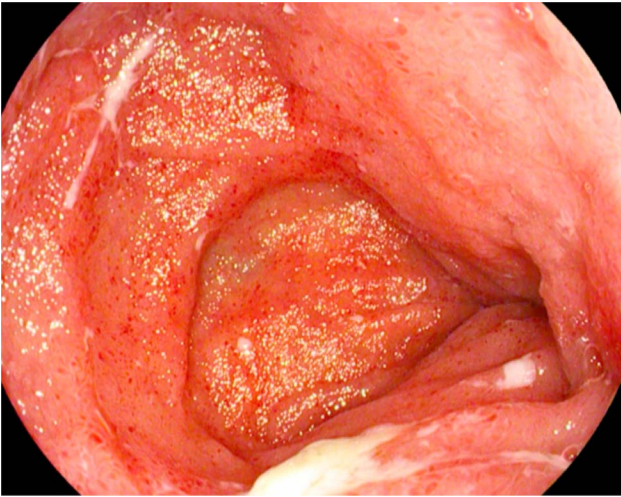


Figure 1. Initial colonoscopy demonstrating severe terminal ileitis diagnostic of Crohn's ileocolitis.

maintenance therapy started at 50 mg daily, shortly increased to 150 mg. At 8 months, he was in clinical remission. He had not been completing regular bloodwork, and the importance of regular bloodwork was reiterated.

At 1 year, a follow-up IUS was performed. JW was hesitant with follow-up imaging or endoscopy; thus, IUS was offered as an alternative. Clinically, he had 2–3 daily semi-formed BMs, with no stool sample provided. No extraintestinal symptoms, bleeding, or obstructions. On IUS, the right lower quadrant demonstrated free fluid, not in-keeping with an organized abscess (Figure 2). The terminal ileum remained inflamed along segments totaling approximately 10 cm. Wall thickness was 5 mm, with a modified Limberg vascularity score of 2/3 (Figure 3). These IUS findings suggested active transmural

disease, and the patient was transitioned to adalimumab without the need for CT, magnetic resonance imaging, or follow-up colonoscopy. With IUS-guided biologic therapy, the goal was to spare steroid use while inducing deep remission. There was no repeat calprotectin at this time. C-reactive protein a few weeks prior was 1.3 mg/L, which did not appear to be a reliable reflection of disease activity.

After 3 months, BMs had decreased to 1–2 formed per day. He did endorse 1 episode of a possible partial bowel obstruction. On repeat IUS, the free fluid in the right lower quadrant resolved (Figure 4). Terminal ileum thickness decreased to 2.8–3.1 mm, with a modified Limberg of 0/3 (Figure 5). There was some recovery of wall stratification consistent with healing. The plan was to wean azathioprine as findings indicated a response to adalimumab. Fecal calprotectin was 16 $\mu\text{g/g}$. As per patient preference, no repeat endoscopy was planned.

DISCUSSION

IUS provides useful clinical information that is affordable, reproducible, and noninvasive.^{1,7,8} Patients prefer not to have invasive tests that require bowel preparation.^{3,7} In conjunction with clinical acumen, IUS can inform treatment decisions such as evaluating response to biologics.¹ It is radiation-free, making repeated imaging safer than CT.⁹

IUS can directly monitor disease activity, even in apparent clinical remission.^{3,4} Its ability to provide information about transmural inflammation is invaluable in a target-to-treat model.^{5,8,10} As in this case, IUS alongside investigations like fecal calprotectin more accurately reflects disease activity. Fecal calprotectin provides an objective measure of activity,

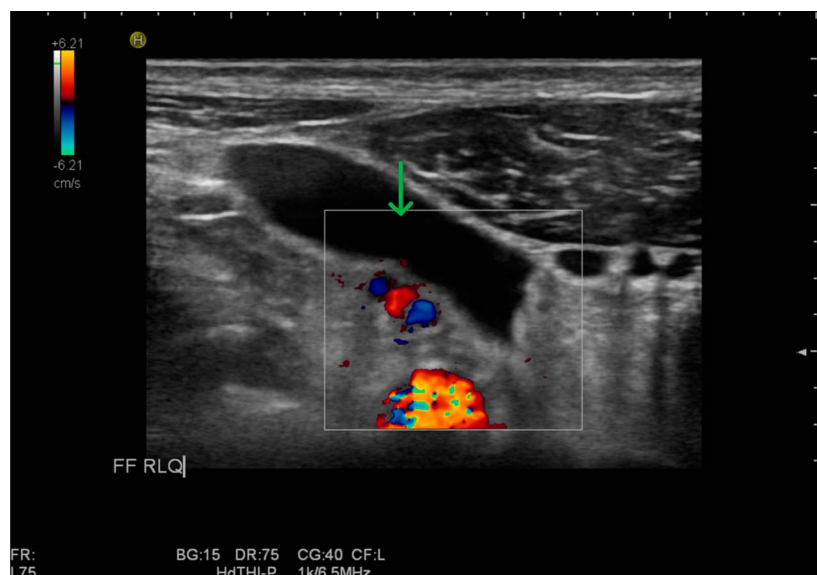


Figure 2. On follow-up intestinal ultrasound at 1 year, the right lower quadrant demonstrated free fluid (green arrow).

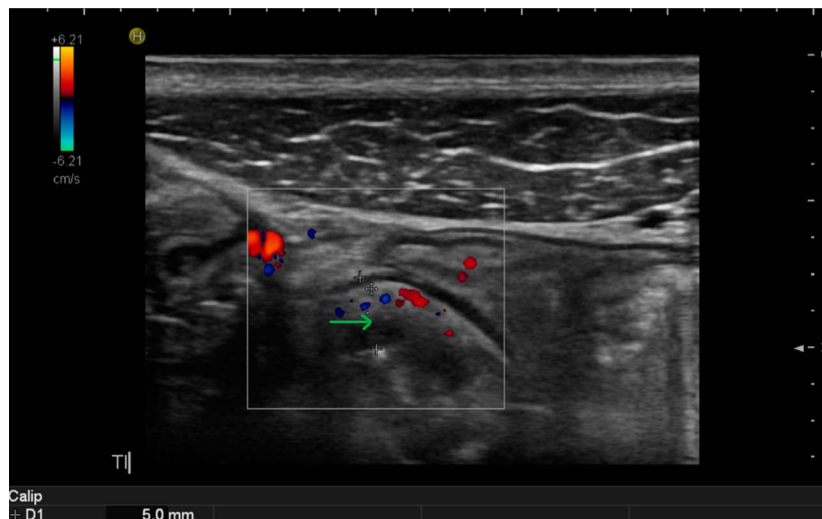


Figure 3. On follow-up intestinal ultrasound at 1 year, wall thickness of the terminal ileum was 5 mm (green arrow) with a modified Limberg vascularity score of 2/3.

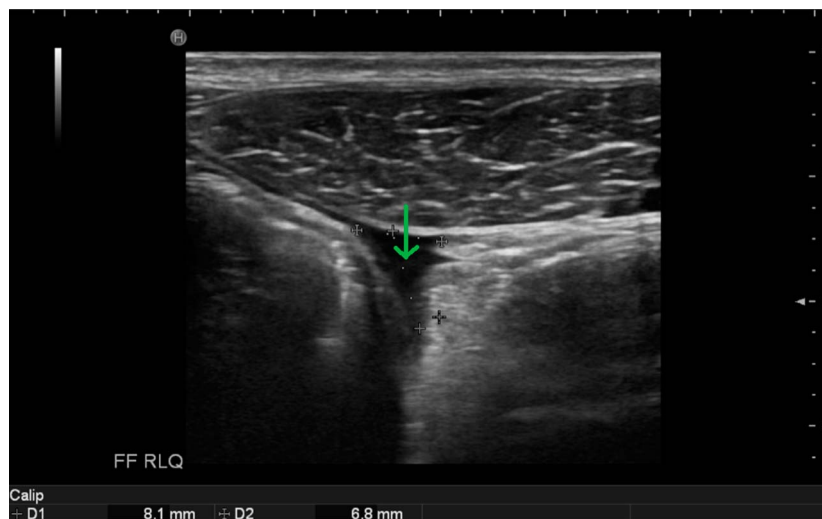


Figure 4. On repeat intestinal ultrasound 3 months later, the free fluid in the right lower quadrant resolved (green arrow).

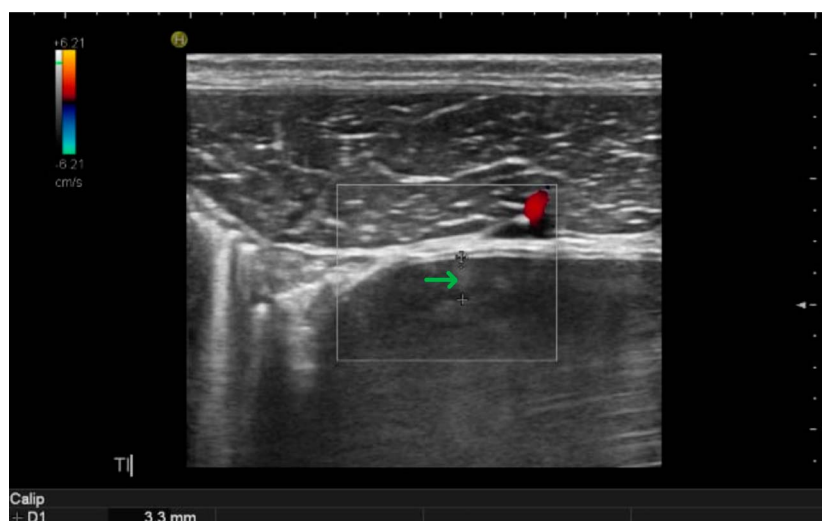

Figure 5. On repeat intestinal ultrasound 3 months later, wall thickness of terminal ileum was 2.8–3.1 mm (green arrow) with a modified limber vascularity score of 0/3.

while IUS directly visualizes the extent of it.^{8,11} This can provide a comprehensive picture for patient follow-up, reducing endoscopy frequency.⁸

The goal in IUS is standardizing reporting and education. A panel of gastroenterologists and radiologists determined ideal components of a disease activity index for CD.¹² These included wall thickness, vascularity, wall stratification, and fat stranding.¹² Standardizing reporting is essential for a universal disease activity index.

Unlike Germany and Italy, there is little opportunity for formal IUS training in countries like Canada.⁸ However, some courses are available through the International Bowel Ultrasound Consortium. With limited practice, concerns are raised about clinician technical skill and accurate interpretation of IUS.¹³ This can be mitigated through practice volume. Studies note a 150–200 scan minimum before trainees acquire sufficient diagnostic skill.^{13,14} There is evidence that increased experience affords a clinician the proficiency to employ IUS in practice.^{13,14} Thus, clinicians should strive to incorporate IUS alongside clinical examination whenever possible.

The role of contrast in IUS is controversial. A comparison of contrast-enhanced IUS to standard IUS in 17 patients with CD found each yielded similar findings.¹⁵ However, a different study comparing 37 patients with mild or severe CD demonstrated that contrast-enhanced IUS may be superior at differentiating between the two.¹⁶ Another study noted increased detection of bowel strictures with contrast.¹⁷ Contrast-enhanced IUS merits further investigation.

IUS can detect life-threatening CD complications such as bowel perforations, expediting more invasive imaging.¹⁸ It can also pinpoint early signs of bowel perforations like free air, facilitating early surgical intervention.¹⁹ Further uses, such as in ulcerative colitis, are being implemented.²⁰ Benefits including efficient resource delegation and real-time information on treatment efficacy apply in ulcerative colitis, as well.²⁰

In summary, this case supports the utility of IUS in managing CD. IUS enhances disease monitoring and can inform treatment. It has potential as a tool in directing therapy in CD and beyond.

DISCLOSURES

Author contributions: Both authors meet the ICMJE criteria for authorship. Together, A. Randhawa and T. Guzowski treated the patient that is the subject of this case report and decided to pursue publication of the report. Both authors participated in drafting, reviewing, and approving this case report. A. Randhawa and T. Guzowski agree to be accountable for all aspects of the work. A. Randhawa is the article guarantor.

Financial disclosure: Amrik Randhawa declares no conflict of interest and no financial interests. Tom Guzowski declares no conflict of interest and no financial interests. He has sat on adboards for and received honorariums for lectures from AbbVie, Janssen Pharmaceuticals, Takeda Pharmaceuticals, and Pfizer. He has also received honorariums for lectures from Ferring Pharmaceuticals and Fresenius Kabi.

Previous presentation: This case report was the subject of a virtual poster presentation on May 18, 2024, at Digestive Disease Week in Washington, DC.

Informed consent was obtained for this case report.

Received March 27, 2024; Accepted August 16, 2024

REFERENCES

- Andrzejewska M, Grzymislawski M. The role of intestinal ultrasound in diagnostics of bowel diseases. *Prz Gastroenterol.* 2018;13(1):1–5.
- Panes J, Bouzas R, Chaparro M, et al. Systematic review: The use of ultrasonography, computed tomography and magnetic resonance imaging for the diagnosis, assessment of activity and abdominal complications of Crohn's disease. *Aliment Pharmacol Ther.* 2011;34(2):125–45.
- Dolinger MT, Kayal M. Intestinal ultrasound as a non-invasive tool to monitor inflammatory bowel disease activity and guide clinical decision making. *World J Gastroenterol.* 2023;29(15):2272–82.
- Sasaki T, Kunisaki R, Kinoshita H, et al. Use of color Doppler ultrasonography for evaluating vascularity of small intestinal lesions in Crohn's disease: Correlation with endoscopic and surgical macroscopic findings. *Scand J Gastroenterol.* 2014;49(3):295–301.
- Allocca M, Furfaro F, Fiorino G, Peyrin-Biroulet L, Danese S. Point-of-care ultrasound in inflammatory bowel disease. *J Crohns Colitis.* 2021;15(1):143–51.
- Jauregui-Amezaga A, Rimola J. Role of intestinal ultrasound in the management of patients with inflammatory bowel disease. *Life (Basel).* 2021;11(7):603.
- Novak KL, Nylund K, Maaser C, et al. Expert consensus on optimal acquisition and development of the international bowel ultrasound segmental activity score [IBUS-SAS]: A reliability and inter-rater variability study on intestinal ultrasonography in Crohn's disease. *J Crohns Colitis.* 2021;15(4):609–16.
- Asthana AK, Friedman AB, Maconi G, et al. Failure of gastroenterologists to apply intestinal ultrasound in inflammatory bowel disease in the Asia-Pacific: A need for action. *J Gastroenterol Hepatol.* 2015;30(3):446–52.
- Chatu S, Subramanian V, Pollok RCG. Meta-analysis: Diagnostic medical radiation exposure in inflammatory bowel disease. *Aliment Pharmacol Ther.* 2012;35(5):529–39.
- Stenczel ND, Purcarea MR, Tribus LC, Oniga GH. The role of the intestinal ultrasound in Crohn's disease diagnosis and monitoring. *J Med Life.* 2021;14(3):310–5.
- De Voogd F, Bots S, Gecse K, Gilja OH, D'Haens G, Nylund K. Intestinal ultrasound early on in treatment follow-up predicts endoscopic response to anti-TNF α treatment in Crohn's disease. *J Crohns Colitis.* 2022;16(10):1598–608.
- Goodsall TM, Jairath V, Feagan BG, et al. Standardisation of intestinal ultrasound scoring in clinical trials for luminal Crohn's disease. *Aliment Pharmacol Ther.* 2021;53(8):873–86.
- Brodersen JB, Jensen MD, Juel MA, Kjeldsen J, Knudsen T, Rafaelsen SR. Intestinal ultrasound in patients with suspected Crohn's disease – results of a prospective evaluation by trainees. *Scand J Gastroenterol.* 2023;58(12):1405–11.
- Monteleone M, Friedman A, Furfaro F, Dell'Era A, Bezzio C, Maconi G. P139 the learning curve of intestinal ultrasonography in assessing inflammatory bowel disease – preliminary results. *J Crohn's Colitis.* 2013;7(S1):S64.
- Servais L, Boschetti G, Meunier C, et al. Intestinal conventional ultrasonography, contrast-enhanced ultrasonography and magnetic resonance enterography in assessment of Crohn's disease activity: A comparison with surgical histopathology analysis. *Dig Dis Sci.* 2022;67(6):2492–502.

16. Liu C, Xu X, Xu H, et al. Conventional ultrasound and contrast-enhanced ultrasound in evaluating the severity of Crohn's disease. *Int J Clin Exp Med*. 2015;8(1):123–34.
17. Parente F, Greco S, Molteni M, et al. Oral contrast enhanced bowel ultrasonography in the assessment of small intestine Crohn's disease. A prospective comparison with conventional ultrasound, x ray studies, and ileocolonoscopy. *Gut*. 2004;53(11):1652–7.
18. Pinto F, Scaglione M, Pinto A, Lassandro F, Romano L, Grassi R. Gastrointestinal perforation: Ultrasound diagnosis. *Emerg Radiol*. 2000;7(5):263–7.
19. Sofic A, Beslic S, Linceder L, et al. Early radiological diagnostics of gastrointestinal perforation. *Radiol Oncol*. 2006;40(2):67–72.
20. Maaser C, Petersen F, Helwig U, et al. Intestinal ultrasound for monitoring therapeutic response in patients with ulcerative colitis: Results from the TRUST&UC study. *Gut*. 2020;69(9):1629–36.

Copyright: © 2024 The Author(s). Published by Wolters Kluwer Health, Inc. on behalf of The American College of Gastroenterology. This is an open access article distributed under the terms of the Creative Commons Attribution-Non Commercial-No Derivatives License 4.0 (CCBY-NC-ND), where it is permissible to download and share the work provided it is properly cited. The work cannot be changed in any way or used commercially without permission from the journal.