

## P142

**Lodderomyces elongisporus: A n emerging cause of fungemia**

Harsimran Kaur<sup>1</sup>, Parakriti Gupta<sup>1</sup>, Shamanth Shankarnarayan<sup>2</sup>, Abhishek Pandey<sup>1</sup>, Anup Ghosh<sup>1</sup>, Arunaloake Chakrabarti<sup>1</sup>, Shivaprakash Rudramurthy<sup>1</sup>

<sup>1</sup>PGIMER Chandigarh, Chandigarh, India

<sup>2</sup>Charlebois lab, Dept. of Physics Edmonton AB, Canada

Poster session 2, September 22, 2022, 12:30 PM - 1:30 PM

**Background:** *Lodderomyces elongisporus*, earlier considered as a sexual state of *Candida parapsilosis*, was described as a distinct species based on ribosomal RNA gene sequencing. Few cases of human infections by this yeast have been described from Mexico, China, Malaysia, Kuwait, Australia, and the USA. We describe here eight cases of fungemia by *L. elongisporus* from a tertiary care hospital in North India.

**Methods:** Clinical characteristics and risk factors associated with *L. elongisporus* fungemia were evaluated. Yeast isolated from blood culture (BD BACTECT<sup>TM</sup> 9240, New Jersey, USA) was identified by matrix-assisted laser desorption/ionization time-of-flight mass spectrometry (MALDI-TOF MS, Bruker Daltonik GmbH, Bremen, Germany) and sequencing of D1/D2 region of a large subunit of ribosomal DNA. We performed antifungal susceptibility testing for amphotericin B, fluconazole, itraconazole, voriconazole, posaconazole, caspofungin, anidulafungin, and micafungin by the microbroth dilution method recommended by the Clinical and Laboratory Standards Institute (CLSI).

**Results:** We report eight cases of fungemia caused by *L. elongisporus* at our tertiary care center. Of these, three were infants (males) and five were adults (3 males and 2 females). The mean age of adults was 43.4 years. Among the pediatric cases, underlying diseases included congenital heart disease/atrophic kidney (neonate), tracheoesophageal fistula (4 months), and late-onset neonatal sepsis (LONS). Among the adults, underlying illnesses included acute kidney injury ( $n = 2$ ), superior mesenteric artery thrombosis with bowel gangrene ( $n = 1$ ), diabetes ( $n = 1$ ), and central nervous system (CNS) lymphoma ( $n = 1$ ). The iatrogenic factors included the history of surgery ( $n = 3$ ), admission to ICU ( $n = 3$ ), presence of urinary catheter ( $n = 4$ ), and presence of central venous catheter ( $n = 1$ ). Seven patients were on broad-spectrum antibiotics. The mean stay in the hospital was 20.38 days. Three of the patients were managed with fluconazole. Six patients improved while one left against medical advice (LAMA) and one expired. The range of minimum inhibitory concentration (MIC) of all the isolates against antifungals was as follows: amphotericin B (0.03-0.25 µg/ml), fluconazole (0.125 µg/ml), voriconazole (0.03 µg/ml), itraconazole (0.03-0.06 µg/ml), posaconazole (0.03-0.25 µg/ml), caspofungin (0.03-0.06 µg/ml), micafungin (0.03-0.06 µg/ml), and anidulafungin (0.03 µg/ml).

**Conclusion:** *Lodderomyces elongisporus* is an emerging pathogenic yeast causing fungemia in patients with comorbidities and undergoing surgery or invasive interventions. Though no antifungal breakpoints exist for this yeast, all the isolates exhibited low MICs to all the tested antifungals.

## P143

**Incidence of chronic pulmonary aspergillosis in a cohort of bacteriologically confirmed TB patients at a tertiary hospital in Ghana**

Bright Ocansey<sup>1</sup>, Benjamin Otoo<sup>2</sup>, Abraham Adjei<sup>3</sup>, Chris Kosmidis<sup>1,4</sup>, Jane Afriyie-Mensah<sup>5,6</sup>, Japheth Opintan<sup>5</sup>, David Denning<sup>1</sup>

<sup>1</sup>University of Manchester, Manchester, United Kingdom

<sup>2</sup>Noguchi Memorial Institute of Medical Research, Accra/Legon, Ghana

<sup>3</sup>Korle-Bu Teaching Hospital, Accra/Korle-Bu, Ghana

<sup>4</sup>Manchester University NHS Foundation Trust, Manchester/Wythenshawe, United Kingdom

<sup>5</sup>University of Ghana Medical School, Accra/Korle-Bu, Ghana

Poster session 2, September 22, 2022, 12:30 PM - 1:30 PM

**Objectives:** Chronic pulmonary aspergillosis (CPA) is a common complication of tuberculosis. Previous studies on CPA in TB had involved general TB patients with a majority not bacteriologically proven. Although, ruling out evidence of TB is critical in diagnostic algorithms for CPA, in rare cases, CPA may occur in patients with active TB. This prospective longitudinal study aimed to determine the incidence of CPA at three timepoints in a cohort of bacteriologically confirmed TB patients placed on anti-TB therapy in Ghana.

**Methods:** Consecutive patients in whom MTB was detected by molecular analysis (GeneXpert MTB) and subsequently placed on anti-TB treatment were enrolled. They were screened for CPA at baseline or the time of TB diagnosis (0-1 week), end of treatment (6-7 months), and post-treatment (12-13 months). Screening involved assessment of signs and symptoms, quality of life (QoL) using St. George's Respiratory Questionnaire, imaging investigations (chest radiograph and/or CT scan), and mycology testing (LDBio *Aspergillus* IgG & IgM ICT and culture). CPA cases were defined based on a diagnostic algorithm developed for resource-constrained settings. During follow-up timepoints, CT scan was done when *Aspergillus* serology changed from negative to positive. GeneXpert MTB or acid-fast bacillus (AFB) smear results were obtained from laboratory records during follow-up timepoints.

**Results:** A total of 46 patients were enrolled at baseline, of whom 34 (74%) were resurveyed at the end of treatment. Only 13 patients have been screened post-treatment so far. There were 6 (13%) relapse cases. At baseline, *Aspergillus* serology was positive in 4 (8.7%) patients and later increased to 6 (17.6%) and now 3 (23.1%) at the end and post-treatment respectively. Specifically, 4 (8.7%), 2 (6.9%), and 1 (10.0%) patient(s) met the criteria for CPA at baseline, end of treatment, and post-treatment respectively. All four cases of CPA described at baseline occurred in relapse patients. Among these patients, the initial MTB load determined by GeneXpert MTB was either trace or very low and follow-up AFB smear and/or GeneXpert MTB were negative between 2 to 3 months. Among relapse patients, average years since the primary episode of TB was four in those with CPA versus nine in those without CPA. Persistent cough and hemoptysis were the common symptoms of CPA. All CPA patients had cavitation, irregular intraluminal lining of cavity, and all but one had pleural thickening and/or paracavitary fibrosis. Two CPA patients at baseline have been rescreened post-treatment, one still has features of CPA and one had died. Also, the two CPA patients at the end of treatment continue to have CPA features when rescreened. Quality of life score improved significantly at the end of treatment for TB without CPA (51.4-3.8) while for those with putative CPA co-infection the improvement was less (53.8-25.7).

**Conclusion:** CPA should be considered in patients with suspected TB relapse, a very low or trace GeneXpert MTB, and positive *Aspergillus* serology. These patients had a less satisfactory symptom improvement after TB treatment. *Aspergillus* serology testing at the beginning of TB relapse therapy may provide prognostic information.

## P144

**The uncommon meets the common: Invasive Aspergillosis and tuberculosis co-infection in non-neutropenic patients – are associations**

Akshatha R<sup>1</sup>, Gopal Krishna Bohra<sup>1</sup>, Durga Shankar<sup>1</sup>, Deepak Kumar<sup>1</sup>, Naresh Kumar Midha<sup>1</sup>, Vidhi Jain<sup>2</sup>, Shivang Sharma<sup>3</sup>, Santhanam N<sup>1</sup>, Mahendra Kumar Garg<sup>1</sup>, Kuldeep Singh<sup>3</sup>, Nishant Kumar Chauhan<sup>4</sup>, Ankur Sharma<sup>5</sup>

<sup>1</sup>Department of Medicine, AIIMS Jodhpur, Jodhpur, India

<sup>2</sup>Department of Microbiology, AIIMS Jodhpur, Jodhpur, India

<sup>3</sup>Department of Pediatrics, AIIMS Jodhpur, Jodhpur, India

<sup>4</sup>Department of Pulmonary Medicine, AIIMS Jodhpur, Jodhpur, India

<sup>5</sup>Department of Anesthesia, AIIMS Jodhpur, Jodhpur, India

Poster session 2, September 22, 2022, 12:30 PM - 1:30 PM

**Background and Objective:** Invasive aspergillosis (IA) is known to occur in immunocompromised patients including neutropenic patients. But, recently increasing cases have been reported in patients with non-classical risk factors and non-neutropenic patients like diabetes mellitus, chronic lung disease, HIV infection, critically ill patients, etc. According to ISHAM these non-classical risk factors should be included in EORTC/MSG host criteria for diagnosis of invasive aspergillosis.

India has a high tuberculosis (TB) burden, and this is always considered as the first differential for any patient with fever, cough, hemoptysis, and weight loss. Post-tubercular chronic pulmonary aspergillosis common reported condition. However, co-infection of active TB and invasive aspergillosis is less reported. This co-infection could be one of the contributors of high morbidity and mortality in cases with tuberculosis.

We hereby present a series of five cases of TB concomitant with invasive aspergillosis in non-neutropenic patients.

**Methods:** This is a prospective observational study, all patients admitted with molecular diagnosis (GeneXpert) of tuberculosis and with at least one non-classical risk factor for invasive aspergillosis were subjected to further evaluation. Diagnosis

of invasive aspergillosis was considered in patients who had at least one clinical and one mycological EORTC criteria. Galactomannan level in different samples was measured via Platelia<sup>TM</sup> ELISA. The efficacy of different antifungals and outcomes were analyzed.

**Results:** Total 57 patients with TB underwent for evaluation of invasive aspergillosis. Among them, five patients were diagnosed to have concomitant TB and invasive aspergillosis, of which three cases of CNS TB and CNS aspergillosis and two had concomitant pulmonary infections. The average age was 31 ± 12 years with a female preponderance (4/5). Two patients were HIV positive, while among non-HIV patients, one had CD4 cytopenia (CD4<171). One patient had no known predisposing factor. Radiologically, most common pulmonary lesions were patchy consolidation with centrilobular nodules with tree in bud appearance, while CNS lesions showed multiple ring-enhancing lesions. All the patients had CBNAAT positive, two from BAL sample, 1 from CSF, and 1 from the lymph node. Rifampicin was sensitive in all, except one who had rifampicin resistance indeterminate. Of these patients, four were probable invasive aspergillosis satisfying the host, mycological and clinical factors as per the EORTC/MSGERC 2021 guidelines. The treatment of coinfection is challenging due to the interaction of rifampicin with voriconazole, which is the drug of choice for invasive aspergillosis. Here, 3 patients were treated with Inj amphotericin B, while the other 2 patients were started on voriconazole with rifampicin sparg regimen for TB. Of the 5 patients, 4 patients survived with excellent response to the treatment, with one fatality.

**Conclusion:** The possibility of concurrent TB and invasive aspergillosis in non-neutropenic hosts should be considered to avoid devastating outcomes. The lack of clinical suspicion may result in misdiagnosis, and most importantly, the chronicity of the infection makes it indistinguishable from TB. Moreover, the co-administration of antifungal and anti-TB medications presents significant therapeutic challenges necessitating thorough evaluation and monitoring.

## P145

**Co-infections due to Aspergillus and Mucorales: Case series from a superspecialty medical center in India**

Bhaskar Rana<sup>1</sup>, Immaculata Xess<sup>1</sup>, Gagandeep Singh<sup>1</sup>, Rakesh Kumar<sup>2</sup>, Manish Soneja<sup>3</sup>, Ashima Jain<sup>4</sup>, Ajay Roy Choudhury<sup>5</sup>

<sup>1</sup>Department of Microbiology, All India Institute of Medical Sciences, New Delhi, India

<sup>2</sup>Department of ENT, All India Institute of Medical Sciences, New Delhi, India

<sup>3</sup>Department of Medicine, All India Institute of Medical Sciences, New Delhi, India

<sup>4</sup>Department of Microbiology, National Cancer Institute, Jhajjar, India

<sup>5</sup>Department of Dental Surgery, All India Institute of Medical Sciences, New Delhi, India

Poster session 2, September 22, 2022, 12:30 PM - 1:30 PM

**Objectives:** To present details of a case series of fungal co-infection (aspergillosis and mucormycosis) including clinical course, laboratory diagnosis, treatment, and outcome.

**Methods:** Clinical histories of 7 cases of fungal co-infection (3 pulmonary, 4 rhino-orbito-cerebral or sino-nasal) were collected by chart review, and reports of samples sent to the mycology laboratory for direct microscopy and fungal culture were retrieved from laboratory records. Presence of septate and aseptate hyphae in direct microscopy of clinical samples and/or growth of *Aspergillus* spp and Mucorales in culture was considered as evidence of probable co-infection with mucormycosis and aspergillosis (as per EORTC guidelines).

**Results:** Mechanical ventilation, cavitory lung disease, and renal failure with metabolic acidosis were unique risk factors observed for pulmonary co-infection, while use of systemic corticosteroids for treatment of SARS-CoV-2 infection was common in rhino-orbito-cerebral (ROC) or sino-nasal (SN) co-infection. Diabetes mellitus was a common risk factor for both groups of cases.

Fever, cough, chest pain, and shortness of breath were the most common features in pulmonary fungal co-infection cases, while headache, facial swelling and pain, nasal stuffiness, decreased vision, and altered sensorium were the most common features in ROC/SN co-infection.

Consolidation or collapse, bronchiectasis, cavitory changes in and nodules were the most frequent radiological features in pulmonary fungal co-infection cases, while mucosal thickening in multiple paranasal sinuses, and involvement of orbit and cavernous sinuses were the most frequent features in ROC or SN co-infection.

Presence of aseptate and septate hyphae in direct microscopy was seen in tissue samples from all ROC/SN cases, which enabled early intervention. However direct microscopy was not indicative of co-infection in any of sputum samples from pulmonary cases, and diagnosis was only established by culture, leading to delayed initiation of treatment or no treatment. Liposomal amphotericin B (IAMB) ranging from 50-200 mg/day was used for treatment of fungal co-infection, with posaconazole 600-800 mg/day as step-down therapy or if IAMB was not tolerated.

Out of three pulmonary fungal co-infection cases, only one received appropriate antifungal treatment but expired nonetheless. Out of the two untreated patients, one expired, and one was discharged against medical advice without resolution of symptoms. Surgical intervention was not done for any patient. In comparison, 3 out of 4 cases of ROC/SN co-infection were appropriately managed with immediate surgical debridement and survived. The remaining patient received appropriate antifungals but refused surgical intervention and expired.

**Conclusions:** Fungal co-infection with aspergillosis and mucormycosis is a serious condition requiring early intervention. This is facilitated by high sensitivity of direct microscopy in tissue samples used for diagnosis in ROC/SN co-infection, but hindered by low sensitivity of direct microscopy in sputum/BAL samples used for diagnosis in pulmonary cases rather than lung biopsy. Robust clinical advisory services, early diagnosis, and combined surgical and pharmacological approaches are crucial to a favorable outcome.

## P146

**Penicillium-like mold: caught red-handed, but remained unidentified**

Sujata Rege<sup>1</sup>, Rajeev Soman<sup>2,3</sup>, Dipali Chavan<sup>3</sup>, Mahendra Dadke<sup>2</sup>

<sup>1</sup>Bharati Vidyapeeth University and Medical College, Pune, India

<sup>2</sup>Jupiter Hospital, Pune, India

<sup>3</sup>Deenanath Mangeshkar Hospital, Pune, India

Poster session 2, September 22, 2022, 12:30 PM - 1:30 PM

**Objective:** This case highlights the presence of a self-limited respiratory mycosis in an immunocompetent host and need for fungal sequencing in diagnosis of such rare cases.

**Methods and Results:** Ms X, a 25-year-old, apparently healthy software engineer, had an overnight journey in an air-conditioned bus from Hyderabad to Pune. The next day, she developed throat irritation followed 3 days later by fever and cough without dyspnea nor wheezing. Her chest X-ray was found to be normal at the time. Three days later she was admitted to our hospital, wherein X-ray chest and CT chest showed bilateral randomly scattered nodular shadows (Fig. 1). She was referred to ID as a case of suspected tuberculosis, but her presenting symptom being sore throat, the acuteness of symptoms, presence of nodular lung shadows which were absent on the X-ray chest done just 3 days earlier were against the diagnosis of TB. Inhalational fungal or viral pneumonitis were hence considered.

Transbronchial biopsy showed an intense alveolar inflammatory exudate, but GMS staining did not reveal any fungal hyphae. BAL Galactomannan, Xpert MTB/RIF were negative. Both BAL and CT guided lung nodule biopsy samples grew a mold. Red pigment formation in culture and its morphological appearance on LPCB mount (Fig. 2) led to a diagnosis of *Penicillium* species infection. MALDI TOF MS, which had only a few *Penicillium* spp in its 2018 database, failed to identify the organism, leading us to believe that it could be a different *Penicillium* species.

Since the patient was showing clinical improvement, a self-limited infection was thought of and therapy was withheld with cautious follow-up. The patient was completely asymptomatic after 10 days and CT chest done 20 days later showed complete resolution of the nodules.

We believe that this illness was due to inhalation of spores from the air-conditioning vent, eliciting a brisk inflammatory response in the alveoli. The organism grew from BAL and CT guided biopsy from viable spores, but it failed to germinate into hyphae in the human host and hence was not seen on histopathology and did not produce galactomannan which is only released from the tips of growing hyphae.

**Conclusion:** Fungi are often isolated from poorly maintained air conditioning vents. In this case, the *Penicillium* like organism failed to produce progressive disease in the immunocompetent host. If the same organism could be cultured from the AC vent, showed genetic relatedness with the clinical isolate; the source, transmission, and disease linkage could have been established in this case.

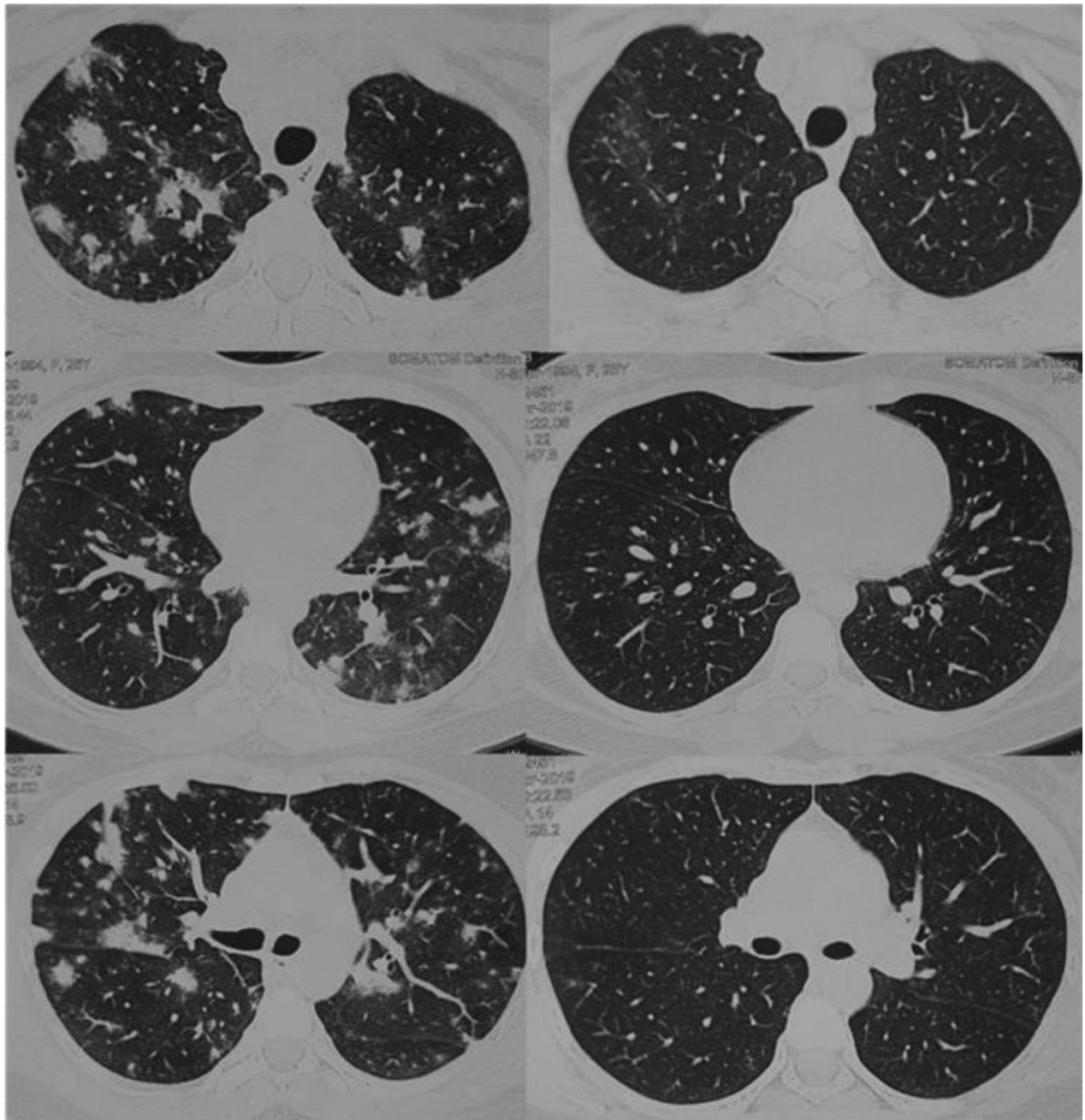
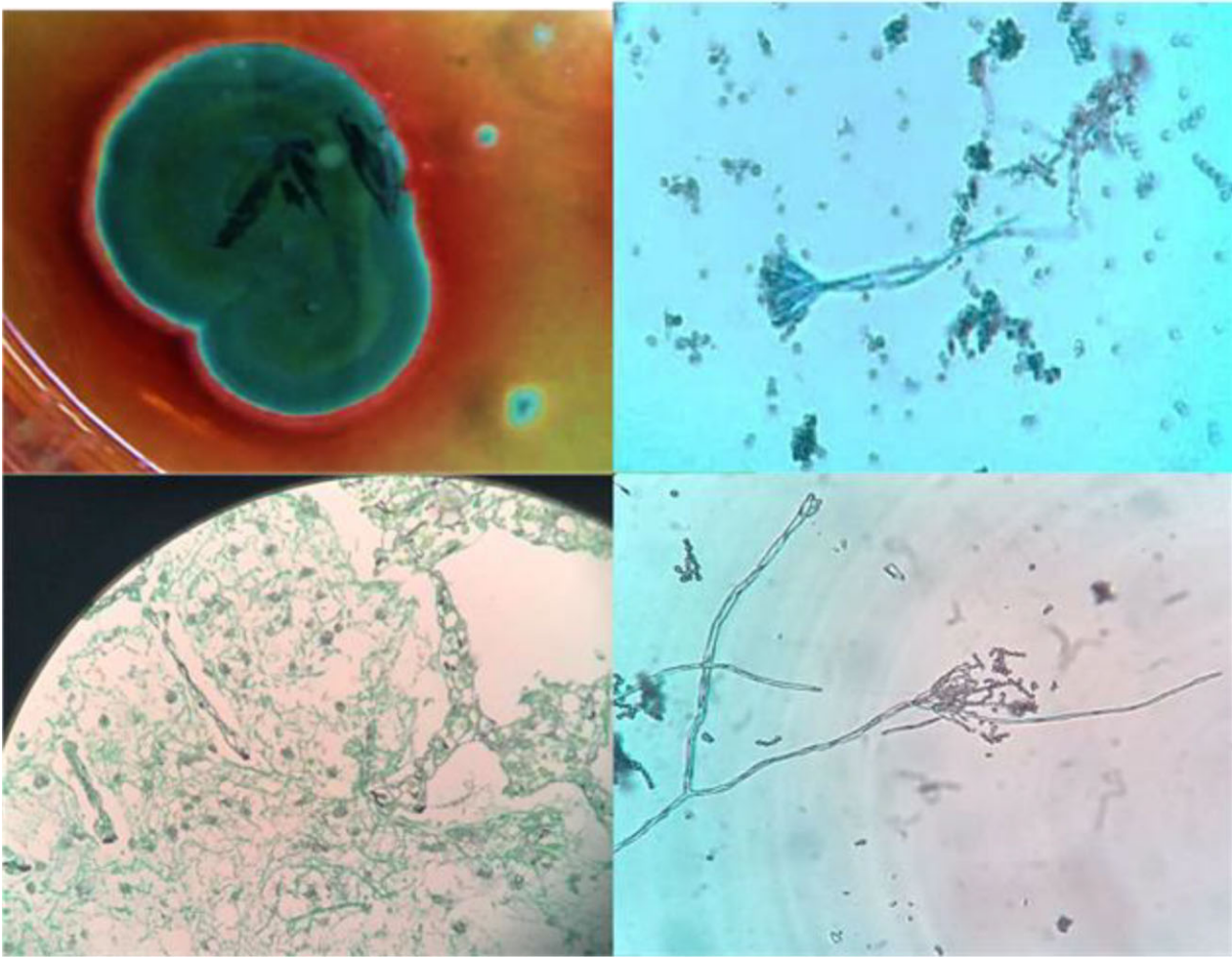


Figure 1.



**Figure 2.**

**P147**  
**Fungal osteomyelitis in patients with chronic granulomatous disease: a case series from a tertiary care medical centre.**

Janya Sachdev<sup>1</sup>, Immaculata Xess<sup>1</sup>, Gagandeep Singh<sup>1</sup>, S.K. Kabra<sup>2</sup>  
<sup>1</sup>Department of Microbiology, All India Institute of Medical Sciences, New Delhi, India  
<sup>2</sup>Department of Paediatrics, All India Institute of Medical Sciences, New Delhi, India

Poster session 2, September 22, 2022, 12:30 PM - 1:30 PM

**Objectives:** To present details of a case series of fungal osteomyelitis initially misdiagnosed as disseminated tuberculosis, in pediatric patients with chronic granulomatous disease.

**Method:** Informed consent was obtained from the parents of three children (known cases of chronic granulomatous disease) with clinical features suggestive of chronic osteomyelitis. Clinical history was collected by interview and chart review. Samples were sent to the mycology laboratory for direct microscopy and fungal culture. Following a diagnosis of fungal osteomyelitis, antifungal therapy was administered and patients were monitored till discharge.

**Results:**

**First case:**

The first patient presented with fever, cough and progressive painful swelling over the left lower chest, and a past history of recurrent pneumonia and cervical lymphadenopathy, which were previously empirically treated with anti-tubercular therapy (ATT) and broad-spectrum antibiotics. Imaging revealed a soft tissue abscess with underlying rib osteomyelitis and pulmonary consolidation. Pus samples showed hyaline septate hyphae in direct microscopy and growth of *Aspergillus nidulans* in culture. The patient was successfully treated with intravenous voriconazole, which was switched to oral formulation on discharge.

**Second case:**

The second patient presented with fever and post-auricular swelling with multiple discharging sinuses, and a past history of fever and hilar lymphadenopathy, which were previously empirically treated with ATT and broad-spectrum antibiotics. Imaging revealed osteomyelitis involving mandible, temporal bone and skull base, with underlying sigmoid sinus thrombosis. Pus and tissue samples showed hyaline septate hyphae in direct microscopy and growth of *Aspergillus fumigatus* in culture. The patient was successfully treated with a combination of intravenous voriconazole and liposomal amphotericin B, and discharged on oral posaconazole.

**Third case:**

The third patient presented with progressive painful swelling over the right upper chest, and a past history of pneumonia, hemoptysis, and mediastinal lymphadenopathy, which were previously empirically treated with ATT and broad-spectrum antibiotics. During a previous hospitalization, imaging showed features suggestive of fungal pneumonia; BAL showed hyaline septate hyphae in direct microscopy and growth of *Aspergillus fumigatus* and *Aspergillus flavus* in culture, providing a diagnosis of fungal pneumonia which was treated with voriconazole and liposomal amphotericin B. During the present admission, imaging of the chest lesion revealed pus collection with underlying rib osteomyelitis, communicating with a cavity in the middle lobe of the right lung. FNAC from the lesion showed hyaline septate hyphae in direct microscopy but no growth in culture (probably due to previous antifungal therapy). The patient was successfully treated with a combination of intravenous voriconazole and liposomal amphotericin B, and discharged on oral posaconazole.

**Conclusions:** Fungal pneumonia and fungal osteomyelitis are often misdiagnosed as tuberculosis or bacterial infections, leading to unnecessary and ineffective ATT or broad-spectrum antibiotics. A high index of suspicion for fungal osteomyelitis is

required in pediatric patients with a history of recurrent/chronic soft tissue infections, preceded by febrile episodes and/or pneumonia, especially if a diagnosis of chronic granulomatous disease (CGD) has already been established; if not, this characteristic clinical picture should in fact warrant evaluation for CGD.

**P148**  
**Emerging and cryptic *Aspergillus* species isolated from hospitalized patients with underlying primary immunodeficiencies**

Chioma Aneke, Jung-Ho Youn, Pavel Khil, Phd Amir Seyedmousavi  
 National Institutes of Health Clinical Center, Bethesda, MD, USA

Poster session 2, September 22, 2022, 12:30 PM - 1:30 PM

**Objectives:** Although *Aspergillus fumigatus* is the most common etiologic agent of invasive aspergillosis, multiple poorly recognized non-*fumigatus* species have been reported from patients with iatrogenic immunosuppression and individuals with underlying primary immunodeficiencies (PIDs). The species-level identification of causative agents and the determination of antifungal susceptibility patterns can play significant roles in the outcome of aspergillosis. In the current study, we aimed to investigate the frequency of non-*fumigatus* *Aspergillus* species isolated from hospitalized patients with PIDs at National Institutes of Health (NIH) Clinical Center, Bethesda, MD, USA.

**Methods:** In a prospective study between January 2019 and December 2021, a total of 279 *Aspergillus* species were isolated from NIH hospitalized patients with underlying PIDs. The species-level identification of each isolate was attempted by colony morphology, microscopic characteristics, matrix-assisted laser desorption/ionization time-of-flight mass spectrometry (MALDI-TOF), and PCR-sequencing of the internal transcribed spacer (ITS) region of ribosomal DNA, the  $\beta$ -tubulin and Calmodulin (CaM) genes.

**Results:** Overall, members of *Aspergillus* section *Fumigati* were the most common group (71%), followed by section *Veriscolores* (7%), section *Usti* (4%), section *Tanneri* (4%), section *Terrei* (3%), section *Nigri* (3%) and section *Nidulantes* (3%). *Aspergillus* species belong to sections *Falvi*, *Clavati*, *Flavipedes*, and *Circumdati* were less frequent, and each counted for only 1% of the total isolates identified.

Notably, cryptic, and non-*fumigatus* members of section *Fumigati* comprised only 12% of the isolates, including *A. felis*, *A. udagawae*, *A. lentulus*, *A. thermanatus*, *A. viridimutans*, and *A. pseudoviridimutans*, while *A. fumigatus* was the dominant species (88%).

MALDI-TOF assay was able to properly differentiate sections of *Aspergillus* from each other. However, PCR-sequencing of the  $\beta$ -tubulin gene was the most reliable target to separate the cryptic species of each section.

**Conclusion:** Our study shows that frequency of rare and cryptic *Aspergillus* species that primarily affect patients with PIDs may significantly differ from those with acquired immunodeficiencies.

Due to their lower susceptibility to available antifungal agents than *A. fumigatus*, correct and prompt identification at the species level is critical for appropriate therapy to improve patient outcomes.

In addition, DNA sequence-based species identification targeting  $\beta$ -tubulin gene is more accurate than ITS and CaM genes and using MALDI-TOF to differentiate the emerging and cryptic *Aspergillus* species.