

REVIEW ARTICLE

Convergent regional brain abnormalities in behavioral variant frontotemporal dementia: A neuroimaging meta-analysis of 73 studies

Aida Kamalian¹ | Tina Khodadadifar² | Amin Saberi^{3,4} | Maryam Masoudi¹ |
Julia A. Camilleri^{3,4} | Claudia R. Eickhoff^{5,6} | Mojtaba Zarei⁷ | Lorenzo Pasquini⁸ |
Angela R. Laird⁹ | Peter T. Fox^{10,11} | Simon B. Eickhoff^{3,4} | Masoud Tahmasian^{3,4}

¹School of Medicine, Tehran University of Medical Sciences, Tehran, Iran

²School of Cognitive Sciences, Institute for Research in Fundamental Sciences, Tehran, Iran

³Institute of Neuroscience and Medicine, Brain and Behavior (INM-7), Research Center Jülich, Jülich, Germany

⁴Institute for Systems Neuroscience, Medical Faculty, Heinrich-Heine University Düsseldorf, Düsseldorf, Germany

⁵Institute of Clinical Neuroscience and Medical Psychology, Heinrich Heine University Düsseldorf, Düsseldorf, Germany

⁶Institute of Neuroscience and Medicine, Research Center Jülich, Structural and Functional Organisation of the Brain (INM-1), Jülich, Germany

⁷Institute of Medical Science and Technology, Shahid Beheshti University, Tehran, Iran

⁸Department of Neurology, Memory and Aging Center, University of California-San Francisco, San Francisco, California, USA

⁹Department of Physics, Florida International University, Miami, Florida, USA

¹⁰Research Imaging Institute, University of Texas Health Science Center, San Antonio, Texas, USA

¹¹South Texas Veterans Health Care System, San Antonio, Texas, USA

Correspondence

Masoud Tahmasian, Institute of Neuroscience and Medicine, Brain & Behaviour (INM-7), Research Centre Jülich, Wilhelm-Johnen-Straße, Jülich, 52428, Germany.
Email: m.tahmasian@fz-juelich.de

Aida Kamalian and Tina Khodadadifar contributed equally to this work.

Abstract

Introduction: Numerous studies have reported brain alterations in behavioral variant frontotemporal dementia (bvFTD). However, they pointed to inconsistent findings.

Methods: We used a meta-analytic approach to identify the convergent structural and functional brain abnormalities in bvFTD. Following current best-practice neuroimaging meta-analysis guidelines, we searched PubMed and Embase databases and performed reference tracking. Then, the coordinates of group comparisons between bvFTD and controls from 73 studies were extracted and tested for convergence using activation likelihood estimation.

Results: We identified convergent abnormalities in the anterior cingulate cortices, anterior insula, amygdala, paracingulate, striatum, and hippocampus. Task-based and resting-state functional connectivity pointed to the networks that are connected to the obtained consistent regions. Functional decoding analyses suggested associated dysfunction of emotional processing, interoception, reward processing, higher-order cognitive functions, and olfactory and gustatory perceptions in bvFTD.

This is an open access article under the terms of the [Creative Commons Attribution-NonCommercial](https://creativecommons.org/licenses/by-nc/4.0/) License, which permits use, distribution and reproduction in any medium, provided the original work is properly cited and is not used for commercial purposes.

© 2022 The Authors. *Alzheimer's & Dementia: Diagnosis, Assessment & Disease Monitoring* published by Wiley Periodicals, LLC on behalf of Alzheimer's Association.

Discussion: Our findings highlighted the key role of the salience network and subcortical regions in the pathophysiology of bvFTD.

KEYWORDS

activation likelihood estimation, behavioral variant frontotemporal dementia, functional decoding, hierarchical clustering, meta-analytic connectivity modeling, resting state functional connectivity, voxel-based physiology, voxel-based morphometry

1 | INTRODUCTION

Behavioral-variant frontotemporal dementia (bvFTD) is a neurodegenerative syndrome characterized by neurodegeneration in the frontal and anterior temporal lobes leading to insidious and progressive changes in behavior, personality, and social functions.¹ BvFTD is the most common frontotemporal dementia (FTD) syndrome and the second major cause of early-onset dementia after Alzheimer's disease (AD).¹ Given the heterogeneous symptomology and gradual course of the disease, early detection of bvFTD is often abstruse and causes frustrating experiences for patients and relatives.² Accordingly, the current bvFTD diagnostic criteria has incorporated neuroimaging findings to improve the accuracy of clinical evaluation, particularly in early stages.³

The most identified structural and functional brain changes in the early stages of bvFTD target a group of interconnected brain regions, so-called "salience network" (SN), which is associated with social-emotional processing.¹ However, individual neuroimaging studies in bvFTD point to divergent findings due to heterogeneous clinical samples, diversity of imaging modalities, flexible analyses, and statistical methods. Thus quantitative assessment of neural abnormalities using neuroimaging meta-analysis is needed to overcome such divergence in the bvFTD literature.^{4,5} There are a few prior bvFTD neuroimaging meta-analyses that have indicated atrophy, hypoconnectivity, and hypometabolism in a wide number of brain regions covering the frontomedial cortex, basal ganglia, anterior insula, and the temporal cortex.⁶⁻⁸ However, these previous meta-analyses were mostly unimodal (i.e., using voxel-based morphometry [VBM] studies only or resting-state voxel-based physiology [VBP] studies of fluorodeoxyglucose-positron emission tomography (FDG-PET) only, or resting-state fMRI [rs-fMRI] only),⁶⁻⁸ and included a low number of patients, various selection criteria, and often used liberal statistical methods, which increases the opportunity for false-positive results.⁹ Moreover, previous meta-analyses have pooled only structural (VBM) studies, highlighting the role of SN in bvFTD.⁶ Thus a multimodal meta-analysis on task activation, VBM and VBP studies, might provide more information on the pathophysiology of bvFTD. Similar studies have provided comprehensive assessment of disease-related effects on attention-deficit/hyperactivity disorder (ADHD)¹⁰ and major depressive disorder.¹¹

To elucidate consensus structural and functional regional aberrations in bvFTD, we applied activation likelihood estimation (ALE), the most commonly applied algorithm among the coordinate-based

meta-analysis (CBMA) methods, which assesses regional convergence between foci obtained from group comparison experiments.¹² Next, we located brain co-activation patterns using meta-analytic connectivity modeling (MACM)¹³ and resting-state functional connectivity (RSFC)¹⁴ to reveal networks connected to the meta-analytically obtained regions in task-based and resting-state experiments, respectively. Finally, we performed hierarchical clustering analysis based on the pairwise RSFC profile and functional decoding of the convergent clusters to reveal sub-networks between convergent regions and assess the mental functions associated with these regions, respectively. We assessed functional characteristics of the identified regions using the BrainMap data set.¹⁵

2 | METHODS AND MATERIALS

The present large-scale CBMA was performed following the recently developed, best-practice guidelines for neuroimaging meta-analyses^{4,5} and adhering to the Preferred Reporting Items for Systematic Reviews and Meta-Analyses (PRISMA) statement.^{16,17} The protocol for this study was pre-registered on International Prospective Register of Systematic Reviews (PROSPERO, code: CRD42020127902).

2.1 | Search strategy, selection criteria, and quality appraisal

We performed a systematic literature search (up to May 2020) to identify structural and functional neuroimaging studies that compared bvFTD patients with their matched healthy controls (details are reported in the supplement). Studies were included if they (1) included clinically diagnosed bvFTD patients with no concurrent psychiatric diagnosis (e.g., major depressive disorder and bipolar mood disorder), other forms of dementia or neurological symptoms, and no history of alcohol and substance abuse,^{3,18} (2) included at least six participants in either the patient or healthy group; (3) used VBM, fMRI (resting-state or task based), and FDG-PET as the imaging modality; (4) reported the coordinates of between-group contrasts in a defined stochastic space (i.e., Montreal Neurological Institute [MNI] or Talairach); and (5) performed a whole-brain analysis. Thus, studies using seed-based functional connectivity (FC), diffusion tensor imaging (DTI), and cortical thickness methods were all excluded, as suggested previously.^{4,5}

RESEARCH IN CONTEXT

- 1. Systematic Review:** Following the best-practice guidelines to conduct neuroimaging meta-analyses, in this large-scale meta-analysis we searched PubMed and Embase databases and performed reference tracking to identify convergent regional abnormality across structural and functional neuroimaging studies on behavioral-variant frontotemporal dementia (bvFTD).
- 2. Interpretation:** Our findings found consistent regional brain abnormality in the salience network and subcortical regions in bvFTD.
- 3. Future Directions:** The future individual and meta-analysis studies on each specific phenotype of bvFTD are a worthwhile endeavor to understand more about the pathophysiology of bvFTD.

We used a 10-point checklist developed by Strakowski et al.¹⁹ and employed by previous meta-analyses to assess individual study quality based on imaging methodology and clinical and demographic properties of the study.^{20–22} The quality assessment score of included studies are reported in Table S1.

2.2 | Activation likelihood estimation analysis

The revised ALE algorithm was used to identify convergent patterns of brain alterations by showing a convergence of reported coordinates across experiments, which is higher than expected under a random spatial association.¹² The experiments were categorized by their effect direction (increases/decreases) and imaging modalities (see the Supplement for details). Separate ALE meta-analyses were performed on four subsets of the experiments: (1) pooling all experiments together; (2) experiments reporting decreases in activity/connectivity, metabolism, or gray matter volume (Control > bvFTD); (3) VBM experiments; and (4) combination of functional imaging (FDG-PET, resting-state fMRI (rs-fMRI), task-based fMRI (t-fMRI)) experiments. The other sets of experiments, including those categorized based on diagnostic criteria, did not reach the minimum required number for sufficient power (≥ 17).⁹

2.3 | Meta-analytic connectivity modeling (MACM) and resting-state functional connectivity (RSFC)

We investigated the task-based and task-free functional connectivity profiles of the obtained regions using MACM¹³ and RSFC,¹⁴ respectively. MACM analysis uses task-based functional neuroimaging studies to meta-analytically identify regions that are co-activated across a range of different tasks with the seed regions, whereas RSFC iden-

tifies task-free FC patterns of the convergent meta-analytic clusters. A more detailed description of each analysis is available in the Supplement.

2.4 | Hierarchical clustering (HC) and functional decoding (FD)

We performed HC analysis based on the pairwise RSFC profile of the identified regions to reveal the sub-networks associated with the convergent regions. Finally, we assessed the functional characteristics of the identified regions using the BrainMap data set.¹⁵ Detailed description of each analysis is available in the Supplement.

3 | RESULTS

3.1 | Experiments included in the meta-analysis

After removing duplicate records, we screened a total number of 5045 abstracts and included 73 studies in our meta-analysis (Figure 1, Table S1). The excluded studies and the reasons of exclusion are reported in Table S2. Of the 495 studies excluded by full-text screening from both electronic databases and reference checking, 124 were excluded because the subjects were not bvFTD patients, 97 were excluded because they did not report coordinates significantly different between two groups, and 78 were excluded due to using regions of interest (detailed reasons for exclusion are reported in Figure 1). Among the included papers, 27 studies were performed based on the FRONTIER open data set, and thus their data were merged to minimize within-group effects.⁴ In addition, eight other studies had partially overlapping samples, and they were pooled together as well. Finally, 31 independent experiments (of 73 studies) comprising 1672 bvFTD patients and 3884 healthy participants were used for ALE analysis. These experiments include VBM ($N = 20$), t-fMRI ($N = 1$), rs-fMRI ($N = 2$), or FDG-PET ($N = 12$). Of note, some experiments used more than one imaging modality; therefore, the collective number of experiments included in each imaging modality exceeds the number of total experiments. A decrease in functional/structural experiments (Controls > bvFTD) was observed more commonly ($N = 28$) and only a few studies ($N = 3$) reported increased functional/structural experiments (bvFTD > Controls).

3.2 | Convergent regional abnormalities in bvFTD

First, we assessed consistent structural and functional abnormalities by pooling all experiments ($N = 31$) and identified five convergent clusters in the following regions ($P < .05$, cluster-level family-wise error (cFWE)): (i) the right amygdala and hippocampus, (ii) the left caudate and subcallosal cortex, (iii) the bilateral paracingulate gyrus and anterior cingulate cortex (ACC), (iv) the bilateral paracingulate gyrus extending to small portions of the medial orbitofrontal cortex, and (v)

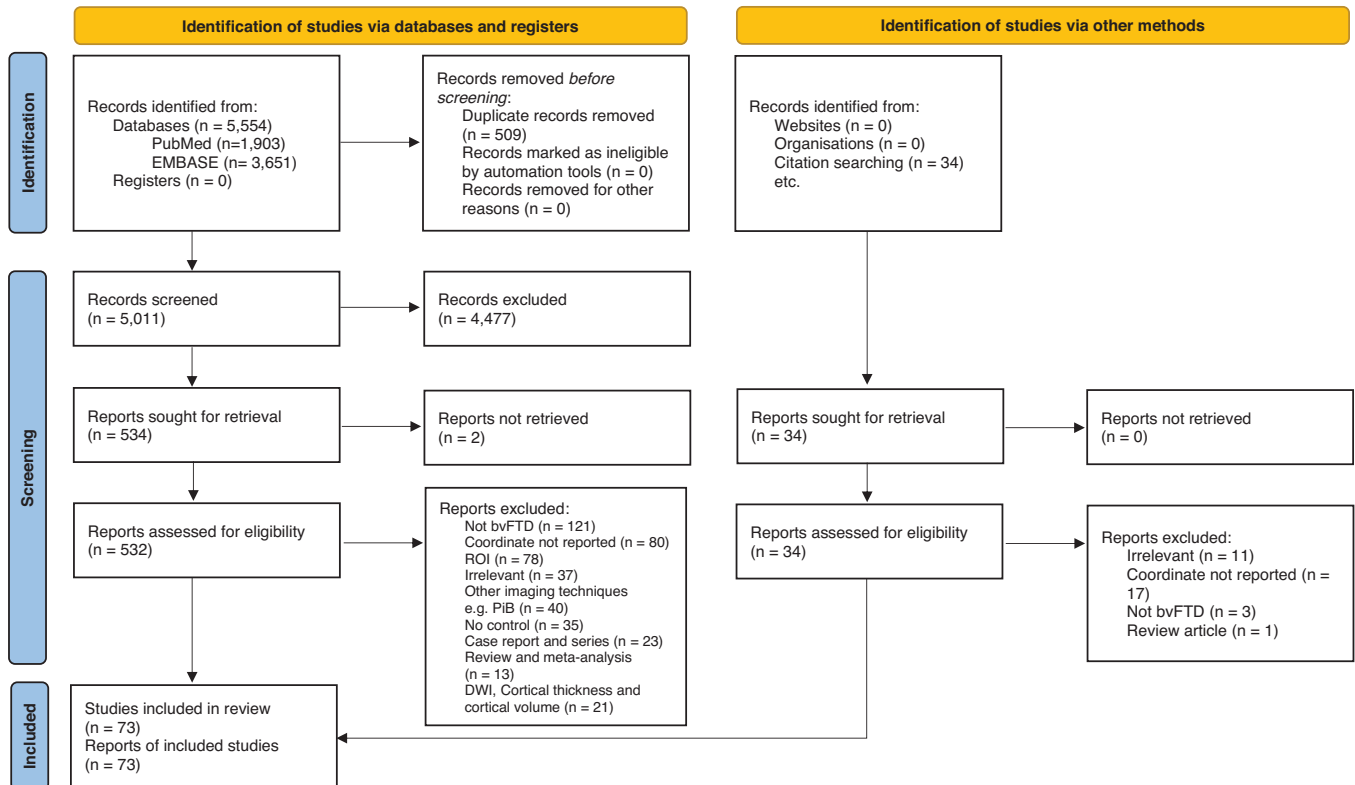


FIGURE 1 PRISMA flowchart of study selection. PRISMA, Preferred Reporting Items for Systematic Reviews and Meta-Analyses

the left anterior insular cortex (AIC) extending to frontal orbital cortex (Figure 2A, Table 1). Most of the included experiments reported “decrease” contrasts (Controls > bvFTD). So, performing ALE analysis on these experiments showed very similar convergent clusters ($P < .05$, cFWE) (Figure 2B).

Next, we performed separate ALE analyses for the imaging modality by categorizing the experiments to structural ($N = 21$) and functional ($N = 17$). The ALE analysis of structural (i.e., VBM) experiments revealed clusters of convergence in the amygdala and hippocampus, paracingulate gyrus and frontal medial cortex, as well as the AIC and frontal orbital cortex ($P < .05$, cFWE) (Table 2, Figure 2C). The location of these clusters corresponded to the first, third, and fifth clusters of the all-experiments analysis, respectively, but was smaller in size. Confining the analysis to the functional experiments (i.e., FDG-PET, rs-fMRI, and t-fMRI) demonstrated three significant clusters in the left caudate and accumbens, paracingulate gyrus and ACC, and another more rostral region in the ACC ($P < .05$, cFWE). The last cluster, unlike the other two, did not correspond to any of the regions identified in the all-experiments analysis (Figure 2C).

3.3 | Connectivity patterns of the identified convergent regions

The MACM and RSFC analyses pointed to the joint networks that are connected to the obtained clusters (Figure 3, Figures S1 and S2). The overlap of MACM and RSFC maps revealed significant task-based

and task-free co-activation of the amygdala and hippocampus cluster with the striatum, thalamus, fusiform gyrus, inferior frontal gyrus, and midline frontal regions. MACM analysis demonstrated that the amygdala/hippocampus cluster has significant co-activation with the AIC. In addition, RSFC analysis showed additional task-free connectivity of amygdala/hippocampus cluster with the entorhinal cortex, superior and middle temporal gyri, precuneus, posterior cingulate cortex, and cerebellum.

The convergent cluster in the left caudate and subcallosal cortex was associated with the striatum, thalamus, AIC, midline frontal regions, posterior cingulate gyrus, and cerebellum in both MACM and RSFC analyses, but with the superior lateral occipital cortex and middle temporal gyrus only in task-free analysis, and the left superior parietal lobule and parietal operculum only in task-based analysis.

The rostral paracingulate and frontal medial cortex cluster showed task-based coactivation and RSFC with the medial frontal regions, posterior cingulate cortex, precuneus, hippocampus, amygdala, and superior lateral occipital cortex, but was also functionally connected to the medial thalamus, AIC, Heschl’s gyrus, and cerebellum only in RSFC analysis. Most of the significant regions for this cluster in the MACM analysis were also observed in the RSFC analysis.

The more caudal significant cluster in the paracingulate and ACC was similarly functionally connected to the medial frontal regions, AIC, striatum, thalamus, middle and inferior frontal gyri, and posterior cingulate cortex in MACM and RSFC analyses, but additionally revealed RSFC with the cerebellum, and meta-analytic co-activation with the superior parietal lobule and right angular gyrus.

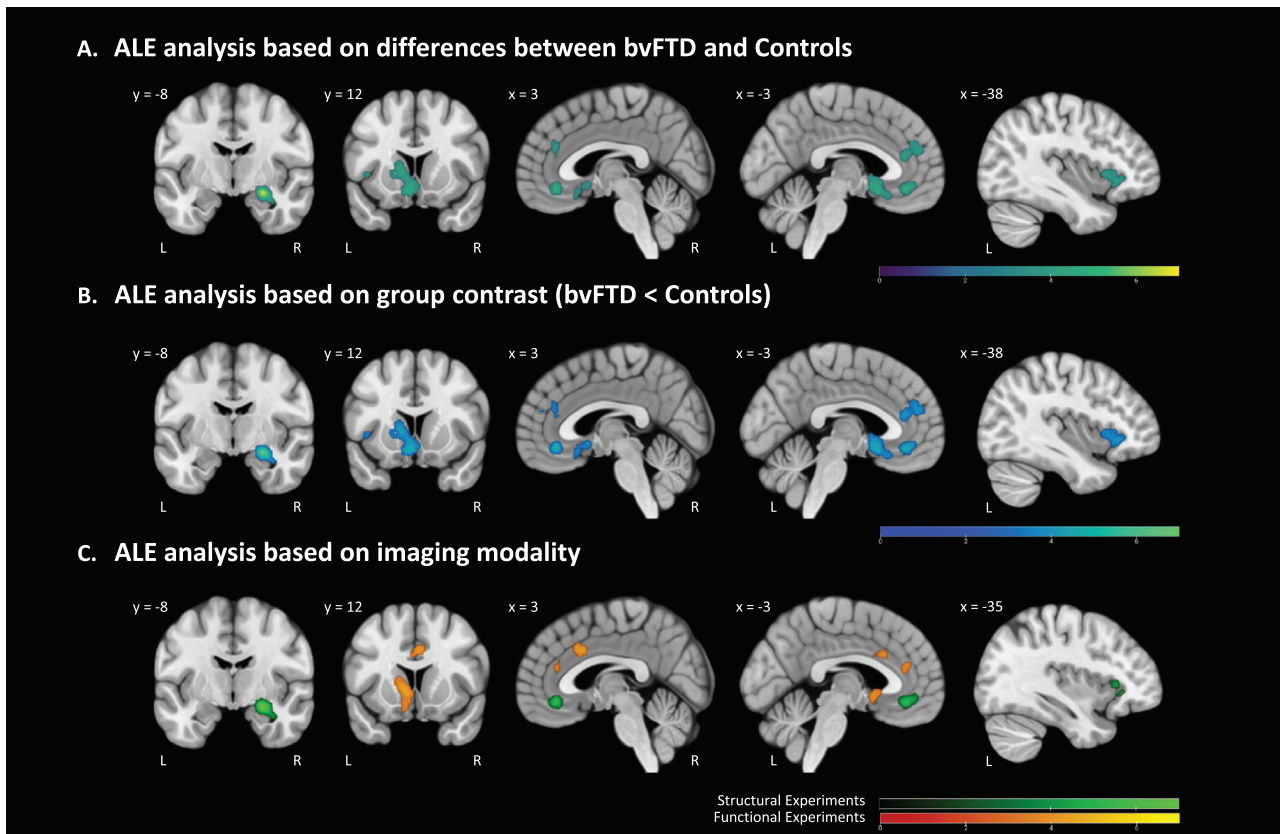


FIGURE 2 Convergence of brain imaging findings in bvFTD compared to healthy controls across all experiments. (A) Experiments reporting atrophy/hypoactivation and (B) experiments using functional (C, orange) or structural (C, green) modalities. The coordinates are in MNI space. Color bars represent Z values. ALE, activation likelihood estimation; bvFTD, behavioral-variant frontotemporal dementia; MNI, Montreal Neurological Institute

TABLE 1 The MNI coordinates of convergent regional abnormalities in bvFTD identified by ALE analysis on all experiments ($P < .05$, cFWE)

Comparison	Cluster	Region	Number of voxels	MNI coordinates (X, Y, Z)
bvFTD < HC	i ^a	The right amygdala and hippocampus	240	24, -6, -14
	ii ^b	The left caudate and subcallosal cortex	534	-4, 12, -12
	iii ^c	Bilateral paracingulate gyrus and ACC	400	10, 34, 28
	iv ^d	Bilateral paracingulate gyrus extending to small portions of the medial orbitofrontal cortex	163	0, 36, -10
	v ^e	The left AIC extending to frontal orbital cortex	173	-32, 22, 4

bvFTD, behavioral variant of frontotemporal dementia; HC, healthy control; MNI, Montreal Neurological Institute (atlas); VBM, voxel-based morphometry; PET, 18F-fluorodeoxyglucose positron emission tomography; rs-fMRI, resting-state functional magnetic resonance imaging; t-fMRI, task-based functional magnetic resonance imaging; ACC, anterior cingulate cortex; AIC, anterior insular cortex; cFWE, cluster family-wise error.

^aTotal 17.8% of voxels located in CA1, 13.1% in centromedial amygdala, 11.1% in dentate gyrus, 11.4% in ventromedial amygdala, and 7.7% in basolateral amygdala. Convergence in this cluster was mostly driven by VBM experiments (87.8%).

^bTotal 5.8% voxels located in s24, 13.8% in area 25, 8.3% in area 33, 4.8 in area Fo2. Convergence in this cluster was driven VBM (54.6%), FDG-PET (28.5%), or both VBM and FDG-PET (16.8%).

^cTotal 14.1% of the volume is located in area 24c, 11.4% in area p32, 10.4% in area p24ab, and 2.6% in area 33. Convergence in this cluster was driven by VBM (53.8%), FDG-PET (33.6%), both VBM and rs-fMRI (7.3%), or both VBM and FDG-PET (5.1%) experiments.

^dTotal 52.5% of voxels located in area s32, 2.19% in area s24, 8.9% in area p24ab, and 3.6% in area p32. This cluster was mostly driven by VBM experiments (98.5%).

^eTotal 30.9% of voxels located in area Id6, 29.9% in area Id7, and 9.6% in area OP8. Convergence in this cluster was driven by VBM experiments (72.3%) and FDG-PET (27.2%).

TABLE 2 The MNI coordinates of convergent regional abnormalities in bvFTD identified by ALE analysis on modality experiments ($P < .05$, cFWE)

Comparison	Modality	Region	Number of voxels	MNI coordinates (X, Y, Z)
bvFTD<HC	VBM	The amygdala and hippocampus	304	24, -6, -14
		Paracingulate gyrus and frontal medial cortex	203	0, 36, -10
		AIC and frontal orbital cortex	100	-32, 22, 4
bvFTD<HC	FDG-PET, rs-fMRI, t-fMRI ^a	Left caudate and accumbens	276	-8, 10, 0
		Paracingulate gyrus and ACC	296	10, 34, 26
		Rostral region of the ACC	156	4, 14, 34

bvFTD, behavioral variant of frontotemporal dementia; HC, healthy control; MNI, Montreal Neurological Institute (atlas); VBM, voxel-based morphometry; PET, 18F-fluorodeoxyglucose positron emission tomography; rs-fMRI, resting-state functional magnetic resonance imaging; t-fMRI, task-based functional magnetic resonance imaging; ACC, anterior cingulate cortex; AIC, anterior insular cortex; cFWE, cluster family-wise error.

^aConvergence in the significant clusters of functional analysis was mainly driven by FDG-PET (67.1%–100% contribution) and rs-fMRI experiments (11.1%–32.9%), whereas t-fMRI experiments had no contribution.

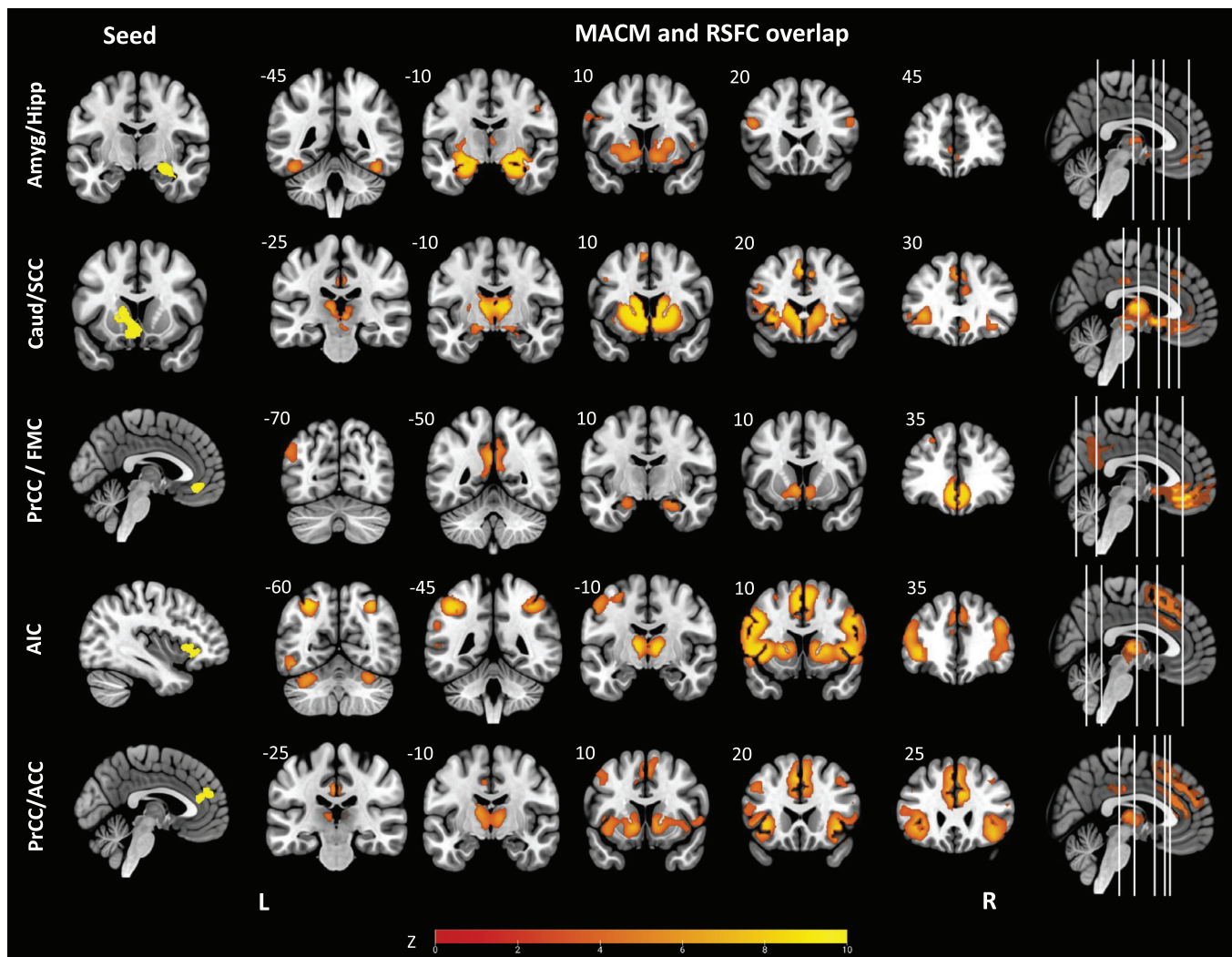


FIGURE 3 The overlap of resting-state functional connectivity and meta-analytic connectivity maps of convergent regions in the all-effects ALE. The coordinates are in MNI space. MACM, meta-analytic connectivity map; RSFC, resting-state functional connectivity; Amyg, amygdala; Hipp, hippocampus; Caud, caudate nucleus; SCC, subcallosal cortex; PrCC, paracingulate cortex; FMC, frontomedial cortex; AIC, anterior insular cortex; ACC, anterior cingulate cortex; ALE, activation likelihood estimation; MNI, Montreal Neurological Institute

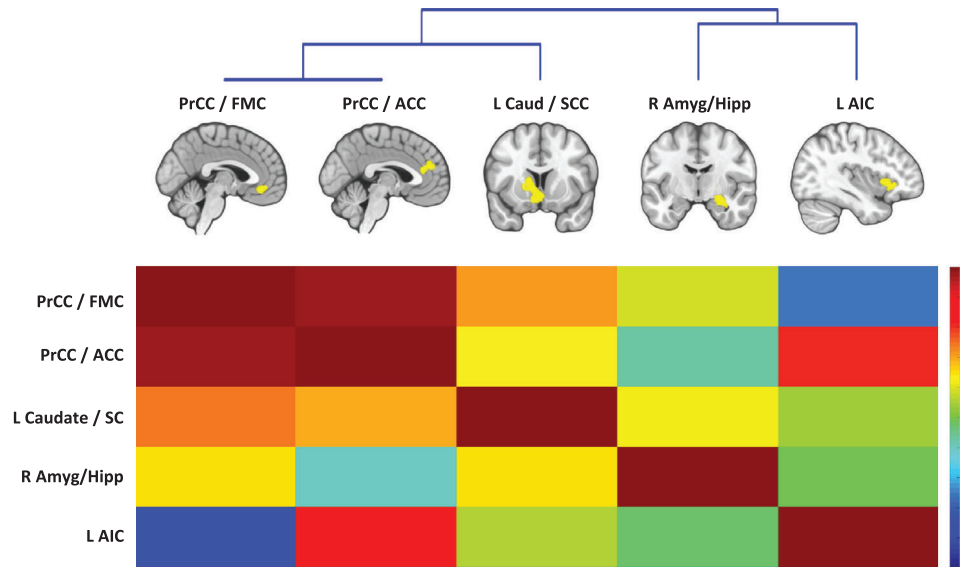


FIGURE 4 Hierarchical clustering of convergent regions in the all-effects ALE. Below the pair-wise functional connectivity matrix of the convergent regions is shown after Fischer's z-transformation and normalization to the maximum. Amyg, amygdala; Hipp, hippocampus; Caud, caudate nucleus; SCC, subcallosal cortex; PrCC, paracingulate cortex; FMC, frontomedial cortex; AIC, anterior insular cortex; ACC, anterior cingulate cortex; ALE, activation likelihood estimation; MNI, Montreal Neurological Institute

The AIC cluster was functionally connected with the paracingulate gyrus and ACC, striatum, thalamus, middle and inferior frontal gyri, superior parietal lobule, and different regions within the cerebellum during both task and rest. In addition, the AIC showed only task-based functional connectivity with the precentral gyrus, fusiform gyrus, and superior parietal lobule; and RSFC with the temporal pole, Heschl's gyrus, intracalcarine cortex, and lingual gyrus. All these results were corrected for cFWE.

3.4 | Hierarchical clustering of convergent findings

To identify functionally coherent sub-networks of the identified consistent regions, we performed hierarchical clustering analysis based on their pairwise RSFC profile. In this analysis, at the first level, we identified two main sub-networks, namely the insula-amygdala network, and the cingulo-striatal network including the ACC, paracingulate cortex, frontal medial cortex, subcallosal cortex, and striatum. The latter was grouped into two additional sub-networks at the second level: one including the two clusters located in the medial frontal lobe, and the other one including the convergent cluster in the striatum and subcallosal cortex (Figure 4).

3.5 | Functional decoding of convergent clusters

Our forward-inference functional decoding of the identified regions using the BrainMap database demonstrated their significant involvement in emotional processing, interoception, reward processing, higher-order cognitive functions, as well as olfactory and gustatory

perception (Figure 5). More specifically, the amygdala/hippocampus cluster was activated in olfactory perception, processing of negative and positive emotions, and reward processing. The convergent cluster in the left caudate and subcallosal cortex was associated primarily with reward processing, gustatory perception, cognitive reasoning, and sexual interoception. Gustatory perception and reward processing were also associated with activations in the rostral paracingulate gyrus/frontal medial cortex cluster. The more caudal paracingulate gyrus and the ACC cluster was more likely to be activated in cognitive reasoning and response to rewards. Finally, the AIC was associated with thermal interoception, processing of disgust, and language semantics. All these results were corrected for false discovery rate (FDR).

4 | DISCUSSION

We performed a large-scale CBMA on both structural and functional brain studies on bvFTD, nearly a decade after the revision of its diagnostic criteria, and we found consistent abnormalities in five clusters including the AIC, ACC, paracingulate cortex (PrCC), subcallosal cortex, striatum, amygdala, and anterior hippocampus in patients with bvFTD compared to healthy subjects. These regions predominantly showed decreased gray matter volume, functional hypoactivation, or dysconnectivity, to various degrees in each region. Although the abnormalities in the striatum were mainly functional, structural abnormalities were more predominant in the AIC, amygdala, and anterior hippocampus, and midline frontal regions were both functionally and structurally impaired. In addition, we used MACM and RSFC analyses to characterize the connectivity pattern of the convergent regions and observed significant co-activation of them with each other, and with




FIGURE 5 Functional decoding analysis of convergent regions in the all-effects ALE based on BrainMap behavioral domain categories and subcategories. The spider plot values are likelihood ratios. Amyg, amygdala; Hipp, hippocampus; Caud, caudate nucleus; SCC, subcallosal cortex; PrCC, paracingulate cortex; FMC, frontomedial cortex; AIC, anterior insular cortex; ACC, anterior cingulate cortex; ALE, activation likelihood estimation; MNI, Montreal Neurological Institute

additional brain regions including the thalamus, lateral prefrontal cortex, and association cortices in the parietal lobe. Next, using hierarchical clustering of the convergent regions, we classified them into two main groups: one including the AIC, amygdala, and hippocampus, and the other one including the midline frontal areas and striatum. Moreover, functional decoding analysis showed involvement of the former set of regions in emotional processing, and of the latter in reward processing and higher-order cognitive functions.

4.1 | The key role of the salience network in bvFTD

The cortical layer 5b of AIC and pregenual ACC (pgACC) contains a specialized type of large spindle-shaped projection neurons called von Economo neurons (VEN), which are presumed to be involved in social cognition and self-awareness.²³ The number of these neurons in the AIC and pgACC is significantly depleted in patients with bvFTD,^{24–26} parallel to clinical severity of bvFTD, and even in the absence of gross atrophy of these regions.²³ Accordingly, histopathological and imaging studies have suggested that the AIC and pgACC are among the earliest atrophied regions in bvFTD.²⁷ These regions are the key hubs of the SN, which guides behavior in response to the perceived salience of current external/internal events, that is, their significance for the survival of the individuals.²⁶ In this network, the AIC and pgACC play distinct, but interdependent roles, acting as afferent (“sensory”) and efferent (“motor”) hubs of the SN, respectively. More specifically, the AIC detects and represents subjective emotional, homeostatic, social, and motivational salience of the immediate environmental or bodily states,^{28,29} and the ACC initiates goal-directed behaviors in response to these salient stimuli.³⁰ Several studies have reported decreased FC within the SN in patients with bvFTD.³¹ It is well-documented that the disturbed main hubs of the SN can lead to the main characteris-

tic symptoms of bvFTD, including impaired emotional processing and social cognition, disinhibition, executive dysfunction, and apathy.

Impaired emotional recognition is a common symptom in bvFTD and has been reported for different types of emotional stimuli, including facial expressions, non-verbal emotional sounds, or music.³² This impairment is selective for negative emotions, and patients’ ability to recognize and react to positive emotions is often spared³³ or even disproportionately increased.³⁴ In addition to emotional recognition, patients with bvFTD have deficits in suppressing emotions, generating emotions, and perceiving self-conscious emotions.³⁵ Decreased gray matter volumes of the amygdala and AIC have been reported in bvFTD patients with impaired emotional recognition of facial expressions.³⁶ Amygdala atrophy, similar to AIC, occurs early in the course of bvFTD,³⁷ and was consistently reported in our included studies. The amygdala has reciprocal connections to the ventral striatum, as well as limbic and paralimbic brain regions,³⁷ and has a central role in recognition of emotions, but also in reward processing, motivation, attention, learning, and memory.³⁸ In addition, the amygdala along with the temporal pole, ventral striatum, and thalamus, is responsible for the SN functions that include providing the AIC with the information about socio-emotional valence of the external and internal world. The information from these different sources is integrated in the AIC, where the salience of the current state is determined/represented and passed on to more downstream regions.³⁰

Lack of empathy, that is, impaired affective social cognition, is a core diagnostic feature of bvFTD³ and is related closely to the deficits in emotional processing.³⁹ Empathy indicates an ability to identify and share the emotions and needs of other individuals.⁴⁰ Deficits in empathy can have a detrimental effect on the relationships of patients with their relatives and caregivers.⁴¹ In addition, lack of empathy, and impaired social cognition in general, can result in disinhibition of socially inappropriate behaviors. More specifically, disinhibition might be a consequence of patients’ inability to

correctly identify social and emotional signals and their associated punishments/rewards, thereby neglecting the negative consequences of their own social acts.³⁹ Recent neuroimaging meta-analyses on healthy individuals have shown that empathy is consistently associated with activation of regions including the AIC, amygdala, ACC, thalamus, and lateral frontal regions.^{42,43} In addition, individual differences in socioemotional sensitivity have been shown to correlate with FC of the SN,⁴⁴ and interestingly, socio-affective training aimed at improving empathy and compassion is associated with plasticity of the AIC.⁴⁴ Several neuroimaging studies on the neural correlates of empathy and social cognition in bvFTD patients have pointed to abnormalities in the similar regions, such as the insula, thalamus, amygdala, inferior frontal gyrus, lateral orbitofrontal cortex, and medial frontal regions, including subcallosal and midcingulate cortex.^{34,44–46} Of interest, similar regions are involved in impaired socio-emotional dysfunctions of other neuropsychiatric disorders, such as autism spectrum disorder,⁴⁷ conduct disorder,⁴⁸ and schizophrenia.⁴⁹

Based on the “simulation theory of empathy,” humans use their own mind as a model to predict and understand the thoughts and feelings of others.²⁸ Therefore, and as self-awareness of affective states largely relies on interoception, that is, awareness of internal bodily homeostatic state, it has been suggested that interoception plays an important role in empathy.⁵⁰ These two closely related functions are presumed to be mediated by the AIC, where dual and corresponding mappings for subjective and empathetic feeling states are represented.⁴⁰ In line with this hypothesis, an fMRI study demonstrated that when subjects are interoceptively aware (attending to their heartbeats), they show a higher empathy-related brain activity in the AIC after observing emotionally valent facial expressions.⁵⁰ Patients with bvFTD display impaired interoception, as has been shown by their decreased performance in the heartbeat detection task,⁵¹ or their lower sensitivity to pain and temperature,⁵² which interestingly is associated with the atrophy of insula and fronto-temporal regions.⁵¹ The lack of empathy in bvFTD patients could therefore be partially attributable to the impairments in interoception, which are due to AIC dysfunction.

According to our findings in the AIC, it is worth noting that this convergent cluster was located more on the dorsal surface of the left AIC. This region, as suggested by previous studies and our functional decoding, is more involved in cognitive control and semantic functions,⁵³ as opposed to the right and ventral AIC, which has a key role in socio-emotional processing.⁵⁴ Although we include only studies on bvFTD patients, this finding suggests that some studies might include bvFTD patients with concomitant language abnormalities or semantic variants of FTD. Nevertheless, the segregation of functions in the dorsal and ventral AIC is not as clear-cut, and different functions of AIC have shown to converge on its dorsal surface.⁵⁵ In addition, our functional decoding analysis showed that the left dorsal AIC is more likely to be activated in interoception than in language functions, and as mentioned earlier, interoception is a key component of empathy. Of note, previous neuroimaging meta-analyses of empathy have also shown activation of both left and right as well as ventral and dorsal AIC in response to emotional stimuli.⁴³

4.2 | Limbic system abnormalities in bvFTD result in executive dysfunction and apathy

The ACC, as the efferent hub of SN, coordinates initiation of appropriate behaviors in response to the states that are emotionally, socially, or homeostatically significant.³⁰ This function is mainly accomplished by switching the brain activity from the default mode network (DMN) to the central executive network (CEN),⁵⁶ which refers to the brain areas that are engaged during executive functions, that is, cognitively demanding tasks that require sustained attention, including working memory, problem solving, planning, inhibiting, and development or implementation of strategies.⁵⁷ Executive dysfunction is a prominent symptom and a key diagnostic feature of bvFTD, which affects many domains of higher-order brain functions, and contributes to development of apathy or inertia (see subsequent text).⁵⁸ Meta-analytic studies have suggested that in healthy individuals, the frontoparietal and subcortical structures such as the dorsolateral prefrontal cortex, superior parietal lobules, dorsal ACC, thalamus, and striatum are involved in executive functions.⁵⁷ Accordingly, executive dysfunction in bvFTD patients is associated with atrophy of anterior cingulate and midcingulate gyri, medial frontal cortex, and lateral prefrontal cortex.⁵⁹ In the present meta-analysis, we found consistent abnormalities in the ACC and caudate nucleus in bvFTD patients. These regions were grouped together in the hierarchical clustering, and showed FC with each other, and with other key regions of the CEN including the prefrontal cortex and superior parietal lobule. However, we found no consistent abnormality in the lateral frontal and parietal regions classically associated with executive functions. This finding suggests that in addition to the primary deficits in the ACC and striatum, executive dysfunction in bvFTD patients might be secondary to their inability to engage these lateral cortical regions due to dysfunction in the ACC and SN. Furthermore, because impairments in classical executive functioning tasks occur later in the course of bvFTD,⁶⁰ some patients may not have yet developed abnormalities in lateral regions of the CEN, making it less likely to be identified consistently across the literature.

Psychopathology of apathy or inertia involves impairments in motivation, initiation, and planning/execution.² Although all three components are dysfunctional in bvFTD patients, lack of motivation is the most prominent abnormality, which contributes to apathy.⁶¹ Motivation refers to the ability of associating positive or negative affective signals with the value of actions and attempting to maximize value by seeking rewards and avoiding punishments.⁶² In this context, abnormal reward processing can lead to a lack of motivation, both by reducing the inclination to perform and complete tasks and the ability to comprehend the consequences of future actions.⁶³ Recent meta-analysis has shown that in healthy individuals, the striatum, insula, amygdala, thalamus, parahippocampal gyrus, and medial frontal regions such as the ACC are involved in reward processing.⁶⁴ We found convergent abnormalities in many of these reward-responsive regions including the left caudate, amygdala, paracingulate cortex, frontal medial cortex, and ACC. Of interest, motivational deficits in bvFTD patients are associated with atrophy of the orbitofrontal cortex and ACC.⁶⁵ These findings suggest that lack of motivation in bvFTD patients occurs as a

result of their decreased sensitivity to rewards and punishments, due to dysfunction of the ACC, orbitofrontal cortex, and striatum.⁶³

4.3 | The role of medial temporal lobe atrophy in amnesic features of bvFTD

Classically bvFTD has been mainly described as a predominantly behavioral disorder with less episodic memory impairment.³ However, patients with bvFTD, like other dementia syndromes, may have deficits in encoding and retrieval of autobiographical memories, comparable to that of AD.⁶⁶ It has been reported that impaired episodic memory functions in patients with bvFTD is attributable to their executive dysfunction, that is, their inability to properly monitor topics and events, check the relevance of incoming memories, and inhibit competing memories, due to frontal lobe abnormalities.²⁷ Although executive dysfunction can contribute to amnesia, it has been suggested that similar to AD, amnesic bvFTD patients have atrophy or dysfunction of the hippocampus and other medial temporal lobe (MTL) structures.^{66,67} Similar to these original studies, we found convergent atrophy in the CA1 and dentate gyrus of the right anterior hippocampus. However, this finding is rather new compared to previous neuroimaging meta-analyses on bvFTD, which reported no convergent abnormalities in the MTL.^{68,68} These findings, however, suggest that MTL atrophy and impaired episodic memory exist in bvFTD, and that, therefore, intact memory function may not constitute a suitable differentiating factor between bvFTD and AD.⁶⁹ An alternative explanation might be that because both bvFTD and AD are often diagnosed using clinical diagnostic criteria that are not certain,^{70,71} a portion of clinically diagnosed bvFTD patients, when assessed histopathologically, may actually have AD pathology (e.g., 12 of 63 patients⁷⁰), or that frontotemporal lobar degeneration⁷⁰ and AD cover a spectrum of neurodegenerative disorders with some bvFTD patients also having underlying AD pathology (and vice versa).⁷²

4.4 | Limitations and future directions

Our main limitation, which was in fact inherited from the included studies, was the heterogeneity of clinical samples, particularly regarding the severity of symptoms, histopathological subtypes, and molecular etiology of bvFTD. Several studies have suggested that distinct pathological or genetic subtypes of frontotemporal lobar degeneration⁷⁰ have different neuroanatomical correlates.⁷³ These subtypes are often difficult to determine, and therefore, very few studies had investigated them separately, preventing us from doing subgroup analyses on those specific subtypes. In addition, because most of the included studies had diagnosed bvFTD using the clinical criteria, it is possible that some of the patients had other disorders characterized by symptoms that can overlap with bvFTD, such as AD or other neuropsychiatric disorders.⁷⁴ Finally, two methodological limitations of our meta-analysis, which are common to all CBMA methods, were that (1) pooling of findings was based on the peak coordinates of significant regions, which essentially

ignores the volume and extent of clusters; and (2) conventional ALE analysis could miss out biological heterogeneity.

Because novel genetic and histopathological subtypes of bvFTD are introduced (C9ORF72 mutation or microtubule-associated protein tau (MAPT) expansion carriers or frontotemporal lobe degeneration (FTLD)-tau and FTLD with TDP-43 inclusions (FTLD-TDP), curiosity about the specific clinical and neuroimaging characteristics of these phenotypes is piqued.⁷³ Although these phenotypes are not diagnosed appropriately by the present criteria of bvFTD, they do manifest with their individual group of symptoms (e.g., C9ORF72 expansion carriers mostly present with psychiatric symptoms).⁷⁵ Looking further into the neurological and neuroimaging markers of genetically susceptible individuals (e.g., C9ORF72 expansion carriers) might give us invaluable insight into onset and pathophysiology of bvFTD. Therefore, the future individual and meta-analysis studies on each specific phenotype of bvFTD are a worthwhile endeavor to understand more about bvFTD.

5 | CONCLUSION

We replicated some of the findings of previous meta-analyses on bvFTD in the frontomedial areas, AIC, and striatum. In addition, we identified a cluster of convergence in the amygdala and hippocampus, probably by virtue of a higher number of structural and functional experiments, as well as the increased meta-analytic power. On the other hand, we found no convergence in some of the regions commonly reported in previous meta-analyses, namely, the lateral frontal cortical areas and thalamus. The results of our study suggest that: (1) dysfunctions of the AIC and amygdala in bvFTD patients may impair their socio-emotional processing and may lead to disinhibition of socially inappropriate behaviors and a lack of empathy; (2) abnormalities of midline frontal regions, basal ganglia, and amygdala in patients with bvFTD may be responsible for their executive dysfunction, as well as apathy primarily through a lack of motivation; and (3) hippocampal atrophy and amnesic symptoms may not suitably differentiate bvFTD and AD. In general, our results highlighted a crucial role of the salience network and subcortical regions in pathophysiology of bvFTD.

ACKNOWLEDGMENTS

National Institute of Mental Health (R01-MH074457), the Helmholtz Portfolio Theme “Supercomputing and Modeling for the Human Brain,” and the European Union’s Horizon 2020 Research and Innovation Programme under Grant Agreement No. 945539 (HBP SGA3); National Institutes of Health (NIH) grant K99-AG065457 to L.P.

Open access funding enabled and organized by Projekt DEAL.

CONFLICTS OF INTEREST

None of the authors report financial interests or potential conflicts of interest.

REFERENCES

1. Seeley WW. Behavioral variant frontotemporal dementia. *Continuum: Lifelong Learning in Neurology*. 2019. 25(1):76–100.

2. Ducharme S, Dols A, Laforce R, et al. Recommendations to distinguish behavioural variant frontotemporal dementia from psychiatric disorders. *Brain*. 2020;143(6):1632–1650.
3. Rascovsky K, Hodges JR, Knopman D, et al. Sensitivity of revised diagnostic criteria for the behavioural variant of frontotemporal dementia. *Brain*. 2011;134(9):2456–2477.
4. Müller VI, Cieslik EC, Laird AR, et al. Ten simple rules for neuroimaging meta-analysis. *Neurosci Biobehav Rev*. 2018;84:151–161.
5. Tahmasian M, Sepehry AA, Samea F, et al. Practical recommendations to conduct a neuroimaging meta-analysis for neuropsychiatric disorders. *Hum Brain Mapp*. 2019;40(17):5142–5154.
6. Pan PL, Song W, Yang J, et al. Gray matter atrophy in behavioral variant frontotemporal dementia: a meta-analysis of voxel-based morphometry studies. *Dement Geriatr Cogn Disord*. 2012;33(2-3):141–148.
7. Pievani M, Pini L, Ferrari C, et al. Coordinate-based meta-analysis of the default mode and salience network for target identification in non-invasive brain stimulation of Alzheimer's disease and behavioral variant frontotemporal dementia networks. *J Alzheimers Dis*. 2017;57(3):825–843.
8. Schroeter ML, Laird AR, Chwiesko C, et al. Conceptualizing neuropsychiatric diseases with multimodal data-driven meta-analyses—the case of behavioral variant frontotemporal dementia. *Cortex*. 2014;57:22–37.
9. Eickhoff SB, Nichols TE, Laird AR, et al. Behavior, sensitivity, and power of activation likelihood estimation characterized by massive empirical simulation. *Neuroimage*. 2016;137:70–85.
10. Samea F, Soluki S, Nejati V, et al. Brain alterations in children/adolescents with ADHD revisited: A neuroimaging meta-analysis of 96 structural and functional studies. *Neurosci Biobehav Rev*. 2019;100:1–8.
11. Gray JP, Müller VI, Eickhoff SB, Fox PT. Multimodal abnormalities of brain structure and function in major depressive disorder: a meta-analysis of neuroimaging studies. *Am J Psychiatry*. 2020;177(5):422–434.
12. Eickhoff SB, Bzdok D, Laird AR, Kurth F, Fox PT. Activation likelihood estimation meta-analysis revisited. *Neuroimage*. 2012;59(3):2349–2361.
13. Laird AR, Eickhoff SB, Kurth F, Fox PM. ALE meta-analysis workflows via the brainmap database: progress towards a probabilistic functional brain atlas. *Front Neuroinf*. 2009;3:23.
14. Shen K, Hutchison RM, Bezgin G, Everling S, McIntosh AR. Network structure shapes spontaneous functional connectivity dynamics. *J Neurosci*. 2015;35(14):5579–5588.
15. Laird AR, Lancaster JJ, Fox PT. Brainmap. *Neuroinformatics*. 2005;3(1):65–77.
16. Moher D, Liberati A, Tetzlaff J, et al. Preferred reporting items for systematic reviews and meta-analyses: the PRISMA statement. *PLoS Med*. 2009;6(7):e1000097.
17. Page MJ, McKenzie JE, Bossuyt PM, et al. The PRISMA 2020 statement: an updated guideline for reporting systematic reviews. *Int J Surg*. 2021;88:105906.
18. McKhann GM, Albert MS, Grossman M, Miller B, Dickson D, Trojanowski JQ. Clinical and pathological diagnosis of frontotemporal dementia: report of the Work Group on Frontotemporal Dementia and Pick's Disease. *Arch Neurol*. 2001;58(11):1803–1809.
19. Strakowski SM, DellBello MP, Adler C, Cecil KM, Sax KW. Neuroimaging in bipolar disorder. *Bipolar Disorders*. 2000;2(3):148–164.
20. Gentili C, Messerotti Benvenuti S, Lettieri G, Costa C, Cecchetti L. ROI and phobias: the effect of ROI approach on an ALE meta-analysis of specific phobias. *Hum Brain Mapp*. 2019;40(6):1814–1828.
21. McLachlan E, Rai S, Al-Shihabi A, et al. Neuroimaging correlates of false memory in 'Alzheimer's disease: a preliminary systematic review. *Psychiatry Res Neuroimaging*. 2020;296:111021.
22. Su T, Gong J, Tang G, et al. Structural and functional brain alterations in anorexia nervosa: a multimodal meta-analysis of neuroimaging studies. *Hum Brain Mapp*. 2021;42(15):5154–5169.
23. Seeley WW, Zhou J, Kim E-J. Frontotemporal dementia: what can the behavioral variant teach us about human brain organization? *Neuroscientist*. 2012;18(4):373–385.
24. Nana AL, Sidhu M, Gaus SE, et al. Neurons selectively targeted in frontotemporal dementia reveal early stage TDP-43 pathobiology. *Acta Neuropathol*. 2019;137(1):27–46.
25. Santillo AF, Nilsson C, Englund E. von Economo neurones are selectively targeted in frontotemporal dementia. *Neuropathol Appl Neurobiol*. 2013;39(5):572–579.
26. Seeley WW, Menon V, Schatzberg AF, et al. Dissociable intrinsic connectivity networks for salience processing and executive control. *J Neurosci*. 2007;27(9):2349–2356.
27. Irish M, Piguet O, Hodges JR. Self-projection and the default network in frontotemporal dementia. *Nat Rev Neurol*. 2012;8(3):152–161.
28. Critchley HD, Harrison NA. Visceral influences on brain and behavior. *Neuron*. 2013;77(4):624–638.
29. Pasquini L, Toller G, Staffaroni A, et al. State and trait characteristics of anterior insula time-varying functional connectivity. *Neuroimage*. 2020;208:116425.
30. Zhou J, Seeley WW. Network dysfunction in Alzheimer's disease and frontotemporal dementia: implications for psychiatry. *Biol Psychiatry*. 2014;75(7):565–573.
31. Toller G, Brown J, Sollberger M, et al. Individual differences in socioemotional sensitivity are an index of salience network function. *Cortex*. 2018;103:211–223.
32. Omar R, Henley SM, Bartlett JW, et al. The structural neuroanatomy of music emotion recognition: evidence from frontotemporal lobar degeneration. *Neuroimage*. 2011;56(3):1814–1821.
33. Lough S, Kipps CM, Treise C, Watson P, Blair JR, Hodges JR. Social reasoning, emotion and empathy in frontotemporal dementia. *Neuropsychologia*. 2006;44(6):950–958.
34. Hua AY, Sibley JJ, Perry DC, et al. Enhanced positive emotional reactivity undermines empathy in behavioral variant frontotemporal dementia. *Front Neurol*. 2018;9:402.
35. Van den Stock J, Kumfor F. Behavioural variant frontotemporal dementia: at the interface of interoception, emotion and social cognition. *Cortex*. 2017;115:335–340.
36. Kumfor F, Irish M, Hodges JR, Piguet O. Discrete neural correlates for the recognition of negative emotions: insights from frontotemporal dementia. *PLoS One*. 2013;8(6):e67457.
37. Bocchetta M, Iglesias JE, Cash DM, Warren JD, Rohrer JD. Amygdala subnuclei are differentially affected in the different genetic and pathological forms of frontotemporal dementia. *Alzheimer's & Dementia: Diagnosis, Assessment & Disease Monitoring*. 2019;11:136–141.
38. Murray EA. The amygdala, reward and emotion. *Trends Cogn Sci*. 2007;11(11):489–497.
39. Cerami C, Cappa SF. The behavioral variant of frontotemporal dementia: linking neuropathology to social cognition. *Neurol Sci*. 2013;34(8):1267–1274.
40. Singer T, Critchley HD, Preuschoff K. A common role of insula in feelings, empathy and uncertainty. *Trends Cogn Sci*. 2009;13(8):334–340.
41. Hsieh S, Irish M, Daveson N, Hodges JR, Piguet O. When one loses empathy: its effect on carers of patients with dementia. *J Geriatr Psychiatry Neurol*. 2013;26(3):174–184.
42. Bzdok D, Schilbach L, Vogeley K, et al. Parsing the neural correlates of moral cognition: ALE meta-analysis on morality, theory of mind, and empathy. *Brain Struct Funct*. 2012;217(4):783–796.
43. Fallon N, Roberts C, Stancak A. Shared and distinct functional networks for empathy and pain processing: a systematic review and meta-analysis of fMRI studies. *Soc Cogn Affect Neurosci*. 2020;15(7):709–723.

44. Pasquini L, Palhano-Fontes F, Araujo DB. Subacute effects of the psychedelic ayahuasca on the salience and default mode networks. *J Psychopharmacol*. 2020;34(6):623–635.
45. Kipps CM, Nestor PJ, Acosta-Cabronero J, Arnold R, Hodges JR. Understanding social dysfunction in the behavioural variant of frontotemporal dementia: the role of emotion and sarcasm processing. *Brain*. 2009;132(3):592–603.
46. Rankin KP, Gorno-Tempini ML, Allison SC, et al. Structural anatomy of empathy in neurodegenerative disease. *Brain*. 2006;129(11):2945–2956.
47. Margolis AE, Pagliaccio D, Thomas L, Banker S, Marsh R. Salience network connectivity and social processing in children with nonverbal learning disability or autism spectrum disorder. *Neuropsychology*. 2019;33(1):135.
48. Sterzer P, Stadler C, Poustka F, Kleinschmidt A. A structural neural deficit in adolescents with conduct disorder and its association with lack of empathy. *Neuroimage*. 2007;37(1):335–342.
49. Mow JL, Gandhi A, Fulford D. Imaging the “social brain” in schizophrenia: a systematic review of neuroimaging studies of social reward and punishment. *Neurosci Biobehav Rev*. 2020;118(1):704–722.
50. Ernst J, Northoff G, Boker H, Seifritz E, Grimm S. Interoceptive awareness enhances neural activity during empathy. *Hum Brain Mapp*. 2013;34(7):1615–1624.
51. García-Cordero I, Sedeno L, De La Fuente L, et al. Feeling, learning from and being aware of inner states: interoceptive dimensions in neurodegeneration and stroke. *Philos Trans R Soc B: Biol Sci*. 2016;371(1708):20160006.
52. Fletcher PD, Downey LE, Golden HL, et al. Pain and temperature processing in dementia: a clinical and neuroanatomical analysis. *Brain*. 2015;138(11):3360–3372.
53. Papagno C, Pisoni A, Mattavelli G, et al. Specific disgust processing in the left insula: new evidence from direct electrical stimulation. *Neuropsychologia*. 2016;84:29–35.
54. Meeter LH, Kaat LD, Rohrer JD, Van Swieten JC. Imaging and fluid biomarkers in frontotemporal dementia. *Nat Rev Neurol*. 2017;13(7):406.
55. Kurth F, Zilles K, Fox PT, Laird AR, Eickhoff SB. A link between the systems: functional differentiation and integration within the human insula revealed by meta-analysis. *Brain Struct Funct*. 2010;214(5-6):519–534.
56. Menon V, Uddin LQ. Saliency, switching, attention and control: a network model of insula function. *Brain Struct Funct*. 2010;214(5-6):655–667.
57. Ardila A, Bernal B, Rosselli M. Executive functions brain system: an activation likelihood estimation meta-analytic study. *Arch Clin Neuropsychol*. 2018;33(4):379–405.
58. Kiselica AM, Benge JF. Quantitative and qualitative features of executive dysfunction in frontotemporal and Alzheimer’s dementia. *Appl Neuropsychol Adult*. 2019;28(4):1–15.
59. Raczka KA, Becker G, Seese A, et al. Executive and behavioral deficits share common neural substrates in frontotemporal lobar degeneration - a pilot FDG-PET study. *Psychiatry Res*. 2010;182(3):274–280.
60. Roca M, Manes F, Gleichgerrcht E, et al. Intelligence and executive functions in frontotemporal dementia. *Neuropsychologia*. 2013;51(4):725–730.
61. Radakovic R, Colville S, Cranley D, Starr JM, Pal S, Abrahams S. Multidimensional apathy in behavioral variant frontotemporal dementia, primary progressive aphasia, and Alzheimer disease. *J Geriatr Psychiatry Neurol*. 2020; 34(5):349–356.
62. Walter H, Abler B, Ciaramidaro A, Erk S. Motivating forces of human actions: neuroimaging reward and social interaction. *Brain Res Bulletin*. 2005;67(5):368–381.
63. Levy R, Dubois B. Apathy and the functional anatomy of the prefrontal cortex–basal ganglia circuits. *Cereb Cortex*. 2006;16(7):916–928.
64. Wang H, Zhang J, Jia H. Separate neural systems value prosocial behaviors and reward: an ALE meta-analysis. *Front Hum Neurosci*. 2019;13:276.
65. Massimo L, Powers JP, Evans LK, et al. Apathy in frontotemporal degeneration: neuroanatomical evidence of impaired goal-directed behavior. *Front Hum Neurosci*. 2015;9:611.
66. Fernández-Matarrubia M, Matias-Guiu JA, Cabrera-Martin MN, et al. Episodic memory dysfunction in behavioral variant frontotemporal dementia: a clinical and FDG-PET study. *J Alzheimers Dis*. 2017;57(4):1251–1264.
67. Bueno APA, de Souza LC, Pinaya WHL, et al. Papez circuit gray matter and episodic memory in amyotrophic lateral sclerosis and behavioural variant frontotemporal dementia. *Brain Imaging Behav*. 2020;15(2):1–11.
68. Luo C, Hu N, Xiao Y, Zhang W, Gong Q, Lui S. Comparison of gray matter atrophy in behavioral variant frontal temporal dementia and amyotrophic lateral sclerosis: a coordinate-based meta-analysis. *Front Aging Neurosci*. 2020;12:14.
69. Hornberger M, Piguet O. Episodic memory in frontotemporal dementia: a critical review. *Brain*. 2012;135(3):678–692.
70. Balasa M, Gelpi E, Martin I, et al. Diagnostic accuracy of behavioral variant frontotemporal dementia consortium criteria (FTDC) in a clinicopathological cohort. *Neuropathol Appl Neurobiol*. 2015;41(7):882–892.
71. Beach TG, Monsell SE, Phillips LE, Kukull W. Accuracy of the clinical diagnosis of Alzheimer disease at National Institute on Aging Alzheimer Disease Centers, 2005–2010. *J Neuropathol Exp Neurol*. 2012;71(4):266–273.
72. van der Zee J, Slegers K, Van Broeckhoven C. Invited article: the Alzheimer disease–frontotemporal lobar degeneration spectrum. *Neurology*. 2008;71(15):1191–1197.
73. Rohrer JD. Behavioural variant frontotemporal dementia—defining genetic and pathological subtypes. *J Mol Neurosci*. 2011;45(3):583–588.
74. Bang J, Spina S, Miller BL. Non-Alzheimer’s dementia 1: frontotemporal dementia. *Lancet*. 2015;386(10004):1672.
75. Solje E, Aaltokallio H, Koivumaa-Honkanen H, et al. The phenotype of the C9ORF72 expansion carriers according to revised criteria for bvFTD. *PLoS One*. 2015;10(7):e0131817.

SUPPORTING INFORMATION

Additional supporting information can be found online in the Supporting Information section at the end of this article.

How to cite this article: Kamalian A, Khodadadifar T, Saberi A, et al. Convergent regional brain abnormalities in behavioral variant frontotemporal dementia: A neuroimaging meta-analysis of 73 studies. *Alzheimer’s Dement*. 2022;14:e12318. <https://doi.org/10.1002/dad2.12318>