

A rare case of epicardial left ventricular sutureless screw-in lead placement causing left anterior descending artery stenosis



Joseph Krepp, MD, David Lu, MD, Pendleton Alexander, MD, Hans Moore, MD, FHRS

From the Department of Cardiology, Veterans Affairs Medical Center, Washington, DC.

Introduction

Implantation of an epicardial left ventricular (LV) lead is a reasonable alternative to a transvenous coronary sinus lead in the case of inadequate coronary sinus anatomy, and is generally considered safe and effective. We report the case of a patient who received an epicardial LV sutureless screw-in lead presenting several months later with a myocardial infarction owing to injury to the left anterior descending (LAD) artery by the epicardial LV screw-in lead.

Case report

A 49-year-old man with an alcohol-induced nonischemic cardiomyopathy and severe biventricular dysfunction underwent placement of a biventricular implantable cardioverter-defibrillator (ICD) for primary prevention and worsening NYHA class IV heart failure. Transvenous insertion of the LV lead failed because of tortuous coronary sinus anatomy with a marked angulation in its mid-course. Using a left lateral video-assisted axillary thoracotomy, with the patient lying supine, an incision was made in the mid-axillary line and a small pericardiotomy was performed beneath the phrenic nerve, allowing a unipolar epicardial LV sutureless screw-in lead (Medtronic 5071; Medtronic, Inc., Mounds View, MN) to be placed adjacent to the left atrial appendage in the high lateral wall of the left ventricle. A second lead was placed approximately 3 cm away to allow for bipolar and backup LV pacing in case of lead failure. A postoperative chest radiograph demonstrates the pacing lead positions along with massive cardiomegaly, occupying much of the left hemithorax (Figure 1).

One week following implantation, the patient was readmitted with intermittent sharp pleuritic chest pain and worsening shortness of breath. He was treated for heart

KEYWORDS Epicardial lead; Resynchronization; Defibrillator; Myocardial infarction; Cardiomyopathy; Complication
(Heart Rhythm Case Reports 2016;2:303–305)

Address reprints and correspondence: Dr Hans Moore, Department of Cardiology, Veterans Affairs Medical Center, 4B108, 50 Irving St NW, Washington, DC 20422. E-mail address: hans.moore@va.gov.

failure and had notable clinical improvement following diuresis. At that time, an echocardiogram documented a new pericardial effusion of moderate size without evidence of tamponade. Serial cardiac troponins and inflammatory biomarkers were negative, and there was normal device function. The etiology of the effusion was thought to be related to postpericardiotomy surgical bleeding rather than an inflammatory syndrome. A repeat echocardiogram demonstrated a decrease in size of the pericardial effusion following diuresis and the patient was discharged home. Follow-up echocardiograms showed resolution of the effusion over the ensuing weeks. Six weeks later the patient had 1 additional admission for atypical chest pain, secondary to a painful mass noted in his left breast, which was later identified as benign gynecomastia on breast biopsy. At that time a chest computed tomography (CT) scan was obtained to exclude pulmonary embolus.

Five months after implant, the patient presented to the Emergency Department with severe chest pain that awoke him from sleep in the setting of progressive exertional chest discomfort over the preceding several weeks. In the Emergency Department substernal chest pain recurred and was associated with diaphoresis, nausea, and a wide complex tachycardia. The electrocardiogram demonstrated a monomorphic ventricular tachycardia (VT) with a left bundle, left axis morphology at a cycle length of 380 ms and a QRS duration of 170 ms. The VT was below the detection setting of the ICD, and thus there were no stored events. The patient received 150 mg of amiodarone intravenously; however, the patient became hypotensive. External synchronized cardioversion restored a biventricular paced rhythm. Monomorphic VT recurred; it failed to terminate with antitachycardia pacing and VT recurred after manual ICD-based internal cardioversion. During this time LV pacing was turned off because our group has witnessed prior cases of LV pacing-induced VT, and there have been case reports describing this phenomenon.^{1,2} Despite these interventions, the rhythm deteriorated into ventricular fibrillation and the patient required cardiopulmonary resuscitation, 1 mg of intravenous epinephrine, intubation, and defibrillation. Subsequently, sinus rhythm and spontaneous circulation was restored.

KEY TEACHING POINTS

- Although considered safe, epicardial lead placement is not devoid of major complications.
- It is important to critically review all imaging modalities that patients receive when presenting with cardiac symptoms in the setting of prior device implantation.
- Biventricular heart failure and right ventricular enlargement can result in lateral displacement of the interventricular septum.

The creatine phosphokinase rose acutely to 2947 U/L and troponin to 45.98 ng/mL and the patient underwent emergent left heart catheterization using a transradial approach.

The mid LAD artery had a discrete 90% stenosis (Figure 2). An LV epicardial lead was noted immediately adjacent to the stenotic lesion (arrow). A comparative image from the patient's cardiac catheterization from a year prior was devoid of any stenosis. With some difficulty, the lesion was crossed with a Stabilizer guide wire and direct stenting performed with delivery of a Resolute Integrity 3.5/12 mm zotarolimus drug-eluting stent. Full stent expansion was achieved after increasing the inflation pressure to 20 atmospheres of pressure with a final stent diameter of 4 mm (Figure 2). Left ventriculography demonstrated global LV dysfunction with an estimated ejection fraction of 20% and LV end diastolic pressure of 22 mm Hg. The left main artery, the left circumflex artery, the right coronary artery, and their branches were free of disease. Review of a nongated chest CT scan, obtained several months earlier to rule out pulmonary embolus, showed that an epicardial screw-in lead was in the immediate proximity to the LAD artery (Figure 3).

The patient required inotropic and ventilator support in addition to ultrafiltration (Aquaphoresis) during the hospital course. The patient recovered from cardiogenic shock, pul-

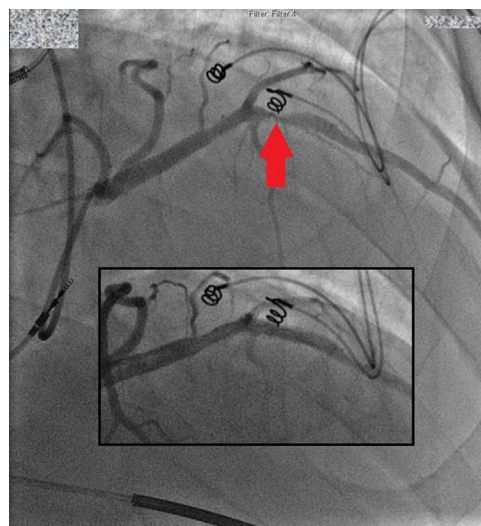

Figure 2 Left heart catheterization demonstrating a severe stenosis to the mid left anterior descending artery (arrow). Inserted is the angiogram displaying the left anterior descending artery following percutaneous coronary intervention.

monary edema, and multiorgan failure and was discharged to home 9 days after presentation, with remarkable clinical improvement. Biventricular pacing had been resumed without adverse effects.

Discussion

Several clinical trials have established beneficial effects of cardiac resynchronization therapy in patients with congestive heart failure and a wide left bundle branch block.³⁻⁵ Although the endovascular transvenous approach to the coronary sinus has become the conventional method for LV lead placement, left-sided thoracotomy and video-assisted thoracoscopy are alternative implantation techniques of an epicardial LV lead.⁶ Surgical epicardial LV lead placement is an established effective means of biventricular pacing when compared to coronary sinus leads.⁷

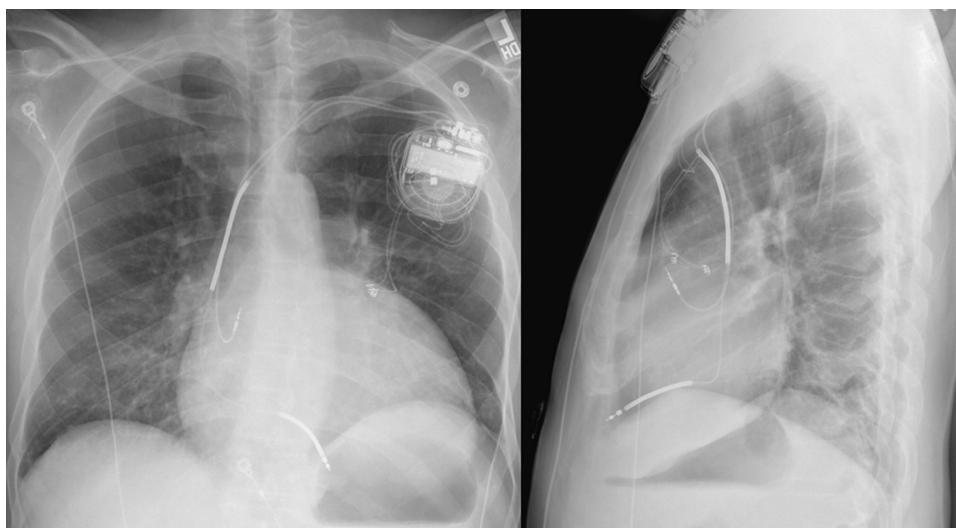


Figure 1 Posteroanterior and lateral chest radiograph demonstrating the position of the 2 left ventricular epicardial leads.

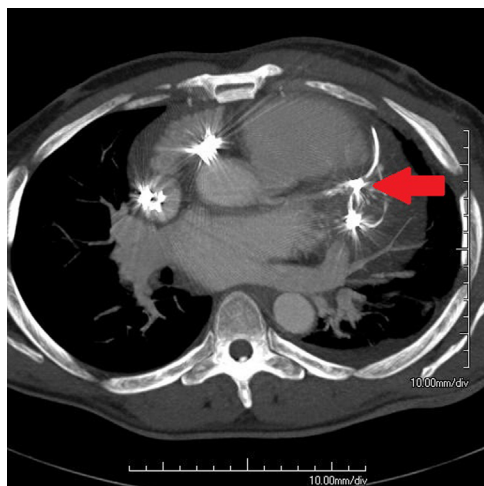


Figure 3 Nongated chest computed tomography scan completed 2 months prior to admission indicating an epicardial pacing lead in close proximity to the left anterior descending artery (arrow).

Although rare, case reports of complications of epicardial LV lead placement have been described. These include pericardial tamponade, pericardial constriction, recurrent pericarditis, infection, and cross-stimulation.^{8–12} To our knowledge, this is the first case report of an epicardial LV lead placement with development of subjacent LAD stenosis. Typically, a lateral approach for an epicardial LV lead placement allows the operator to safely avoid the major epicardial coronary vasculature. However, in rare circumstances, such as in the case of biventricular heart failure or right ventricular dilatation, the interventricular septum can be laterally displaced.¹³ As seen in this patient, this places the LAD artery at increased risk of mechanical complications when epicardial LV lead placement is performed, and the operator needs to consider this anatomical distortion. Additionally, the marked angulation of the coronary sinus in the setting of biventricular dysfunction and enlargement should alert the operator to the possibility of lateral displacement of the interventricular septum. This case also illustrates the importance of reviewing and scrutinizing all imaging data, as the nongated chest CT demonstrates the placement of the epicardial leads adjacent to the LAD.

The mechanism of stenosis in this case is not certain, but given the proximity of the pacing lead to the LAD, it is thought to be most likely related to external mechanical compression of the LAD. Additionally, although the epicardial LV leads were “sutureless,” the sharp screw-in tip could penetrate adjacent tissues with myocardial contraction while the fibrotic scarring process is occurring. There was no

clearly defined operative injury to the LAD, but there was development of a postoperative effusion that possibly could have been related to a perforation of the LAD. The subsequent periarterial inflammatory cascade and fibrosis at the region of the vessel injury could also be a culprit for the LAD stenosis.

Conclusion

This case reviews a rare complication of an epicardial LV sutureless screw-in pacing lead, which was surgically placed and led to stenosis of the LAD artery. In circumstances of significant biventricular dilatation and axial rotation of the heart, the operator should be alerted to possible inferior and lateral displacement of the LAD artery.

References

- Shukla G, Chaudhry GM, Orlov M, Hoffmeister P, Haffajee C. Potential proarrhythmic effect of biventricular pacing: fact or myth? *Heart Rhythm* 2005;2: 951–956.
- Guerra JM, Wu J, Miller JM, Goh WJ. Increase in ventricular tachycardia frequency after biventricular implantable cardioverter defibrillator upgrade. *J Cardiovasc Electrophysiol* 2003;14:1245–1247.
- Cazeau S, Leclercq C, Lavergne T, et al. The multisite stimulation in cardiomyopathies (MUSTIC) Study Investigators. Effects of multisite biventricular pacing in patients with heart failure and intraventricular conduction delay. *N Engl J Med* 2001;344:873–880.
- Abraham WT, Fisher WG, Smith AL, et al. MIRACLE Study Group. Multicenter InSync Randomized Clinical Evaluation. Cardiac resynchronization in chronic heart failure. *N Engl J Med* 2002;346:1845–1853.
- Bristow MR, Saxon LA, Boehmer J, et al. Comparison of Medical Therapy, Pacing, and Defibrillation in Heart Failure (COMPANION) Investigators. Cardiac-resynchronization therapy with or without an implantable defibrillator in advanced chronic heart failure. *N Engl J Med* 2004;350:2140–2150.
- Mair H, Jansens JL, Lattouf OM, Reichart B, Dabritz S. Epicardial lead implantation techniques for biventricular pacing via left lateral mini-thoracotomy, video-assisted thoracoscopy, and robotic approach. *Heart Surg Forum* 2003;6: 412–417.
- Mair H, Sachweh J, Meuris B, et al. Surgical epicardial left ventricular lead versus coronary sinus lead placement in biventricular pacing. *Eur J Cardiothorac Surg* 2005;27:235–242.
- Peters R, Scheinman M, Raskin S, Thomas A. Unusual complications of epicardial pacemakers: recurrent pericarditis, cardiac tamponade and pericardial constriction. *Am J Cardiol* 1980;45:1088–1094.
- Bass J. Recurrent pericardial effusion: an unusual complication of epicardial pacemaker placement. *J Natl Med Assoc* 1984;76:283–285.
- Schwartz D, Thanavaro S, Kleiger R, Krone R, Connors J, Oliver G. Epicardial pacemaker complicated by cardiac tamponade and constrictive pericarditis. *Chest* 1979;76:226–227.
- Smith D III, DeAnda A, Towe C, Balsam LB. Retroaortic abscess: an unusual complication of a retained epicardial pacing wire. *Interact Cardiovasc Thorac Surg* 2013;16:221–223.
- Shah AM, Cannon BC, Kertesz NJ, Kim JJ. Cross-stimulation: a rare complication of chronic epicardial leads. *J Cardiovasc Electrophysiol* 2009;20: 1065–1067.
- Nelson G, Sayed-Ahmed E, Kroeker C, et al. Compression of interventricular septum during right ventricular pressure loading. *Am J Physiol Heart Circ Physiol* 2001;280:2639–2648.