

This article is licensed under the Creative Commons Attribution-NonCommercial 4.0 International License (CC BY-NC) (<http://www.karger.com/Services/OpenAccessLicense>). Usage and distribution for commercial purposes requires written permission.

Case Report

A Rare Form of Corneal Opacity Associated with Spondyloepiphyseal Dysplasia Congenita

Yuichiro Ishida^a Shizuka Koh^{a, b} Takashi Kaito^c Kohji Nishida^a

^aDepartment of Ophthalmology, Osaka University Graduate School of Medicine, Osaka, Japan; ^bDepartment of Innovative Visual Science, Osaka University Graduate School of Medicine, Osaka, Japan; ^cDepartment of Orthopedic Surgery, Osaka University Graduate School of Medicine, Osaka, Japan

Keywords

Spondyloepiphyseal dysplasia congenita · Corneal opacity · Anterior segment optical coherence tomography

Abstract

A 13-year-old Japanese female diagnosed with spondyloepiphyseal dysplasia congenita (SEDC) was referred for ophthalmologic evaluation. Examination with slit-lamp and optical coherence tomography revealed bilateral thin cornea with diffuse corneal opacity which was localised at the posterior stromal depth in the central cornea. Unlike the two previously reported cases of diffuse and nodular patterns of corneal opacity in SEDC, the current case exhibited a rare form of corneal opacity. SEDC is one of the type II collagenopathies, characterised by dwarfism because the mutations in COL2A1 prevent bone growth. Although the existence of type II collagen has not been reported in the human corneal stroma, the aetiology of the opacity in the corneal stroma in SEDC type II collagenopathy is of interest.

© 2018 The Author(s)
Published by S. Karger AG, Basel

Introduction

Spondyloepiphyseal dysplasia congenita (SEDC) is a rare inherited bone growth disorder with an estimated prevalence of 1:40,000. SEDC is characterised by dwarfism and skeletal abnormalities caused by mutations of the *COL2A1* gene, which prevent bone growth. *COL2A1* encodes the alpha-1 chain of type II collagen (found primarily in cartilage) and disorders involving type II collagen abnormalities are commonly associated with ocular and hearing problems. Because the vitreous body is primarily composed of type II collagen, myopia and retinal detachment are the major ocular manifestations of SEDC [1].

Here, we discuss the case of a patient with SEDC who presented with a rare form of corneal opacity, as well as the relevant findings obtained via cross-sectional anterior segment optical coherence tomography (OCT) imaging.

Case Report

A 13-year-old Japanese girl diagnosed with SEDC was referred to the Ophthalmology Department, Osaka University Hospital, for decreased vision. Her general appearance was notable in that she exhibited a relatively short trunk and limbs (Fig. 1). Her best-corrected visual acuity was 20/100 in the right eye and 20/60 in the left eye. Slit-lamp examination revealed a diffuse corneal opacity in the central cornea of both eyes, localised in the depth of the posterior corneal stroma (Fig. 2a). No peripheral corneal involvement was observed in either eye. Corneal topographic measurements showed vertical bowtie pattern with mild inferior-superior dioptric asymmetry for both eyes (Fig. 3). There were no other abnormal findings in the anterior or posterior segment. Fourier-domain OCT (RTVue-100; Optovue, Inc., Fremont, CA, USA) revealed that the opacity was localised in the central cornea and deep stroma (Fig. 2b). Thickness mapping of the total cornea and corneal epithelium demonstrated a central corneal thickness of 448 and 449 μm and a corneal epithelial thickness of 51 and 52 μm for the right and left eyes, respectively. While the total cornea appeared to be thinner, the corneal epithelium appeared normal, suggesting decreased thickness of the corneal stroma.

Corneal findings associated with SEDC have been reported in 2 other cases (a 67-year-old man and 58-year-old woman) [2, 3]. In the previous cases, both diffuse and nodular patterns of corneal opacity were observed across the periphery, while the opacity was centrally localised in the present case. This difference may be partially attributed to the large difference in patient age, although longer follow-up of this patient is necessary for further clarification. OCT clearly differentiated the corneal epithelium and stroma and quantitatively demonstrated decreased thickness of the corneal stroma in our patient. Although both studies utilised ultrasound pachymetry, Wells et al. [2] reported a case of SEDC in a patient with normal corneal thickness, while Hirata et al. [3] reported the case of a Japanese patient with SEDC who exhibited decreased central corneal thicknesses (473 and 478 μm). The total corneal thickness values in our young Japanese patient were relatively closer to those reported by Hirata et al. [3].

The corneal stroma reportedly contains types I, III, V, and VI collagen. However, to our knowledge, no reports have described the existence of type II collagen in the human corneal stroma. Previous studies regarding the morphogenesis of the chick corneal stroma have revealed that type II collagen is contained in the primary corneal stroma [4, 5]. We may speculate that abnormal clinical findings in the corneal stroma of patients with SEDC might

be associated with alterations in type II collagen that occur during the developmental stages of the primary corneal stroma, although there is no evidence to support this. Future studies should aim to clarify the pathology of SEDC and potential involvement of type II collagen in the human corneal stroma.

Statement of Ethics

Written consent to publish personal information and case details has been obtained from the patient.

Disclosure Statement

None of the authors or their family members has a proprietary or financial interest in any of the materials or instruments mentioned in this article.

Author Contributions

All authors contributed to patient management and writing of the report.

References

- 1 Terhal PA, Nievelein RJ, Verver EJ, et al: A study of the clinical and radiological features in a cohort of 93 patients with a COL2A1 mutation causing spondyloepiphyseal dysplasia congenita or a related phenotype. *Am J Med Genet A* 2015;167:461–475.
- 2 Wells JA 3rd, Ellerine NP, Fernhoff PM, Waring GO 3rd: Corneal opacities in spondyloepiphyseal dysplasia tarda. *Cornea* 1994;13:280–283.
- 3 Hirata Y, Watanabe H, Maeda N, Inoue Y, Shimomura Y, Tano Y: Corneal changes in spondyloepiphyseal dysplasia tarda. *Jpn J Ophthalmol* 2000;44:29–32.
- 4 Hendrix MJ, Hay ED, von der Mark K, Linsenmayer TF: Immunohistochemical localization of collagen types I and II in the developing chick cornea and tibia by electron microscopy. *Invest Ophthalmol Vis Sci* 1982;22:359–375.
- 5 Ruggiero F, Barge A, Coll JL, Garrone R: Extracellular matrix production by embryonic epithelium cultured on type IV collagen. *Cell Differ Dev* 1990;29:95–104.



Fig. 1. General appearance of a 13-year-old Japanese girl with spondyloepiphyseal dysplasia congenita. She exhibited short trunk and limbs.

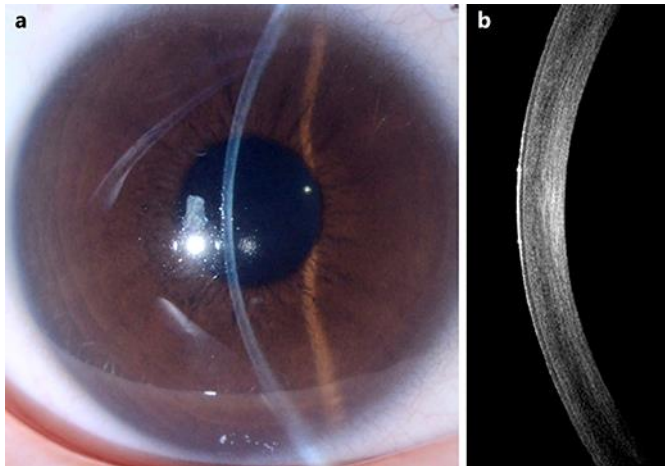


Fig. 2. Corneal imaging findings. **a** Slit-lamp biomicroscopy shows a diffuse opacity in the central cornea of the right eye. **b** Fourier-domain optical coherence tomography shows an opacity localised in the central cornea and deep stroma of the right eye.

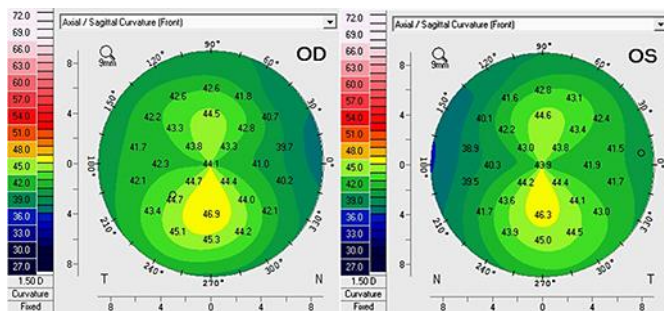


Fig. 3. Corneal axial maps obtained with a rotating Scheimpflug-based corneal tomography (Pentacam HR; Oculus GmbH, Wetzlar, Germany) showed a vertical bowtie pattern with mild inferior-superior dioptric asymmetry for both eyes.