

Case Report



Natural History of Early Gastric Cancer: a Case Report and Literature Review

Tomohiro Iwai, Masao Yoshida, Hiroyuki Ono, Naomi Kakushima, Kohei Takizawa, Masaki Tanaka, Noboru Kawata, Sayo Ito, Kenichiro Imai, Kinichi Hotta, Hirotoishi Ishiwatari, Hiroyuki Matsubayashi

Division of Endoscopy, Shizuoka Cancer Center, Shizuoka, Japan



Received: Sep 19, 2016

Revised: Nov 2, 2016

Accepted: Nov 10, 2016

Correspondence to

Naomi Kakushima

Division of Endoscopy, Shizuoka Cancer Center, 1007 Shimonagakubo, Nagaizumi, Suntogun, Shizuoka 411-8777, Japan.

Tel: +81-55-9895222

Fax: +81-55-9895783

E-mail: kakushin-tyk@umin.ac.jp

Copyright © 2017. Korean Gastric Cancer Association

This is an Open Access article distributed under the terms of the Creative Commons Attribution Non-Commercial License (<https://creativecommons.org/licenses/by-nc/4.0>) which permits unrestricted noncommercial use, distribution, and reproduction in any medium, provided the original work is properly cited.

Conflict of Interest

No potential conflict of interest relevant to this article was reported.

ABSTRACT

Early detection and treatment decrease the mortality rate associated with gastric cancer (GC). However, the natural history of GC remains unclear. An 85-year-old woman was referred to our hospital for evaluation of a gastric tumor. Esophagogastroduodenoscopy identified a 6 mm, flat-elevated lesion at the lesser curvature of the antrum. A biopsy specimen showed a well-differentiated tubular adenocarcinoma. The depth of the lesion was estimated to be intramucosal. Although the lesion met the indications for endoscopic resection, periodic endoscopic follow-up was performed due to the patient's advanced age and comorbidities. The mucosal GC invaded into the submucosa 3 years later, and finally progressed to advanced cancer 5 years after the initial examination. The patient died of tumor hemorrhage 6.4 years after the initial examination. In this case, mucosal GC progressed to advanced GC, eventually leading to the patient's death from GC. Early and appropriate treatment is required to prevent GC-related death.

Keywords: Early gastric cancer; Natural history

INTRODUCTION

Gastric cancer (GC) accounts for 10% of all cancer-related deaths [1]. Although the reported 5-year overall survival rates in advanced GC range from 15% to 52% [2,3], those in early gastric cancer (EGC) range from 88% to 97% [4,5]. Early detection and treatment contribute to decreased mortality rates [6]. With the increased use of endoscopic treatment in EGC, the natural history of EGC must be considered in order to evaluate the efficacy of endoscopic resection and to improve treatment decision-making; this is particularly relevant for elderly patients. However, the chronological changes of GC, including whether mucosal GC can progress to advanced cancer, remain unclear due to a lack of follow-up with high-resolution endoscopic images [7-10]. We present a case with prospective follow-up that provides a better understanding of the natural growth of GC.

CASE REPORT

An 85-year-old woman was referred to Shizuoka Cancer Center for evaluation of a gastric tumor in April 2007. Esophagogastroduodenoscopy (EGD) identified a 6 mm, flat-elevated lesion at the lesser curvature of the antrum. The lesion was diagnosed as Type 0-IIa EGC by endoscopy. The depth of the lesion was estimated to be intramucosal, because it was a flat-elevated lesion without nodules, remarkable depression, or fold convergence (Fig. 1A, B). Evaluation of a biopsy specimen revealed a well-differentiated tubular adenocarcinoma (Fig. 2A, B). Due to the patient's advanced age and comorbidities (rheumatoid arthritis and ischemic heart disease), she wished to receive periodic endoscopic follow-up and best supportive care without invasive treatment. Follow-up EGDs were performed at intervals of 6 months to 1 year.

From 2007 to 2009, the lesion showed no change in size or morphology. The estimated depth of the lesion remained within the mucosal layer. In order to reconfirm the initial diagnosis, a biopsy specimen was obtained from the lesion; it revealed a higher grade of cytological and structural atypia than the initial biopsy specimen (Fig. 2C, D).

In 2010 and 2011, the follow-up EGD showed that the lesion had grown to 12 mm in size. It had also developed a slight depression and a 4 mm nodule, indicating submucosal invasion (Fig. 1C, D).

In May 2012, further evaluation revealed that the lesion had an ulcer surrounded by a swollen gastric wall with clear margins. The macroscopic type was classified as Type 2 (Fig. 1E). The estimated depth of the Type 2 tumor was the muscularis propria. Six months later, the patient

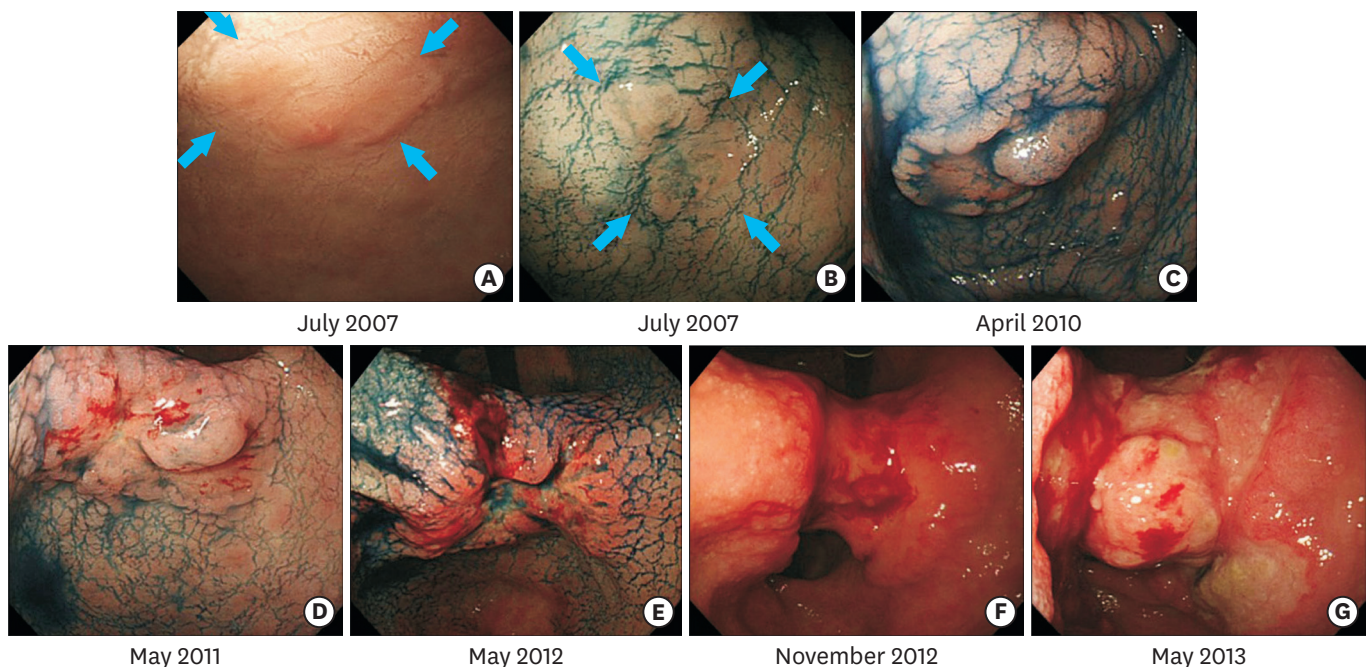


Fig. 1. Chronological changes of the lesion. (A, B) A 6-mm, flat-elevated lesion at the lesser curvature of the antrum (Type 0-IIa, depth of tumor: mucosa). (C) Slight depression and small nodule was detected (Type 0-IIa+IIc, depth of tumor: submucosa). (D) The lesion sized up to 12 mm, and the depression became deeper (Type 0-IIa+IIc, depth of tumor: submucosa). (E) The lesion had enlarged, and ulceration was observed in the center of the lesion (Type 2, depth of tumor: muscularis propria). (F) The lesion invaded laterally, and the lesion enlarged to 50 mm with tumor oozing (Type 3, depth of tumor: subserosa). (G) The lesion became larger than 100 mm with severe stricture (Type 3, depth of tumor: serosa).

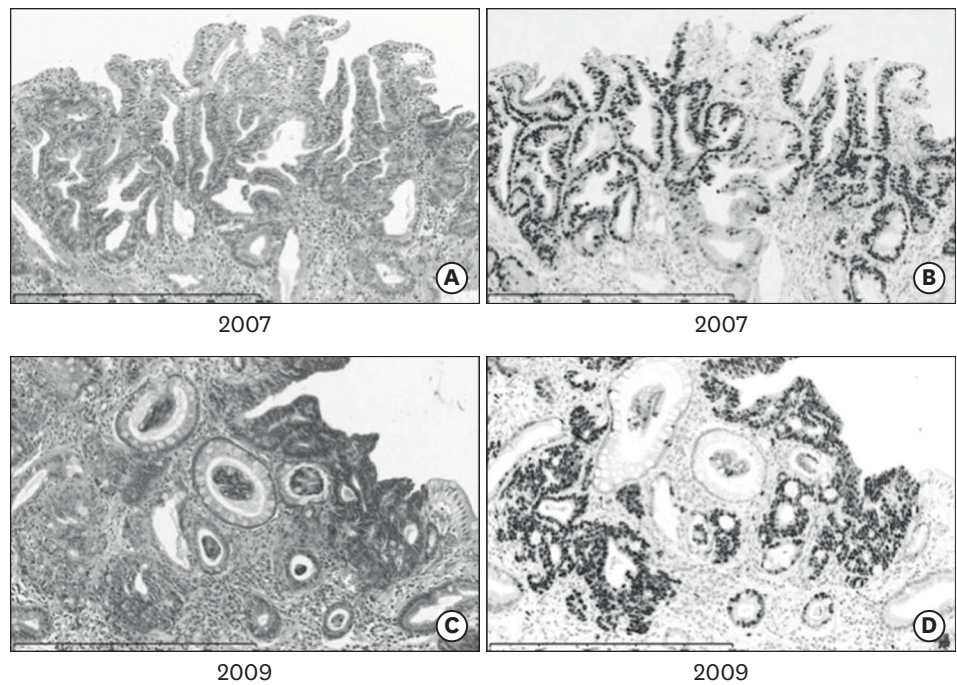


Fig. 2. Microscopic findings of the biopsy specimen. (A) Evaluation of a biopsy specimen showing a well differentiated tubular adenocarcinoma (H&E, bar length 500 μ m). (B) Immunostaining with Ki-67 showing positive cells in all layers of the mucosa (Ki-67, bar length 500 μ m). (C) Re-obtained biopsy specimen showing development of cytological and structural atypia in comparison with the initial examination (H&E, bar length 500 μ m). (D) Immunostaining with Ki-67 showing positive cells in all layers of the mucosa and a higher rate of positive cells than the initial biopsy specimen (Ki-67, bar length 500 μ m)

presented with symptoms of anemia, which was diagnosed as moderate anemia (hemoglobin 8.3 g/dl). EGD revealed oozing from the excavated ulcer of the tumor. The size of the lesion had increased to 50 mm. The advanced lesion invaded laterally without clear margins. The macroscopic type had progressed from Type 2 to Type 3. The depth of the lesion was estimated to extend to the subserosa (**Fig. 1F**).

In 2013, the patient complained of insufficient food intake and symptoms of anemia. Her serum albumin and hemoglobin levels were 2.6 g/dL and 8.8 g/dl, respectively. The lesion had increased to more than 100 mm in size with severe stricture, which suggested tumor penetration of the serosa (**Fig. 1G**). That year, 6.6 years after the initial examination, the patient died of tumor hemorrhage.

The Institutional Review Board of Shizuoka Cancer Center approved this case report (institutional code number: 25-J82-25-1-3).

DISCUSSION

The present case shows the natural history of EGC resulting in cancer-related death. At the initial examination, the lesion was classified as intramucosal cancer, and it remained in the early stage for at least 3.8 years. It could have been curatively treated by endoscopic submucosal dissection (ESD) until 2009 (two years after the initial examination). Five years after the initial examination, the lesion finally progressed to advanced GC. The outcome may

Table 1. Summary of reported cases presenting the natural history of early gastric cancer

Variable		Case 1 [14]	Case 2 [15]	Present case
Age (yr)		89	37	85
Sex		Male	Male	Female
Initial findings	Location	M, anterior wall	U, lesser curvature	L, lesser curvature
	Morphological type*	Type 0-IIc	Type 0-IIc	Type 0-IIa
	Size (mm)	20	Not known	6
	Depth	Mucosa	Mucosa or submucosa	Mucosa
Period of mucosal cancer (yr)		3	Not known	3
Period of submucosal cancer (yr)		2	Not known	2
Last findings	Interval [†] (yr)	8	7.9	6.4
	Morphological type*	Type 3	Type 3	Type 3
	Size (mm)	60	Not known	100
	Depth	Subserosa or serosa	Subserosa	Subserosa
Outcome		Death from other disease	Alive after gastrectomy	Death from gastric cancer

M = middle third of the stomach; U = upper third of the stomach; L = lower third of the stomach.

*Classification according to the Japanese Gastric Cancer Association guideline. [†]The time from the initial examination to the last examination.

have been different if the patient had undergone ESD. In Japan, it has been reported that 87% of new lesions are detected in the early stage [11,12], and 81% to 95% of these lesions meet the indications for ESD [4,5]. However, due to differences in the pathological diagnostic criteria for EGC between Japan and Western countries, EGC in Western countries, especially mucosal cancer, is often followed up as a pre-malignant lesion or pseudo-disease that is not expected to invade into the deeper layer [10,13]. This case might represent a milestone in appreciating the importance of ESD for mucosal EGC.

A review of the literature revealed two other case reports with prospective follow-up information (Table 1) [14,15]. In both cases, the morphological type progressed from Type 0-IIc to Type 3. In the present case, the morphological type progressed to Type 3 via Type 0-IIa+IIc, comparable to the data in the previous reports. The duration of time in which the cancer remained within the mucosal layer after the initial examination was 3 years in one case and unknown in the other. In the present case, the cancer also remained within the mucosal layer for 3 years after the initial examination, which suggests that mucosal cancer has the potential to invade into the submucosal layer in approximately 3 years. A previous cohort study reported that the estimated median duration of the early stage disease was 3.7 years, and that the duration of the submucosal cancer was no more than 2 years [7]. Regarding the duration of the submucosal cancer, in the presented case and in one of the previous case reports, the duration was 2 years; this indicates that tumor growth may accelerate following submucosal invasion. One reported case was followed for 8 years and the patient died of other disease, while the other case was followed for 7.9 years and the patient underwent gastrectomy. To the best of our knowledge, there have been no reports of primary cases resulting in GC-related death with long-term observation. In the present case, EGC was the cause of death 6.4 years after the initial examination. A decision to treat EGC could be made if the average life expectancy of the patient is expected to be at least 5 years from the time of EGC diagnosis.

The present case and the literature review indicate that mucosal cancer can develop into submucosal invasive cancer, remain in the submucosal layer for about 2 years, and then invade into deeper layers. EGC should be treated appropriately, because it leads to cancer-related death even if the patient is elderly. The present case emphasizes the importance of early detection and appropriate treatment.

REFERENCES

1. Jemal A, Bray F, Center MM, Ferlay J, Ward E, Forman D. Global cancer statistics. *CA Cancer J Clin* 2011;61:69-90.
[PUBMED](#) | [CROSSREF](#)
2. Marchet A, Mocellin S, Ambrosi A, Morgagni P, Vittimberga G, Roviello F, et al. Validation of the new AJCC TNM staging system for gastric cancer in a large cohort of patients (n = 2,155): focus on the T category. *Eur J Surg Oncol* 2011;37:779-785.
[PUBMED](#) | [CROSSREF](#)
3. Nashimoto A, Akazawa K, Isoe Y, Miyashiro I, Katai H, Kodera Y, et al. Gastric cancer treated in 2002 in Japan: 2009 annual report of the JGCA nationwide registry. *Gastric Cancer* 2013;16:1-27.
[PUBMED](#) | [CROSSREF](#)
4. Sekiguchi M, Suzuki H, Oda I, Abe S, Nonaka S, Yoshinaga S, et al. Favorable long-term outcomes of endoscopic submucosal dissection for locally recurrent early gastric cancer after endoscopic resection. *Endoscopy* 2013;45:708-713.
[PUBMED](#) | [CROSSREF](#)
5. Isomoto H, Shikuwa S, Yamaguchi N, Fukuda E, Ikeda K, Nishiyama H, et al. Endoscopic submucosal dissection for early gastric cancer: a large-scale feasibility study. *Gut* 2009;58:331-336.
[PUBMED](#) | [CROSSREF](#)
6. Tsukuma H, Mishima T, Oshima A. Prospective study of "early" gastric cancer. *Int J Cancer* 1983;31:421-426.
[PUBMED](#) | [CROSSREF](#)
7. Tsukuma H, Oshima A, Narahara H, Morii T. Natural history of early gastric cancer: a non-concurrent, long term, follow up study. *Gut* 2000;47:618-621.
[PUBMED](#) | [CROSSREF](#)
8. Lansdown M, Quirke P, Dixon MF, Axon AT, Johnston D. High grade dysplasia of the gastric mucosa: a marker for gastric carcinoma. *Gut* 1990;31:977-983.
[PUBMED](#) | [CROSSREF](#)
9. Everett SM, Axon AT. Early gastric cancer: disease or pseudo-disease? *Lancet* 1998;351:1350-1352.
[PUBMED](#) | [CROSSREF](#)
10. Rugge M, Cassaro M, Di Mario F, Leo G, Leandro G, Russo VM, et al. Interdisciplinary Group on Gastric Epithelial Dysplasia (IGGED). The long term outcome of gastric non-invasive neoplasia. *Gut* 2003;52:1111-1116.
[PUBMED](#) | [CROSSREF](#)
11. Kaneko E, Nakamura T, Umeda N, Fujino M, Niwa H. Outcome of gastric carcinoma detected by gastric mass survey in Japan. *Gut* 1977;18:626-630.
[PUBMED](#) | [CROSSREF](#)
12. Tashiro A, Sano M, Kinameri K, Fujita K, Takeuchi Y. Comparing mass screening techniques for gastric cancer in Japan. *World J Gastroenterol* 2006;12:4873-4874.
[PUBMED](#)
13. Yoshida M, Shimoda T, Kusafuka K, Sugino T, Nakajima T, Ono H. Comparative study of Western and Japanese criteria for biopsy-based diagnosis of gastric epithelial neoplasia. *Gastric Cancer* 2015;18:239-245.
[PUBMED](#) | [CROSSREF](#)
14. Fujisaki J, Nakajima T, Hirasawa T, Yamamoto Y, Ishiyama A, Tsuchida T, et al. Natural history of gastric cancer—a case followed up for eight years: early to advanced gastric cancer. *Clin J Gastroenterol* 2012;5:351-354.
[PUBMED](#) | [CROSSREF](#)
15. Furukawa K, Yamada K, Konomi K, Tanaka M. Gastric carcinoma resected 95 months after being diagnosed: report of a case. *Surg Today* 1994;24:756-758.
[PUBMED](#) | [CROSSREF](#)