

Available online at [www.sciencedirect.com](http://www.sciencedirect.com)

ScienceDirect

journal homepage: [www.elsevier.com/locate/radcr](http://www.elsevier.com/locate/radcr)

## Case Report

# A case of traumatic anterior cerebral artery-cavernous sinus fistula<sup>☆</sup>

Tran Anh Tuan, MD, PhD<sup>a,b</sup>, Nguyen Van Tuan, MD<sup>c</sup>, Le Nguyen Quyen, MD, PhD<sup>d,\*</sup>,  
Nguyen Tat Thien, MD<sup>b</sup>

<sup>a</sup>Radiology Department, Hanoi Medical University, Ha Noi, Vietnam

<sup>b</sup>Radiology Center, Bach Mai Hospital, Ha Noi, Vietnam

<sup>c</sup>Neurology Department, Bach Mai Hospital, Ha Noi, Vietnam

<sup>d</sup>Department of Thoracic, Vascular and Neurology, Trung Vuong Hospital, Ho Chi Minh city, Vietnam

## ARTICLE INFO

## Article history:

Received 12 September 2020

Revised 3 November 2020

Accepted 5 November 2020

## Keywords:

Trauma

Cerebral Artery

Cavernous Sinus

Fistula

## ABSTRACT

Direct anterior cerebral artery-cavernous sinus fistula is an extremely rare complication of head trauma. We describe a male patient (age 49 years) with a history of head trauma 15 years ago who was hospitalised for a bulging red eye and tinnitus. Digital subtraction angiography showed a direct anterior cerebral artery (fork junction A1 - prior passage)-cavernous sinus fistula. The patient was treated with arterial endovascular intervention, complete sealing of the fistula orifice using coils. He was discharged 5 days later with no symptoms of a bulging red eye, ringing in the ears, or nerve paralysis. Re-examination after 3 months of stable clinical features did not show recurrent fistula. In conclusion, anterior cerebral artery-cavernous sinus fistula is an extremely rare lesion, and arterial endovascular intervention using coils is a safe and effective method for treatment of such lesion.

© 2020 The Authors. Published by Elsevier Inc. on behalf of University of Washington.

This is an open access article under the CC BY-NC-ND license

(<http://creativecommons.org/licenses/by-nc-nd/4.0/>)

## Introduction

Intracranial arteriovenous fistula is one of the vascular complications of head trauma. The most common condition is carotid cavernous fistula (CCF), which has been fully understood and described in the literature [1]. Our paper describes

a very rare clinical case, as far as we know, of direct anterior cerebral artery (ACA)-cavernous sinus fistula; only 1 case has been reported previously in the world [2]. We aimed to introduce radiologists and neurointerventional radiologists to an extremely rare clinical case of an arteriovenous fistula in the cavernous sinus area, and discuss the results of endovascular intervention using coils.

Abbreviation: CCF, carotid cavernous fistula; ACA, anterior cerebral artery; AcoA, Anterior communicating artery; DSA, digital subtraction angiography.

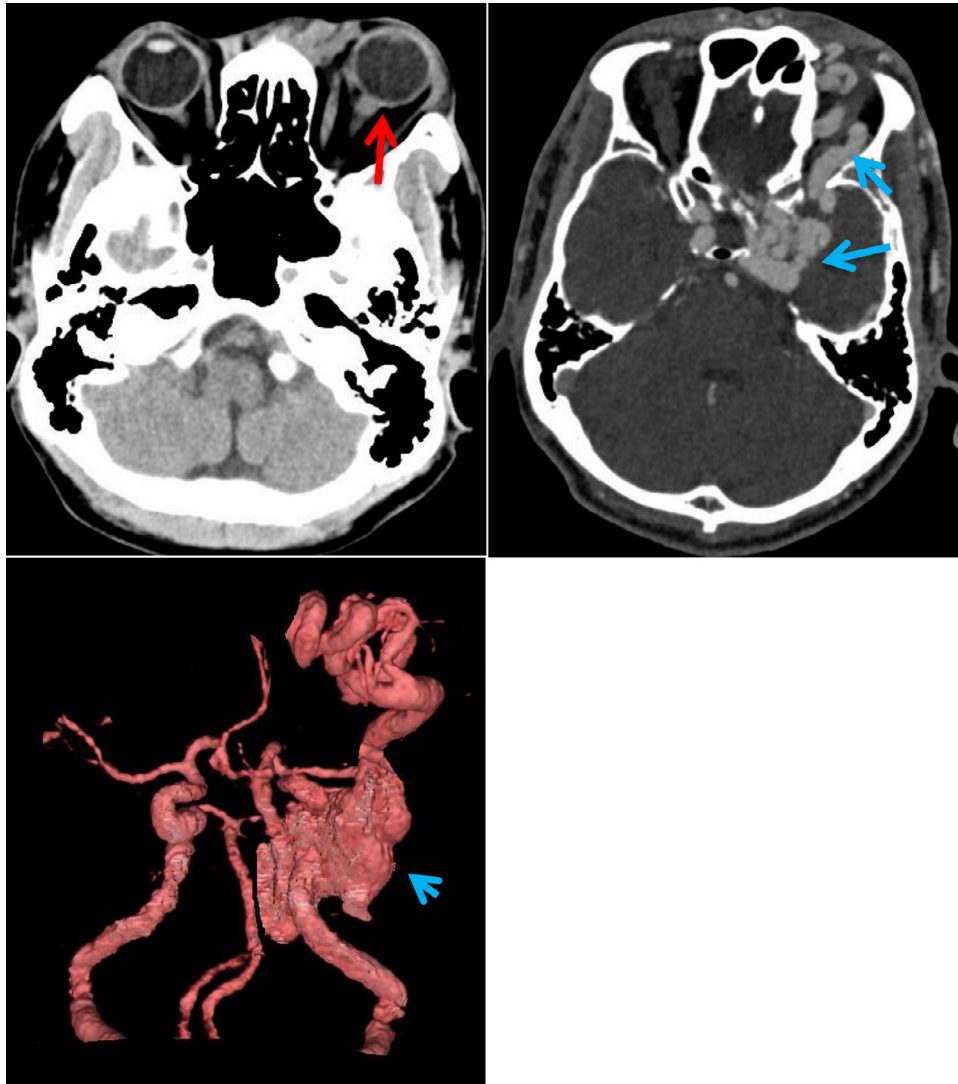
<sup>☆</sup> Competing Interests: none

\* Corresponding author.

E-mail address: [lenguyen.quyen@yahoo.com](mailto:lenguyen.quyen@yahoo.com) (L.N. Quyen).

<https://doi.org/10.1016/j.radcr.2020.11.012>

1930-0433/© 2020 The Authors. Published by Elsevier Inc. on behalf of University of Washington. This is an open access article under the CC BY-NC-ND license (<http://creativecommons.org/licenses/by-nc-nd/4.0/>)



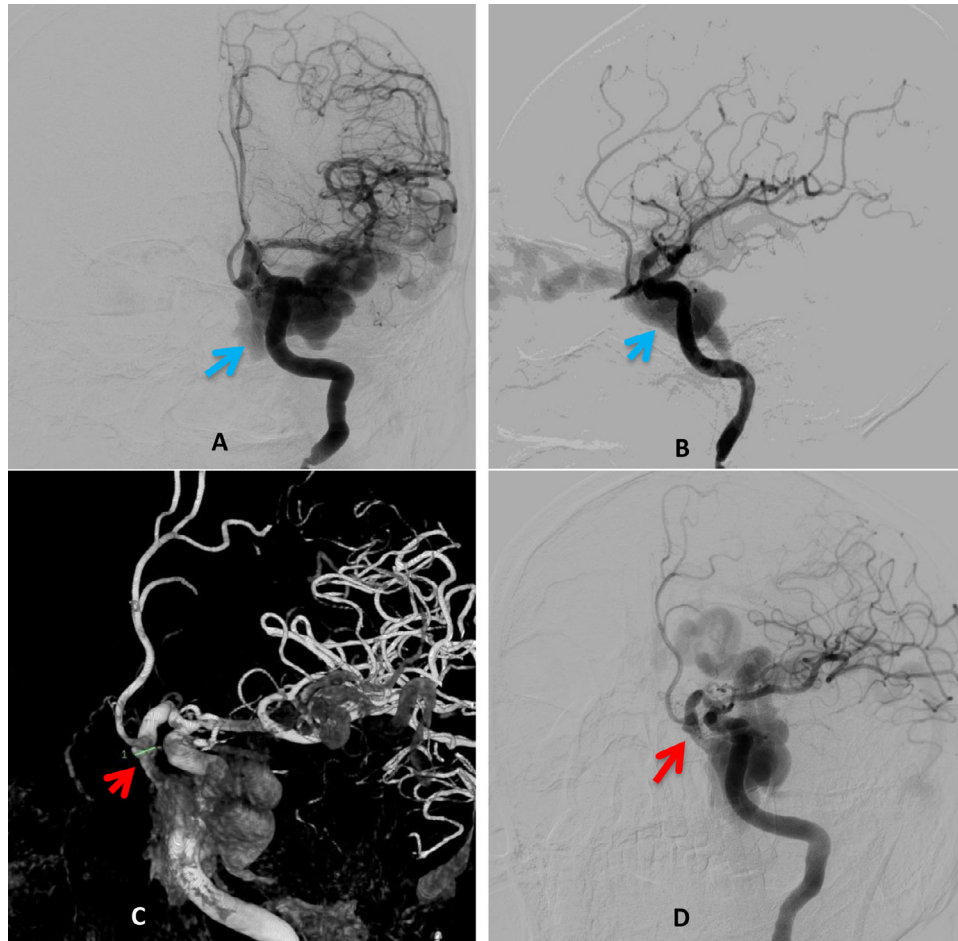
**Fig. 1** – Multi-slice computed tomography image, suspected of left carotid artery – cavernous sinus fistula, unknown carotid artery tear, notice of fistula from left ACA into left cavernous sinus. Red arrow: Exophthalmos; blue arrow: Dilatation of cavernous sinus and ophthalmic vein.

### Case presentation

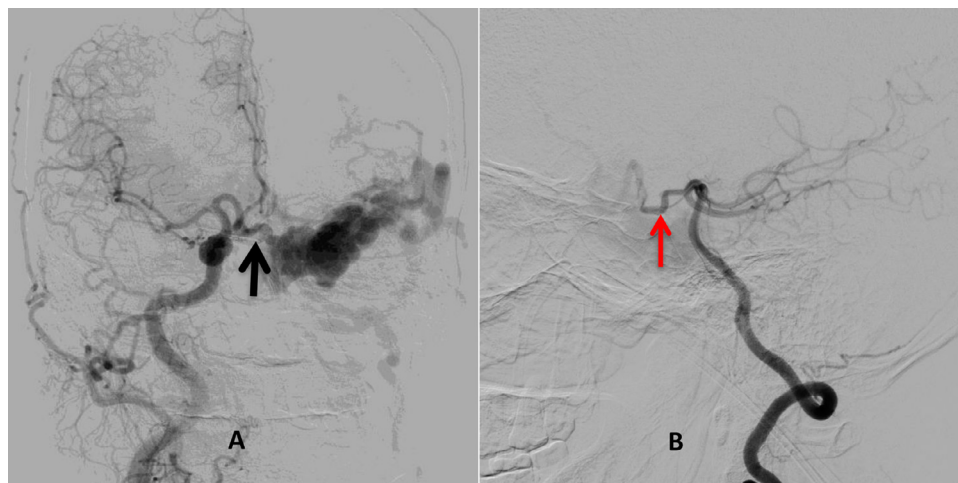
**Clinical findings:** A male patient aged 49 years had a history of traffic accident 15 years prior, with complex facial trauma and orthopaedic surgery of the lower jaw. He had no other abnormalities, but imaging data were not available at the time. Before his admission to the hospital, he experienced symptoms including bulging red eye, increased tinnitus in the left ear, and pain in the left half of his head for about 2 months. Head multi-slice computed tomography imaging showed remote contusions in both frontal lobes, cranial deformity (old bone fractures and osteodystrophy), protracted left eye, enlarged left cavernous sinus, early opacification of artery, and retrograde venous drainage of the left superior ophthalmic vein and cerebral cortex vein. Imaging findings suggested direct CCF; the orifice of the ruptured inner carotid was not vis-

ible because of image overlap, and we noted a fistula between the left ACA A1-anterior communicating artery (AcoA) junction and the left cavernous sinus (Fig. 1).

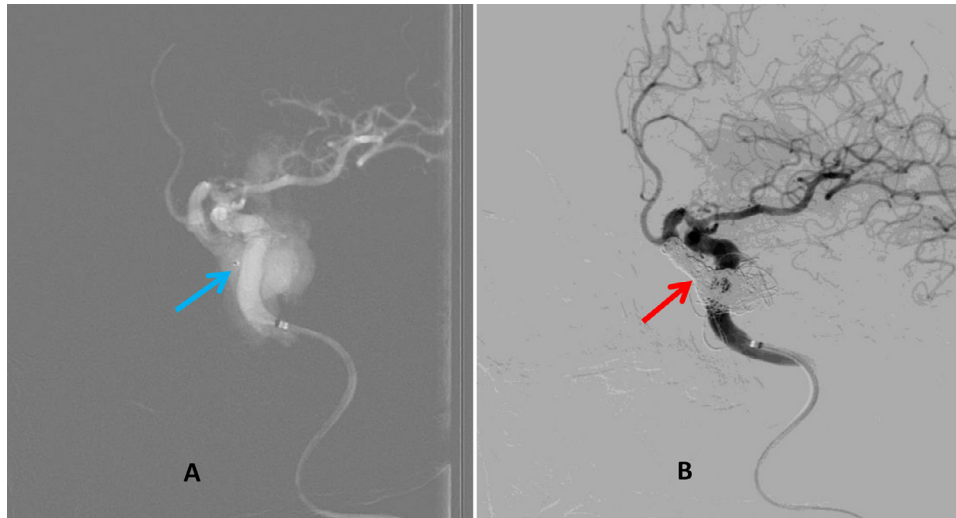
The patient was scheduled to undergo digital subtraction angiography (DSA) 1 day later. Left carotid angiography showed that the left A1 artery was located anteriorly (forward) and downward, and there was a direct fistula with the left cavernous sinus; pouch-like enlargement of the left cavernous sinus; retrograde drainage of the ipsilateral superior ophthalmic vein, mastoid emissary vein, and cerebral cortex vein; and no tearing of the left internal carotid artery (Fig. 2). A scan of the right common carotid artery and left vertebral artery showed that collateral circulation at the anterior and posterior communicating arteries was relatively good, with circulation through the collateral vessels and into the fistula (Fig. 3A, B). Bilateral external carotid angiography did not show the fistula orifice in the cavernous sinus. Therefore, the



**Fig. 2** – The DSA showed cavernous sinus (blue arrow); and fistula between ACA and cavernous sinus (red arrow). A: Left carotid artery – coronal view; B: Left carotid artery – sagittal view; C: 3D exposure of left ACA – cavernous sinus; D: Left carotid artery – interventional view.



**Fig. 3** – The DSA showed anterior communicating artery (black arrow) and posterior communicating arteries (red arrow). A: Right common carotid artery, flow between anterior communicating artery and fistula orifice; B: Left vertebral artery, flow through posterior communicating artery into fistula orifice.



**Fig. 4 – Endovascular treatment with microcath head (blue arrow) and coils inside cavernous sinus and fistula (red arrow). A: Microcath head inside cavernous sinus image; B: After fistula thrombogenic clogging – interventional view.**

patient had a direct fistula going from the left ACA into the left cavernous sinus. The position of the neck of the fistula was determined on 3-dimensional imaging; the neck diameter was 4.5 mm, and the left cavernous sinus was dilated with a diameter of about 20 mm. We decided to treat the patient immediately with an option for access through the artery.

**Endovascular treatment:** The dual-guiding Neuro Max 088 (Penumbra Inc.) and 6-French (F) Navien catheter (Covidien/Medtronic) were positioned at the C3 segment of the left internal carotid artery to reveal the position of the neck of the fistula and preserve the ACA and anterior communicating artery. Then the 1.7-F microcatheter (curved head, 45 degrees; Echelon) was used with a 0.014" Transcend microwire (Stryker) to approach the left ACA, through the fistula orifice into the left cavernous sinus so the the microcatheter head would be placed in the middle of the sinus pouch. Here, we proceeded to release coils (sizes 20/50 × 3, 18/40 × 2, 12/40); they coiled around inside the cavernous sinus pouch and created a resting spot so we could release and extract the microcatheter head near the neck of the fistula. Then we continued releasing coils (sizes 8/30, 7/30) close to the neck of the fistula (Fig. 4A). Examination of both internal carotid arteries showed that the flow was completely blocked, ACA and anterior communicating artery were preserved, and circulation to the brain was not slow or blocked (Fig. 5A-C). Clinically, the patient improved immediately after the intervention: the aching, bulging red eye was reduced and tinnitus was relieved.

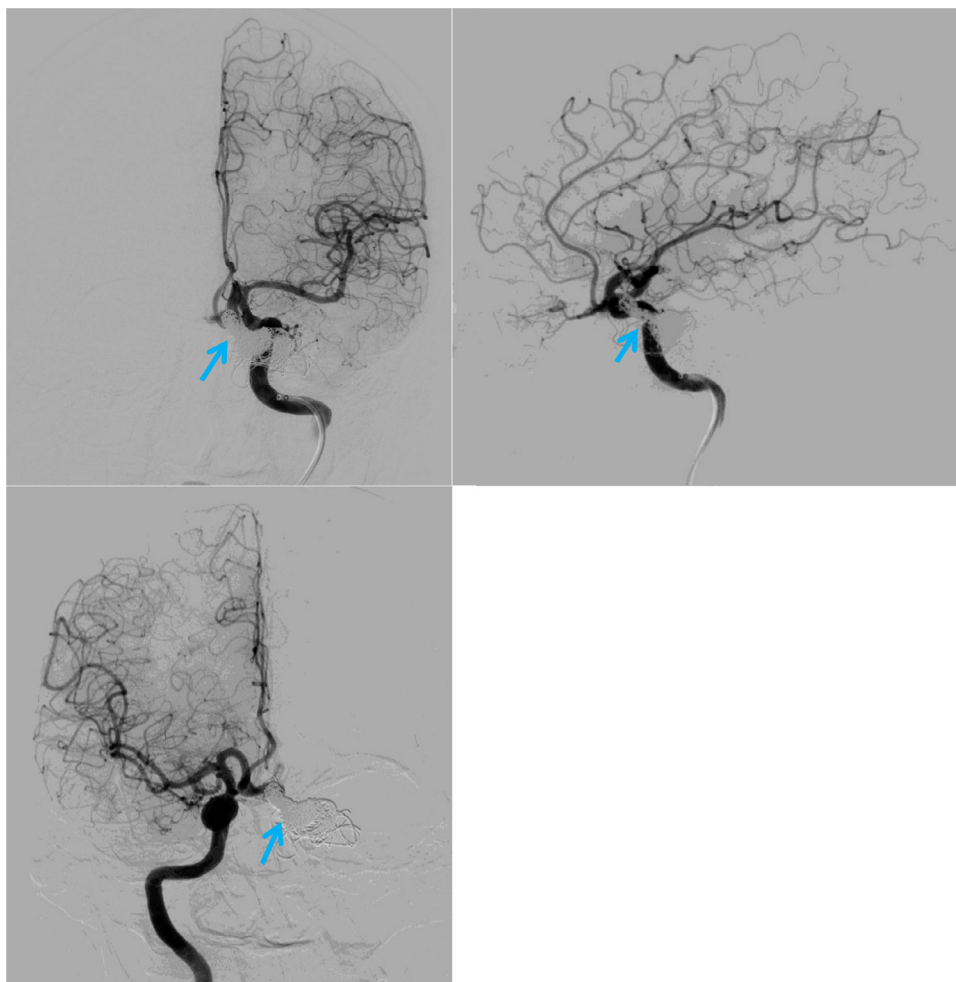
**Outcome:** The patient was discharged after 5 days with stable clinical features and laboratory test results. Follow-up examination after 3 months showed that the clinical and imaging features were improved. The patient no longer had symptoms of ACA-cavernous sinus fistula. Magnetic resonance imaging also showed completed occlusion of circulation (Fig. 6).

## Discussion

The term CCF refers to the common anomalous pathology between the carotid artery and cavernous sinus, and Barrow's classic classification of CCF is based on arterial blood supply and includes 4 groups: a, b, c, and d [3]. Most arteriovenous fistula lesions in the cavernous sinus belong to 1 of these 4 groups. Nevertheless, there are many reports of cases of arteriovenous fistula lesions outside the four categories mentioned above, such as posterior communicating artery-cavernous sinus fistula (8 cases) [4] and trigeminal embryonic artery-cavernous sinus fistula (10 cases) [5]. Fundamentally, CCFs are direct branches from the internal carotid artery located inside or close to dural cavernous sinuses. However, our case of ACA-cavernous sinus fistula is very rare and rarely reported in the literature.

Anatomically, the cavernous sinus is located on either side of the sellar turcica; its inner and lower walls are adjacent to the skull base, and its upper and outer walls are covered by dura mater. The A1 segment of the ACA is a component of the circle of Willis, which is located in the basal basin, above the sellar turcica, usually on the optic chiasm (70%) or optic nerve (30%) [6], quite separate from the location of the cavernous sinus. In the event of a fistula between the ACA and cavernous sinus after injury, physicians are more inclined to assume that two concurrent lesions have occurred simultaneously, which is the formation of a pseudoaneurysm at the lower edge of the ACA-ACoA junction, in parallel with tearing of the dura mater of the cavernous sinus. Over time the pseudoaneurysm grows bigger, extending downwards and lying within the left cavernous sinus, surrounded by the connective tissue and surrounding structures. Later, the phenomenon of rupture occurs at the bottom of the pseudoaneurysmal sac within the sinus [7,8], which causes arteriovenous fistula with a characteristic clinical presentation: blood flow drains in the cavernous

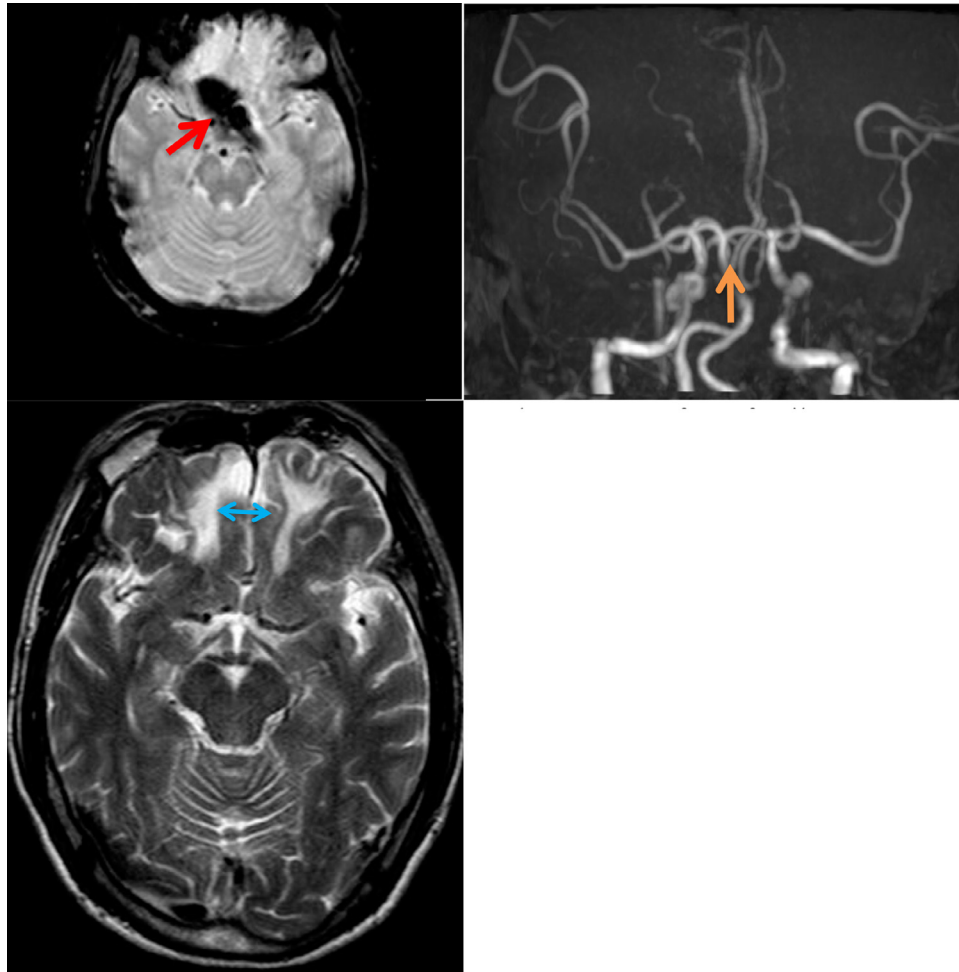




**Fig. 5 – Series of images after intervention, preserved ACA and anterior communicating artery (blue arrow: coils closing fistula).**

sinus and venous system, there is no subarachnoid haemorrhage because of the connective tissue, and dura mater of the cavernous sinus is sealed. Because of the lack of image data during the period before clinical presentation, the above scenario is only hypothetical. The mechanism behind the formation of ACA pseudoaneurysm after head injury, either due to a fragment of a sphenoid bone fracture or a tearing force, is actually quite rare [9]. The simultaneous occurrence of tearing of the dura mater of the cavernous sinus and pseudoaneurysmal rupture within the cavernous sinus is even more rare in reality. In a case report by Sakamoto et al. [2], computed tomography angiography of a head trauma patient with subarachnoid haemorrhage showed a fairly clear image of the AcoA aneurysm. The detection of the AcoA-cavernous sinus fistula was accidental on DSA, and there were no characteristic clinical manifestations because of the small flow circulation. In our case, the morphology of the pseudoaneurysm was unclear, but the ACA fistula orifice flowed directly into the enlarged left cavernous sinus with a high flow through the shunt.

Surgery carries many risks because of the involvement of many neurological components in the cavernous sinus, and radiation surgery is not effective with a direct high-flow shunt. In cases where the direct fistula lesion of the carotid artery is within the cavernous sinus, endovascular intervention is currently the procedure of choice, with the two most common materials being detachable balloons or coils [10]. In this case, use of a balloon was not possible because of the distance of the tear-orifice position and the vessel segment behind the cavernous sinus had many zigzag bends. Hence, we chose to treat the patient with an endovascular intervention via artery access and to use Guglielmi detachable coils. With the fistula orifice located at the AcoA-A2 junction, use of the coils must ensure closure of the fistula orifice without blocking the A1 and anterior communicating artery. We chose an interventional site at which the border of the fistula neck and A1 were clearly exposed, and then we proceeded to approach and release the coils into the cavernous sinus as treatment for a giant aneurysm; the difference here is that there was no need for coil release into the aneurysm because it would cause



**Fig. 6 – MRI scan 3 months after intervention showed normal cerebral vascular, no existing ACA - cavernous sinus flow (red arrow: artefact of coils on T2W hemo; orange arrow: close of fistula; blue arrow: ancient of frontal contusion due to traumatism).**

extensive mass effect and would not be successful. Thus, the goal of simply blocking the tear flow is sufficient. However, because of the enlargement of the cavernous sinus and high pressure flow inside, we chose the maximum coil sizes, which helped us quickly create the resting spot in the cavernous sinus, forming the fulcrum for the coils that gradually accumulated to the fistula neck later. For the finishing coils, we chose coil sizes that corresponded to the aneurysm size near the neck segment, and we tried to perform a controlled release under DSA guidance (smart marks).

## Conclusion

ACA-cavernous sinus fistula following head trauma is very rare in the literature, and it is hypothetically thought to be formed by ACA pseudoaneurysm, which then ruptures into the cavernous sinus. We described a rare clinical case of direct ACA-cavernous sinus fistula for which endovascular intervention via arterial access with use of coils was effective and safe.

## Informed consent

Written informed consent for publication of this case was obtained from the patient.

## REFERENCES

- [1] Fabian TS, Woody JD, Ciraulo DL, Lett ED, Phlegar RF, Barker DE, et al. Posttraumatic carotid cavernous fistula: frequency analysis of signs, symptoms, and disability outcomes after angiographic embolization. *J Trauma* 1999;47:275–81.
- [2] Sakamoto S, Shibukawa M, Kiura Y, Tsumura R, Okazaki T, Matsushige T, et al. Traumatic anterior communicating artery pseudoaneurysm with cavernous sinus fistula. *Acta Neurochir (Wien)* 2009;151:1531–5.
- [3] Barrow DL, Spector RH, Braun IF, Landman JA, Tindall SC, Tindall GT. Classification and treatment of spontaneous carotid-cavernous sinus fistulas. *J Neurosurg* 1985;62:248–56.

- 
- [4] Li W, Li N, Lv M, Li Y. Comprehensive endovascular treatments of traumatic pseudoaneurysm of the posterior communicating artery combined with cavernous sinus fistula: a case report and literature review. *Int J Clin Exp Med* 2019;12:4428–33.
- [5] Fan Y, Li Y, Zhang T, Jiang C, Zhang P. Carotid-Cavernous Sinus Fistula caused by Persistent Primitive Trigeminal Artery Aneurysm rupture: A case report. *J Stroke Cerebrovasc Dis* 2019;28:104306.
- [6] Wolpert SM. The circle of Willis. *AJNR Am J Neuroradiol* 1997;18:1033–4.
- [7] Cohen JE, Gomori JM, Segal R, Spivak A, Margolin E, Svirin G, et al. Results of endovascular treatment of traumatic intracranial aneurysms. *Neurosurgery* 2008;63:476–85 discussion 485–6.
- [8] De Blasi R, Bracciolini E, Chiumarulo L, Salvati A, Monetti C, Federico F, et al. Pseudoaneurysm formation following intrasphenoid rupture of an idiopathic intracavernous carotid artery aneurysm: coil migration and early recurrence after endovascular treatment. *Interv Neuroradiol* 2010;16:442–6.
- [9] Yang TC, Lo YL, Huang YC, Yang ST. Traumatic anterior cerebral artery aneurysm following blunt craniofacial trauma. *Eur Neurol* 2007;58:239–45.
- [10] Korkmazer B, Kocak B, Tureci E, Islak C, Kocer N, Kizilkilic O. Endovascular treatment of carotid cavernous sinus fistula: A systematic review. *World J Radiol* 2013;5:143–55.