

## Technical Note

# Novel surgical technique to solidify cyst-type metastatic brain tumors using autologous fibrin glue for complete resection

Takeshi Okuda, Mitsugu Fujita<sup>1</sup>, Hiromasa Yoshioka, Takayuki Tasaki, Amami KatoDepartments of Neurosurgery and <sup>1</sup>Microbiology, Kinki University Faculty of Medicine, 377-2 Ohno-Higashi, Osaka-Sayama, Osaka 589-8511, JapanE-mail: \*Takeshi Okuda - [okuda@med.kindai.ac.jp](mailto:okuda@med.kindai.ac.jp); Mitsugu Fujita - [mfujita@med.kindai.ac.jp](mailto:mfujita@med.kindai.ac.jp); Hiromasa Yoshioka - [yoshioka2327@med.kindai.ac.jp](mailto:yoshioka2327@med.kindai.ac.jp); Takayuki Tasaki - [tasaki-kin@umin.org](mailto:tasaki-kin@umin.org); Amami Kato - [akato-osk@umin.org](mailto:akato-osk@umin.org)

\*Corresponding author

Received: 06 February 14 Accepted: 02 May 14 Published: 25 June 14

**This article may be cited as:**Okuda T, Fujita M, Yoshioka H, Tasaki T, Kato A. Novel surgical technique to solidify cyst-type metastatic brain tumors using autologous fibrin glue for complete resection. *Surg Neurol Int* 2014;5:100.Available FREE in open access from: <http://www.surgicalneurologyint.com/text.asp?2014/5/1/100/135304>

Copyright: © 2014 Okuda T. This is an open-access article distributed under the terms of the Creative Commons Attribution License, which permits unrestricted use, distribution, and reproduction in any medium, provided the original author and source are credited.

## Abstract

**Background:** An outstanding issue regarding the surgical treatment of cyst-type metastatic brain tumors is the incomplete resection of cyst walls. Herein we propose a novel surgical technique that can overcome this issue. During a surgical procedure for cystic tumors, autologous fibrin glue is to be injected into the tumor cysts, which solidifies the cyst lumens and cyst walls *en bloc* with reducing the tumor size. As a result, tumor masses and cyst walls can be removed completely in an *en bloc* fashion in all cases.

**Methods:** The illustrative case presented in this report is a patient with metastatic brain tumors in the frontal lobe. When we reached the tumor wall surgically, we first suctioned out the cyst content and subsequently injected autologous fibrin glue into the cyst lumen. The autologous fibrin glue solidified the tumor *en bloc*, and we resected the tumor mass and the cyst walls in an *en bloc* fashion.

**Results:** We have applied this technique to four cases with cyst-type metastatic brain tumors. This approach made it possible to perform ideal *en bloc* resection in all cases. There were no adverse events due to the autologous fibrin glue.

**Conclusion:** We developed a novel surgical technique to solidify cyst-type metastatic brain tumors using autologous fibrin glue, which allows *en bloc* resection of tumor masses and cyst walls quite safely using inexpensive materials. Given these advantages, it appears a promising surgical strategy for cyst-type metastatic brain tumors.

**Key Words:** Autologous fibrin glue, brain metastasis, cystic brain tumor

**Access this article online****Website:**[www.surgicalneurologyint.com](http://www.surgicalneurologyint.com)**DOI:**

10.4103/2152-7806.135304

**Quick Response Code:**

## INTRODUCTION

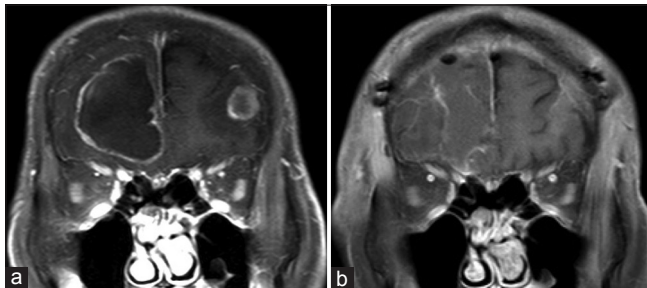
Among various therapeutic approaches for metastatic brain tumors, surgical resection is the most powerful because it allows a substantial reduction in tumor volume. In particular, *en bloc* resection of tumors is considered ideal (including those with a circumferential margin of about 5 mm).<sup>[3]</sup> However, cystic tumors

are often difficult to completely remove due to the thinness and plasticity of the cyst walls. There is also a risk of tumor dissemination by dispersion of the cyst contents into cerebrospinal fluid.<sup>[4]</sup> To overcome these issues, several ingenious methods have been proposed to solidify the cystic tumors with solid-state materials such as cotton sheets or hydrofiber dressing.<sup>[5]</sup> To further strengthen the principle of these strategies, we developed

another new technique to use liquid-state autologous fibrin glue for cyst-type metastatic brain tumors. In this technique, autologous fibrin glue fill cyst lumens and solidify the tumors *en bloc*. As a result, it became easily achievable to resect tumor masses/cyst walls *en bloc* in all cases. Given the advantages of this technique, it appears a promising surgical strategy for cyst-type metastatic brain tumors.

## METHODS

Herein we show an illustrative case of metastatic brain tumor in bilateral frontal lobes [Figure 1a]. To apply this technique, we collected 300 ml of peripheral blood from the patient in advance and extracted approximately 6 ml of autologous cryoprecipitate. At the beginning of the surgery, 5000 units thrombin (Mochida, Tokyo, Japan) was dissolved in physiological saline in total 7.5 ml. Then, we performed a bilateral craniotomy to approach



**Figure 1: MR images before and after surgery. (a) Preoperative images. The tumors are located in the bilateral frontal lobes; the present method is planned for the right frontal lesion. (b) Postoperative images 1 day after surgery. Total resection of the tumor is achieved with no tumor remnants. Both are coronal contrast-enhanced T1-weighted images**

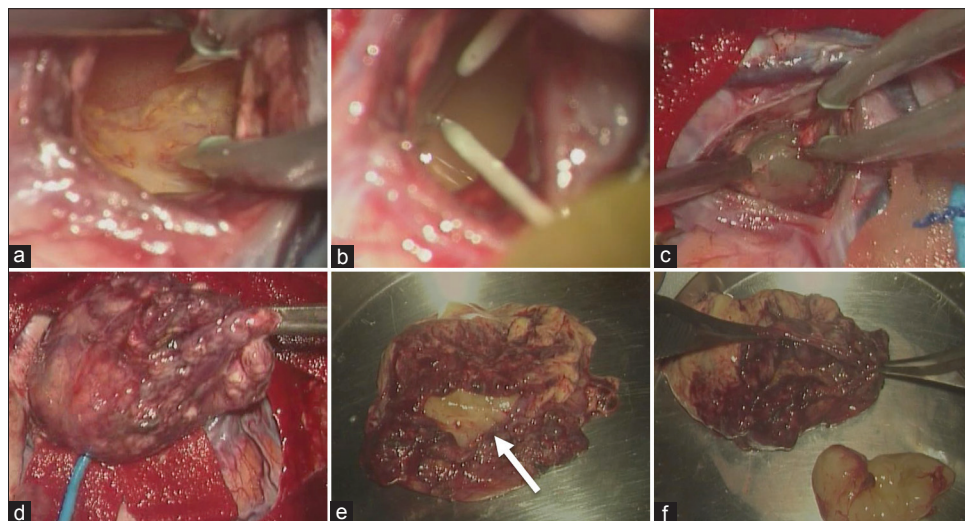
the large cystic lesion in the right frontal lobe. When we reached the tumor located in the right frontal lobe, the cyst contents were suctioned out to investigate the inside of the tumor cyst [Figure 2a]. A small piece of the tumor tissue was removed for intraoperative pathological diagnosis, and the autologous cryoprecipitate (6 ml) and the thrombin solution (6 ml) were injected into the cyst lumen [Figure 2b]. Intraoperative ultrasonography pre- and postinjection of the fibrin glue demonstrated a substantial reduction in tumor size (less than half in diameter) along with the solidification of the cyst walls [Figure 3]. We resected the tumor mass and the cyst walls in an *en bloc* fashion [Figure 2c-f]. Postoperative magnetic resonance images demonstrated complete resection with no remnants [Figure 1b]. No particular adverse events were encountered during the perioperative period.

## RESULTS

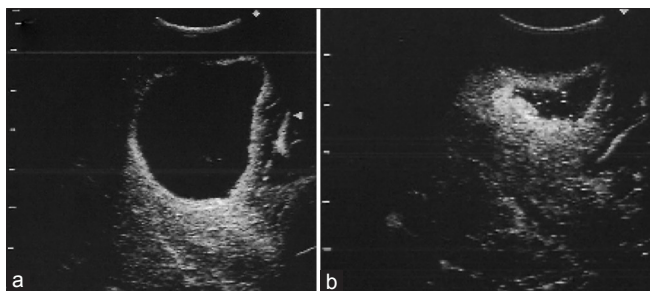
We have applied this technique to four cases with cyst-type metastatic brain tumors. This approach made it possible to perform ideal *en bloc* resection in all cases. There were no adverse events, local recurrence, and/or dissemination observed during 3 months follow-up periods.

## DISCUSSION

Autologous fibrin glue was first reported in 1983 and is currently used in various surgical procedures.<sup>[1]</sup> Autologous fibrin glue offers excellent tissue hemostasis, adhesion, and covering effects. In addition, complement and immunoglobulins in autologous fibrin glue are known to inhibit proliferation of *Escherichia coli*, which



**Figure 2: Intraoperative photographs. (a) Cyst contents are drained and the lumen is observed. (b) Autologous cryoprecipitate and thrombin solution are injected simultaneously. (c) Tumor cyst is solidified. The autologous fibrin glue is filled to level of the injection site. (d) *En bloc* resection is performed including the cyst walls. (e) Resected tumor. Arrow: the injection site. (f) Separation of the solidified autologous fibrin glue from the cystic tumor**



**Figure 3: Intraoperative ultrasound photographs. (a) Before drainage of the cyst contents. (b) After the drainage of cyst contents followed by injection of autologous fibrin glue. The tumor size reduces to less than half of the original size. The cyst wall is thickened**

suggests that this material can help prevent surgical wound infection.<sup>[2]</sup>

We used the autologous fibrin glue to solidify tumor cyst lumens and cyst wall *en bloc*. This method allows complete resection of tumor masses and cyst walls in most cases. Previously, cotton sheets, hydrofiber dressing, or some other solid-state materials have been used to solidify the cystic tumors.<sup>[5]</sup> In this study, to further strengthen the principle of these strategies, we developed another new technique to use liquid-state autologous fibrin glue for cyst-type metastatic brain tumors. Compared with the solid-state materials, the autologous fibrin glue can fill the cyst lumens equally even if tumors are in complex shapes. Moreover, autologous fibrin glue solidifies the cystic tumors to a moderate hardness (harder than normal tissues), which makes cyst wall resection very feasible. Another advantage of the present method is that solidification of the cyst contents can prevent tumor cell dissemination into cerebrospinal fluid. Furthermore, the present method reduces the tumor size approximately into half, which makes the resection much easier. Finally, autologous fibrin glue is relatively inexpensive to prepare compared with commercially available fibrin glue products and therefore can be used easily at most institutions.

We have not achieved long-term follow-up for the patients thus far. However, mid-term follow-up (3 months at shortest) indicates no local recurrence or dissemination. However, it still remains to be elucidated whether this technique contributes to reduce local failure and/or dissemination during long-term follow-up periods after surgery.

A disadvantage of the present method is that autologous blood draw is necessary prior to surgery. Since advanced cancer patients often exhibit chronic anemia, even a small

volume of blood draw (200 ml) could be a heavy burden. Another possible issue is that viral infection or allergic reactions may occur because thrombin is derived from pooled human serum. To overcome this issue, complete thrombin isolation and purification system is currently under development.<sup>[6]</sup>

## CONCLUSION

We developed a novel surgical technique to solidify cyst-type metastatic brain tumors using autologous fibrin glue. This procedure allowed *en bloc* resection of tumor masses as well as cyst walls in all cases quite safely using inexpensive materials. Given these advantages, it appears a promising surgical strategy for cyst-type metastatic brain tumors.

Author contributions to the study and manuscript preparation include the following: Conception and design: Okuda. Acquisition of data: All authors. Drafting the article: Okuda, Fujita. Study supervision: Kato.

## ACKNOWLEDGMENT

The authors thank Ms. Heather A. Garing at Children's Hospital of UPMC for her writing/proofing assistance.

## DISCLOSURE

Dr. Kato has received support from GlaxoSmithkline K.K. and Otsuka Pharmaceutical Co., Ltd for nonstudy-related clinical or research effort. Other authors report no conflict of interest concerning the materials or methods used in this study or the findings specified in this manuscript.

## REFERENCES

1. Gestring GF, Lerner R. Autologous Fibrinogen for Tissue-Adhesion, Hemostasis and Embolization. *Vasc Endovascular Surg* 1983;17:294-304.
2. Kinoshita Y, Udagawa H, Tsutsumi K, Ueno M, Nakamura T, Iizuka T, et al. Bacteriological study of autologous cryoprecipitate-derived fibrin glue as the operative sealant. *Transfus Med* 2005;15:429-33.
3. Modha A, Shepard SR, Gutin PH. Surgery of brain metastases--is there still a place for it? *J Neurooncol* 2005;75:21-9.
4. Nakagawa H, Kimura S, Kubo S, Fujita T, Tsuruzono K, Hayakawa T. Prognostic factors in patients surviving for more than 1 or 5 years after removal of metastatic brain tumors. *Neurol Med Chir (Tokyo)* 1992;32:947-51.
5. Okuda T, Teramoto Y, Yugami H, Kataoka K, Kato A. Surgical technique for a cystic-type metastatic brain tumor: Transformation to a solid-type tumor using hydrofiber dressing. *Surg Neurol* 2009;72:703-6.
6. Rock G, Neurath D, Semple E, Harvey M, Freedman M. Preparation and characterization of human thrombin for use in a fibrin glue. *Transfus Med* 2007;17:187-91.