

Double-Eyelid Surgery Using Septoaponeurosis Junctional Thickening Results in Dynamic Fold in Asians

Hong Seok Kim, MD, PhD*
Kun Hwang, MD, PhD†
Chang Kyung Kim, MS‡
Kenneth K. Kim, MD, FACS†§

Background: To avoid a static double-eyelid fold characterized by nonmobile overdepression of the fold, we propose a new surgical approach of using septoaponeurosis junctional thickening (SAJT) to create a dynamic fold.

Methods: Six hundred eighty patients underwent double-eyelid surgery using the SAJT fixation technique. The orbital septum was exposed and transversely opened superior to the incision margin. The lower septal stump was trimmed to expose the SAJT. The dermis and orbicularis oculi muscle of the lower flap of the upper eyelid were attached to the SAJT. Patients were followed for 2–8 years (mean, 3.6 y). Anatomic study with 28 upper eyelids from 28 Korean adult cadavers was performed to confirm the histological structure of the SAJT.

Results: This technique created a dynamic fold. When the eyes were open, the fold depth was moderate. When the eyes were closed, the fold site was smooth and not depressed. The surgery had a 95% patient satisfaction rate (365 responded as satisfied and 236 responded as very satisfied). Postoperative complications included partial or complete loss of the double-eyelid line in 14 and 4 cases, respectively, hypertrophic scar formation in 7 cases, and asymmetric fold in 8 cases.

Conclusions: The authors introduce a double-eyelid surgery technique using the SAJT. This SAJT fixation technique creates a dynamic double-eyelid fold. Our study showed a high patient satisfaction rate and that the resulting fold mimics the movement of the congenital supratarsal fold in Asians. (PRS GO 2013;1:e14; doi:10.1097/GOX.0b013e318293dc69; Published online 9 May 2013.)

Upper eyelid blepharoplasty is the most commonly performed procedure in Asian aesthetic plastic surgery.^{1–3} A great emphasis was placed on creating the ideal eye, which mimics the

congenital or “natural” double eyelid, characterized as follows: 1) a smooth upper eyelid with a shallow fold line when eyes are closed; 2) a fold line that is not fixated onto the tarsus and thus capable of changing with eye movement; 3) equally distributed

From the *Ohkims Plastic Surgical Clinic, Ilsan, South Korea; †Department of Plastic Surgery, College of Medicine, Inha University, Incheon, South Korea; ‡Dream Medical Group, Los Angeles, Calif.; and §Division of Plastic and Reconstructive Surgery, David Geffen School of Medicine at University of California, Los Angeles, Calif.

Presented at the Korean Society of Plastic and Reconstructive Surgeons, in Seoul, South Korea, November 20, 2009, and at the World Congress of the Minimal Invasive Plastic Surgery and Dermatology, Seoul, South Korea, September 10, 2010.

Received for publication November 12, 2012; accepted March 21, 2013.

Copyright © 2013 American Society of Plastic Surgeons. Unauthorized reproduction of this article is prohibited. This is an open-access article distributed under the terms of the Creative Commons Attribution-NonCommercial-

NoDerivatives 3.0 License, where it is permissible to download and share the work provided it is properly cited. The work cannot be changed in any way or used commercially.

DOI: 10.1097/GOX.0b013e318293dc69

Disclosure: The authors have no financial interest to declare in relation to the content of this article. The Article Processing Charge was paid for by the authors.

Supplemental digital content is available for this article. Clickable URL citations appear in the text.

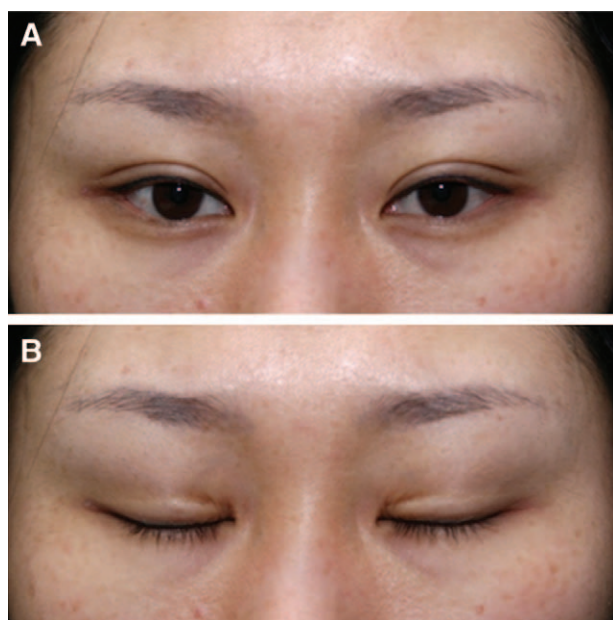



Fig. 1. Photographs of a 27-y-old woman exhibiting a static fold after she underwent double-eyelid surgery using the tarsal fixation technique. A static fold is characterized by deep fold formation (A), a visibly depressed line along the incision with eyes closed, and an immobile line (B).



Video Graphic 1. See video, Supplemental Digital Content 1, which shows the front and side views of a 29-year-old woman exhibiting a static fold after she underwent double eyelid surgery using the tarsal fixation technique as she opens and closes her eyes, <http://links.lww.com/PRSGO/A0>.

tension at the upper and lower flaps of the fold line; and 4) appropriate depth of the fold when the eyes are fully open.

Despite the variation of techniques in blepharoplasty, there resides a fundamental goal to fix the dermis of the upper eyelid to the posterior lamella, a region involved in eyelid elevation. There are suture (nonincisional) and incisional techniques in double-eyelid surgery. The suture technique is advantageous in which it creates the ideal fold without making an incision, and thus, no postoperative scars. However, many Asian patients with single

eyelids have thick soft tissue (retro-orbicularis ocular fat, preaponeurotic fat, thick orbicularis muscle) and redundant skin, which contribute to puffiness in the eyelid.³⁻⁵ Under such conditions, the suture technique does not provide an effective and permanent result due to the heavy imposition of the thick eyelid layer on the fixating sutures. In addition, a patient with excess skin requires excision of redundant soft tissue. Therefore, the incisional technique is a preferable method for these patients.

The tarsal fixation technique (dermis of upper lid to tarsus) is the oldest and more commonly performed method, but the technique over-resects pretarsal tissue, resulting in a deep, immovable, depressed fold. This type of fold is defined as a static fold (Fig. 1) (See video, Supplemental Digital Content 1, which shows the front and side views of a 29-year-old woman exhibiting a static fold after she underwent double eyelid surgery using the tarsal fixation technique as she opens and closes her eyes, <http://links.lww.com/PRSGO/A0>.)

We devised a technique that uses the septoaponeurosis junctional thickening (SAJT). It creates a fold line that changes with the movement of the eyelid. When the eyes are closed, the SAJT extends toward the skin and prevents formation of a depressed fold. When the eyes are open, the levator excursion pulls the SAJT, and the fold occurs. This movement mimics the natural fold mechanism, and this type of fold is defined as the dynamic fold (Fig. 2) (See video, Supplemental Digital Content 2, which shows the front and quarter views of the same patient exhibiting a dynamic fold after she received double eyelid surgery using septoaponeurosis junctional thickening fixation as she opens and closes her eyes, <http://links.lww.com/PRSGO/A1>.)

PATIENTS AND METHODS

Anatomic Study

Twenty-eight upper eyelids from 28 Korean adult cadavers [mean age, 65.8 y (SD, 10.8 y); 13 males, 15 females] were used to confirm the histological structure of the SAJT. Specimen preparation and Masson's trichrome staining were performed as described.⁶

The septum inner layer joins the levator aponeurosis at the conjoined junction above the tarsal plate. The septum outer layer (Fig. 3, *blue arrow*) extends inferiorly to the tarsus where it connects with the orbicularis oculi muscle fascia and interdigitates with the distal portion of the levator aponeurosis to the ciliary margin.⁶⁻⁸ As both the inner and outer layers of the septum fuse at the distal levator aponeurosis anterosuperior to the tarsal plate, thick septal tissue

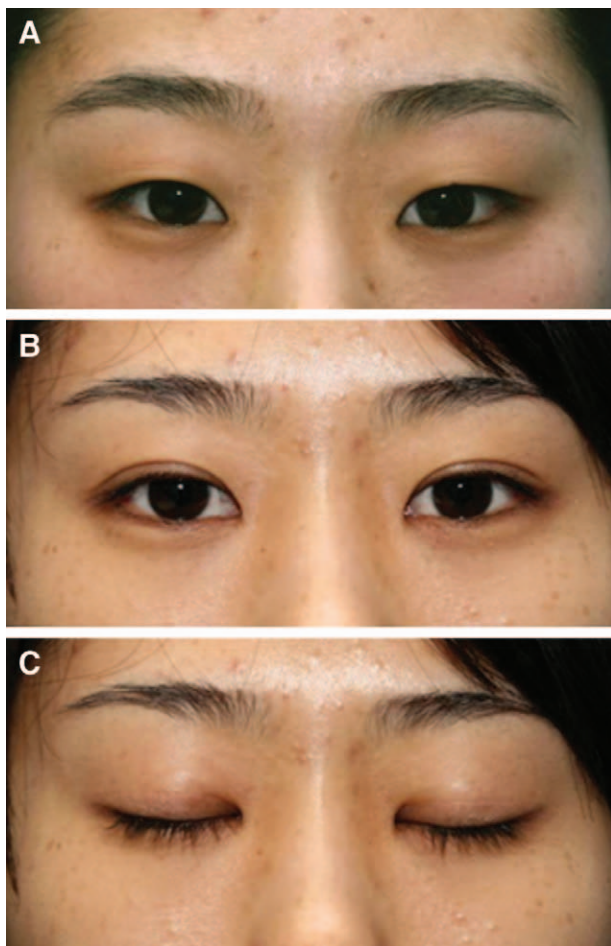
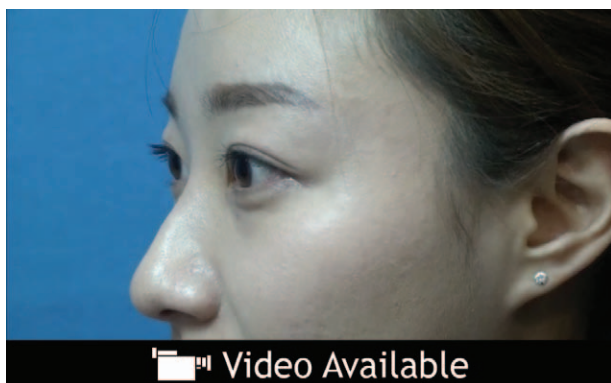

Fig. 2. A 24-y-old woman who underwent the incisional double-eyelid surgery technique (A). Two years postoperatively, the patient is exhibiting a dynamic fold, which is characterized by moderate depth of the fold with eyes open (B) and a minimally depressed scar along the incision line with eyes closed (C) with a mobile fold line.



Video Graphic 2. See video, Supplemental Digital Content 2, which shows the front and quarter views of the same patient exhibiting a dynamic fold after she received double eyelid surgery using septoaponeurosis junctional thickening fixation as she opens and closes her eyes, <http://links.lww.com/PRSGO/A1>.

exists in this region (Fig. 3). This portion of the septum was named the SAJT.

Operative Method

Between January 2004 and February 2010, 680 patients without blepharoptosis were treated with the incisional method using SAJT fixation (586 women and 94 men; mean age, 31.5 y). Four hundred eighty-eight female and 52 male patients simultaneously underwent epicanthoplasty.

Design

Preoperative design was performed with the patient in the upright position and facing forward. The optimal central height (Fig. 4A) was marked at a point of midpupillary line as the surgeon manually elevated the eyebrow. This point was determined by observing fold height that was aesthetically appropriate for the patient. The extent of skin excision was determined by releasing the elevated eyebrow from the first marked point (Fig. 4B).

The medial height was determined by gently tapering from the central height to the medial canthus (Fig. 4C). From the central marked point A to point D at the same height above the lateral canthal angle, the lower line was drawn parallel to the curvilinear shape of the eyes. At this point, the lateral line extended parallel to the lateral canthus slant to the lateral raphe (Fig. 4E). The upper incision line was drawn by gently connecting the epicanthus (Fig. 4C) to point B and tapering from point B to the lateral endpoint E (Fig. 4).

Incision and Dissection (Exposure of SAJT)

Operations were performed under local anesthesia with or without intravenous anesthesia. A no. 15 scalpel blade was used to make incisions. The lower incision line was cut beveled cephalad to increase the dermis exposure of the lower flap. The upper incision line was made using the blade angled perpendicular to the skin surface to facilitate clean excision of the orbicularis muscle. From the upper incision line, electrocautery was used to cut the orbicularis muscle and to expose the septum. The strip of skin and orbicularis oculi muscle between two incision lines was excised using sharp curved scissors. Again from the upper incision line, the upper myocutaneous flap was elevated just superficial to the septum at a distance of 5 mm cephalad. The exposed septum was transversely opened using scissors 7 mm superior to the lower incision line from lateral to medial direction. The inferior transverse ligament was then cut to prevent hindrance of levator aponeurosis movement (Fig. 5).

The preaponeurotic fat and the levator aponeurosis were sufficiently dissected from each other. Im-

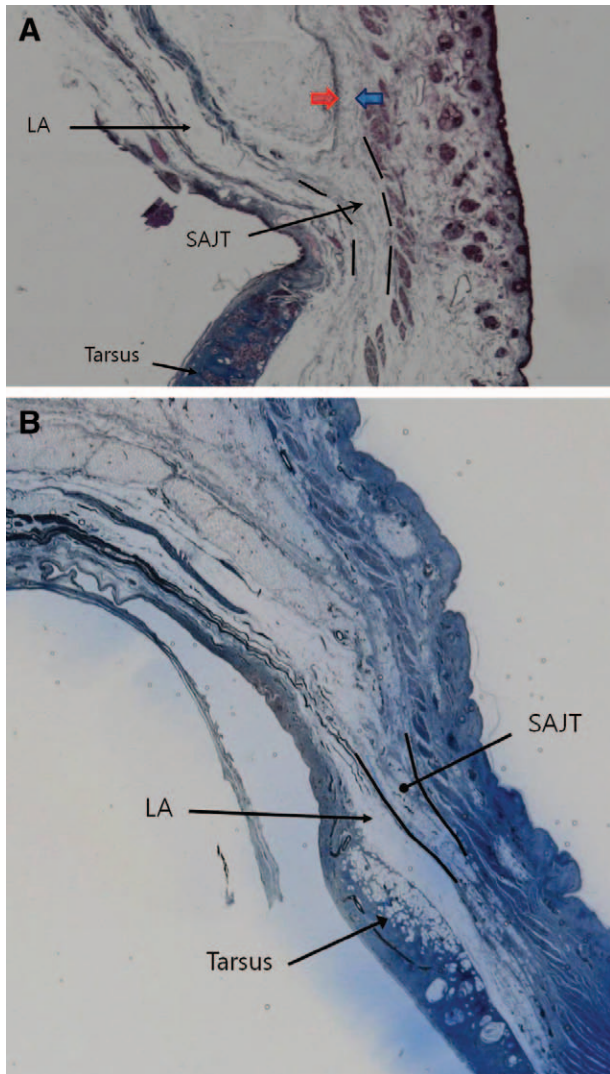


Fig. 3. Histology showing the SAJT, the inner layer (red arrow) and outer layer (blue arrow) of the septum, levator aponeurosis (LA) and the tarsus (A). The SAJT lies in between the outer layers of the orbital septum and the LA (B).

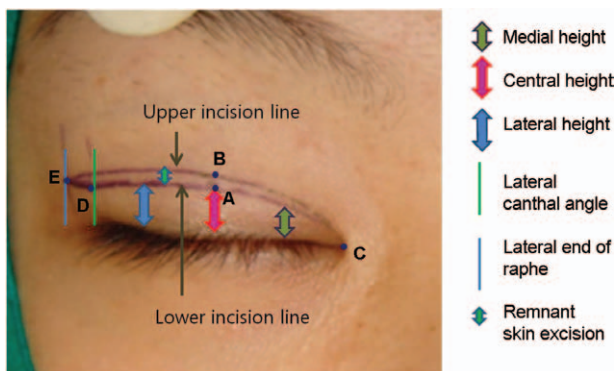


Fig. 4. Preoperative designing of the lower and upper incision lines: Central height (A), extent of skin excision (B), medial canthus (C), lateral height (D), and lateral raphe (E).

mediately superior to the lower flap is the redundant septal stump and orbicularis oculi muscle. A strip of the orbicularis oculi muscle was excised carefully to not damage the levator aponeurosis. In this region, septal layers can be noted. The inner layer (Fig. 3, red arrow) of the remaining septal stump is connected to the levator aponeurosis. The outer layer (Fig. 3, blue arrow) extends inferiorly to the tarsus. The redundant septal stump was carefully trimmed until the thickened septal tissue, SAJT, was uncovered (Fig. 6A). SAJT is firm and elastic, and is tightly attached to the levator aponeurosis. Redundant preaponeurotic fat was removed, and the remaining fat was anchored at the upper septal stump using 7-0 white nylon mattress sutures at 1–2 sites to prevent preaponeurotic fat ptosis.

SAJT Fixation to Lower Flap

The dermis and superficial layer of the orbicularis muscle of the lower flap were sutured to the SAJT 6–8 points at a uniform distance using 7-0 white nylon. In the traditional tarsal fixation method, the lower flap is sutured to the tarsus at only 3–4 points because the tarsus is a hard structure compared with the SAJT. Because the SAJT is a soft structure, fixation requires more suture sites for even distribution of tension of the lower flap (Fig. 7B).

Skin Suture and Postoperative Care

Skin closure was performed using 8-0 black nylon in a continuous running fashion. Skin tape was placed just above the incision to reduce swelling and to prevent formation of triple folds.

Degree of the Depression Measurement

Side-view pictures of the patients' eyes were taken at 3, 9, and 12 weeks postoperatively. All pictures were taken at equal distance in the same setting. The resolution of the pictures was 2544 × 1696 pixels, and the pictures were viewed at full scale on a monitor with resolution of 1920 × 1200 pixels. A line connecting the most convex surface of the upper flap to the most convex surface of the lower flap was drawn. The distance from the line connecting the convex surfaces to the depressed point was measured using the vernier caliper.

RESULTS

The skin sutures were removed 5 days after the operation. The evaluation criteria were based on fold size, scar depression, and patient satisfaction. The first measurement was taken 5–7 days after the surgery when the skin sutures were taken out. Consecutive measurements were taken at 3, 6, and 9 weeks and at 1, 2, 4, and 8 years postoperatively. The follow-up period ranged from 2 to 8 years (mean, 3.6 y).

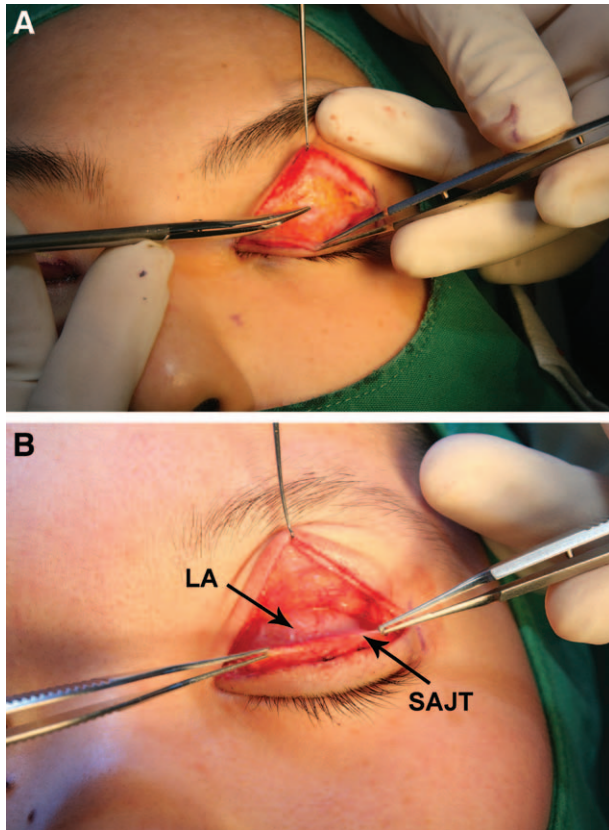


Fig. 5. (A) The septum was transversely incised at 7 mm above the skin incision site using scissors from lateral to medial direction. (B) Complete incision of the septum is required to prevent hindrance of LA movement while uncovering the SAJT.

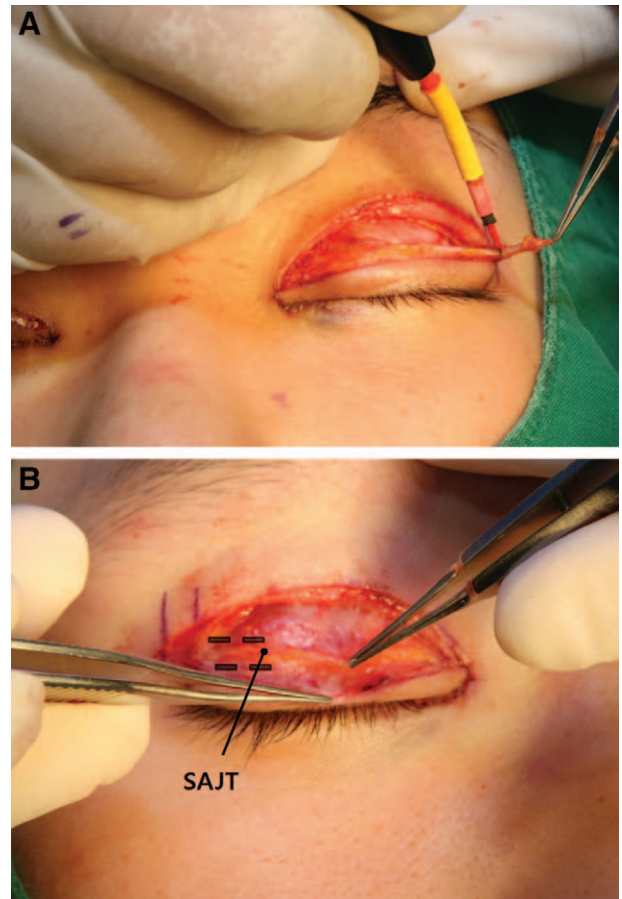


Fig. 6. (A) The lower stump of the septum was trimmed before suture fixation. (B) The remnant of the septum was pulled and examined to determine whether the SAJT was adequately trimmed.

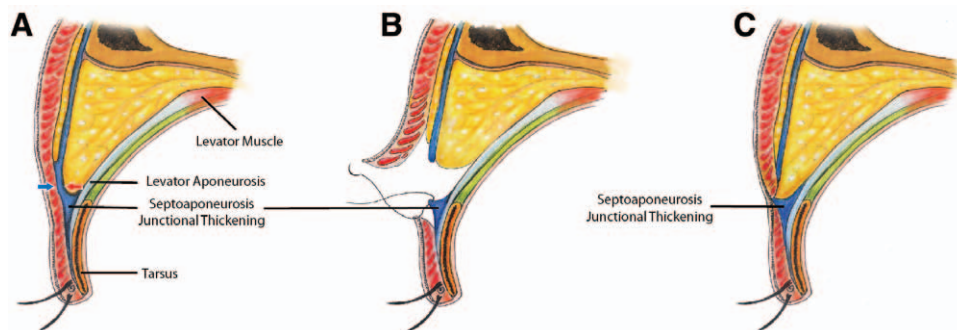


Fig. 7. Diagram showing the suture fixation of the dermis and SAJT. (A) The SAJT defines the thickened septal tissue between the inner (red arrow) and outer layers (blue arrow) of the orbital septum immediately cephalad to the tarsus and anterior to the LA. (B) Once the SAJT was uncovered and trimmed, the dermis of the lower flap was fixated to the SAJT at 6–8 sites. (C) The skin closure was performed with 8-0 black nylon in a continuous running fashion.

The Change in Size of the Double-Eyelid Fold

The size of the double-eyelid fold was determined by measuring the visible fold with the patient in the upright position, facing forward with eyes open. The first measurement was taken immediately after skin

sutures were removed, and following measurements were taken at 3, 5, 9, and 12 weeks and at 2 and 4 years postoperatively. Edema and swelling were observed 5–7 days after surgery. At 3 and 12 weeks postoperatively, edema and swelling were reduced, and the mean

Table 1. Fold Height Measurements Taken After 5–7 Days, 3, 9, and 12 Weeks, and 4 Years Postoperatively ($n = 630$)

Patients	5–7 d, mm	3 wk, mm (%)*	9 wk, mm (%)	12 wk, mm (%)	~4 y, mm (%)
1	5.2	4.1 (79)	3.9 (75)	3.7 (71)	3.7 (72)
2	8.8	7.5 (85)	5.9 (67)	5.7 (65)	5.6 (64)
3	6.6	5.5 (83)	5.5 (83)	5.2 (79)	5.3 (80)
4	7.9	6.2 (78)	5.9 (75)	5.6 (71)	5.5 (70)
5	6.1	4.8 (79)	4.5 (74)	4.2 (69)	4.2 (69)
Mean (%)		81	74.8	71	71
± SD (%)		3.43	4.35	4.21	4.60

*The percentage change in fold height is based relative to the first measurement taken on 5–7 d postoperatively. Mean percentage of the change in the fold height.

Table 2. Measurement of Depression of the Fold Line ($n = 630$)

Patients	5–7 d, mm	3 wk, mm (%)*	9 wk, mm (%)	12 wk, mm (%)	~4 y, mm (%)
1	2.8	1.9 (68)	1.3 (46)	0.5 (18)	0.5 (18)
2	2.5	1.2 (48)	1.1 (44)	0.5 (20)	0.5 (20)
3	3.7	2.3 (62)	1.7 (46)	0.6 (16)	0.5 (14)
4	3.9	2.6 (67)	1.8 (46)	0.7 (18)	0.6 (15)
5	2.9	1.7 (59)	1.2 (41)	0.8 (28)	0.7 (24)
Mean (%)	3.13	1.79 (57)	1.33 (43)	0.54 (18)	0.51 (17)
± SD, mm (%)	0.53	0.45 (9.86)	0.24 (4.87)	0.14 (5.79)	0.11 (5.47)

*The percentage change in the depression of the fold line is based relative to the first measurement taken on 5–7 d postoperatively. Mean percentage of the change in the depression of the fold line.

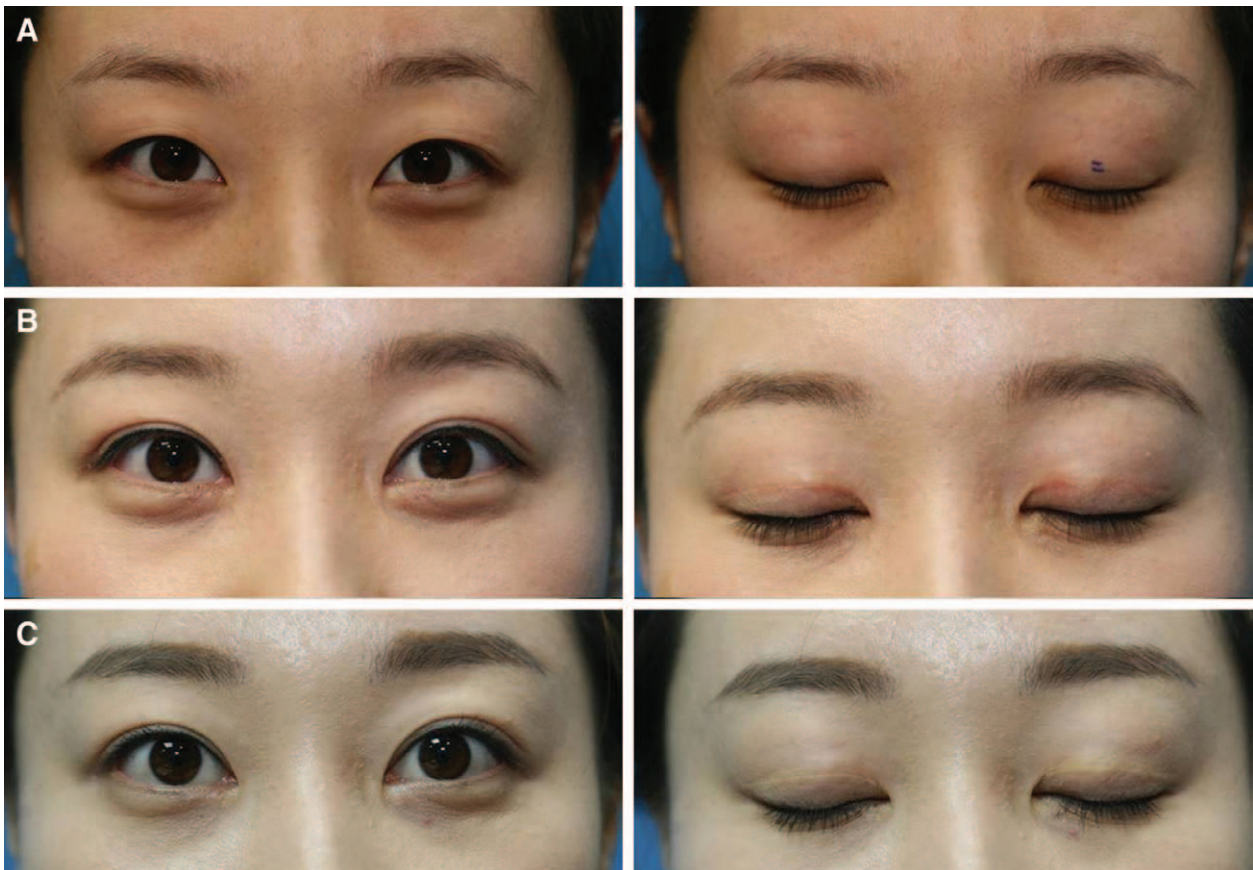


Fig. 8. Preoperative view of a 28-y-old woman with redundant and puffy upper eyelids with eyes open (left column) and with eyes closed (right column) (A). The patient underwent incisional double-eyelid surgery using SAJT fixation and epic-anthoplasty. One-month (B) and 4-y (C) postoperative views with eyes open (left column) and eyes closed (right column).

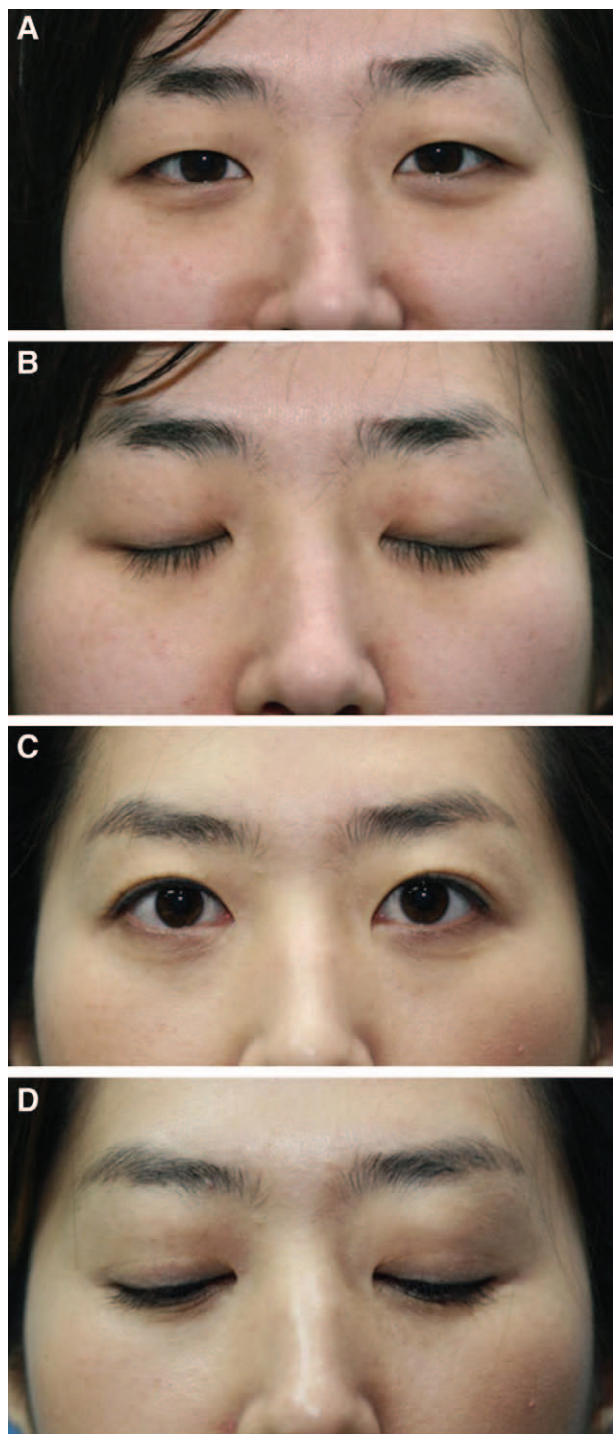


Fig. 9. Preoperative view of a 22-y-old woman with redundant and puffy upper eyelids with eyes open (A) and with eyes closed (B). Three-year postoperative view with eyes open (C) and with eyes closed (D).

change in fold height at 3 weeks was 81% and at 12 weeks was 71% (Table 1). No further changes in fold height were observed after 12 weeks in most patients.

Depression of the Fold Line

The degree of double-eyelid fold depression was measured at the same follow-up periods mentioned above (Table 2). Generally, the patients exhibited a slight depression of the fold line 3 weeks after surgery, but the depression gradually faded at 6, 9, and 12 weeks postoperatively. The average percentage change in the depression of the fold line at 3 weeks and 12 weeks postoperatively were 57% and 17%, respectively. A faint depression was observed after 12 weeks in most patients. Two to 4 years of follow-up revealed that the patients exhibited equal tension distributions at the lower and upper flaps and minimal depressed scars (Figs. 8 and 9).

Patient Satisfaction

At 2-year follow-up, patients were asked to rate their satisfaction with their surgery from 1 to 5, with 1 being very unsatisfied to 5 being very satisfied. Ninety-five percent of the patients responded that they were satisfied with their surgery, with 365 (57.7%) patients responded as satisfied with a score of 4, and 236 (37.3%) patients responded as very satisfied with a score of 5 (Table 3).

Complications

Postoperative complications included partial or complete loss of the double-eyelid line in 14 and 4 cases, hypertrophic scar formation in 7 cases, and asymmetric fold in 8 cases (Table 4).

Partial or complete loss of the crease line occurred when adequate tension was not maintained at the lower flap during the fixation step. If fixation of the lower flap to the SAJT is weak, then the fold loosens. To restore the loosened crease line, the partial or full incisions at the crease line were remade, and new fixation sutures were placed on the SAJT with more tension. This was accomplished by shortening the SAJT and confirming with increased eyelash eversion.

Stitch abscess formation was mostly observed in patients with thin skin. Stitch abscess was treated by transversely cutting about 2 mm using a no. 11 scalpel blade and removing the knot.

Hypertrophic scar formation was mostly observed at the medial quarter of the upper eyelid incision in

Table 3. Patient Satisfaction With the Surgery (*n* = 633)*

Satisfaction Score	Very Unsatisfied (1)	Unsatisfied (2)	Neutral (3)	Satisfied (4)	Very Satisfied (5)
<i>N</i> (%)	0	14 (2.2)	18 (2.8)	365 (57.7)	236 (37.3)

*47 patients were lost to 2-y follow-up.

Table 4. SAJT Fixation Postoperative Complications (n = 680)

Complications	% (Cases)
No complications	95.5 (649)
Partial loss of the fold	2.0 (14)
Complete loss of the fold	0.3 (2)
Hypertrophic scar formation	1.0 (7)
Asymmetric fold*	1.2 (8)
Total	4.5 (31)

*Asymmetry of >1 mm that required surgical correction.

patients who simultaneously underwent epicanthoplasty. These patients were treated with intralesional triamcinolone injections.

DISCUSSION

A congenital supratarsal fold begins at the epicanthus with moderate fold depth that is not overly depressed. Natural double-eyelid fold occurs when the levator aponeurosis inserts into the intramuscular septum⁹ or the subcutaneous tissue.¹⁰ Furthermore, congenital supratarsal fold depth changes with eyelid movement. The fold appears flat with the eyes closed and occurs with eyes open.

One of the early descriptions of incisional double-eyelid surgery involves excision of pretarsal orbicularis muscle and fixing the dermis of the lower skin flap to the tarsus.^{1,11} This technique is simple to perform and creates durable but static folds. A static fold is characterized by depressed scars, deep depth of the fold, stretched eyelid lower flap, and immobile fold line with the surrounding tissues. In addition, the lower flap appears excessively full due to the deep fold line created by tarsodermal fixation. The depth discrepancy between the skin and the tarsus creates the appearance of fullness in tarsal fixation (Fig. 1). Overall, the static fold looks unnatural and not desirable.

To create a less-static double-eyelid fold, dermis to levator aponeurosis fixation has been advocated by Fernandez.¹² However, a direct dermal fixation to levator aponeurosis still creates a deep and excessively strong-appearing fold due to depth discrepancy between the skin and the levator aponeurosis. Soft tissue of Asian eyelids tends to be thick because of thick orbicularis muscle and preaponeurotic fat. Therefore, a direct fixation of dermis to levator aponeurosis creates a deeply pinched and high fold. On average, the distance from eyelash to fold most commonly performed in Asians is 6–10 mm. If the fold is designed below the level of the surgically exposed levator aponeurosis, the lower flap has to accommodate the higher (cephalic) position of the levator aponeurosis. This can lead to permanent eyelash eversion and/or eyelid retraction. Furthermore, excessively

high folds may occur from skin being stretched to the attached levator aponeurosis. In contrast, our technique fixates the dermis of the upper lid onto the SAJT located superficial to aponeurosis. This results in a double-eyelid fold that is not deep or does not stretch the lower flap.

Lee et al devised a septodermal fixation technique that created a less-depressed double-eyelid fold.¹³ The orbital septum was not opened, and septum was attached to the dermis of the lower edge of the pretarsal skin incision. Flowers described a similar “septoaponeurotic vehicle” procedure where anterior septum was incised, rotated, and fixed to the eyelid skin.¹⁴ However, both of these techniques often resulted in loosening of the fold.¹⁴ The fold loosened because the redundant septum had too much slack, and the adequate amount of force from the levator aponeurosis was not transmitted to the lower flap of the eyelid. However, our technique fixates onto the firm SAJT that is connected to the distal levator aponeurosis. Because the SAJT is not a redundant structure, it creates a long-lasting double-eyelid fold.

The orbital septum is a multilayered structure that encloses preaponeurotic fat. The orbital septum begins at the arcus marginalis along the orbital rim and is continuous with other layers on the forehead and within the orbit. The inner layer of the septum is formed by the periosteum from the forehead, whereas the outer layer is formed by the deep galea. These fibrous layers fuse to the arcus marginalis and continue caudally as the inner and outer layers of the septum.^{6–8} Within the orbit, the inner layer of the septum joins with the levator aponeurosis at 2–5 mm above the tarsal plate, and the outer layer extends inferiorly down and over the tarsal surface.^{7,16} A thickened, dense septal tissue lies in between the inner and outer layers of the caudal orbital septum. We describe this structure as the SAJT (Fig. 3).

Although the SAJT, septal extension, and conjoined fascia may appear as similar structures, and they all originate from the septum, there are differences in the region described and the density of the septal tissue. The term “SAJT” describes the proximal end of the septal extension and conjoined fascia. In Asians, this region of the septal tissue is thickened. It is also the area where the outer and inner layers of the septum join. The terms “septal extension” and “conjoined fascia” describe septal tissue that extends distally from SAJT. The conjoined fascia was described by Segal as a “layer of fascia located between the eyelid fold and the eyelashes ... fusion of the levator aponeurosis and orbicularis fascia.”⁹ Reid et al describes septal extension as a “distinct fibrous anatomical layer which extends from the orbital septum to cover the tarsus.”¹⁷

Unlike the cephalic septoaponeurosis junction, in the most caudal region, there is a firm attachment between the SAJT and the levator aponeurosis. Clinically, one can peel away the septum from the levator aponeurosis. However, in the most distal region where the SAJT is present, the septoaponeurosis connection is firm (Fig. 7C). When the SAJT is used as a fixation structure in double-eyelid surgery, it effectively transmits the pulling power of the levator palpebrae muscle to create the supratarsal fold.

The SAJT functions as a fibrous connection to mimic the congenital crease fold. When the eyes are closed, the thickness of the SAJT allows the fold to remain superficial and smooth (not depressed). When the eyes are open, the firm component of the stretched SAJT creates a well-defined yet not overly depressed fold. This creates a natural-appearing fold line with eyes closed and open (Figs. 2, 8 and 9).

To expose the SAJT, the septum is cut transversely 3–5 mm above the SAJT. If the incision is placed at a lower position, the SAJT can be cut. Cutting the SAJT reduces the amount of structure required to anchor the fixation. In such cases, the hinge effect of the SAJT is lost, and the dermis is attached to the levator aponeurosis. This can lead to excessive eyelash eversion. Therefore, the septum must be opened at a sufficiently high position to preserve the SAJT.

One of our technical complications worth noting was partial fold loosening (14 cases). If the septum is not completely opened (separating the septum from the SAJT), then the SAJT cannot move freely in conjunction with levator movement. In this case, the hindered SAJT (still connected to portion of the surrounding septum) prevents well-defined fold invagination. This could induce loosening of the double-eyelid fold or insufficient depth of the crease.

Follow-up revealed the fold line was retained in the patients without further changes in the size, depth, and shape 3 months postoperatively. The incision line appeared smooth and faint with eyes closed, and the fold occurred with adequate depth with the eyes open (dynamic fold).

CONCLUSION

The double-eyelid surgery using SAJT fixation requires meticulous dissection and has a longer operative time compared with the classic technique using tarsus fixation, septal fixation, or levator fixation. However, SAJT fixation provides the following advantages: 1) the eyelid appears smooth without fold depression on downward gaze or eyes closed; 2) absence of depressed scar formation on the fold line; 3) gentle and not overly invaginated fold with the opening of eyes; and 4) similar skin tension at the upper and lower flaps. Using SAJT fixation cre-

ates the dynamic double-eyelid folds that mimic the movement of congenital folds.

Using the SAJT fixation technique can create a dynamic and long-lasting double eyelid in Asian patients with puffy eyelids or eyelids with excess skin.

PATIENT CONSENT

Patients provided written consent for the use of their images.

Hong Seok Kim
Lotte Clinic Building
3rd Floor, 784 Janghang-dong
Ilsangu, Goyangcity
Kyung-gi-do, South Korea
E-mail: ohkims743@naver.com

REFERENCES

1. Chen W PD. *Asian Blepharoplasty and the Eyelid Crease*. 2nd ed. New York, NY: Elsevier; 2006.
2. McCurdy JA. *Cosmetic Surgery of the Asian Face*. New York, NY: Thieme Medical Publishers; 1990.
3. Kikkawa DO, Kim JW. Asian blepharoplasty. *Int Ophthalmol Clin*. 1997;37:193–204.
4. Chen W PD. In: Putterman AM, ed. *Cosmetic Oculoplastic Surgery*. Philadelphia, PA: WB Saunders; 1999:101–111.
5. Jeong S, Lemke BN, Dortzbach RK, et al. The Asian upper eyelid: an anatomical study with comparison to the Caucasian eyelid. *Arch Ophthalmol*. 1999;117:907–912.
6. Hwang K, Huan F, Kim DJ. Levator sheath revisited. *J Craniofac Surg*. 2012;23:1476–1478.
7. Hwang K, Kim DJ, Chung RS, et al. An anatomical study of the junction of the orbital septum and the levator aponeurosis in Orientals. *Br J Plast Surg*. 1998;51:594–598.
8. Whitnall SE. *Anatomy of the Human Orbit and Accessory Organs of Vision*. 2nd ed. London: Oxford University Press; 1932:140–148.
9. Siegel R. Surgical anatomy of the upper eyelid fascia. *Ann Plast Surg*. 1984;13:263–273.
10. Collin JR, Beard C, Wood I. Experimental and clinical data on the insertion of the levator palpebrae superioris muscle. *Am J Ophthalmol*. 1978;85:792–801.
11. Stasior GO, Lemke BN, Wallow IH, et al. Levator aponeurosis elastic fiber network. *Ophthalm Plast Reconstr Surg*. 1993;9:1–10.
12. Fernandez LR. Double eyelid operation in the Oriental in Hawaii. *Plast Reconstr Surg Transplant Bull*. 1960;25:257–264.
13. Lee JS, Park WJ, Shin MS, et al. Simplified anatomic method of double-eyelid operation: septodermal fixation technique. *Plast Reconstr Surg*. 1997;100:170–8; discussion 179.
14. Flowers RS. In: *Transactions of the 6th International Congress of Plastic and Reconstructive Surgery*. Paris, France: Masson; 1975.
15. Flowers, RS. Simplified anatomic method of double-eyelid operation: septodermal fixation technique. *Plast Reconstr Surg*. 1997;100:179–181.
16. Meyer DR, Linberg JV, Wobig JL, et al. Anatomy of the orbital septum and associated eyelid connective tissues. Implications for ptosis surgery. *Ophthalm Plast Reconstr Surg*. 1991;7:104–113.
17. Reid RR, Said HK, Yu M, et al. Revisiting upper eyelid anatomy: introduction of the septal extension. *Plast Reconstr Surg*. 2006;117:65–6; discussion 71.