

# Anatomic Pectoralis Major Repair With Intramedullary Anchor Fixation



Joshua W. Sy, CPT, D.O., Zackary A. Johnson, CPT, M.D., and Kyong S. Min, MAJ, M.D.

**Abstract:** Although previously described as a rare injury, pectoralis major tendon rupture has shown increased reports in recent years. This injury can be managed conservatively; however, given the propensity for young, physically active male individuals, surgical repair is often preferred. Definitive surgical repair can be performed through various techniques such as bone trough, transosseous fixation, suture anchor, and cortical button techniques. This technique guide describes surgical repair through intramedullary anchor fixation with a unique pull-through method using taped suture to secure the tendon repair to its anatomic footprint. We believe this method is biomechanically advantageous, reduces bone loss that may lead to postoperative fractures, and re-creates the anatomic footprint of the torn tendon.

Rupture of the pectoralis major tendon has been previously described as a rare injury; however, recent literature has reported an increasing number of cases.<sup>1-4</sup> Given the susceptibility of young, physically active male individuals to this injury, surgical repair is often preferred over conservative management and has shown favorable (i.e., good or excellent) results in 88% versus 27% of patients.<sup>5</sup> More specifically, active populations such as the military have been studied, and after operative repair, 94% of patients have returned to full duty.<sup>6</sup>

Several repair techniques have been described including bone trough, transosseous fixation, suture anchor, and cortical button techniques; all have reported high rates of success.<sup>7-10</sup> The bone trough technique docks the pectoralis tendon within the humeral canal and provides excellent fixation; however, this technique requires a large cortical defect within the proximal humerus. The transosseous

fixation technique requires multiple unicortical tunnels; this method is technically difficult and requires multiple drill tunnels, which increases the number of stress risers. As a result, many orthopaedic surgeons have adopted suture anchor or cortical buttons for pectoralis major repair.

Given the ease of use and ability to anatomically re-create the footprint of the pectoralis major, a pull-through intramedullary anchor technique using taped suture is described in this report. This technique offers repair of the pectoralis tendon to its anatomic footprint with strong fixation and a unique suture configuration while having the advantage of a smaller-profile, 2.9-mm drill.

## Surgical Technique

**Video 1** shows the entire surgical technique. The patient is placed in the beach-chair position, and the standard deltopectoral surgical approach is used for exposure. The ruptured heads of the pectoralis are often retracted medially, and the tendon involutes into the muscle belly. Release of scar tissue surrounding the tendon and muscle belly is necessary to gain the desired excursion. Care must be taken to avoid extensive deep dissection under the muscle belly; aggressive dissection can injure the medial and lateral pectoral nerves. The pectoralis major has been classically described as having 2 heads, the clavicular head and the sternocostal head; however, at times, a distinction can be made between the sternal and costal heads. In these situations, they can be carefully dissected, mobilized, and grasped separately. Once the various heads of the pectoralis major tendon are identified and exposed, the proximal

From the Department of Orthopaedics, Tripler Army Medical Center, Tripler AMC, Hawaii, U.S.A

The authors report no conflicts of interest in the authorship and publication of this article. Full ICMJE author disclosure forms are available for this article online, as [supplementary material](#).

Received December 5, 2019; accepted February 28, 2020.

Address correspondence to Joshua W. Sy, CPT, D.O., Department of Orthopaedics, Tripler Army Medical Center, Tripler Orthopaedics 4F, One Jarret White Road, Tripler AMC, HI 96859, U.S.A. E-mail: [Joshua.w.sy.mil@mail.mil](mailto:Joshua.w.sy.mil@mail.mil)

Published by Elsevier on behalf of the Arthroscopy Association of North America. This is an open access article under the CC BY-NC-ND license (<http://creativecommons.org/licenses/by-nc-nd/4.0/>).

2212-6287/191502

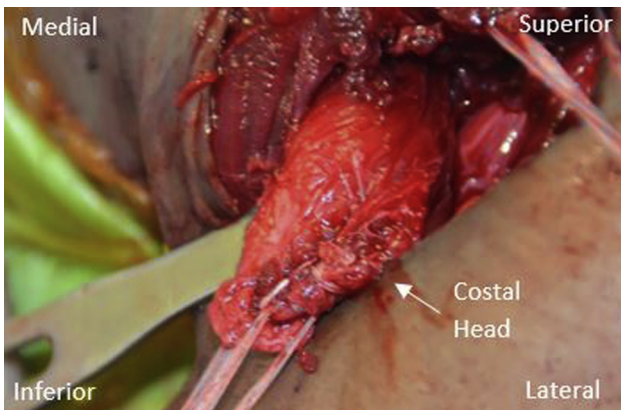
<https://doi.org/10.1016/j.eats.2020.02.023>

and distal borders of each head are captured with locking Krackow stitches using a robust taped suture (Figs 1 and 2). One limb from each of these taped sutures will be loaded into an anchor.

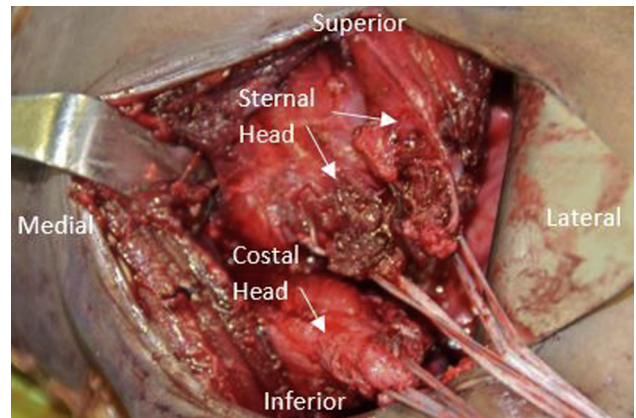
Quite often, the clavicular head is intact and only the sternal and costal heads are ruptured. When the clavicular head is intact, this can be used to help identify the pectoralis major footprint; the clavicular head is the distal-most insertion of the pectoralis major tendon. If all portions of the tendon are ruptured, the insertion of the latissimus dorsi can help identify the footprint. The pectoralis major tendon inserts along the lateral border of the bicipital groove, and the distal footprint ends at the superior insertion of the latissimus dorsi. The average dimensions of the footprint are 73 mm in length and 3 mm in width.<sup>11</sup> Once the footprint is defined, it is decorticated and prepared with a rasp.

With the footprint is exposed and prepared, unicortical drill holes are made at 1.0- to 1.5-cm intervals using a 2.9-mm drill (Fig 3). For this technique, we use a double-loaded, unicortical, intramedullary, bio-composite anchor (Lupine; Mitek) for fixation. We prefer this anchor for its ease of insertion, small drill hole (2.9 mm), and biocomposite composition. To help with suture management and visualization, the tendon is repaired from distal to proximal.

A pull-through technique is used to load each taped suture into the intramedullary anchor. Starting with the inferior-most taped suture, a free needle is used to thread the taped suture through the center of 1 suture from the intramedullary anchor (Fig 4). The suture is then pulled through the anchor, which loads the taped suture into the anchor. This limb of the taped suture will serve as the post. By pulling on this post, the taped suture will slide through the anchor and



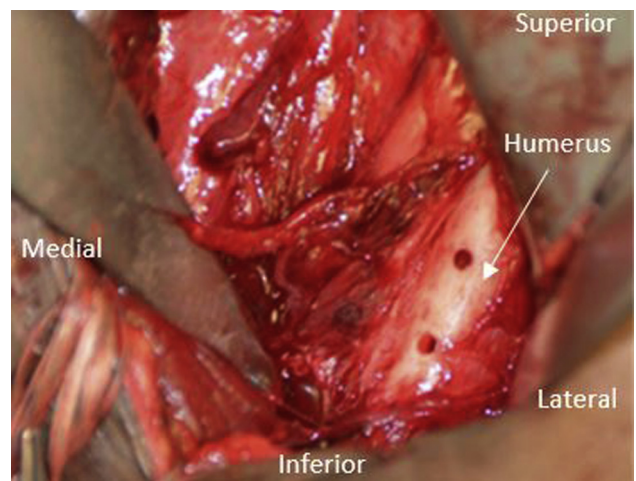
**Fig 1.** Left shoulder in beach chair position with two Krackow stitches shown on the costal head of the pectoralis major through the standard deltopectoral incision. One stitch is placed on the superior aspect of the head, and one stitch is placed on the inferior aspect; these will be used for repair onto the humerus.



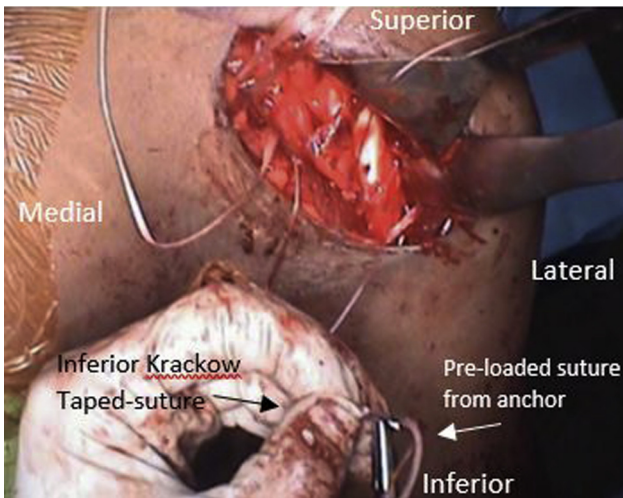
**Fig 2.** Left shoulder in beach chair position with both the sternal and costal heads shown through the standard deltopectoral incision with Krackow stitches individually on the superior and inferior aspects of each head, for a total of 4 stitches. These will be incorporated with suture anchors for fixation onto the humerus.

bring the torn tendon directly down to bone. While tension is maintained on the post, the other end of the taped suture is tied over the post and secures the repair (Fig 5).

If additional fixation is necessary, the second suture from the intramedullary anchor can be used for backup fixation. This pull-through technique is repeated until all the taped sutures are secured (Figs 6 and 7). The final repair shows the pectoralis major muscle belly anatomically reduced with its attachment onto the humerus (Fig 8). Table 1 presents advantages and disadvantages of the described technique, and Table 2 shows pearls and pitfalls.

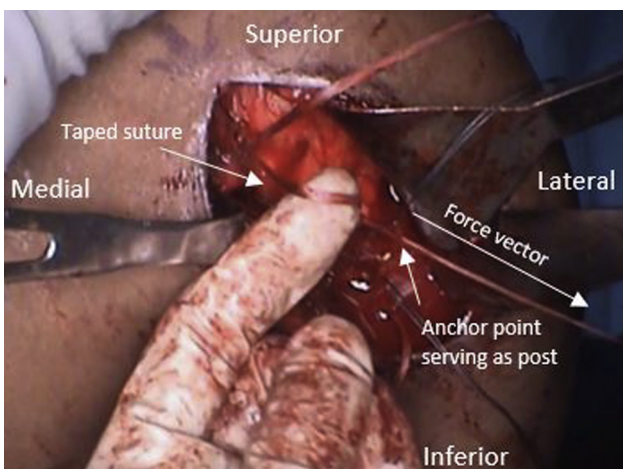


**Fig 3.** Left shoulder in beach chair position with two proximal suture anchor holes shown on the humerus, with the third distal (inferior) hole filled with a suture anchor. These are the fixation points on the humerus for tendon reduction to its native footprint.

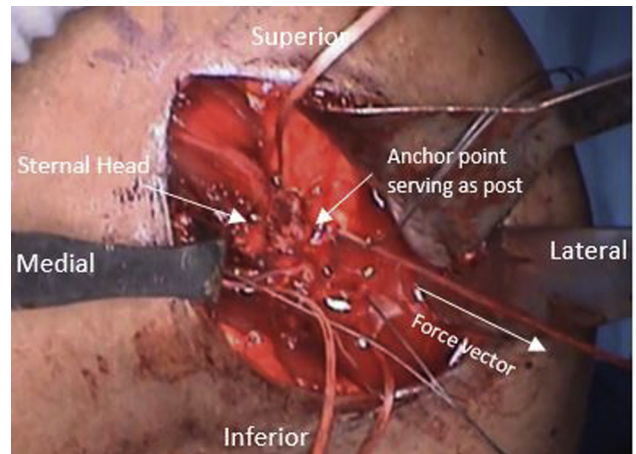


**Fig 4.** Left shoulder in beach chair position with inferior taped-suture Krackow stitch on the costal head being threaded with the preloaded suture on the anchor by the pull-through technique.

Postoperatively, patients wear a sling for the first 4 weeks. Pendulum exercises are initiated immediately, and painless passive range of motion starts 2 weeks after surgery. Painless active-assisted range of motion starts 4 weeks after surgery, and active range of motion starts 6 weeks after surgery. For the first 6 weeks, external rotation is limited to 30°. Strengthening ensues 12 weeks after surgery. Return to sport is allowed once adequate active and passive range of motion for sport, as well as strength greater than 90% compared with the nonoperative shoulder, is achieved.



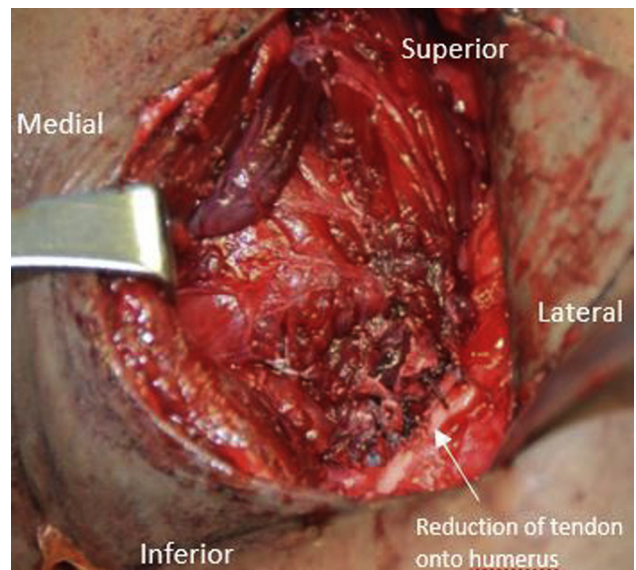
**Fig 5.** Left shoulder in beach chair position with the taped suture from the tendon, shown on the gloved index finger, that has been threaded with the preloaded suture from the anchor being pulled through the anchor, which serves as a post for reduction in a pulley maneuver. The force vector, marked with the arrow pointing laterally, shows the direction of the reduction of the pectoralis tendon onto the humerus.



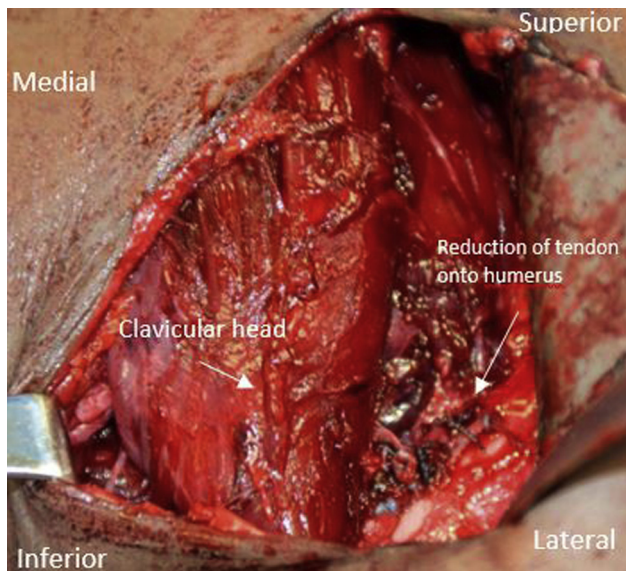
**Fig 6.** Left shoulder in beach chair position with the sternal head tendon reduced onto the humerus at the anchor point after the pull-through technique is performed. Tension is maintained on the post suture in the direction of the force vector prior to being tied down.

## Discussion

Suture anchors are just one of the techniques used to repair pectoralis major ruptures that have shown excellent results. Mooers et al.<sup>12</sup> studied 20 ruptures repaired with various suture anchors and showed good or excellent results in 66% and fair results in 33%. Sherman et al.<sup>13</sup> studied the biomechanics of suture anchor repair, transosseous suture fixation, and cortical button repair and found no difference between fixation devices regarding load to failure or cyclic loading.



**Fig 7.** Left shoulder in beach chair position with finished repair of pectoralis major with clavicular head retracted medially. The sternal head is visualized anatomically reduced onto the humerus with sutures in view.



**Fig 8.** Left shoulder in beach chair position with completed pectoralis major repair with anatomic reduction of torn tendon onto humerus laterally with clavicular head overlying repair.

Most patients with pectoralis ruptures sustain the injury while bench pressing.<sup>14</sup> These high-level athletes place large amounts of torsional force on their humeral diaphysis. There is a concern that large cortical defects in the diaphyseal bone may result in proximal humeral fractures from stress risers. Proximal humeral shaft fractures may occur at the site of bone troughs and cortical drill holes after a pectoralis tendon rupture repair.<sup>15</sup> Wilson et al.<sup>16</sup> performed a biomechanical study testing the effects of cortical defects on the humeral diaphysis. Their study compared the effect of a 5-mm × 40-mm bone trough, two 7-mm × 15-mm biocomposite interference screws, and three 2.9-mm unicortical suture anchors. Failure occurred from the rotational force producing a spiral fracture through unicortical stress risers in all cases. The bone trough group failed after fewer cycles and under lower forces; these differences were statistically

**Table 1.** Advantages and Disadvantages

**Advantages**

- Suture anchors create smaller cortical defects compared with traditional bone tunnels and possibly have a lower risk of postoperative fracture.
- More fixation points can be placed to match the broad anatomic tendon footprint.
- Biomechanically superior strength is achieved with a taped suture and a running locking configuration.
- A biocomposite anchor resorbs over time and potentially would not need to be removed in cases of infections.

**Disadvantages**

- Potential cost of anchor implants over traditional bone troughs.
- Learning curve for placement of anchors.

**Table 2.** Pearls and Pitfalls

**Pearls**

- Distinguishing and dissecting out the individual sternal and costal heads of the pectoralis major may help achieve anatomic reduction to match the broad tendon insertion.
- Proper exposure of the humerus and placement of anchors 1.0-1.5 mm apart ensure more anatomic re-creation of the insertional footprint.

**Pitfalls**

- Inadequate maintenance of tension after the pull-through technique prior to tying down the suture may cause laxity in reduction of the tendon onto the humerus.
- Improper drill placement for suture anchors may cause the anchors to be too close together and potentially weaken bony fixation and increase anchor pullout risk.

significant. In addition, the unicortical suture anchors were the most resistant to fracture.<sup>16</sup>

When repairing the pectoralis major, we believe it is important to re-create the anatomic pectoralis major footprint. The clavicular head commonly remains intact; therefore, it helps to define the distal-most insertion of the tendon. Dannenbaum et al.<sup>11</sup> found that, in the presence of a complete rupture of all heads, the superior margin of the pectoralis tendon should be within 1 mm of the latissimus dorsi insertion, and the average footprint is 73 mm × 3 mm.

Suture biomechanics in pectoralis major repair have been studied in cadavers to evaluate tensile strength and points of failure. Gregory et al.<sup>17</sup> found that the suture configuration had a profound effect on repair strength. The use of a running, locked configuration and the use of polyethylene tape showed higher loads to failure.<sup>17</sup> Edgar et al.<sup>18</sup> found that taped suture in combination with No. 5 high-strength suture showed 61% greater construct strength than the traditional bone trough technique.

The incidence of postoperative infection after open shoulder surgery is rare, at 0.5% to 4%.<sup>19</sup> However, in situations of infection, all hardware must be removed to clear the infection. Intramedullary cortical buttons are made of metal, and in the setting of an infection, a large cortical window may be required to remove a metal button from the intramedullary canal.

The pull-through intramedullary anchor technique has several advantages. The suture anchor creates the smallest cortical defect (2.9 mm) and yields the lowest risk of postoperative humeral fractures.<sup>11</sup> In addition, more points of fixation can be placed, which allows a more anatomic repair of the tendon. Furthermore, this repair technique uses a taped suture with a running locking configuration, which has been shown to be biomechanically superior.<sup>18</sup> Moreover, the anchor is made of biocomposite and will resorb over time; so, in cases of postoperative infections, it would not have to be removed. Finally, by having a post limb through the anchor, the tendon can be easily and effectively

reduced onto the bone to reduce gap formation. The pull-through intramedullary anchor technique for pectoralis major repair provides a biomechanically superior technique, has the lowest risk of postoperative fractures, and re-creates the anatomic footprint of the torn tendon.

### Acknowledgments

The views expressed in this article are those of the authors and do not reflect the official policy or position of the Department of the Army, Department of Defense, or the U.S. Government.

### References

1. Antosh IJ, Grassbaugh JA, Parada SA, Arrington ED. Pectoralis major tendon repairs in the active-duty population. *Am J Orthop (Belle Mead NJ)* 2009;38:26-30.
2. Baker HP, Tjong VK, Varelas A, Wonais M, Terry MA. A case series of pectoralis major injuries on one collegiate football team. *Curr Sports Med Rep* 2017;16:346-350.
3. Balazs GC, Brelin AM, Donohue MA, et al. Incidence rate and results of the surgical treatment of pectoralis major tendon ruptures in active-duty military personnel. *Am J Sports Med* 2016;44:1837-1843.
4. ElMaraghy AW, Devereaux MW. A systematic review and comprehensive classification of pectoralis major tears. *J Shoulder Elbow Surg* 2012;21:412-422.
5. Bak K, Cameron EA, Henderson IJ. Rupture of the pectoralis major: A meta-analysis of 112 cases. *Knee Surg Sports Traumatol Arthrosc* 2000;8:113-119.
6. Nute DW, Kusnezov N, Dunn JC, Waterman BR. Return to function, complication, and reoperation rates following primary pectoralis major tendon repair in military service members. *J Bone Joint Surg Am* 2017;99:25-32.
7. Butt U, Mehta S, Funk L, Monga P. Pectoralis major ruptures: A review of current management. *J Shoulder Elbow Surg* 2015;24:655-662.
8. Metzger PD, Bailey JR, Filler RD, Waltz RA, Provencher MT, Dewing CB. Pectoralis major muscle rupture repair: Technique using unicortical buttons. *Arthrosc Tech* 2012;1:e119-e125.
9. Pochini AC, Rodrigues MSB, Yamashita L, Belangero PS, Andreoli CV, Ejnisman B. Surgical treatment of pectoralis major muscle rupture with adjustable cortical button. *Rev Bras Ortop* 2017;53:60-66.
10. Sanchez A, Ferrari MB, Frangiamore SJ, Sanchez G, Kruckeberg BM, Provencher MT. Pectoralis major repair with unicortical button fixation and suture tape. *Arthrosc Tech* 2017;6:e729-e735.
11. Dannenbaum JH, Eckhoff MD, Galvin JW, Bean BK, Wilson DJ, Arrington ED. Pectoralis major tendon insertion anatomy and description of a novel anatomic reference. *J Surg Orthop Adv* 2018;27:39-41.
12. Mooers BR, Westermann RW, Wolf BR. Outcomes following suture-anchor repair of pectoralis major tears: A case series and review of the literature. *Iowa Orthop J* 2015;35:8-12.
13. Sherman SL, Lin EC, Verma NN, et al. Biomechanical analysis of the pectoralis major tendon and comparison of techniques for tendo-osseous repair. *Am J Sports Med* 2012;40:1887-1894.
14. Haley CA, Zacchilli MA. Pectoralis major injuries: Evaluation and treatment. *Clin Sports Med* 2014;33:739-756.
15. Silverstein J, Goldberg B, Wolin P. Proximal humerus shaft fracture after pectoralis major tendon rupture repair. *Orthopedics* 2011;34:e222-e224.
16. Wilson DJ, Milam BP, Scully WF, et al. Biomechanical evaluation of unicortical stress risers of the proximal humerus associated with pectoralis major repair. *Orthopedics* 2017;40:e801-e805.
17. Gregory JM, Klosterman EL, Thomas JM, et al. Suture technique influences the biomechanical integrity of pectoralis major repairs. *Orthopedics* 2015;38:e746-e752.
18. Edgar CM, Singh H, Obopilwe E, et al. Pectoralis major repair: A biomechanical analysis of modern repair configurations versus traditional repair configuration. *Am J Sports Med* 2017;45:2858-2863.
19. Saltzman MD, Marecek GS, Edwards SL, Kalainov DM. Infection after shoulder surgery. *J Am Acad Orthop Surg* 2011;19:208-218.