

## CASE REPORT

# Custom double tray for a special impression technique for flabby maxillary residual ridge: Case report

Aisha Zakaria Hashem Mostafa<sup>1</sup>  | Sarab Muzil Alanazi<sup>2</sup> |  
Samaher Mohammad Almarshedy<sup>3</sup>

<sup>1</sup>Prosthodontics Department, Collage of Dentistry, Mansoura University, Mansoura, Egypt

<sup>2</sup>Faculty of dentistry, Ha'il University, Ha'il, Saudi Arabia

<sup>3</sup>Restorative Department, Collage of Dentistry, University of Ha'il, Ha'il, Saudi Arabia

## Correspondence

Aisha Zakaria Hashem Mostafa,  
Prosthodontics Department, Collage of Dentistry, Mansoura University, Mansoura, Egypt.  
Emails: dr.aishazakaria25@yahoo.com; aishazakaria@mans.edu.eg

## Funding information

None

## Abstract

The construction of a removable dental prosthesis for patients with compromised residual alveolar ridges is a challenge for prosthodontists. Flabby anterior ridges and hypermobile tissues in completely edentulous arches require special considerations during prosthetic management, especially when natural dentations remain on the opposite side. Previous studies have revealed that the displacement of flabby tissue can be reduced during impressions by controlling the applied forces via changes in factors such as the tray design, scraping of impression trays, impression material, window technique, and seating velocity of the impressions. However, there may still be some forces applied during impression or there is no even space because there are no trays supporting the vinyl polysiloxane (VPS) impression material in the open window area. Using a custom double tray with even gap between these trays and injecting light body impression material may eliminate these forces and provide accuracy due to even space for the impression material. This article is a clinical report of a patient who presented with an anterior flabby maxillary edentulous ridge opposing the remaining anterior natural teeth. A custom double tray was fabricated using the principle of the window technique. The gap between the double trays allows mucostatic impressions of flabby ridge tissue to be made with accuracy. The maxillary single denture, which was made with a custom double tray, satisfied the patient.

## KEYWORDS

double tray, flabby tissue, hypermobile tissues, special impression technique, window technique

## 1 | INTRODUCTION

Flabby tissues or hypermobile tissues in the denture bearing area may cause problems for complete dentures, such as pain during denture wearing and displacement of the denture.

When a flabby ridge occurs in the presence of anterior hyperfunction syndrome, the main problem during impression making is the displacement or distortion of flabby tissues by the force exerted during impression making. Dentures may be ill-fitting if they are constructed based on this impression.<sup>1,2</sup>

This is an open access article under the terms of the Creative Commons Attribution-NonCommercial-NoDerivs License, which permits use and distribution in any medium, provided the original work is properly cited, the use is non-commercial and no modifications or adaptations are made.

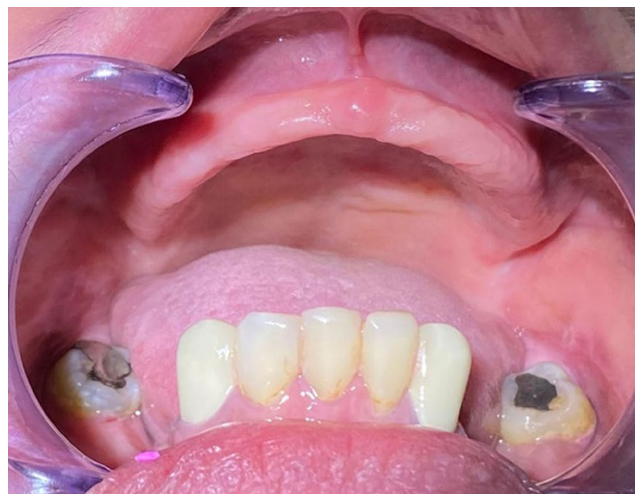© 2022 The Authors. *Clinical Case Reports* published by John Wiley & Sons Ltd

Flabby ridges can be managed using either prosthetic management or surgical management. Different surgical treatment options are accessible for flabby ridges, including ridge augmentation, excision, and the injection of sclerosing solutions.<sup>2,3</sup> The prosthodontic management of hypermobile tissues cases can be performed by accurately recording hypermobile soft tissues and maintaining stable occlusal contact. There is controversy regarding whether compressive or static methods are better for recording flabby ridge impressions. Clinicians have supported the latter concept of static methods for recording tissues. Several methods have been employed for the static recording of tissues. Static impressions can be performed with minimal tissue displacement by controlling the force applied when the impression is made by regulating many factors, such as the impression tray design, impression material type, and impression seating velocity. The tray design can be altered either with spacers or perforating impression trays, scraping impression trays, using open trays with the window technique, and using detachable trays.<sup>4-22</sup> Trays with additional spacers and holes or trays that open near the flabby ridge area reduce tissue displacement.<sup>18</sup> Open window trays yield the smallest magnitude of displacement.<sup>19</sup> According to Masri et al,<sup>10</sup> the viscosity of the impression material has a direct impact on the amount of pressure applied during the impression process. However, based on that it is critical to use rigid custom trays to get accurate impressions,<sup>23</sup> using an open window tray with vinyl polysiloxane (VPS) without tray support anteriorly may affect the accuracy of the impression. Thus, another keyed tray can be used. The tray provides even thickness of the impression material to help improve dimensional accuracy.<sup>24</sup> Polysiloxane impressions made using custom trays were more accurate and reliable than were stock tray impressions.<sup>25</sup>

This article is a case report of the impression technique (comparable to the window technique) being performed using an acrylic resin custom double tray, the two-step impression technique, and VPS elastomeric impression material for a patient with a flabby maxillary ridge.

## 2 | CASE REPORT

A 53-year-old female patient presented to the prosthodontic clinic of dentistry with complaints of an ill-fitting maxillary complete denture constructed many years ago. The patient was also complaining that the newly constructed denture was not comfortable for use. The intraoral examination revealed an edentulous maxillary arch with an anterior flabby ridge and a partially edentulous mandibular arch (Figure 1). Epulis fissuratum was present at the vestibule of the maxillary anterior area. A radiographic



**FIGURE 1** Patient with a maxillary edentulous arch with anterior flabby ridge and mandibular partially edentulous arch

examination was performed for the patient as routine examination. It revealed that the bone was free of any pathological conditions. Only the maxillary arch had severe bone resorption.

The previous removable prosthodontics for the patient was maxillary single denture opposed by mandibular removable partial denture with acrylic extension to cover the anterior and posterior remaining teeth. This extension resemble the occlusal splint (Figure 2).

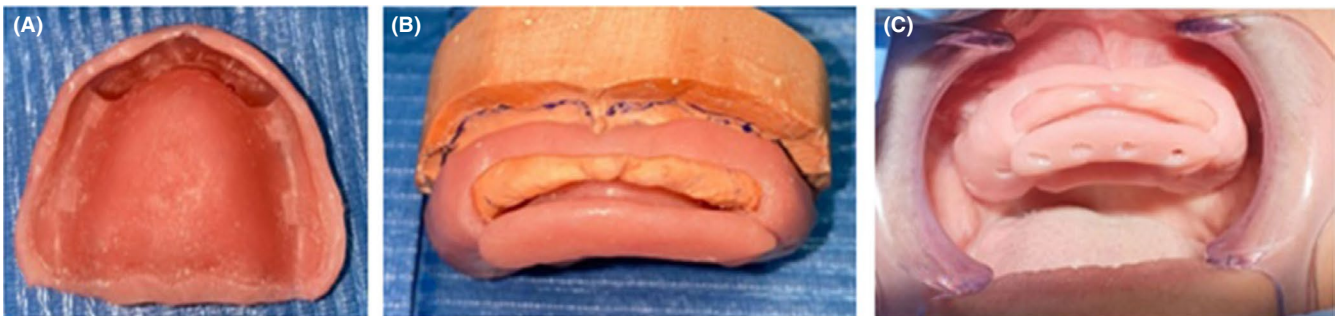
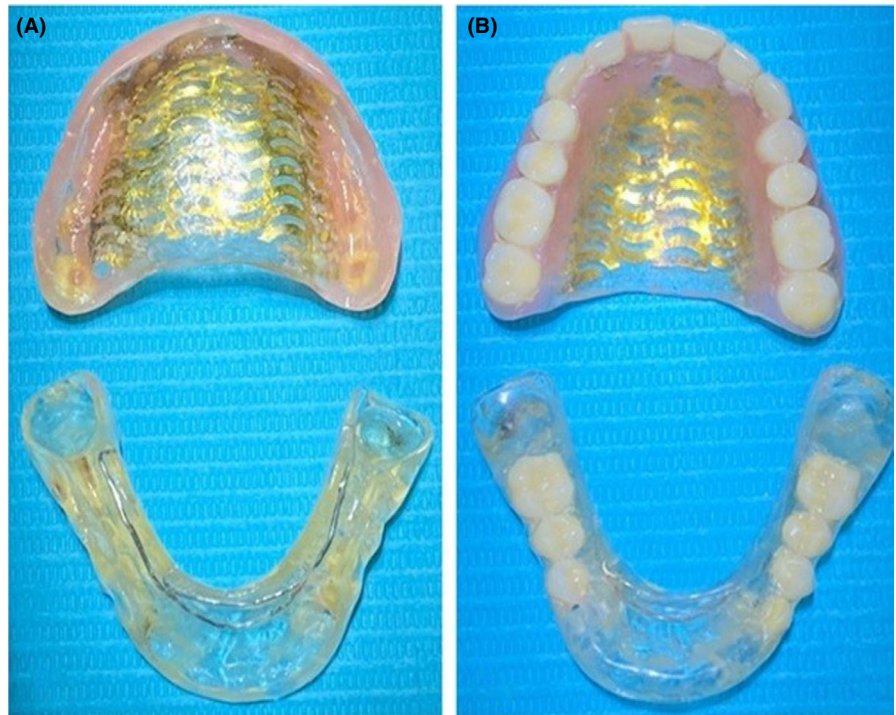
The patient's lost teeth were to be replaced with a new maxillary single complete denture, which would be paired with a class III modification 1 mandibular removable partial denture. Since the patient came with another new denture constructed with a conventional impression and she complained of this denture, the treatment plan was to use a special impression technique to fabricate a new denture for the maxillary flabby anterior ridge. A custom double tray was planned and constructed with a special window impression technique using VPS material for the master impression.

## 3 | TECHNIQUE

The custom double tray construction and impression techniques were as follows:

1. A preliminary impression was made with alginate (Cavex CA37, Germany) material using edentulous plastic stock trays of sizes suitable for the patient.
2. A maxillary preliminary cast was poured (Dental stone, Type IV, Kulzer, UK), and then, the flabby ridge area was identified on the cast.
3. The custom double tray was fabricated as follows (Figure 3):

**FIGURE 2** The previous prosthetic restoration (maxillary single denture opposed by mandibular removable partial denture stent). A. Tissue surface. B. Polished surface



**FIGURE 3** The double trays acrylic resin special tray: A. With spacer. B. Double tray with 2 mm gap between the trays. C. Double tray with perforations after check intraoral

- a. The borders of the tray were determined to be 2 mm less than the depth of the vestibule (sulcus).
- b. The flabby ridge area was marked on the cast.
- c. A wax sheet was applied to the cast to create a custom tray spacer with stoppers.
- d. Self-cured acrylic resin tray material was applied to cover the maxillary cast except in the area of the flabby ridge, and a horizontal handle was inserted in the palatal vault area to act as a key for the second tray.
- e. A double sheet of base plate wax (Cavex Set Up Regular, Modeling wax, Germany) was applied at the flabby ridge area.
- f. The second tray was constructed to cover the flabby ridge area and palatal area of the first tray. It was adapted to create a keyway with the handle of the 1<sup>st</sup> tray (Key).
- g. Perforations were made on the custom double tray for mechanical retention of the impression material and to allow the escape of excess impression material.
4. The custom impression tray was tested in the patient's mouth, and the tray flanges were adjusted to be 2 mm shorter than the depth of the sulcus using a slow-speed motor and carbide acrylic trimming bur.
5. Border molding was added to the first part of the tray using the elastomeric impression material (heavy body material). Then, a maxillary impression was made using elastomeric impression material (light body VPS) (Correct Plus impression material, USA) (Figure 4). The light body elastomeric impression material was mixed using dynamic mechanical mixing.
6. The impression was evaluated carefully for defects, and any excess material on the periphery was



removed. In addition, any excess impression material in the area of the flabby ridge was carefully removed using a scalpel blade (Figure 4).

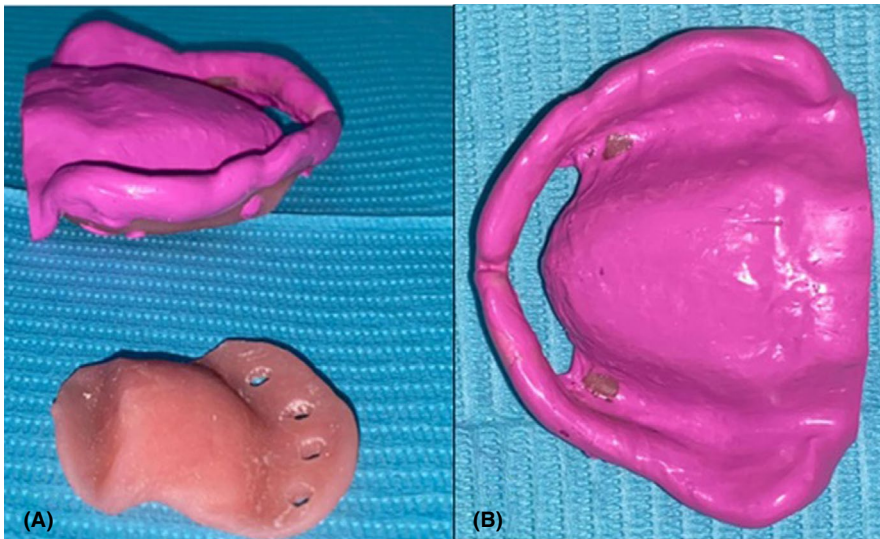
7. The impression was reseated in the patient's mouth, and the second custom tray was applied using the key/keyway method with the first tray.
8. The light body VPS elastomeric impression material (Correct Plus [VPS] impression material, USA) was injected through the gap present between the first and second trays until some excess material leaked from the holes (Figure 5).
9. A master cast was poured from the master impression (by using boxing and pouring), and a record block was fabricated for the maxillomandibular relationship record.
10. After try in and processing, the denture was inserted intraorally and the patient was given instruction for use and home care of the prosthesis.
11. Follow-up was done at 3 and 6 months. The patient was satisfied by the denture in comparison to the previous maxillary dentures that was done with conventional impression technique. She feel that this

maxillary single denture is more comfortable. Clinical examination revealed that the denture constructed with window special impression technique using custom double tray was stable and retentive. Written consent from the patient has been obtained.

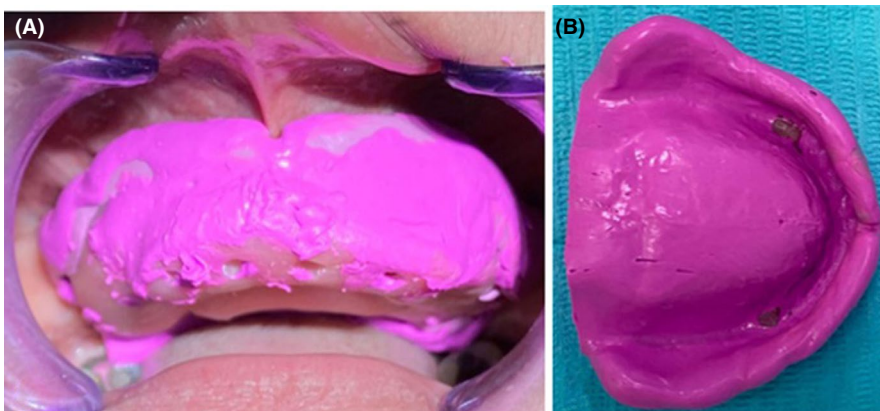
## 4 | DISCUSSION

The major aim of complete denture therapy is to restore function and esthetics and maintain patient health. Managing a patient with a maxillary flabby ridge may be challenging and problematic. The flabby ridge can be managed surgically, prosthetically, or both surgically and prosthetically.<sup>1-3</sup> When surgical management is not preferred, prosthodontic management can be performed mainly through the impression technique and by conserving established occlusal contacts.<sup>1-24</sup>

In 2016, Shine et al. found that the design of the tray affects tissue displacement and that impressions with trays with additional spacers and holes or trays with openings at the flabby ridge areas reduce tissue displacement.<sup>18</sup>



**FIGURE 4** First tray after border molding and impression using heavy and light body vinyl polysiloxane (VPS) impression material. A. Lateral view. B. Occlusal view



**FIGURE 5** Final impression after injection of light body vinyl polysiloxane (VPS) impression material in the gap between the first and second trays. A. Intraoral view. B. Extraoral view

In 2019, Shine et al. found that open window impressions yield the smallest magnitude of displacement. Additionally, the impression technique affects the magnitude of flabby ridge displacement; the two-step impression technique yields less tissue displacement than does the one-step impression technique.<sup>19</sup>

Based on these previously mentioned studies, the window technique is preferred.<sup>18,19</sup> Using an open window tray with VPS without any tray support anterior to the flabby ridge area may lead to distortion of the impression during casting of the impression. Therefore, using an additional tray keyed to the first tray prevents distortion during cast pouring. In addition to that, the presence of tray offer uniform thickness of the impression material to develop dimensional accuracy of the impression.<sup>24</sup>

In this current case, the described window technique, the custom two-step double tray technique, enabled the flabby tissue to be accurately recorded without displacement. The gap that is present between the two trays allows light body VPS elastomeric impression material to be injected without any pressure from the tray, which leads to an undistorted impression. The flabby ridge area is recorded in the rest position with easy and stable special double trays. The even thickness of impression material at the hypermobile tissue area improves the accuracy of the impression. The uniform thickness of the impression material ensures that the impression is accurate.<sup>24</sup>

The custom double tray used in this study can be constructed easily with key and keyway methods in the palatal area of the tray to allow accurate assembly of the 2 trays and preserve an even gap between the 2 trays of approximately 2 mm. The window technique using double trays allows mucostatic recordings of flabby tissue provide a uniform thickness of the impression material and offer dimensional accuracy. Also, it may preserves the impression material from being distorted in the open tray area.

The denture base, which was constructed on a cast generated using this approach, was accurate and allowed for precise tissue adaptation. Passive denture base adaptation was achieved without limiting the vascularity of the flabby tissue or interfering with its viscoelasticity, sustaining tissue health, denture fit, and, as a result, patient comfort.

In the partially edentulous jaw, impression methods using an intraoral scanner are often utilized; in the entirely edentulous jaw, various errors may arise due to a lack of anatomical indications, and moveable tissues such as the vestibule and soft palate were particularly unstable in certain cases. Furthermore, due to the scanner's improper design and size, taking an impression of the entire edentulous arch presents various obstacles.<sup>26</sup>

Individual trays are used either for open or closed mouth technique with a digital device in case of digitalized complete denture.

Despite the fact that an intraoral scanner is unable to make a direct definitive impression of complete dentures due to movable tissues such as the vestibule and soft palate, as well as the presence of flabby ridge, which can be extremely unstable in some cases, the individual tray that is used for digitalization of complete denture construction in cases of flabby ridge can be constructed using the double custom tray as described in this case report.

## 5 | CONCLUSION

When surgical management of a hypermobile tissue or flabby maxillary residual ridge is not an option, prosthodontic management, by accurately recording this tissue using a custom double tray, is an alternative method for successful management. The maxillary single denture, which was made with a custom double tray, satisfied the patient.

## ACKNOWLEDGEMENT

None.

## CONFLICT OF INTEREST

The authors declare there are no potential conflicts of interest.

## AUTHOR CONTRIBUTIONS

AZHM provided the idea of this management of the patient, wrote the manuscript, supervised on this clinical management of the case as all, organized the clinical management, and did the submission and editing. SMAA shared in the clinical management of the patient and did the follow-up of the patient. SMA shared in scientific writing and clinical management of the patient. All the authors were approved this case report.

## ETHICAL APPROVAL

This case report was done to follow the ethical guideline of the Ethics Committee of the University of Mansoura, Faculty of Dentistry.

## CONSENT

The patient was signed an informed consent for participation in this study after they were informed about the full details of this case report.

## DATA AVAILABILITY STATEMENT

The data that support the findings of this case report are available from the corresponding authors upon reasonable request.

## ORCID

Aisha Zakaria Hashem Mostafa  <https://orcid.org/0000-0001-7268-2993>

## REFERENCES

- Crawford RW, Walmsley AD. A review of prosthodontic management of fibrous ridges. *Br Dent J.* 2005;199:715-719.
- Zarb GA, Hobkirk JA, Eckert SE, Jacob RF. *Prosthodontic Treatment for Edentulous Patients.* Mosby. 2013;48, 80.
- Desjardins RP, Tolman DE. Etiology and management of hypermobile mucosa overlying the residual ridge. *J Prosthet Dent.* 1974;32:619-638.
- Frank RP. Analysis of pressures produced during maxillary edentulous impression procedures. *J Prosthet Dent.* 1969;22:400-413.
- Al-Ahmad A, Masri R, Driscoll CF, et al. Pressure generated on a simulated mandibular oral analog by impression materials in custom trays of different design. *J Prosthodont.* 2006;15:95-101.
- Komiyama O, Saeki H, Kawara M, et al. Effects of relief space and escape holes on pressure characteristics of maxillary edentulous impressions. *J Prosthet Dent.* 2004;91:570-576.
- Klein IE, Broner AS. Complete denture secondary impression technique to minimize distortion of ridge and border tissues. *J Prosthet Dent.* 1985;54:660-664.
- Javid NS, Michael CG, Mohammed HA, et al. Three-dimensional analysis of maxillary denture displacement during reline impression procedure. *J Prosthet Dent.* 1985;54:232-237.
- Yamashita S, Ai M, Geng Q, Sato M, Shinoda H, Ando S. Application of a newly developed 3-D deformation measurement system to prosthetic dentistry. *J Oral Rehabil.* 1996;23:849-855.
- Masri R, Driscoll CF, Burkhardt J, Fraunhofer A, Romberg E. Pressure generated on a simulated oral analog by impression materials in custom trays of different designs. *J Prosthodont.* 2002;11:155-160.
- Nishigawa G, Natsuaki N, Maruo Y, Okamoto M, Minagi S. Visual observation of the dynamic flow of elastomer rubber impression material between the impression tray and oral mucosa while seating the impression tray. *J Oral Rehabil.* 2003;30:608-613.
- Lynch CD, Allen PF. Case report: management of the flabby ridge: re-visiting the principles of complete denture construction. *Eur J Prosthodont Restor Dent.* 2003;11:145-148.
- Lynch C, Allen P. Management of the flabby ridge: using contemporary materials to solve an old problem. *Br Dent J.* 2006;200:258-261.
- Hyde TP, Craddock H, Brunton P. The effect of seating velocity on pressure within impressions. *J Prosthet Dent.* 2008;100:384-389.
- Bindhoo Y, Thirumurthy V, Kurien A. Complete mucostatic impression: a new attempt. *J Prosthodont.* 2012;21:209-214.
- Shum MH, Pow EH. Management of excessive movable tissue: a modified impression technique. *J Prosthet Dent.* 2014;112:387-389.
- Reddy SM, Mohan CA, Vijitha D, Balasubramanian R, Satish A, Kumar M. Pressure produced on the residual maxillary alveolar ridge by different impression materials and tray design: an in vivo study. *J Indian Prosthodont Soc.* 2013;13:509-512.
- Shin JO, Huh YH, Cho LR, Park CJ. The effect of edentulous maxillary impression tray designs when flabby tissue is present: an in vitro study. *Int J Prosthodont.* 2016;29:467-472.
- Shin JO, Ko KH, Huh YH, Cho LR, Park CJ. Displacement of simulated flabby tissue by different tray designs and impression materials. *J Prosthodont.* 2019;28:444-451.
- Showkat R, Sharma A, Kumar S, Kaura S. Management of flabby ridge using Hobkirk's technique: a case report. *Eur J Dent Oral Health.* 2020;1(4):1-4.
- Osborne J. Two impression methods for mobile fibrous ridges. *Br Dent J.* 1964;117:392-394.
- Devlin H. A method for recording an impression for a patient with a fibrous maxillary alveolar ridge. *Quintessence Int.* 1985;16(6):395-397.
- Burns J, Palmer R, Howe L, Wilson R. Accuracy of open tray implant impressions: an in vitro comparison of stock versus custom trays. *J Prosthet Dent.* 2003;89(3):250-255.
- Smith PW, Richmond R, McCord JF. The design and use of special trays in prosthodontics: guidelines to improve clinical effectiveness. *Br Dent J.* 1999;187(8):423-426.
- Millstein P, Maya A, Segura C. Determining the accuracy of stock and custom tray impression/casts. *J Oral Rehabil.* 1998;25(8):645-648.
- Jung S, Park C, Yang HS, et al. Comparison of different impression techniques for edentulous jaws using three-dimensional analysis. *J Adv Prosthodont.* 2019;11(3):179-186.

**How to cite this article:** Mostafa AZH, Alanazi SM, Almarshedy SM. Custom double tray for a special impression technique for flabby maxillary residual ridge: Case report. *Clin Case Rep.* 2022;10:e05593. doi:[10.1002/ccr3.5593](https://doi.org/10.1002/ccr3.5593)