



Since January 2020 Elsevier has created a COVID-19 resource centre with free information in English and Mandarin on the novel coronavirus COVID-19. The COVID-19 resource centre is hosted on Elsevier Connect, the company's public news and information website.

Elsevier hereby grants permission to make all its COVID-19-related research that is available on the COVID-19 resource centre - including this research content - immediately available in PubMed Central and other publicly funded repositories, such as the WHO COVID database with rights for unrestricted research re-use and analyses in any form or by any means with acknowledgement of the original source. These permissions are granted for free by Elsevier for as long as the COVID-19 resource centre remains active.

Myocarditis in a 16-year-old boy positive for SARS-CoV-2



Massimiliano Gnechi, Francesco Moretti, Emilio Maria Bassi, Sergio Leonardi, Rossana Totaro, Luciano Perotti, Valentina Zuccaro, Stefano Perlini, Lorenzo Preda, Fausto Baldanti, Raffaele Bruno, Luigi Oltrona Visconti

A 16-year-old boy was admitted to our emergency department, in Lombardy, complaining of intense pain in his chest—radiating to his left arm—which had started 1 h earlier. The day before he had a fever of 38.3°C that decreased after 100 mg of nimesulide. He reported no other symptoms, no medical history, and no contact with anyone with confirmed COVID-19.

We found his vital signs to be normal apart from his temperature which was raised at 38.5°C. On auscultation of the patient's chest, we heard normal heart sounds, no pericardial rub, and no abnormal respiratory signs. We found no lymphadenopathy, no rash, and no areas of localised tenderness on the chest wall. An electrocardiogram (ECG) showed inferolateral ST-segment elevation (figure) and a transthoracic echocardiography showed hypokinesia of the inferior and inferolateral segments of the left ventricle, with a preserved ejection fraction of 52%; no pericardial effusion was seen. Investigations showed raised high-sensitivity cardiac troponin I (9449 ng/L), creatine phosphokinase (671.0 U/L), C-reactive protein (32.5 mg/L), and lactate dehydrogenase (276.0 U/L) concentrations (appendix). The leucocyte count was 12.75×10^9 per L, the neutrophil count was 10.04×10^9 per L, and the lymphocyte count was 0.78×10^9 per L.

We gave the boy aspirin to relieve his pain and transferred him to the coronary care unit with a working diagnosis of acute myocarditis. The patient's pain gradually improved and after 2 h had completely resolved.

However, during the first night, he reported further chest pain; the ECG was repeated but no significant changes were seen (appendix). We started him on intravenous ibuprofen 600 mg three times a day and both his symptoms and raised temperature resolved. Tests for autoantibodies and cardiotropic viruses were negative (appendix). On day 3, a nasopharyngeal swab test for severe acute respiratory syndrome coronavirus 2 (SARS-CoV-2) was positive, so we started hydroxychloroquine and antiviral therapy. Serial measurements of the patient's troponin concentration showed a gradual reduction from a peak of 16862 ng/L on day 1, to 39 ng/L on day 8. The inflammatory markers also returned to normal and the ST-segment elevation on ECG resolved (appendix).

On day 11—after nasopharyngeal swabs taken on 2 consecutive days were negative—MRI T2-weighted

short-tau inversion recovery sequences showed changes supporting the diagnosis of acute myocarditis (figure; appendix). On day 12, he was well, asymptomatic, and allowed home.

Notably, throughout the entire time he was in hospital, our patient did not have any of the signs or symptoms—apart from a fever—typically reported in COVID-19; his peripheral oxygen saturation levels remained within normal limits and two chest x-rays, on days 3 and 6, were clear (appendix). Paediatric patients reporting chest pain and other features suggestive of acute myocarditis—with or without respiratory symptoms—should, we believe, also be tested for SARS-CoV-2 (video).

Contributors

We were all involved in the care and management of the patient, and the writing and editing of the manuscript. Written consent for publication was obtained from the patient and his parents.

© 2020 Elsevier Ltd. All rights reserved.

Lancet 2020; 395: e116

Coronary Care Unit and Laboratory of Clinical and Experimental Cardiology (Prof M Gnechi MD, F Moretti MD, S Leonardi MD, R Totaro MD), Radiology Unit (E M Bassi MD, L Preda MD), Anaesthesia and Resuscitation Unit, (L Perotti MD), Infectious Diseases I Unit (V Zuccaro MD, R Bruno MD), Emergency Department (S Perlini MD), Molecular Virology Unit (F Baldanti MD), and Cardiology Unit (L Oltrona Visconti MD), Fondazione IRCCS Policlinico San Matteo, Pavia, Italy; and Department of Molecular Medicine, Cardiology Unit (Prof M Gnechi, F Moretti, S Leonardi), Department of Internal Medicine and Therapeutics (S Perlini), and Department of Clinical, Surgical, Diagnostic and Paediatric Sciences (L Preda, F Baldanti, R Bruno), University of Pavia, Pavia, Italy

Correspondence to: Prof Massimiliano Gnechi, Department of Molecular Medicine, Cardiology Unit, University of Pavia, DEA Tower A, Pavia 27100, Italy
m.gnechi@unipv.it

See Online for appendix

See Online for video

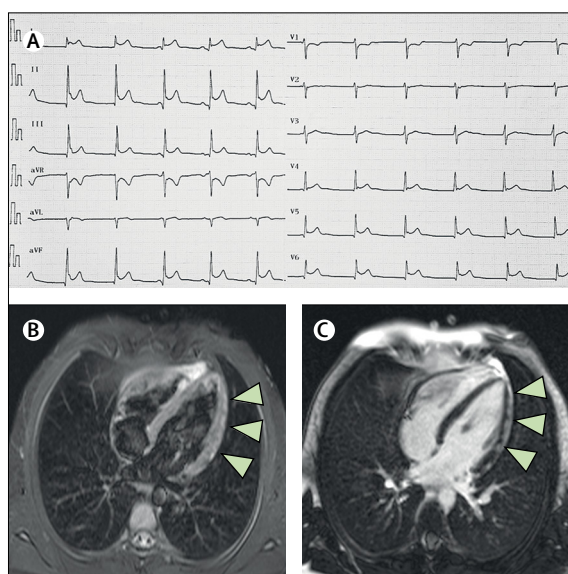


Figure: Myocarditis in a paediatric patient with COVID-19

An electrocardiogram shows ST-segment changes in inferolateral, aVR, and V1 leads (A). An MRI T2-weighted short-tau inversion recovery image shows a subepicardial band-like high signal indicating patchy oedema involving the whole of the lateral wall (arrowheads; B) and a late gadolinium-enhanced image shows a high intensity signal—indicating necrosis—in the same place (arrowheads; C).