



OPEN ACCESS

CASE REPORT

Concomitant *Plasmodium vivax* malaria and murine typhus infection with pulmonary involvement

Chayasin Mansanguan, Weerapong Phumratanaprapin

Faculty of Tropical Medicine,
Mahidol University, Bangkok,
Thailand

Correspondence to

Dr Weerapong
Phumratanaprapin,
weerapong.phu@mahidol.ac.th

Accepted 15 November 2018

SUMMARY

We report a case of *Plasmodium vivax* and murine typhus coinfection in a 30-year-old woman who presented with intermittent, high-grade fever. Her peripheral blood smear showed ring-form trophozoites of *P. vivax*, with an initial murine typhus serological test being negative. Although the *P. vivax* infection was successfully treated, she still had intermittent, high-grade fever, developed dyspnoea and bilateral interstitial pneumonitis shown in the chest X-ray. Thus, coinfection was suspected, and empirical antibiotics were given. The second serological test confirmed the concomitant murine typhus infection, and antibiotics treatment were successful with the complete recovery. This case emphasises that an initial negative murine typhus serological test does not necessarily rule out the presence of the disease. A follow-up murine typhus serological or molecular test within 1–2 weeks is therefore recommended.

BACKGROUND

Thailand is an endemic area for tropical disease infections, including malaria, dengue, scrub typhus, murine typhus and leptospirosis, all of which may be present as an acute febrile illness with an acute undifferentiated fever. Coinfection usually causes more severe symptoms than single infection, and usually requires a time-consuming and challenging process of diagnosis.^{1,2} Coinfections of *Plasmodium vivax* malaria and murine typhus are not common in our clinical practice. Murine typhus with severe manifestation as pneumonitis is atypical manifestation.^{3,4} In particular, coinfection between murine typhus and malaria is likely to be underdiagnosed or may be confused with other acute febrile infections.⁵ In this present report, we report the first case of *P. vivax* malaria and murine typhus with pulmonary involvement coinfection in Thailand.

CASE PRESENTATION

A 30-year-old woman presented with intermittent, high-grade fever with chills for 5 days prior to admission associated with headache, myalgia and nausea. With the high frequency of fever, leucopenia and thrombocytopenia during rainy season, a provisional diagnosis of dengue infection was made at a nearby hospital. The patient started on intravenous fluids and supportive treatment, and was then referred to the Bangkok Hospital for Tropical Diseases, a referral centre for tropical diseases, for further investigations and management.

On the first day of admission to the hospital, she was mildly pale, febrile (37.8°C), with the heart rate of 84 beats/min and respiratory rate of 20 breaths/min without hepatosplenomegaly. Other examinations were unremarkable. *P. vivax* was detected in her peripheral blood smear. She was diagnosed as *P. vivax* infection and chloroquine was thus given.

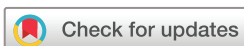On the fourth day of admission, although malaria peripheral blood smear was negative, she still had an intermittent, high-grade fever, and developed dyspnoea and oxygen desaturation (O₂sat=91% on room air).

INVESTIGATIONS

The initial blood test showed mild leucopenia—a white cell count of 2.1x10⁹/L, with 43% of neutrophils, 28% of lymphocytes, 16% of band, 7% of monocyte and 6% of atypical lymphocyte. Haemoglobin, haematocrit and platelets were 10.2 g/dL, 32.7% and 85x10⁹/L, respectively. The blood film for malarial parasites showed ring-form trophozoites of *P. vivax*, with parasite count of 10.5 parasites/μL.

Urea and electrolytes showed the levels of sodium, potassium, urea and creatinine at 137 mmol/L, 3.5 mmol/L, 8.1 mg/dL and 0.58 mg/dL, respectively. The liver function tests revealed a total protein of 6.1 g/dL, albumin of 3.6 g/dL, alkaline phosphatase of 35 U/L, aspartate aminotransferase of 71 U/L, alanine transaminase of 50 U/L, total bilirubin of 0.2 mg/dL and direct bilirubin of 0.1 mg/dL. Her glucose-6-phosphate dehydrogenase level was normal.

She still had high-grade intermittent fever each day, and on the fourth day of admission she developed dyspnoea. The blood film for malaria was negative. Her chest radiograph showed bilateral interstitial infiltration, suggestive of bilateral pneumonitis (figure 1). Coinfection was considered for further investigations. It was found that sputum gram stain, acid-fast bacilli, culture, *Pneumocystis jirovecii* pneumonia and anti-HIV were all negative. Two blood cultures have been taken a few hours apart. The automated blood culture system (BACTEC 9050) is used in microbiology laboratory. Her blood culture showed no growth for 7 days. Serological investigations for dengue (IgM and IgG antibodies), dengue PCR, scrub typhus (IgG antibody) and murine typhus (IgM and IgG antibodies) were also negative. Scrub typhus IgM antibody in acute serum was positive at a titre 1:100; however, the titre remained the same in convalescent serum. A follow-up murine typhus serological titre was



© BMJ Publishing Group Limited 2018. Re-use permitted under CC BY-NC. No commercial re-use. See rights and permissions. Published by BMJ.

To cite: Mansanguan C, Phumratanaprapin W. *BMJ Case Rep* 2018;**11**:e226139. doi:10.1136/bcr-2018-226139

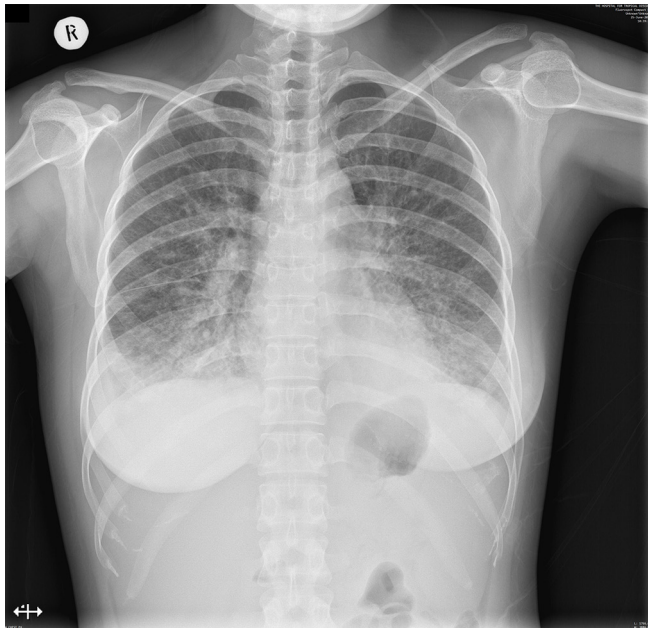


Figure 1 The chest radiograph showed bilateral interstitial infiltration, suggestive of bilateral pneumonitis.

performed 1 week after the initial test which showed a positive murine typhus (IgM 1:3200 and IgG 1:1600).

DIFFERENTIAL DIAGNOSIS

P. vivax malaria and murine typhus coinfection.

TREATMENT

The patient received chloroquine followed by primaquine orally as an antimalarial medication because Thailand is in the area with chloroquine-susceptible *P. vivax* infection. On the third day of admission, she still had fever, and ceftriaxone intravenous plus doxycycline with loading dose of 200 mg followed by 200 mg per day in divided dose orally were empirical antibiotics. On the fourth day of admission, she had intermittent fever, developed dyspnoea and chest radiograph showed bilateral interstitial infiltration. Coinfection was suspected and the empirical antibiotics were prescribed with intravenous levofloxacin and continued doxycycline to cover bacterial and rickettsial infections. After empirical antibiotics, her oxygenation was improved and she became afebrile after 72 hours. Levofloxacin was discontinued after murine typhus coinfection was confirmed. Doxycycline was continued for 7 days. She was discharged after 7 days on levofloxacin.

OUTCOME AND FOLLOW-UP

She was discharged 10 days after admission with normal clinical conditions. The follow-up chest radiograph at the Out Patient Department showed complete clearing of pulmonary infiltration (figure 2).

DISCUSSION

The clinical features of uncomplicated malaria are common in *P. vivax* infection. Nevertheless, *P. vivax* can cause severe symptoms during the early course of an infection. This case was a 30-year-old woman presenting with *P. vivax* with murine typhus coinfection. On the third day of admission, malaria blood smear was negative, yet she still had a high-grade, intermittent fever. We suspected coinfection for two reasons. First, the patient

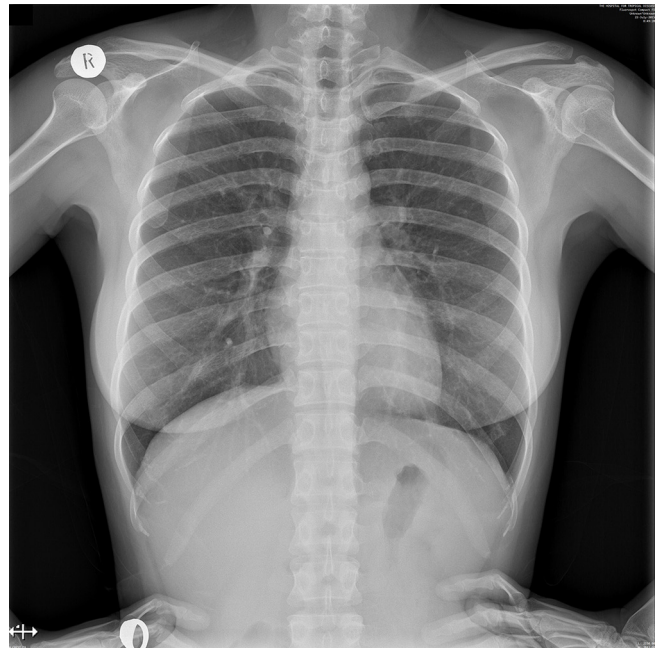


Figure 2 The followed-up chest radiograph showed complete clearing of pulmonary infiltration.

still had a high-grade fever, despite the negative malaria blood smear. Second, on the fourth day of admission, although she had received effective antimalarial drug, her clinical status still worsened, with the development of dyspnoea and oxygen desaturation. Her chest radiograph showed interstitial pneumonia that was suspected from murine typhus coinfection. The mechanism of pulmonary infiltration is still unknown; however, the mechanism may be associated with pulmonary microcirculation damage.^{3 4}

Apart from dengue NS1 Ag, IgG and IgM serological tests at admission, we also performed other investigations to rule out other causes of undifferentiated fever, including IgM and IgG for both murine typhus and scrub typhus.

The definite diagnosis of murine typhus was required, with the use of serological method by immunofluorescence assay (IFA) as the 'gold standard'. The serological test for murine typhus may be negative when blood samples are collected in the first week of fever. Therefore, a convalescent phase specimen is required to confirm diagnosis.⁶ A study conducted in South Texas showed that 50% of the seroconversion (fourfold increased antibody titres) found in infected patients at the first week of onset, whereas 100% of the seroconversion was observed in these patients at approximately 15 days after the onset of IFA technique.^{7 8} A fourfold rise in titre between the first and convalescent-phase serum is considered to be diagnostic.

A retrospective study conducted in Thailand showed that 45 out of 194 malaria patients (23.2%) were also diagnosed as murine typhus infection, which was made by single serological test with no clinical involvement.⁹ Another study conducted nearby Thai–Burma border also showed approximately 4% of coinfection between rickettsia and malaria in pregnant woman cohort.¹⁰

Our patients showed the confirmed coinfection of *P. vivax* malaria and murine typhus evidenced by her peripheral blood film that showed the ring-form trophozoites of *P. vivax*. Her serum IFA showed murine typhus IgM positive (1:3200) and IgG

positive (1:1600), which was a fourfold increase when compared with those of the first IFA serum.

The positive IFA to *Rickettsia typhi* should be caution with cross reactivity among *R. prowazekii*, *R. felis* and *R. rickettsii*.¹¹ However, *R. prowazekii*, *R. felis* and *R. rickettsii* are not endemic in Thailand. Both malaria and murine typhus are endemic in Southeast Asia, especially in Thailand. Thus, persons living in this area may acquire coinfection.

This article emphasises the concomitant of *P. vivax* malaria and murine typhus infection with pulmonary involvement. An initial negative murine typhus serological test does not rule out the absence of the disease in a febrile patient with a positive test result for a different febrile infectious disease. The authors suggest that a follow-up murine typhus serological or molecular test should be performed approximately 1–2 weeks after the initial test in the patient who is not responding to therapy. Physicians should also recognise the time when to search for a diagnosis of coinfection to treat the patient promptly and effectively.¹²

Learning points

- ▶ Murine typhus infection in Thailand is unaware.
- ▶ Searching for coinfection at the right time can help better the diagnosis and treatment for the patients.
- ▶ This article emphasises the significance of the followed-up test after 1–2 weeks after the initial test in order to avoid the pitfall of assuming that an initial negative murine typhus serological test does not rule out the absence of the diseases in a febrile patient.

Contributors CM wrote the proposal, collected the data, wrote the manuscript and also read the final draft. WP supervised the overall work and read the final draft of the manuscript.

Funding The authors have not declared a specific grant for this research from any funding agency in the public, commercial or not-for-profit sectors.

Competing interests None declared.

Patient consent Obtained.

Provenance and peer review Not commissioned; externally peer reviewed.

Open access This is an open access article distributed in accordance with the Creative Commons Attribution Non Commercial (CC BY-NC 4.0) license, which permits others to distribute, remix, adapt, build upon this work non-commercially, and license their derivative works on different terms, provided the original work is properly cited and the use is non-commercial. See: <http://creativecommons.org/licenses/by-nc/4.0/>

REFERENCES

- 1 Epelboin L, Hanf M, Dussart P, *et al.* Is dengue and malaria co-infection more severe than single infections? A retrospective matched-pair study in French Guiana. *Malar J* 2012;11:142.
- 2 Bhat R, Kodan P, Shetty MA. Medley of infections-a diagnostic challenge. *Asian Pac J Trop Biomed* 2015;5:418–20.
- 3 van der Vaart TW, van Thiel PP, Juffermans NP, *et al.* Severe murine typhus with pulmonary system involvement. *Emerg Infect Dis* 2014;20:1375–7.
- 4 Malheiro L, Ceia F, Alves J, *et al.* Severe interstitial pneumonia due to murine typhus in a patient returning from Bali. *IDCases* 2017;9:17–20.
- 5 D'Silva A, Akroyd R, Brooks T, *et al.* Of mice and men. *BMJ Case Rep* 2014;2014:bcr2013200938.
- 6 Kelly DJ, Chan CT, Paxton H, *et al.* Comparative evaluation of a commercial enzyme immunoassay for the detection of human antibody to *Rickettsia typhi*. *Clin Diagn Lab Immunol* 1995;2:356–60.
- 7 Dumler JS, Taylor JP, Walker DH. Clinical and laboratory features of murine typhus in south Texas, 1980 through 1987. *JAMA* 1991;266:1365–70.
- 8 Civen R, Ngo V. Murine typhus: an unrecognized suburban vectorborne disease. *Clin Infect Dis* 2008;46:913–8.
- 9 Singhsilarak T, Phongtananant S, Jenjittikul M, *et al.* Possible acute coinfections in Thai malaria patients. *Southeast Asian J Trop Med Public Health* 2006;37:1–4.
- 10 McGready R, Ashley EA, Wuthiekanun V, *et al.* Arthropod borne disease: the leading cause of fever in pregnancy on the Thai-Burmese border. *PLoS Negl Trop Dis* 2010;4:e888.
- 11 Teoh YT, Hii SF, Stevenson MA, *et al.* Serological evidence of exposure to *Rickettsia felis* and *Rickettsia typhi* in Australian veterinarians. *Parasit Vectors* 2017;10:1–8.
- 12 Issarangoon na ayuthaya S, Wangjirapan A, Oberdorfer P. An 11-year-old boy with *Plasmodium falciparum* malaria and dengue co-infection. *BMJ Case Rep* 2014;2014:bcr2013202998.

Copyright 2018 BMJ Publishing Group. All rights reserved. For permission to reuse any of this content visit <https://www.bmj.com/company/products-services/rights-and-licensing/permissions/>
BMJ Case Report Fellows may re-use this article for personal use and teaching without any further permission.

Become a Fellow of BMJ Case Reports today and you can:

- ▶ Submit as many cases as you like
- ▶ Enjoy fast sympathetic peer review and rapid publication of accepted articles
- ▶ Access all the published articles
- ▶ Re-use any of the published material for personal use and teaching without further permission

For information on Institutional Fellowships contact consortiasales@bmjgroup.com

Visit casereports.bmj.com for more articles like this and to become a Fellow