

Percutaneous cardiac support during myocardial infarction drastically reduces mortality: perspectives from a swine model

Maria Giovanna Trivella¹, Alessandra Piersigilli², Fabio Bernini³, Gualtiero Pelosi¹, Silvia Burchielli⁴, Stefano Pozzuoli³, Claudia Kusmic¹, Antonio L'Abbate^{1,3}

¹CNR Institute of Clinical Physiology, Pisa - Italy

²Weill Cornell Medicine, New York City, NY - USA

³Institute of Life Sciences, Scuola Superiore Sant'Anna, Pisa - Italy

⁴Fondazione Toscana Gabriele Monasterio, Pisa - Italy

Prof. Alessandra Piersigilli and Dr. Stefano Pozzuoli participated in the study during their PhD at the Scuola Superiore Sant'Anna, Pisa - Italy

ABSTRACT

Background/aims: Acute myocardial infarction (AMI) with cardiogenic shock (CS) remains the leading cause of in-hospital death in acute coronary syndromes. In the AMI-CS pig model we tested the efficacy of temporary percutaneous cardiorespiratory assist device (PCRA) in rescuing the failing heart and reducing early mortality.

Methods: In open-chest pigs we induced AMI by proximal left anterior descending coronary artery (LAD) ligation. Eight animals without PCRA (C group) were compared with 12 animals otherwise treated with PCRA (T group), starting approximately at 60 minutes post-occlusion and lasting 120-180 minutes. In 3 animals of the T group, regional myocardial oxygen content was also imaged by two-dimensional near infrared spectroscopy (2D-NIRS) with and without PCRA, before and after LAD reperfusion.

Results: All animals without PCRA died despite unrelenting resuscitation maneuvers (120 minutes average survival time). Conversely, animals treated with PCRA showed a reduction in life-threatening arrhythmia and maintenance of aortic pressure, allowing interruption of PCRA in all cases early in the experiments, with sound hemodynamics at the end of the observation period. During LAD occlusion, NIRS showed severe de-oxygenation of the LAD territory that improved with PCRA. After PCRA suspension and LAD reperfusion, the residual de-oxygenated area proved to be smaller than the initial risk area.

Conclusions: In AMI, PCRA initiated during advanced CS drastically reduced early mortality from 100% to 0% in a 4-5 hour observation period. PCRA promoted oxygenation of the ischemic area during LAD occlusion. Results support the use of PCRA as first line of treatment in AMI-CS, improving myocardial rescue and short-term survival.

Keywords: Acute myocardial infarction, Cardiac 2D NIRS imaging, Cardiogenic shock, Percutaneous cardiorespiratory assist device, Pig model

Introduction

Acute myocardial infarction (AMI) complicated by cardiogenic shock (CS) is the leading cause of in-hospital death in patients admitted for acute coronary syndromes. Among patients reaching the hospital with the diagnosis of AMI, those with

ST elevation in the anterior or antero-lateral precordial leads (STEMI anterior infarction) have the highest mortality: 8.0% as compared to 5.2% in non-STEMI, according to the National Registry of Myocardial Infarction from 1990 to 2006 (1).

These statistics keep rising despite the continuously increasing number of primary and rescue coronary angioplasties performed with associated pharmacological treatment (2, 3) of the coronary arteries, and the favorable outcome. Main causes of death are life-threatening arrhythmias, pulmonary edema and cardiogenic shock (4).

Until few years ago expert guidelines for the care of AMI-CS patients recommend early revascularization with intra-aortic balloon pump support (IABP) (5, 6). However, the actual benefit of IABP on AMI-CS-related mortality is an object of controversy (7, 8). In the IABP-SHOCK II trial, the largest controlled trial on this topic, no difference was observed

Accepted: April 27, 2017

Published online: June 6, 2017

Corresponding author:

Maria Giovanna Trivella
CNR Institute of Clinical Physiology
Via Moruzzi 1
56124, Pisa, Italy
trivella@ifc.cnr.it



in 30-day mortality in 600 patients with AMI-CS randomized to IABP or conventional treatment (9). An updated review of the Cochrane Database System concludes that although IABP may have a beneficial effect on some hemodynamic parameters, this treatment did not result in survival in infarct-related cardiogenic shock (10). Thus, the international guidelines no longer endorse the use of IABP in treating AMI-CS with a class 1 recommendation. As compared to IABP, ventricular assist devices (VADs) offer the advantages of providing greater and longer-term cardiac support and may improve outcomes when inserted early after heart failure symptoms begin (11-14).

Patients with acute myocardial infarction face a lack of oxygen in the myocardium, which in turn reduces the ejection fraction and blood/oxygen supply to the rest of the body. VADs can rapidly increase and maintain blood flow without straining the ischemic heart. Importantly, improved systemic circulation with VAD enables recovery of end-organ (i.e., brain, liver, kidney, lung) failure, following acute shock.

Accordingly, the aims of this study were i) to validate a cardiorespiratory support device made-up for percutaneous application in interventional cardiology (PCRA) in a swine model of AMI; and ii) to evaluate the protection of the device during the early phase of acute AMI.

We challenged the efficacy of PCRA in increasing survival, in the model of anterior myocardial infarction following proximal LAD ligation in the anesthetized open-chest pig. In this model, mortality has been reported to be very high due to the extent of the ischemic area and the incidence of life-threatening arrhythmias and irreversible arterial hypotension (15). We tested the efficacy of PCRA by comparing 2 groups of treated or non-treated animals, using the mortality rate during a 240-300-minute post-occlusion observation period as the primary hard end-point.

Materials and methods

Twenty farm pigs of both sexes were studied. The body weight was 38.6 ± 9.77 kg and they were 3-5 months old. Animals were randomly allocated to the control group (C group n = 8) or to the treated group (T group n = 12).

Study protocol

The study protocol was designed to compare short-term mortality in 2 groups of anesthetized, open-chest pigs with AMI-CS induced by proximal LAD ligation: i) control group ii) treated group, i.e., treated with venoarterial and oxygenator pump. The experimental session duration was scheduled as a 4-5-hour observation/treatment period following LAD occlusion. In the treated group the support device was initiated at 60-80 minutes following LAD ligation or earlier in the event that the death of the animal was judged to be imminent. The single endpoint for comparison of the 2 groups was mortality.

The study was performed according to the Guiding Principles for Research Involving Animals and Human Beings, approved by the Council of the American Physiological Society, and according to European and Italian laws and regulations (European Directives for Animal Use in Experimental Research; DL116/92, DL 26/2014). Animals were premedi-

cated with a combination of Zoletil® (10 mg/kg) and atropine (0.003 mg/kg); then anesthesia was induced with propofol (2 mg/kg intravenously [i.v.]) and maintained with 1% isoflurane in air enriched by 30%-40% oxygen. Blood pH and respiratory gas concentration were periodically controlled and adjusted as needed.

Following median sternotomy, a snare around the isolated proximal LAD was positioned, in order to occlude or open the vessel according to the study protocol phases. During the experiment we continuously monitored electrocardiogram, aortic and left ventricular pressure, and type and timing of life-threatening events, including ventricular fibrillation, cardiac arrest and electro-mechanical dissociation as well as life support interventions such as direct current (DC) shock, manual cardiac massage and dose and number of lidocaine (20 mg i.v. when needed, associated with an infusion of 1 mg/min), adrenaline (0.2 mg i.v.) administration and dopamine infusion. Cardiac output was measured by Schwan-Ganz catheter and thermodilution method (Oximetrix 3; Abbott®).

In the control group, LAD was occluded and all efforts were made to keep the animal alive as long as possible. Death was declared when the left ventricle was clearly unable to develop pressure in spite of all attempted pharmacological supports, repetitive defibrillation and prolonged manual cardiac massage. In the treated group, the onset of PCRA was scheduled at 60-80 minutes following LAD ligation or earlier in the event that the death of the animal was judged to be imminent.

Cardio-respiratory support was planned to last from 120 to 180 minutes, according to the soundness of the hemodynamics and cardiac rhythm. At the end of this period, PCRA was discontinued, the prime blood was returned back to the animal, and the observation was prolonged to challenge the reliability of the heart to sustain sound hemodynamics in the absence of artificial cardiorespiratory support.

In 3 animals of the T group, the two-dimensional near infrared spectroscopy (2D-NIRS) technique (see below) was applied along with the entire experimental protocol as above and LAD reopening (reperfusion) following PCRA discontinuation was added as a further step. At the end of the experiment, anesthetized animals were sacrificed by potassium chloride injection.

Mechanical cardiorespiratory assistance device

A prototype of a percutaneous cardiorespiratory system designed for adult human application was used. The device was characterized by a peripheral venoarterial extracorporeal circuit provided with a membrane oxygenator and a centrifugal pump in series (Stöckert®). Because the dimensions of the input and output polyurethane cannulae did not fit the animal vessels, we used the right atrium as input and the aortic arch as output sites. We assumed the results would predict the efficacy of the device applied percutaneously as first-line treatment in AMI complicated with refractory shock in humans.

Cannulation of the right atrium and of the aortic arch was performed in the T group during the preparation period before LAD occlusion. Liqueimin® (Roche) was used for anticoagulation; activated coagulation time (ACT) was periodically controlled (Hemochron®; Accriva Diagnostics).

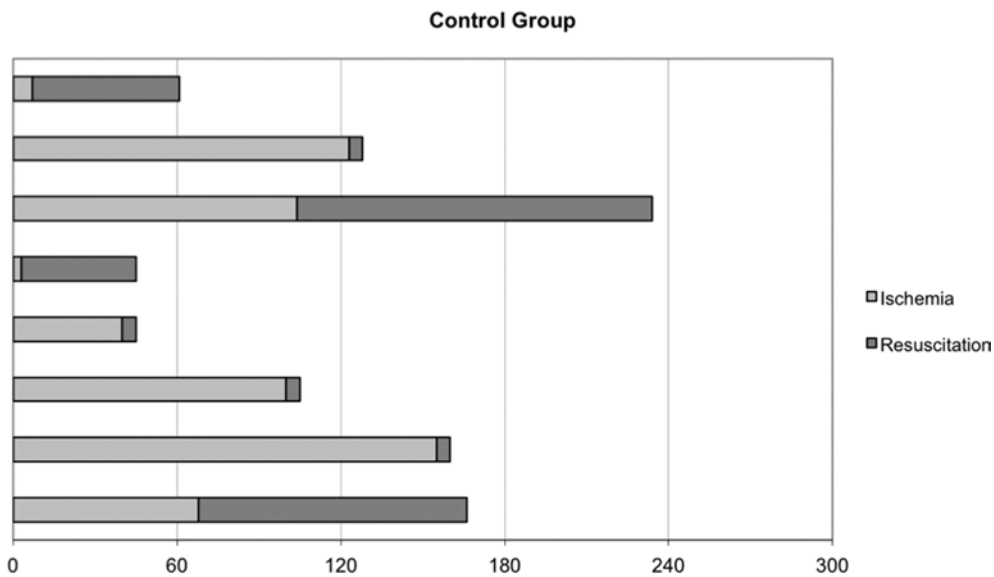


Fig. 1 - Time (minutes) to death following proximal left anterior descending coronary artery (LAD) occlusion in control group (n = 8). Time 0 corresponds to LAD occlusion. Dark segments (resuscitation) indicate the time-periods spent in repeated manual cardiac massage in an unsuccessful attempt to restore left ventricular systolic pressure. Mortality rate was 100%, average survival time was 60 minutes (max. 125 minutes) without resuscitation and 120 minutes (max. 235 minutes) including resuscitation time.

Two-dimensional near-infrared spectroscopy cardiac imaging

We used an optical near-infrared (NIR) spectroscopic 2D imaging camera, developed by the NRC Institute for Biodiagnostics of Winnipeg, Manitoba, Canada (16, 17). The NIRS technique capitalizes on the different NIR absorbance spectra of oxygenated versus deoxygenated hemoglobin (HbO₂ versus Hb) and oxygenated versus deoxygenated myoglobin (MbO₂ vs. Mb) and offers the possibility of real-time imaging of their distribution in the 3-4-mm thick myocardium of the imaged heart (18-20). The acquisition time for cardiac imaging was 45 seconds. Separate images of HbO₂ + MbO₂, of Hb + Mb and of Hb + Mb percent oxygen saturation were obtained.

Endpoints

For group comparison, death within the 4-5 hours of observation following LAD occlusion was considered as the primary end-point.

Statistical analysis

Changes in the hemodynamic parameters, i.e., left ventricular pressure and positive and negative dp/dt, during the different phases of the protocol were analyzed by paired t-test. A p value of <0.05 was considered significant.

Results

Control group

The cardiac output values in the baseline condition ranged from 2.12 to 4.39 L/min, with an evident and immediate reduction after LAD occlusion (range of measurements 1.04-2.9 L/min made in 5 animals, because of hemodynamic instability in the other 3). Mortality in the 8 control animals was 100% after 240 minutes of LAD occlusion, despite

unrelenting attempts at resuscitation (Fig. 1). Deaths occurred within 60 minutes in 3 animals, between 60 to 120 minutes in 1 and within 120 to 235 minutes in the remaining 3. Average time to death following LAD occlusion was 120 minutes, including resuscitation time. Life-threatening arrhythmias began within the first 10 minutes of ischemia in all but 1 animal. A severe heart failure with repeated life-threatening arrhythmias and cardiac arrest periods after defibrillation occurred in all animals, showing the incapacity of the heart to develop pressure and cardiac output.

Treated group

Cardiac output values in the T group ranged from 2.79 to 5.20 L/min, with an immediate reduction after LAD occlusion (range of measurements 1.7-2.84 L/min made in 5 animals, because of hemodynamic instability in the others). As compared to the C group, no significant differences were found in the pre-PCRA period in number, type and onset of life threatening arrhythmias as well as in the adoption of resuscitation maneuvers. On the average, PCRA was initiated following 80 minutes of LAD ligation. In 3 animals, PCRA was activated earlier due to unresponsive cardiac failure. With the cardiac assistance by the support device, all animals showed a progressive reduction of arrhythmic life-threatening events, without periods of cardiac arrest. The cardiac output measurements during cardiorespiratory support ranged from 2.3 to 3.38 L/min. As shown in Figure 2, all animals were alive at the end of the observation period (mean 240 minutes, range 205-295 minutes). During the last 40-60 minutes of PCRA no animal experienced life-threatening arrhythmias while all showed sound hemodynamic values (Fig. 3).

Pump flow ranged from 350 to 800 mL/min; it was set up so as avoid suction, as the input flow was dependent on the different size of the animals.

After PCRA discontinuation, we prolonged the observation for 20 more minutes on the average (range 7-35 minutes) to assess heart capability in maintaining hemodynamics even

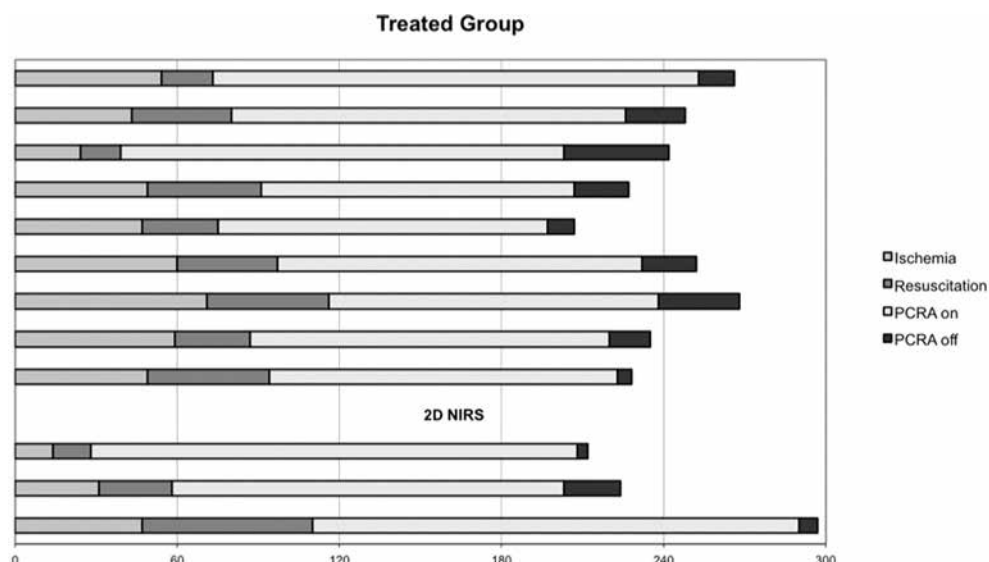


Fig. 2 - Time (minutes) to death following proximal left anterior descending coronary artery (LAD) total occlusion and the application of percutaneous cardiorespiratory assistance (PCRA) in treated group (n = 12). Time 0 corresponds to LAD occlusion. As in Figure 1, resuscitation (cardiac massage) was started when the left ventricle was no longer able to develop pressure. PCRA application restored left ventricle ability to develop pressure and all animals survived during a 205-295-minute observation period. In 3 additional animals of the treated group we performed two-dimensional near infrared spectroscopy (2D-NIRS) imaging of the LAD myocardial territory. In these animals reperfusion of the ischemic area was accomplished by LAD reopening at the end of the experiment.

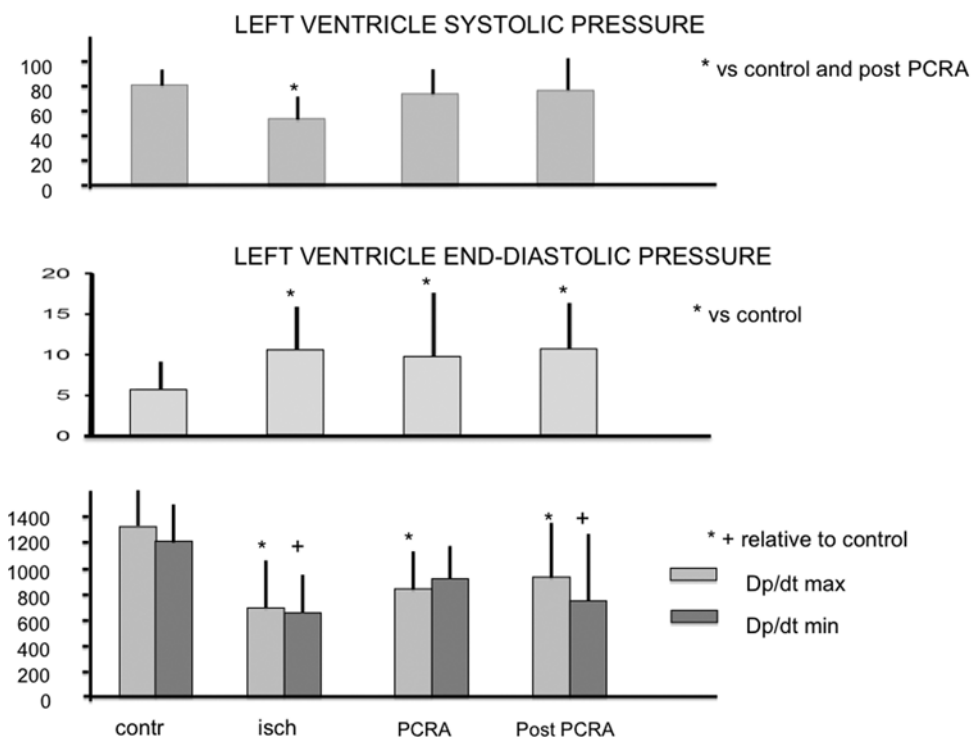


Fig. 3 - Mean \pm SD values of left ventricular systolic pressure, left ventricular diastolic pressure and positive and negative dp/dt in treated group during the different phases of the study. Values were obtained before left anterior descending coronary artery (LAD) occlusion (contr) and, in periods free of sustained arrhythmias and relatively far from life-support interventions, 30 \pm 15 minutes after LAD occlusion (isch), 30 \pm 15 minutes from onset of cardiorespiratory assistance (PCRA) and 10 \pm 5 minutes following PCRA discontinuation with LAD still occluded (post-PCRA). The resuscitation period is missing because of the absence, by definition, of developed ventricular pressure during this period.

in the absence of PCRA and with persistent LAD occlusion. In all animals hemodynamics and cardiac rhythm remained unchanged and the experiment was concluded with the animal still alive (Figs. 2 and 3). The cardiac output measurements after support discontinuation ranged from 1.1 to 3.4 L/min.

Two-dimensional near-infrared spectroscopy imaging

In 3 additional animals of the T group, we had the opportunity of obtaining 2D-NIRS images of the anterior portion of the exposed heart. Imaging was obtained in all phases of the study including pre-occlusion control condition, LAD

occlusion, PCRA, post-PCRA with LAD still occluded, and finally LAD opening (reperfusion).

Using this technique, color-coded de-oxygenation (blue) and oxygenation (red) of the LAD territory can be documented during short-time LAD occlusion and reperfusion, respectively (19). Figure 4 shows the image sequence from 1 animal: (A) baseline; (B) 2 minutes after LAD occlusion to assess the risk area; (C) 60 minutes after occlusion, immediately before PCRA; (D) during PCRA; (E) after PCRA discontinuation with LAD still closed; or (F) opened (reperfusion). A marked de-oxygenation of the LAD area (blue color) became evident after a few minutes of LAD occlusion and progressively



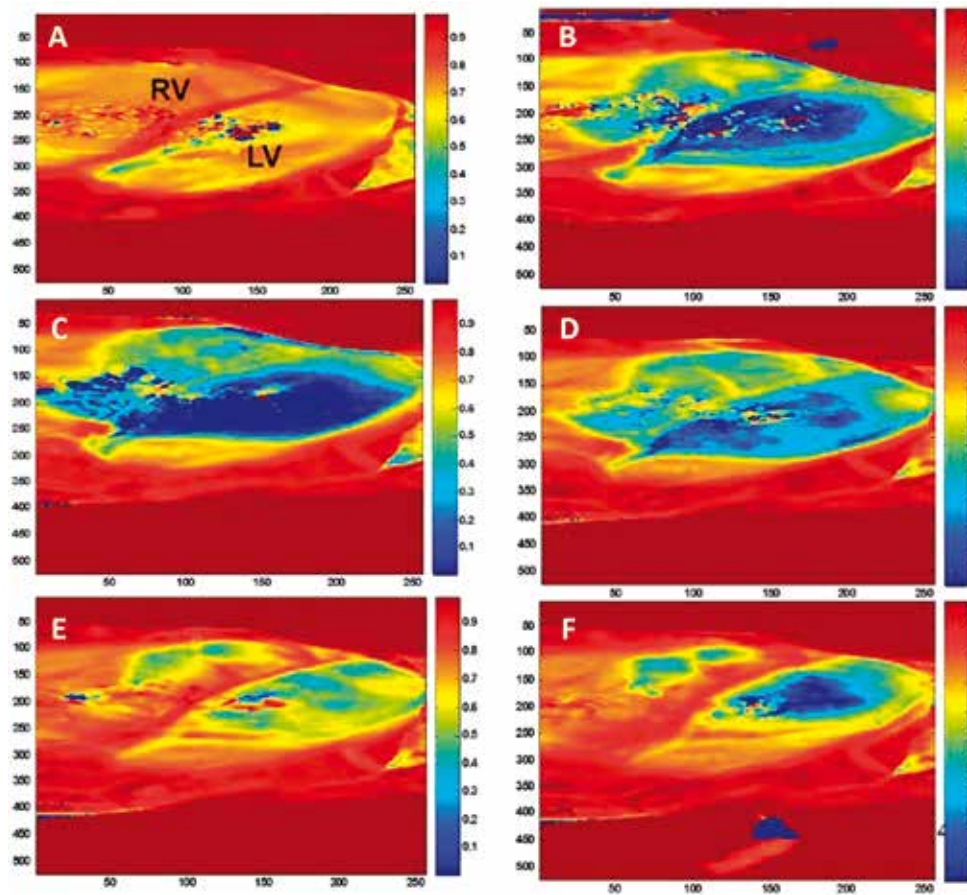


Fig. 4 - 2D-NIRS imaging of HbO₂ & MbO₂ content of exposed superficial myocardium. (A). Control condition: RV = right ventricle; LV = left ventricle. Predominant red color indicates heart is well oxygenated. (B). 2-minute left anterior descending coronary artery (LAD) occlusion: the blue area indicates deoxygenated myocardium in the LAD territory and delineates the 'risk area'. (C). 60 minutes following LAD occlusion, just before the onset of cardiorespiratory assistance: the blue area expands to the anterior right ventricular wall. (D). Following 60 minutes of cardiorespiratory assistance (PCRA) the reduction of de-oxygenation signal in the LAD territory becomes evident. (E). After PCRA discontinuation and immediately after LAD reopening (reperfusion): only mildly oxygenated (green) areas are visible during reactive hyperemia. (F). Final picture at 10 minutes from reperfusion: residual deoxygenated area following 3 hours of LAD occlusion proves to be much smaller than the 'risk area' outlined in the initial minutes of ischemia (see frame (B)).

worsened with time. When PCRA was established, along with a visual decrease in heart volume and increased aortic pressure, tissue oxygenation improved despite the persisting LAD blockage (E). Following PCRA discontinuation, reperfusion occurred in all the 3 animals by LAD reopening. Myocardial oxygenation immediately increased in the entire LAD territory (reactive hyperemia) (F) to decrease thereafter in a core region of the anterior ventricular surface, which was markedly smaller than the 'area at risk', delineated at the beginning of the ischemic period.

Discussion

AMI-CS is the leading cause of in-hospital death for patients admitted with acute coronary syndromes. As previously mentioned, until recently the guidelines for the care of AMI-CS patients recommend early revascularization with IABP support (5, 6). However, recent reviews of the available clinical studies stress the lack of evidence of IABP benefit in AMI-CS (9, 10).

Ventricular mechanical assistance represents a valid alternative to IABP as it provides greater and long-lasting cardiac support. Experience with the use of VAD in patients with AMI-CS is limited (21-23). In recent years, surveys on VAD support in the setting of AMI cardiogenic shock have produced in-hospital mortality rates of 24% to 44%, even if with conflicting reports (24-31). Although these series are small, the reduction in mortality compared with conventional therapy

appears significant. Comparative studies show superior hemodynamic support by VAD as compared with standard IABP treatment (32-34). This evidence raises the possibility for a definitive role of VADs in the treatment of AMI-CS.

One of the drawbacks of VADs is their invasiveness (i.e., apical cannulation of left ventricle or micro-pump in the left ventricle or aorta, etc.). To overcome this limitation, percutaneous devices have been developed with extracorporeal pump – with or without oxygenator – for temporary support that are easy to apply. These are impelling for rescue intervention in early-stage AMI-CS or even as a bridge to coronary revascularization.

The aim of this study was thus to investigate the feasibility and putative benefit of the percutaneous approach using the venoarterial extracorporeal circuit enriched with a blood oxygenator in the early treatment of cardiogenic shock due to proximal LAD occlusion and large myocardial infarction in the anesthetized open-chest pig. The choice of this open-chest model was dictated by the reproducibility of infarct size (surgical ligation of the proximal LAD), the consistent occurrence of cardiac shock with a high mortality rate to compare with any testing proposal, and the duration of the experimental protocol that was close enough to the clinical emergency of severe AMI with CS.

The extracorporeal system used for the study was the prototype of a percutaneous cardiorespiratory system designed for adult human application. The device is characterized by a peripheral venoarterial extracorporeal circuit provided with

a membrane oxygenator and a centrifugal pump in series (Stöckert®). The acronym PCRA is the English translation of the Italian project acronym on device validation designed for cardiorespiratory support in AMI.

As expected, results in the control group confirmed the severity of the experimental model with high-grade heart failure, repeated life-threatening arrhythmias and ultimately the incapacity of the heart to develop pressure and cardiac output, with a mortality rate of 100% despite all attempts at resuscitation, including direct massage of the exposed heart.

Conversely, the treated group showed progressive recovery after the support. A progressive reduction of incidence and severity of arrhythmias, without periods of cardiac arrest, and ultimately the capacity to develop pressure and cardiac output after 2 hours of PCRA were observed.

The system was designed for percutaneous interventional procedures in humans. Its central surgical application in our study, required by interspecies (pig vs. human) size differences, was able to drastically reduce death and major adverse cardiac events even in the presence of sub-maximal flow rates.

In 3 additional animals, we had the opportunity to test the 2D-NIRS imaging of the exposed heart during the entire protocol study as well as during the eventual reopening of the LAD. The aim of using 2D-NIRS was to get information on changes in microvascular coronary circulation and tissue oxygenation of the ischemic region during temporary PCRA support, after its discontinuation and finally after reperfusion.

2D-NIRS imaging suggests the beneficial effect of PCRA in terms of metabolic amelioration of the ischemic tissue even in the absence of reperfusion. In particular, a better oxygenation of the peripheral infarct area might be related to ventricle volume unloading, including right ventricle, and maintenance of coronary perfusion pressure. It appears important to underline the limited extension of the final de-oxygenated area as compared with the so-called risk area, which was well delineated at the onset of the ischemic process, as one of the more crucial prerequisites for containing ventricular remodeling.

Study limitations

Some aspects of our study deserve a few comments. The anesthetized open-chest animal model we studied is certainly far from the clinical model of early acute myocardial infarction with cardiogenic shock. However, the open chest approach, as compared to LAD occlusion by catheter-induced thrombosis or balloon inflation, had the advantage of a very reproducible infarct induction (in terms of location, size, time of onset, and severity), of a continuous direct inspection of the heart and the possibility of more effective resuscitation maneuvers.

Due to different fitting dimensions of the input and output polyurethane cannulae to the animal peripheral vessels, we were forced to use the right atrium as input and the aortic arch as output sites. We assumed in the present study that the results of such a circulatory arrangement would be able to predict the results of the percutaneous application of the device in AMI-CS in humans. However, due to the different effects on cardiac loads of the different input and output sites of the extracorporeal circuit, the reliability of such an assumption should be verified by later ad hoc studies.

The times and durations of PCRA were dictated by their compatibility with the timing of the experimental laboratory facilities and were contained to the minimum time necessary to show a clear-cut difference as compared with the control conditions.

2D-NIRS cardiac imaging still has important limitations. This technique provides qualitative and quantitative information on myocardial O₂ content (HbO₂ + MbO₂ vs Hb + Mb) limited to the visible portion of the exposed heart and to a few millimeters deep into the ventricular wall. As such, the application in clinical cardiology can be foreseen only during open-chest surgery. However, our use of NIRS imaging in the study had an exclusively pathophysiologic significance.

Conclusions

The aim of our study was to investigate the putative benefit of a percutaneous circulatory and respiratory assistance (PCRA) device for treating cardiogenic shock and reducing mortality during severe acute infarction. In a pig model of AMI, PCRA was documented as being able to drastically reduce mortality and to serve as an effective bridge to reperfusion. In addition, pivotal NIRS imaging of the LAD area during ongoing myocardial infarction, due to complete LAD ligation, suggests that PCRA reduces the extension and the severity of myocardial de-oxygenation. The mechanism(s) of such an effect remain(s) to be elucidated. In conclusion, our results in the swine model suggest that unloading of the right heart and pulmonary circulation during the early stage of AMI represents an interventional tool capable of limiting ischemic cardiac failure, life-threatening arrhythmias and death.

Acknowledgments

The authors wish to express their gratitude to Luigi Taddei, Doretta Magnozzi and Graziano Barsotti for their valuable support during the experimental sessions and to Dr. Lorenzo Leonardi from IBD of Winnipeg, Manitoba, Canada, for his technical assistance and valuable suggestions.

Disclosures

Financial support: This study was supported by a grant from the Italian Ministry of Education and Research (MIUR) assigned to the Institute of Clinical Physiology - CNR, Pisa, Italy (FIRB - Assistenza Percutanea Cardiorespiratoria [APEC] RBNE01FK3H_001). Partial support was received from the Italian Ministry of Education, University and Research (FIRB Italy/Canada RBIN06RYWX - Nuove tecniche di imaging per lo studio e il trattamento della patologia cardiaca). Conflict of interest: None of the authors has financial interest related to this study to disclose.

References

1. Rogers WJ, Frederick PD, Stoehr E, et al. Trends in presenting characteristics and hospital mortality among patients with ST elevation and non-ST elevation myocardial infarction in the National Registry of Myocardial Infarction from 1990 to 2006. *Am Heart J.* 2008;156(6):1026-1034.
2. Stone GW. Angioplasty strategies in ST-segment-elevation myocardial infarction: part I: primary percutaneous coronary intervention. *Circulation.* 2008;118(5):538-551.

3. Stone GW. Angioplasty strategies in ST-segment-elevation myocardial infarction: part II: intervention after fibrinolytic therapy, integrated treatment recommendations, and future directions. *Circulation*. 2008;118(5):552-566.
4. Buller CE, Fu Y, Mahaffey KW, et al. ST-segment recovery and outcome after primary percutaneous coronary intervention for ST-elevation myocardial infarction: insights from the Assessment of Pexelizumab in Acute Myocardial Infarction (APEX-AMI) trial. *Circulation*. 2008;118(13):1335-1346.
5. Antman EM, Anbe DT, Armstrong PW, et al. ACC/AHA guidelines for the management of patients with ST-elevation myocardial infarction executive summary: a report of the American College of Cardiology/American Heart Association Task Force on Practice Guidelines (Writing Committee to Revise the 1999 Guidelines for the Management of Patients With Acute Myocardial Infarction). *Circulation*. 2004;110(5):588-636.
6. Wijns W, Kolh P, Danchin N, et al. Task Force on Myocardial Revascularization of the European Society of Cardiology (ESC) and the European Association for Cardio-Thoracic Surgery (EACTS); European Association for Percutaneous Cardiovascular Interventions (EAPCI). Guidelines on myocardial revascularization. *Eur Heart J*. 2010;31(20):2501-2555.
7. Sjaauw KD, Engström AE, Vis MM, et al. A systematic review and meta-analysis of intra-aortic balloon pump therapy in ST-elevation myocardial infarction: should we change the guidelines? *Eur Heart J*. 2009;30(4):459-468.
8. Zeymer U, Bauer T, Hamm C, et al. Use and impact of intra-aortic balloon pump on mortality in patients with acute myocardial infarction complicated by cardiogenic shock: results of the Euro Heart Survey on PCI. *EuroIntervention*. 2011;7(4):437-441.
9. Thiele H, Zeymer U, Neumann FJ, et al. IABP-SHOCK II Trial Investigators. Intraaortic balloon support for myocardial infarction with cardiogenic shock. *N Engl J Med*. 2012;367(14):1287-1296.
10. Unverzagt S, Buerke M, de Waha A, et al. Intra-aortic balloon pump counterpulsation (IABP) for myocardial infarction complicated by cardiogenic shock. *Cochrane Database Syst Rev*. 2015;3(3):CD007398.
11. Dang NC, Topkara VK, Leacche M, John R, Byrne JG, Naka Y. Left ventricular assist device implantation after acute anterior wall myocardial infarction and cardiogenic shock: a two-center study. *J Thorac Cardiovasc Surg*. 2005;130(3):693-698.
12. Burkhoff D, Cohen H, Brunckhorst C, O'Neill W. for the Tandem-Heart Investigators Group. A randomized multicenter clinical study to evaluate the safety and efficacy of the Tandem-Heart percutaneous ventricular assist device versus conventional therapy with intraaortic balloon pumping for treatment of cardiogenic shock. *Am Heart J*. 2006;152(3):469. e1-469.e8.
13. Aggarwal S, Slaughter MS. Acute myocardial infarction complicated by cardiogenic shock: role of mechanical circulatory support. *Expert Rev Cardiovasc Ther*. 2008;6(9):1223-1235.
14. Cheng JM, den Uil CA, Hoeks SE, et al. Percutaneous left ventricular assist devices vs. intra-aortic balloon pump counterpulsation for treatment of cardiogenic shock: a meta-analysis of controlled trials. *Eur Heart J*. 2009;30(17):2102-2108.
15. Munz MR, Faria MA, Monteiro JR, Águas AP, Amorim MJ. Surgical porcine myocardial infarction model through permanent coronary occlusion. *Comp Med*. 2011;61(5):445-452.
16. Jackson M, Sowa MG, Mantsch HH. Infrared spectroscopy: a new frontier in medicine. *Biophys Chem*. 1997;68(1-3):109-125.
17. Leonardi L, Sowa MG, Payette JR, Mantsch HH. Near-infrared spectroscopy and imaging: a new approach to assess burn injuries. *Am Clin Lab*. 2000;19(8):20-22.
18. Nighswander-Rempel SP, Anthony Shaw R, Mansfield JR, Hewko M, Kupriyanov VV, Mantsch HH. Regional variations in myocardial tissue oxygenation mapped by near-infrared spectroscopic imaging. *J Mol Cell Cardiol*. 2002;34(9):1195-1203.
19. Kupriyanov VV, Nighswander-Rempel S, Xiang B. Mapping regional oxygenation and flow in pig hearts in vivo using near-infrared spectroscopic imaging. *J Mol Cell Cardiol*. 2004;37(5):947-957.
20. Kupriyanov VV, Manley DM, Xiang B. Detection of moderate regional ischemia in pig hearts in vivo by near-infrared and thermal imaging: effects of dipyridamole. *Int J Cardiovasc Imaging*. 2008;24(1):113-123.
21. Van de Werf F, Bax J, Betriu A, et al. ESC Committee for Practice Guidelines (CPG). Management of acute myocardial infarction in patients presenting with persistent ST-segment elevation: the Task Force on the Management of ST-Segment Elevation Acute Myocardial Infarction of the European Society of Cardiology. *Eur Heart J*. 2008;29(23):2909-2945.
22. Fincke R, Hochman JS, Lowe AM, et al. SHOCK Investigators. Cardiac power is the strongest hemodynamic correlate of mortality in cardiogenic shock: a report from the SHOCK trial registry. *J Am Coll Cardiol*. 2004;44(2):340-348.
23. Minha S, Barbash IM, Dvir D, et al. Correlates for mortality in patients presented with acute myocardial infarct complicated by cardiogenic shock. *Cardiovasc Revasc Med*. 2014;15(1):13-17.
24. Werdan K, Gielen S, Ebelt H, Hochman JS. Mechanical circulatory support in cardiogenic shock. *Eur Heart J*. 2014;35(3):156-167.
25. Wohlschlaeger J, Schmitz KJ, Schmid C, et al. Reverse remodeling following insertion of left ventricular assist devices (LVAD): a review of the morphological and molecular changes. *Cardiovasc Res*. 2005;68(3):376-386.
26. Henriques JP, Rummelink M, Baan J Jr, et al. Safety and feasibility of elective high-risk percutaneous coronary intervention procedures with left ventricular support of the Impella Recover LP 2.5. *Am J Cardiol*. 2006;97(7):990-992.
27. Leshnower BG, Gleason TG, O'Hara ML, et al. Safety and efficacy of left ventricular assist device support in postmyocardial infarction cardiogenic shock. *Ann Thorac Surg*. 2006;81(4):1365-1370, discussion 1370-1371.
28. Sjaauw KD, Konorza T, Erbel R, et al. Supported high-risk percutaneous coronary intervention with the Impella 2.5 device the Europella registry. *J Am Coll Cardiol*. 2009;54:2430-4.
29. Ferreira JL, Gómez-Hospital JA, Cequier AR, et al. Use of Impella Recover LP 2.5 in elective high risk percutaneous coronary intervention. *Int J Cardiol*. 2010;145(2):235-237.
30. Sjaauw KD, Rummelink M, Baan J Jr, et al. Left ventricular unloading in acute ST-segment elevation myocardial infarction patients is safe and feasible and provides acute and sustained left ventricular recovery. *J Am Coll Cardiol*. 2008;51(10):1044-1046.
31. Gilotra NA, Stevens GR. Temporary mechanical circulatory support: a review of the options, indications, and outcomes. *Clin Med Insights Cardiol*. 2015;8(Suppl 1):75-85.
32. Seyfarth M, Sibbing D, Bauer I, et al. A randomized clinical trial to evaluate the safety and efficacy of a percutaneous left ventricular assist device versus intra-aortic balloon pumping for treatment of cardiogenic shock caused by myocardial infarction. *J Am Coll Cardiol*. 2008;52(19):1584-1588.
33. Dangas GD, Kini AS, Sharma SK, et al. Impact of hemodynamic support with Impella 2.5 versus intra-aortic balloon pump on prognostically important clinical outcomes in patients undergoing high-risk percutaneous coronary intervention (from the PROTECT II randomized trial). *Am J Cardiol*. 2014;113(2):222-228.
34. Negi SI, Sokolovic M, Koifman E, et al. Contemporary Use of Veno-Arterial Extracorporeal Membrane Oxygenation for Refractory Cardiogenic Shock in Acute Coronary Syndrome. *J Invasive Cardiol*. 2016;28(2):52-57.