

## Case Report

# Bronchial Leech Infestation in a 15-Year-Old Female

Mohammad Ashkan Moslehi,<sup>1</sup> Mohammad Hadi Imanieh,<sup>2</sup> and Ali Adib<sup>3</sup>

<sup>1</sup>*Pediatric Pulmonology Division, Namazi Hospital, Shiraz University of Medical Sciences, Shiraz, Iran*

<sup>2</sup>*Department of Pediatric Gastroenterology, Shiraz University of Medical Sciences, Shiraz, Iran*

<sup>3</sup>*Student Research Committee, Shiraz University of Medical Sciences, Shiraz, Iran*

Correspondence should be addressed to Ali Adib; aliadibmail@gmail.com

Received 16 July 2016; Revised 4 September 2016; Accepted 7 September 2016

Academic Editor: Nina L. Shapiro

Copyright © 2016 Mohammad Ashkan Moslehi et al. This is an open access article distributed under the Creative Commons Attribution License, which permits unrestricted use, distribution, and reproduction in any medium, provided the original work is properly cited.

Foreign body aspiration (FBA) is a common incidence in young children. Leeches are rarely reported as FBA at any age. This study describes a 15-year-old female who presented with hemoptysis, hematemesis, coughs, melena, and anemia seven months prior to admission. Chest X-ray showed a round hyperdensity in the right lower lobe. A chest computed tomography (CT) demonstrated an area of consolidation and surrounding ground glass opacities in the right lower lobe. Hematological investigations revealed anemia. Finally, bronchoscopy was performed and a 5 cm leech was found within the right B<sub>7-8</sub> bronchus and removed by forceps and a Dormia basket.

## 1. Introduction

Foreign body aspiration (FBA) is a common life threatening event among children and mostly occurs between one and four years of age [1]. The clinical presentations can include persistent cough, dyspnea, choking, cyanosis, epistaxis, and hemoptysis [2].

Flexible bronchoscopy is the most sensitive and specific procedure for diagnosis of FBA [3]. Most FBAs are secondary to foods (seeds, nuts, beans, or fruit parts) or inorganic material including plastic and metallic objects [4]. However, leeches are rarely reported as FBA [5–7]. Leeches are blood sucking annelids. Leech infestation (hirudiniasis) can occur internally secondary to accidental ingestion from drinking from or swimming in contaminated water [8]. In this case report, we report a girl with bronchial hirudiniasis.

## 2. Case Presentation

A 15-year-old female was admitted to Namazi Hospital in Shiraz (southern Iran) in January 2015. She complained of occasional hemoptysis, hematemesis, coughing, vomiting, epistaxis, and melena approximately seven months prior to admission. She had a history of anemia that did not improve

with ferrous sulfate supplementation. On physical examination, she was pale and afebrile. Fine crackles in the right lower lobe were present on pulmonary auscultation. Her abdomen was soft without organomegaly. She received octreotide and pantoprazole due to suspicion of gastrointestinal bleeding.

On admission, laboratory results revealed normocytic anemia (Table 1).

In stool exam, occult blood was 3+ and occult parasite was negative. Urine analysis showed normal values. Sputum examination for acid fast bacilli was negative.

Chest X-ray showed a round hyperdensity in the right lower lobe (Figure 1). In abdomen and pelvic ultrasonography, the liver and spleen were normal in size and parenchyma. Gastrointestinal endoscopy revealed normal esophagus, stomach, and duodenum mucosa. Chest ultrasonography showed a minimal amount of free fluid in the right plural space. Spiral computed tomography (CT) scan with contrast of the chest and mediastinum was performed and demonstrated an area of consolidation and surrounding ground glass opacity in the right lower lobe (Figure 2). It also showed a filling defect in a segmental branch of the right bronchus suspicious for a clot, as well as bilateral reactive axillary lymph nodes.

TABLE 1: Laboratory results at admission and one month later.

Laboratory results	Admission	One-month follow-up
Hemoglobin (g/dL)	7.9	11.8
Red blood cell (/mm <sup>3</sup> )	2750000	3950000
Mean corpuscular volume (fl)	82.9	85
White blood cell (/mm <sup>3</sup> )	6900	5800
Neutrophils (%)	66.4	57
Lymphocytes (%)	28.1	37.9
Mixed (%)	5.5	5.1
Platelet (mm <sup>3</sup> )	241000	313000
Prothrombin time (sec)	14.5	12.7
International normalized ratio	1.21	1
Partial thromboplastin time (sec)	27	25
Erythrocyte sedimentation rate (mm/hr)	23	
Blood urea nitrogen (mg%)	13.5	
Creatinine (mg%)	0.6	
C-reactive protein (mg/dL)	3.9 (negative)	

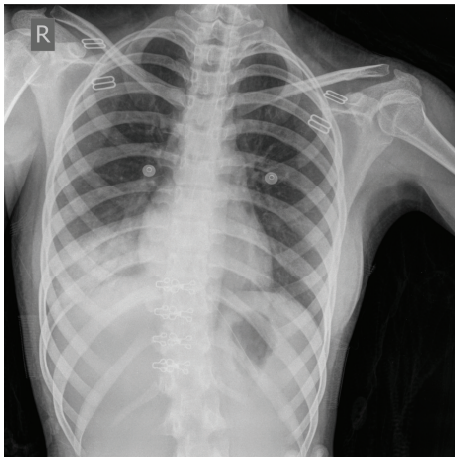


FIGURE 1: PA chest X-ray demonstrating right lower lobe opacity.

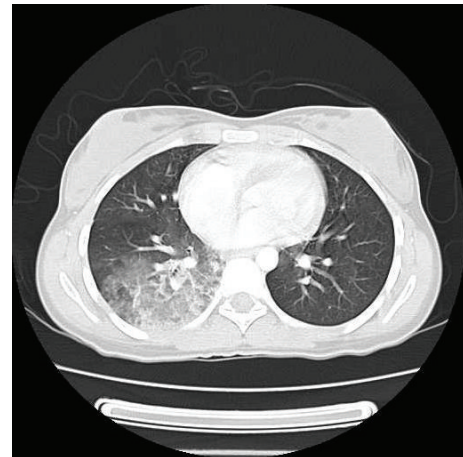

FIGURE 2: Spiral CT scan of the chest demonstrates an area of consolidation and surrounding ground glass opacity in the right lower lobe.

Because FBA was suspected, a flexible bronchoscopy under general anesthesia was performed. We sprayed lidocaine on the patient's vocal cords. A 5 cm worm-like undulating foreign body was found within the right lower lobe anteromedial bronchus (B<sub>7,8</sub>) (Figure 3). Also, there were some blood clots in the right mainstem bronchus (B<sub>7</sub>). We sprayed lidocaine on the worm to help detaching it. While trying to remove the worm by forceps, it ruptured and the leech's sucker remained attached to the mucosa. Next, the involved bronchus was washed with hypertonic saline (3%) solution to help removing the attached segment. A Dormia basket was passed through the remaining worm particle; it was then closed. After that, Dormia basket and the bronchoscope tube were removed. Figure 4 shows B<sub>8</sub> bronchus after complete removal of the leech. The animal's particle and the bronchoscopic tissue forceps biopsy were sent to the pathology lab, which confirmed that the foreign body was a leech. Figure 5 shows the leech's body after removal.

### 3. Follow-Up

Repeat flexible bronchoscopy a month later revealed no leech, mass, or blood clot. Hematologic studies were repeated and her anemia was resolved (Table 1).

### 4. Discussion

Leeches are hermaphroditic parasites which live on blood. Leeches have been used for medical purposes for many centuries for a variety of conditions including dermatological diseases, reproductive system problems, inflammation, and venous congestion [9]. However, leeches can also cause disease such as internal hirudiniasis that may present with cough, hemoptysis, epistaxis, hematemesis, melena, dysphagia, hoarseness, and dyspnea [10]. The diagnosis is made

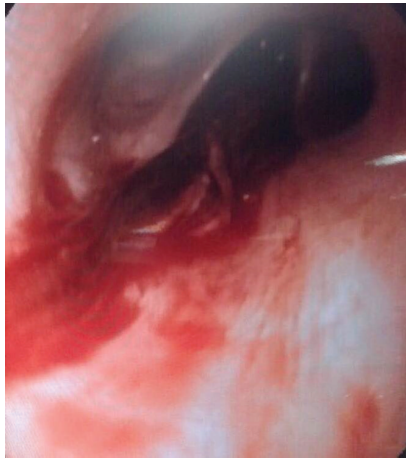

FIGURE 3: Image capture of the ruptured leech completely obstructing the right lower lobe bronchus ( $B_8$ ).

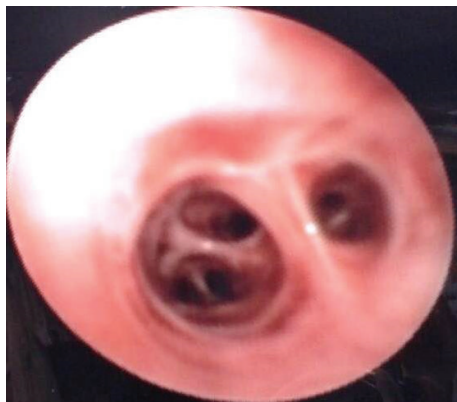

FIGURE 4: Right lower lobe bronchus ( $B_8$ ) following immediate removal of the leech.

sooner if the history includes drinking from infested waters, but in our case she reported to us that she drank from ab anbar (a traditional source of drinking water), after hirudiniasis was confirmed. Since our patient's clinical manifestation (hematemesis, vomiting, and melena) was similar to gastrointestinal bleeding, her diagnosis was delayed.

Several articles reported pharyngeal, laryngeal, and nasal hirudiniasis [6, 11, 12]. There are some rare reports of vaginal and ocular hirudiniasis [13, 14]. A similar case was a 40-year-old woman from China with tracheal leech infestation [7]. She had presented with hemoptysis, dyspnea, and a foreign body sensation in her throat, and she was diagnosed with asthma first [7]. In addition, a case report described a 7-year-old male from Ethiopia in whom the leech infestation was located in the proximal trachea [5].

Leeches secrete an anticoagulant agent called hirudin which makes the wound bleeding more than expected and it may persist even after the worm is removed. Therefore, as reported previously, hirudiniasis may lead to anemia such as in our case [15]. Treatment is removal of the leech as soon as possible to prevent complications.




FIGURE 5: Leech after removal.

Because leeches attach to the mucosa by strong suction, rupture of the worm is a risk. The detachment should be done carefully. The literature suggests lidocaine spray, hypertonic saline, or vinegar to assist with leech detachment [12, 16]. In our case, although lidocaine and hypertonic saline were instilled on the leech, it ruptured while attempting to detach it from the bronchial mucosa.

In conclusion, hirudiniasis should be considered in the differential diagnosis when a patient presents with hemoptysis, cough, dyspnea, and anemia. High suspicion is warranted when the patient is from a rural area or when they provide a history of drinking water from springs or rivers.

### Competing Interests

The authors declare that they have no conflict of interests.

### Acknowledgments

The authors would like to thank Center for Development of Clinical Research of Namazi Hospital and Dr. Nasrin Shokrpour for editorial assistance.

### References

- [1] R. Grassi, A. Faggian, F. Somma, C. N. De Cecco, A. Laghi, and F. Caseiro-Alves, "Application of imaging guidelines in patients with foreign body ingestion or inhalation: literature review," *Seminars in Ultrasound, CT and MRI*, vol. 36, no. 1, pp. 48–56, 2015.
- [2] R. Samarei, "Survey of foreign body aspiration in airways and lungs," *Global journal of health science*, vol. 6, no. 7, pp. 130–135, 2014.
- [3] A. Hitter, E. Hullo, C. Durand, and C.-A. Righini, "Diagnostic value of various investigations in children with suspected foreign body aspiration: review," *European Annals of Otorhinolaryngology, Head and Neck Diseases*, vol. 128, no. 5, pp. 248–252, 2011.
- [4] A. Sahin, F. Meteroglu, S. Eren, and Y. Celik, "Inhalation of foreign bodies in children: experience of 22 years," *Journal of Trauma and Acute Care Surgery*, vol. 74, no. 2, pp. 658–663, 2013.

- [5] D. Mekonnen, "Leech infestation: the unusual cause of upper airway obstruction," *Ethiopian Journal of Health Sciences*, vol. 23, no. 1, pp. 65–68, 2013.
- [6] T. San, E. Gürkan, A. Karaaslan, and B. Erdoğan, "An unusual cause of hemoptysis: leech in the supraglottic region of the larynx," *Journal of Craniofacial Surgery*, vol. 25, no. 2, pp. 531–532, 2014.
- [7] P. Zhang, R. Zhang, J. Zou, and T. Zhu, "A rare case report of tracheal leech infestation in a 40-year-old woman," *International Journal of Clinical and Experimental Medicine*, vol. 7, no. 10, pp. 3599–3601, 2014.
- [8] S. Dutta, S. Saha, and S. Pal, "Epistaxis due to leech infestation in nose: a report of six cases and review of literature," *Indian Journal of Otolaryngology and Head & Neck Surgery*, vol. 68, no. 1, pp. 42–45, 2016.
- [9] A. M. Abdulkader, A. M. Ghawi, M. Alaama, M. Awang, and A. Merzouk, "Leech therapeutic applications," *Indian Journal of Pharmaceutical Sciences*, vol. 75, no. 2, pp. 127–137, 2013.
- [10] J. Heukelbach and U. R. Hengge, "Bed bugs, leeches and hookworm larvae in the skin," *Clinics in Dermatology*, vol. 27, no. 3, pp. 285–290, 2009.
- [11] A. Bulent, O. Ilknur, S. Beray, C. Tulin, T. Ulku, and D. Yildiz, "An unusual cause of hemoptysis in a child: live leech in the posterior pharynx," *Tropical Biomedicine*, vol. 27, no. 2, pp. 208–210, 2010.
- [12] W.-C. Chen, C.-Y. Chien, C.-H. Yang, J.-H. Li, and C.-F. Hwang, "Nasal leech infestation: report of seven leeches and literature review," *European Archives of Oto-Rhino-Laryngology*, vol. 267, no. 8, pp. 1225–1229, 2010.
- [13] Y.-C. Lee and C.-J. Chiu, "Ocular leech infestation," *Clinical Ophthalmology*, vol. 9, pp. 419–421, 2015.
- [14] S. Senthilkumaran, R. G. Menezes, S. Pant, and P. Thirumalainkolundusubramanian, "Unexpected reach of a leech," *Journal of Parasitic Diseases*, vol. 37, no. 2, pp. 291–293, 2013.
- [15] A. El Koraichi, A. Ayoubi, M. Y. Benjelloun, A. Bentalha, and S. E. El Kettani, "Melena revealing a nasopharyngeal leech: a paediatric case," *Arab Journal of Gastroenterology*, vol. 15, no. 1, pp. 36–37, 2014.
- [16] N. Askari and A. Eshaghian, "Otorrhagia bleeding due to leech bite," *Advanced Biomedical Research*, vol. 1, article 15, 2012.