

Single Case – General Neurology

Large Intraneural Ganglion Cyst in the Peroneal Nerve

Antti Pemmari^a Katri Mäkelä^a Jimi Niemi^b Tommi Kiekara^{b, c}
Sari-Leena Himanen^{a, b}

^aDepartment of Clinical Neurophysiology, Tampere University Hospital, Medical Imaging Centre and Hospital Pharmacy, Tampere, Finland; ^bFaculty of Medicine and Health Technology, Tampere University, Tampere, Finland; ^cDepartment of Radiology, Tampere University Hospital, Medical Imaging Centre and Hospital Pharmacy, Tampere, Finland

Keywords

Intraneural ganglion cyst · Electroneuromyography · Ultrasound · Peroneal nerve · Peripheral neuropathy

Abstract

A 23-year-old previously healthy male was referred to the clinical neurophysiology unit due to a relatively fast-onset paralysis of muscles of the anterior right leg. Electroneuromyography (ENMG) revealed a total denervation of the muscles innervated by the deep peroneal nerve, diminished sensory response of the superficial peroneal nerve, and partial denervation of the peroneus longus muscle. Ultrasound and magnetic resonance imaging (MRI) revealed a large fluid collection inside the common peroneal nerve, primarily suspected to be an intraneural ganglion cyst. The cyst was surgically excised, and the function of the muscles innervated by the peroneal nerve was recovering at the control ENMG 6 months later. We describe a case of a large intraneural ganglion cyst of the peroneal nerve in an otherwise healthy young male, diagnosis by ENMG, ultrasound, and MRI, as well as subsequent operative treatment. This report demonstrates the utility of nerve ultrasound in differentiating between different causes of peroneal nerve dysfunction.

© 2022 The Author(s).
Published by S. Karger AG, Basel

Antti Pemmari and Katri Mäkelä contributed equally.

Correspondence to:
Katri Mäkelä, katri.makela@tuni.fi

Introduction

An intraneural ganglion cyst is a benign mucinous cyst locating within a peripheral nerve. These underdiagnosed cysts have been documented in a wide variety of different peripheral nerves, but the common peroneal nerve makes up the vast majority of these cases; in a meta-analysis of over 600 individual reported cysts, 60.6% of the lesions were reported to be located in the common peroneal nerve [1]. Magnetic resonance imaging (MRI) is commonly used in diagnostic workup of a wide spectrum of knee-related symptoms. For intraneural ganglion cysts, the fluid content of the cyst and its location inside the nerve are diagnostic findings [2].

The intraneural ganglion cyst is thought to be caused by a microtrauma of the peroneal nerve, followed by infiltration of the synovial cells from the superior tibiofibular joint into the nerve and production of the synovial fluid [1]. Identified risk factors for cyst formation include degenerative changes in the neighboring joint [1] and direct or torsional trauma [3, 4]. Owing to the topographic distribution of fascicles of the common peroneal nerve, the fascicles of the deep peroneal nerve are usually affected more severely and prior to those of the superficial peroneal nerve [5].

Several different surgical strategies have been proposed and employed, yet microscope-assisted cyst resection has been reported to be the most popular [1]. Disconnecting the articular branch of the peroneal nerve, which is part of a standard surgical procedure, has been shown to improve the surgical outcome and to prevent recurrence [5, 6]. Wilson et al. [7] report a majority of good outcomes in a series of 65 patients with a recurrence rate of 9%, all recurrences being extraneural.

This case report demonstrates the usefulness of ultrasound in diagnosing as well as the role of surgery in treating the cause of a disabling foot drop in an otherwise healthy young patient. Permission for publication of this case report and any accompanying images was obtained from the patient.

Case Presentation

The patient is a 23-year-old male with no relevant medical history and a background as an active amateur soccer player. During a soccer game about 3 months prior to the first presentation to the clinical neurophysiology unit, the patient noticed a rapid-onset weakness of the muscles innervated by the common peroneal nerve and loss of sensation in the skin area innervated by both superficial and deep branches of the peroneal nerve. There was no history of trauma or other forthcoming predisposing factors and no relevant history of back pain.

The patient saw a primary practitioner who diagnosed a peroneal nerve palsy. The symptoms were temporarily alleviated by rest but soon worsened again to the point of an almost total foot drop. The patient was referred to a clinical neurophysiology unit for electro-neuromyography (ENMG). Upon presentation to the clinical neurophysiology unit, the patient had to use a foot drop brace for walking and had been forced to abandon soccer along with other sports.

ENMG Findings

In the ENMG examination, neurography showed a reduced superficial peroneal nerve sensory action potential amplitude that was 50% smaller compared to the symptomless side. Compound muscle action potential of the peroneal nerve could not be registered from the extensor digitorum brevis muscle. The compound muscle action potential registered from

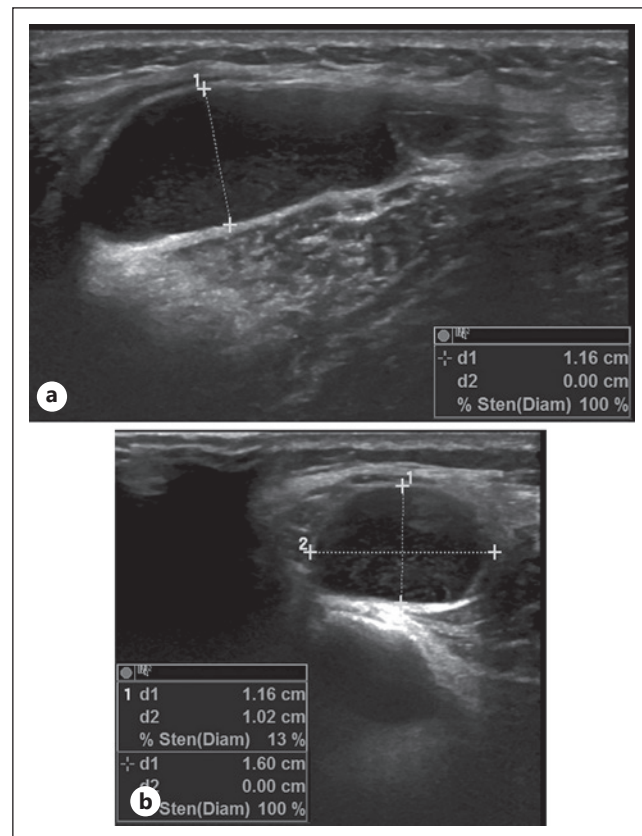


Fig. 1. Preoperative ultrasound images of the peroneal ganglion cyst. **a** Ultrasound image showing a longitudinal cross-section of the cyst, which appears as a cavity of low echogenicity, sized 1.16 cm in diameter. **b** Ultrasound image showing a parallel cross-section of the cyst.

tibialis anterior (TA) muscle showed low amplitude and slow conduction velocity (35.3 m/s) over the proximal fibular head. Myography showed a complete denervation of TA and extensor hallucis longus muscles with profuse fibrillations and positive sharp waves. Peroneus longus muscle displayed some fibrillations and positive sharp waves along with a low level of voluntary activation. All other studied muscles were intact, including the more proximal L5-innervated muscles tensor fasciae latae, semitendinosus, and biceps femoris.

Visualization of the Peroneal Nerve

In the ultrasound examination, the structure of the common peroneal nerve was normal in the popliteal fossa with a cross-sectional area of 10 mm². More distally, just before the bifurcation of the superficial peroneal nerve, prominent nerve fascicles and reduced echogenicity were discerned inside the nerve, eventually revealing an intraneural fluid collection, constructed of a multilocular cavity longer than the head of the ultrasound probe (4 cm) and up to 1.16 cm in thickness (Fig. 1).

A preoperative MRI was performed, and the findings were in accordance with ENMG and ultrasound. The anterosuperior part of the ganglion cyst was connected with the proximal tibiofibular joint. The dorsal part of the horseshoe-shaped cyst entered inside the peroneal nerve, compressing the nerve fascicles (Fig. 2). The patient was referred to the hand surgery department for microscope-assisted surgical excision of the lesion.

In the operation, the articular branch of the peroneal nerve was cut, and the intraneural fluid collection was emptied. Nerve fascicles were found to be pressed against the walls of the cavity. The walls of the cavity were not resected due to the risk of iatrogenic nerve damage. Diagnosis of intraneural ganglion cyst was later confirmed histopathologically.

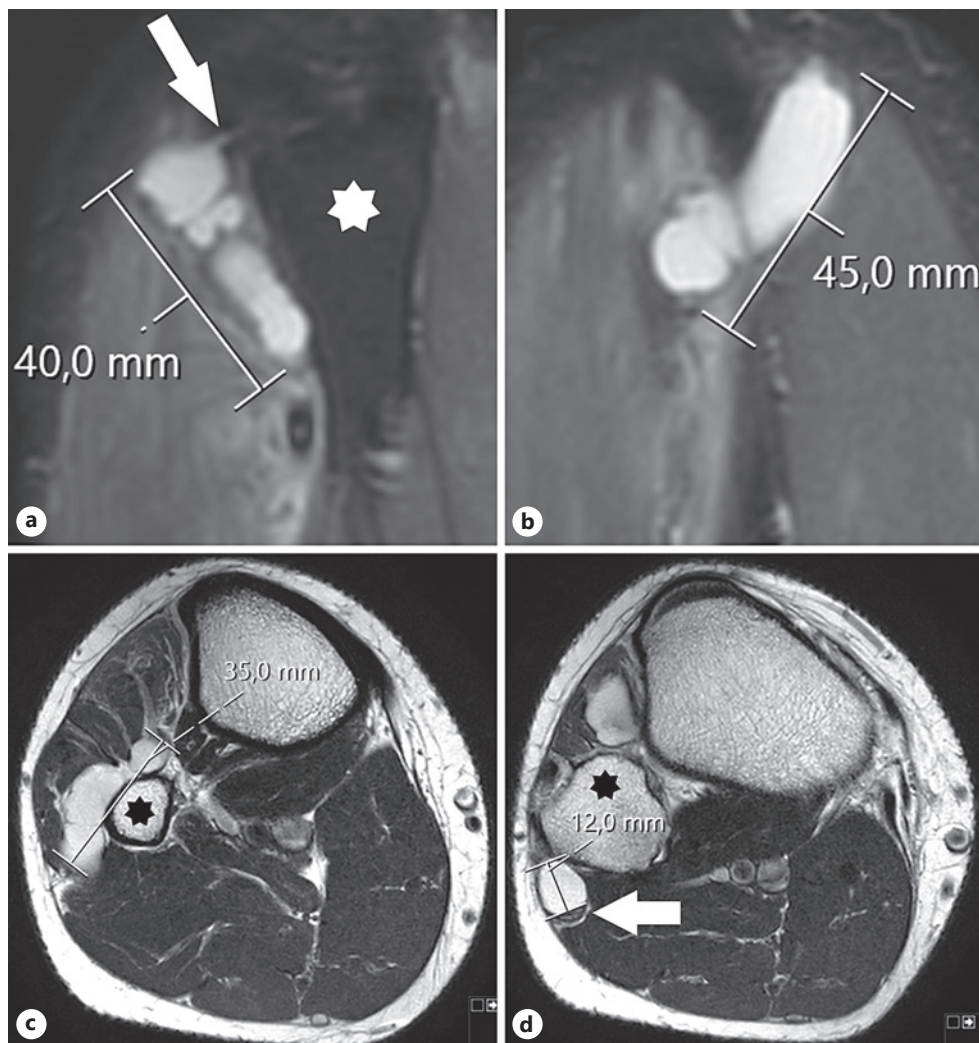


Fig. 2. Preoperative MR images of the peroneal ganglion cyst. **a** Sagittal MR image shows the anterior part of the horseshoe-shaped ganglion cyst and its connection to the proximal tibiofibular joint (white arrow). The fibula is marked with a star. **b** Sagittal MR image shows the posterior part of the cyst that is located inside the peroneal nerve. **c** Axial MR image shows the transverse distal part of the ganglion cyst. The cyst is in the common peroneal nerve and the transverse limb of the articular trunk. The fibula is marked with a star. **d** Axial MR image shows the 12-mm transverse diameter of the posterior part of the ganglion cyst and the dorsally compressed nerve fascicles (arrow). The cyst appears to involve also the deep peroneal nerve and the nerve branch leading to TA muscle. The fibula is marked with a star.

Follow-up ENMG was performed 6 months after the first ENMG and four and a half months after the surgery. Peroneal nerve conduction velocity had slightly improved, while the superficial peroneal nerve sensory action potential could not be registered. In contrast to the first ENMG, TA and extensor hallucis longus muscles displayed voluntary activation. However, the motor unit loss was profound. Both muscles showed lower numbers of fibrillations and positive sharp waves compared to the first examination. Peroneus longus muscle no longer had any abnormal spontaneous activity and no obvious abnormalities in voluntary activation. Peroneal nerve ultrasound showed increased intraneural echogenicity and some prominent fascicles but no evidence of fluid (Fig. 3). Maximum cross-sectional area of the nerve was now 25.5 mm² at the resection site and 8.6 mm² in the popliteal fossa. The maximum diameter was 2.8 mm.

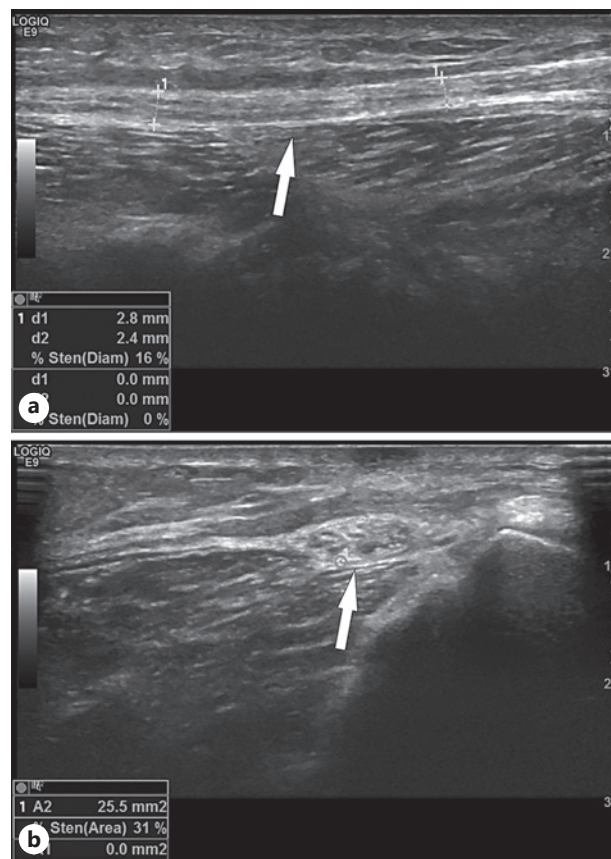


Fig. 3. Postoperative ultrasound images of the peroneal nerve at the resection site. **a** Ultrasound image showing a longitudinal cross-section of the nerve (marked with white arrow). **b** Parallel ultrasound slice of the nerve showing increased intraneural echogenicity.

The patient was able to resume soccer 1 year after the surgery. Only slight side-to-side variation remains in ankle dorsiflexion force and in the sensation of the peroneal nerve dermatome.

Discussion

In ENMG, differentiating an intraneural ganglion cyst from, e.g., repetitive stress-related peroneal nerve injury, poses a problem as both lesions are usually located in the vicinity of the proximal fibular head. Nerve imaging is needed to identify the etiology of the defect. Both MRI and ultrasound are accurate methods in visualizing peripheral nerves. Of these, ultrasound is preferred as it has been shown to be more sensitive than MRI with equivalent specificity in detecting peripheral nerve lesions, including ganglion cysts [8]. Additionally, unlike MRI, ultrasound can be performed inexpensively and rapidly after ENMG and during the same visit. In the presented case, the surgeon also wanted an MRI for confirmation of US findings and as a map for preoperative planning.

In general, intraneural peroneal nerve cysts are considered rare. However, Visser [9] studied patients with nontraumatic acute foot drop and reported that up to 18% of the patients had a peroneal nerve intraneural ganglion cyst causing the symptoms. Although to our knowledge the study of Visser [9] has not yet been reproduced, according to the study result, it is possible that the peroneal nerve intraneural ganglion cysts are more common than thought and underdiagnosed. Thus, in clinical practice, the possibility of an intraneural ganglion cyst should be considered in case of a peroneal palsy with an unclear etiology.

As illustrated by the case discussed, ultrasound holds great potential for identifying intraneural ganglion cysts at the time of the initial ENMG examination, thus avoiding missed diagnoses and delays in management. In the case presented prompt surgical treatment with the standard procedure resulted in a good functional outcome on the follow-up.

Statement of Ethics

Permission for publication of this case report and any accompanying images was obtained from the patient. The board of ethics of the local health care district (Pirkanmaa Hospital District, Tampere, Finland; reference number R19002; date of approval February 19, 2019) approved the study.

Conflict of Interest Statement

None of the authors have potential conflicts of interest to be disclosed.

Funding Sources

This study was financially supported by the Competitive State Research Financing of the Expert Responsibility area of Tampere University Hospital (grant nos. 9U007 and 9V005).

Author Contributions

Antti Pemmari and Katri Mäkelä, with equal contribution: study design, data collection, literature search, writing, and design of figures. Jimi Niemi: study design and writing. Tommi Kiekara: evaluation of MRI findings, writing, design of figures, and final approval of the manuscript. Sari-Leena Himanen: study design and final approval of the manuscript.

Data Availability Statement

The data of the findings used to support the conclusions of the case report are included within the case presentation and figures of this article.

References

- 1 Desy NM, Wang H, Elshiekh MA, Tanaka S, Choi TW, Howe BM, et al. Intraneural ganglion cysts: a systematic review and reinterpretation of the world's literature. *J Neurosurg*. 2016 Sep;125(3):615–30.
- 2 McCarthy CL, McNally EG. The MRI appearance of cystic lesions around the knee. *Skeletal Radiol*. 2004 Apr; 33(4):187–209.
- 3 Cesmebasi A, Howe BM, Amrami KK, Spinner RJ. Sequential MR imaging demonstrates evolution of a fibular intraneural ganglion cyst after knee dislocation. *Clin Anat*. 2015 Jan;28(1):2–4.
- 4 Spinner RJ, Ibrahim Elshiekh MA, Tubbs RS, Turner NS 3rd, Amrami KK. Posttraumatic torsional injury as an indirect cause of fibular intraneural ganglion cysts: case illustrations and potential mechanisms. *Clin Anat*. 2012 Jul;25(5):641–6.
- 5 Spinner RJ, Atkinson JL, Tiel RL. Peroneal intraneural ganglia: the importance of the articular branch. A unifying theory. *J Neurosurg*. 2003 Aug;99(2):330–43.

- 6 Spinner RJ, Desy NM, Rock MG, Amrami KK. Peroneal intraneural ganglia. Part II. Lessons learned and pitfalls to avoid for successful diagnosis and treatment. [Neurosurg Focus](#). 2007 Jun 15;22(6):E27.
- 7 Wilson TJ, Mauermann ML, Rock MG, Spinner RJ. Outcomes following surgery for peroneal intraneural ganglion cysts. [Muscle Nerve](#). 2018 Jun;57(6):989–93.
- 8 Zaidman CM, Seelig MJ, Baker JC, Mackinnon SE, Pestronk A. Detection of peripheral nerve pathology: comparison of ultrasound and MRI. [Neurology](#). 2013 Apr 30;80(18):1634–40.
- 9 Visser LH. High-resolution sonography of the common peroneal nerve: detection of intraneural ganglia. [Neurology](#). 2006 Oct 24;67(8):1473–5.