



Bilateral empyema secondary to *Hemophilus influenzae* epiglottitis

Aleksandr Kalininskiy^{*}, Justin M. Weis

Department of Medicine, Pulmonary Diseases and Critical Care, University of Rochester, Strong Memorial Hospital, 601 Elmwood Avenue, Box 692, Rochester, NY 14642-8692, USA

ARTICLE INFO

Keywords:

Empyema
Bilateral empyema
Hemophilus influenzae
Epiglottitis
Pleural effusion
Fibrinolysis

ABSTRACT

An empyema is a collection of pus in the pleural space, often due to aerobic bacteria, that requires drainage typically done with a small bore chest tube and fibrinolytics. The large majority of empyemas are unilateral. Bilateral empyemas are rare, usually non-infectious and typically require surgical management. We report a case of *Hemophilus influenzae* epiglottitis complicated by bilateral culture proven empyema successfully managed without surgery. The aim of this report is to present a rare complication of epiglottitis and discuss the theoretical issues with management of multiple infected pleural spaces requiring fibrinolytics.

1. Introduction

An empyema is a collection of pus in the pleural space that can complicate a pneumonia and is associated with a mortality rate of 10% [1]. Most community acquired empyemas are unilateral and due to aerobic bacteria with *Streptococcus anginosus* and *Streptococcus pneumoniae* being the most common [2]. Bilateral empyemas are rare and often managed surgically [3]. We report a case of bilateral empyema complicating *Hemophilus influenzae* epiglottitis managed successfully with two small bore chest tubes and fibrinolytics.

2. Case report

50 year old woman with history of rheumatoid arthritis on infliximab and methotrexate presented to a specialty clinic with ear and throat pain of several days. Laryngoscopy demonstrated edema of the epiglottis consistent with epiglottitis. Clindamycin, ibuprofen and corticosteroids were initiated. 5 days later she presented to the emergency department with dyspnea, productive cough, black stools and subjective fever. On arrival, she was afebrile with a heart rate of 115, normotensive and saturating 95% on room air. Physical exam was notable for a hoarse voice without stridor, enlarged tonsils without exudate, dull breath sounds and diffuse epigastric tenderness.

Blood tests revealed a white blood cell count of 37,500 per microliter (74% neutrophils), a hemoglobin of 6.6 g per deciliter and a CRP of 130 mg/L. Rapid streptococcal antigen test and throat culture were negative. A CT of the abdomen demonstrated bilateral loculated pleural effusions

at the lung bases (Fig. 1). Vancomycin, aztreonam and metronidazole were started. A diagnostic thoracentesis showed frank yellow-green pus (Fig. 2a) with 29,550 nucleated cells (34% segs) per microliter, LDH of 7161 U/L, glucose of <5 mg/dL, pH of 7 and triglycerides of 66 mg/dL. Gram stain demonstrated gram negative bacilli and ultimately grew non-typeable *H. influenzae*, as did two sets of blood cultures. A diagnosis of bilateral empyema was made. Bilateral 14 French chest tubes were placed (Fig. 2b) and fibrinolytics (5mg t-PA/5mg DNase) were instilled into each tube 8–12 hours apart. A total of 3 infusions were administered into each tube over 2 days. The chest tubes were removed once drainage slowed and patient's dyspnea improved. She was discharged on 4 weeks of ceftriaxone and a repeat chest CT showed near complete resolution of empyema (Fig. 3).

3. Discussion

Non-typeable *H. influenzae* is a gram negative bacillus that is a commensal organism in the nasopharynx. It causes epiglottitis, sinusitis and otitis, with rare cases of bacteremia and pleural effusions [4]. Pleural disease from *H. influenzae* develops via seeding of the bacteria from the blood stream into the pleural space, local spread into the lower respiratory tract or cough resulting in esophageal rupture or pneumothorax [4]. The treatment for invasive disease consists of source control and either ceftriaxone or ciprofloxacin [5].

Bilateral empyema itself is a rare entity usually seen in the context of mediastinal trauma or esophageal rupture. This case is unique in that the empyemas were the result of epiglottitis seeding into both lungs via the

^{*} Corresponding author.

E-mail address: aleksandr.kalininskiy@urmc.rochester.edu (A. Kalininskiy).

<https://doi.org/10.1016/j.rmcr.2021.101461>

Received 10 May 2021; Accepted 16 June 2021

Available online 27 June 2021

2213-0071/© 2021 The Authors.

Published by Elsevier Ltd.

This is an open access article under the CC BY-NC-ND license

(<http://creativecommons.org/licenses/by-nc-nd/4.0/>).

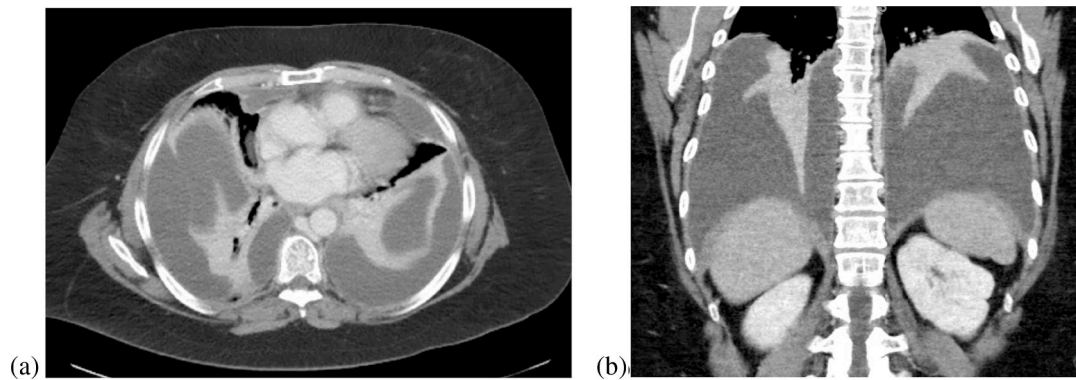


Fig. 1. (a)Caption: Representative sections of a CT scan (axial section on the left (a), coronal section on the right (b)) showing bilateral pleural effusions with loculations at the lung bases.

bloodstream in an immunosuppressed patient and managed successfully without surgery.

There is no data to guide management of bilateral empyemas with chest tubes alone. The MIST2 trial demonstrated that chest tube drainage with instillation of 10mg t-PA and 5mg of DNase every 12 hours was effective at resolving most unilateral empyemas without need for surgical drainage [6]. The total possible dose of t-PA/DNase in MIST2 was 60mg/30mg respectively. The notable complication in the trial was bleeding, and this is of higher concern when multiple chest tubes are placed. Local bleeding is known to correlate with the t-PA dose [7], and theoretically more pockets with more chest tubes would equate to higher dose of local t-PA administered. Systemic bleeding from t-PA absorption from multiple chest tubes is also a possibility. While the amount of systemic absorption of locally administered t-PA and DNase is not established, it is likely minimal as even when giving large boluses intravenously, t-PA is rapidly metabolized and eliminated by the liver [8]. This is supported by a study showing that intra-pleural streptokinase administration had no effect on systemic thrombolysis [9]. When managing multiple infected spaces, the total administered dose of fi-

brinolytics should be taken into account with concern for local accumulation causing hemorrhage [10]. It may be prudent to temporally separate t-PA and DNase administration in each cavity to minimize accumulation and maintain total dosing at or below levels studied in MIST2. We recommend daily tracking of the total amount of fibrinolytics administered, hematocrit and pleural fluid color.

4. Conclusion

H. Influenzae epiglottitis may rarely be complicated by bilateral empyema. Bilateral empyema is a rare entity with limited literature to guide management. While surgical referrals are often necessary, our case illustrates that some bilateral empyemas may be treated with chest tube drainage and fibrinolytics alone. Temporal separation of t-PA and DNase administration as well as judicious tracking of total fibrinolytic amount, hematocrit and pleural fluid color is recommended to maintain awareness of bleeding complications.

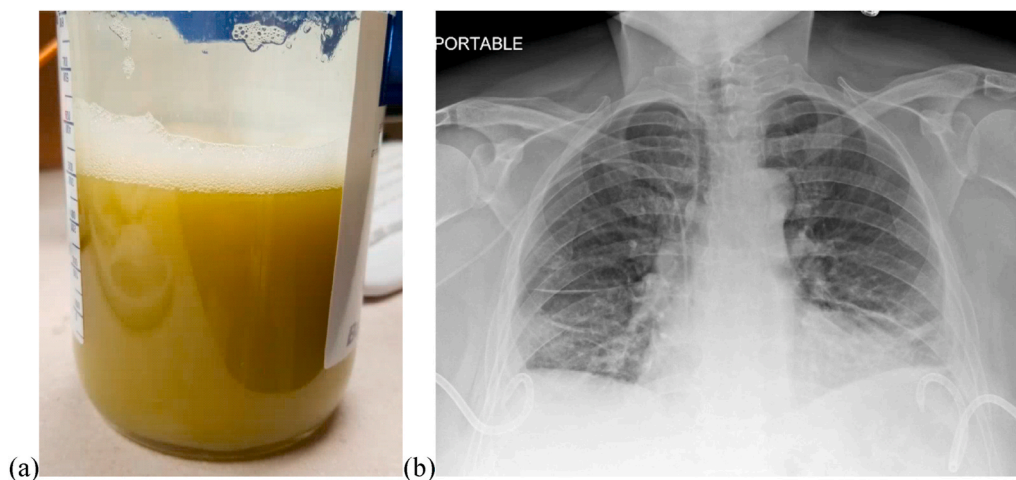


Fig. 2. (b)Caption: Yellow-green empyema fluid (a) after placement of bilateral 14 french pigtail catheters (b). (For interpretation of the references to color in this figure legend, the reader is referred to the Web version of this article.)

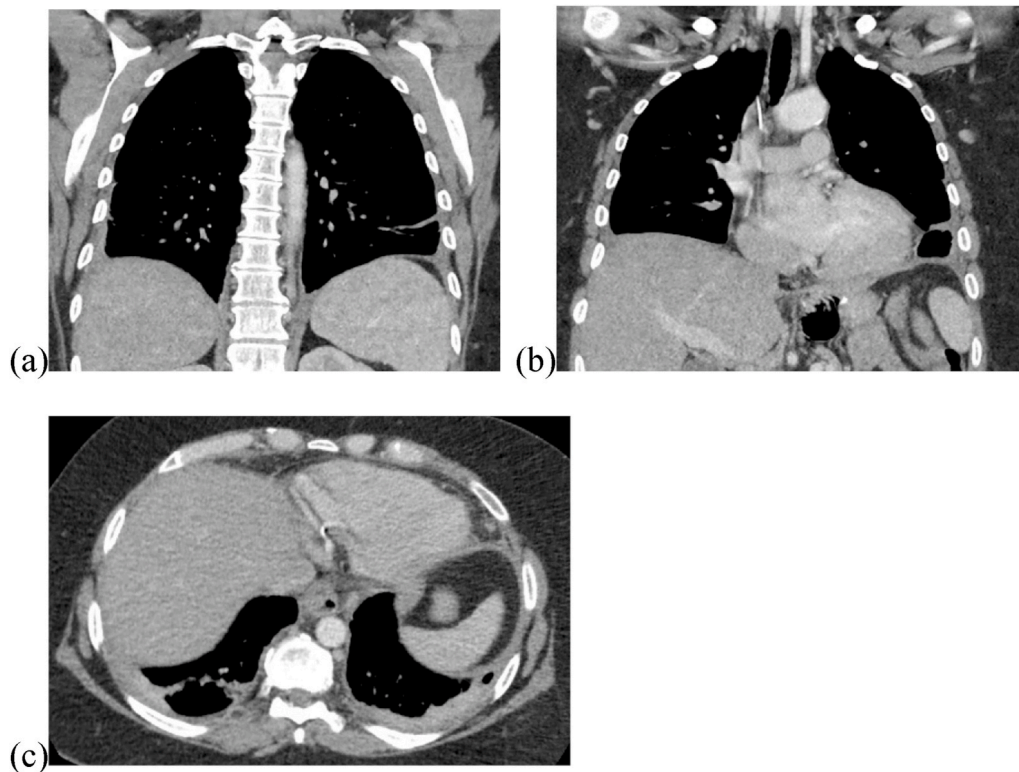


Fig. 3. Caption: CT scan sections showing near-complete resolution of bilateral empyema after discharge with coronal (a)(b) and axial (c) views.

Declaration of competing interest

None.

References

- [1] F. Farjah, R.G. Symons, B. Krishnadasan, D.E. Wood, D.R. Flum, Management of pleural space infections: a population-based analysis, *J. Thorac. Cardiovasc. Surg.* 133 (2) (2007) 346–351, e341.
- [2] N.A. Maskell, S. Batt, E.L. Hedley, C.W. Davies, S.H. Gillespie, R.J. Davies, The bacteriology of pleural infection by genetic and standard methods and its mortality significance, *Am. J. Respir. Crit. Care Med.* 174 (7) (2006) 817–823.
- [3] N. Nose, T. Anami, Simultaneous bilateral decortications via video-assisted thoracic surgery for bilateral empyema, *International journal of surgery case reports* 6 (2015) 81–83.
- [4] W. Hussan, N. Keaney, Bilateral thoracic empyema complicating adult epiglottitis, *J. Laryngol. Otol.* 105 (10) (1991) 858–859.
- [5] E.C. Briere, L. Rubin, P.L. Moro, A. Cohn, T. Clark, N. Messonnier, Prevention and control of haemophilus influenzae type b disease: recommendations of the advisory committee on immunization practices (ACIP), *MMWR Recomm. Rep. (Morb. Mortal. Wkly. Rep.)* 63 (1) (2014) 1–14.
- [6] N.M. Rahman, N.A. Maskell, A. West, et al., Intrapleural use of tissue plasminogen activator and DNase in pleural infection, *N. Engl. J. Med.* 365 (6) (2011) 518–526.
- [7] C. Alemán, J.M. Porcel, J. Alegre, et al., Intrapleural fibrinolysis with urokinase versus alteplase in complicated parapneumonic pleural effusions and empyemas: a prospective randomized study, *Lung* 193 (6) (2015) 993–1000.
- [8] W. Chandler, M. Alessi, M. Aillaud, P. Henderson, P. Vague, I. Juhan-Vague, Clearance of tissue plasminogen activator (TPA) and TPA/plasminogen activator inhibitor type 1 (PAI-1) complex: relationship to elevated TPA antigen in patients with high PAI-1 activity levels, *Circulation* 96 (3) (1997) 761–768.
- [9] E.B. Wo, R. Ekroth, A.-C. Teger-Nilsson, G. William-Olsson, Intrapleural instillation of streptokinase effects on systemic fibrinolysis, *Thorac. Cardiovasc. Surg.* 29 (2) (1981) 124–126.
- [10] F. Piccolo, N. Pitman, R. Bhatnagar, et al., Intrapleural tissue plasminogen activator and deoxyribonuclease for pleural infection. An effective and safe alternative to surgery, *Annals of the American Thoracic Society* 11 (9) (2014) 1419–1425.