

Intracystic Papillary Carcinoma in a Man with Gynecomastia

Joshua B. Johnson, B.Ch.E., and Tim H. Emory, M.D.

Male breast cancer is a rare disease in the male breast whereas gynecomastia is quite common. An elevation of the estrogen-to-androgen ratio increases the risk of both of these diseases. However, a connection between gynecomastia and subsequent breast cancer development is controversial and unclear. Imaging studies including mammography and ultrasound provide valuable information in leading to a correct diagnosis. Traditionally, intracystic papillary carcinoma, also known as encapsulated papillary carcinoma, has been considered a form of ductal carcinoma in situ. Recent immunohistochemical studies, demonstrating an absence of myoepithelium, in many cases would be more compatible with the diagnosis of invasive malignancy. However, intracystic papillary carcinoma holds a favorable prognosis with local therapy alone. We report a case of intracystic papillary carcinoma in a male patient with long-standing gynecomastia diagnosed eight years prior by mammography. The patient presented with a breast lump on both occasions. Current work-up consisted of both mammography and ultrasound. Ultrasound provided key information revealing a complex mass requiring further evaluation. Ultrasound-guided core needle biopsy revealed intracystic papillary carcinoma with confirmation upon surgical excision.

Citation: Johnson JB, Emory TH. Intracystic papillary carcinoma in a man with gynecomastia. *Radiology Case Reports*. [Online] 2008;3:214.

Copyright: © 2008 The Authors. This is an open-access article distributed under the terms of the Creative Commons Attribution-NonCommercial-NoDerivs 2.5 License, which permits reproduction and distribution, provided the original work is properly cited. Commercial use and derivative works are not permitted.

Abbreviations: CC, cranio-caudal; DCIS, ductal carcinoma-in-situ; MLO, medio-lateral oblique

Joshua B. Johnson, B.Ch.E. (Email: john4033@umn.edu), is at the University of Minnesota Medical School, Minneapolis, MN, USA.

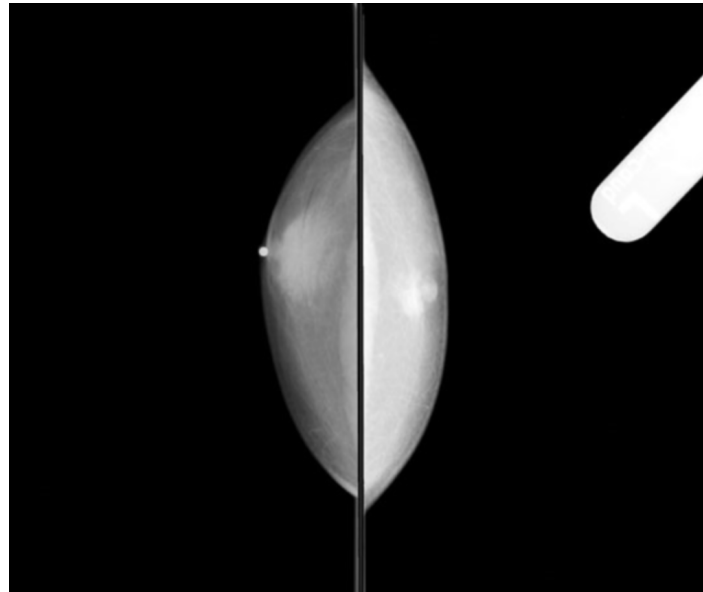
Tim H. Emory, M.D. (Email: emory002@umn.edu), is in the Department of Radiology, University of Minnesota Medical Center-Fairview, Minneapolis, MN, USA.

Published: October 1, 2008

DOI: 10.2484/rcr.v3i4.214

Introduction

Male breast cancer is a rare disease, estimated to comprise less than 0.3% of all male cancer cases and approximately 1% of all breast cancer cases in 2008 [1]. The papillary variant of breast cancer represents 1 to 2% of cases in women but is relatively more common in males, representing 3 to 5% of cases [2]. Intracystic papillary carcinoma is also referred to as encapsulated papillary carcinoma based on recent immunohistochemical studies [3,4]. The differential diagnosis for a male breast lump includes both gynecomastia and male breast cancer. The prevalence of gynecomastia in the general population shows a bimodal peak in neonates and again in the elderly and is much more common than one would expect, up to 60% in men over 50 [5].



RIGHT

LEFT

Figure 1A. 70-year-old man with intracystic papillary carcinoma. Eight years prior to presentation, CC mammogram revealed bilateral gynecomastia, with right greater than left.

The risk for both gynecomastia and male breast cancer is increased given a prolonged elevation of the estrogen-to-androgen ratio. However, the link between gynecomastia and subsequent development of breast cancer remains unclear. We report the case of a 70-year-old male with gynecomastia previously diagnosed by mammography presenting eight years later with a breast lump. Mammography and ultrasound findings led to ultrasound-guided core-needle biopsy and subsequent surgical excision, which confirmed the diagnosis of intracystic papillary carcinoma.

Case Report

A 70-year-old man was referred to our Breast Center from his primary care provider with the chief complaint of a left breast lump. The patient was seen eight years prior to the current presentation with a lump in his opposite breast. Mammography performed eight years prior to the current presentation revealed bilateral gynecomastia, with right greater than left (Fig. 1).

On current evaluation, the patient presented with the history of a left breast lump for more than one month with no associated pain or nipple discharge.

He had no family history of breast cancer. On physical exam, there was a 2 cm, visible and palpable lump beneath the left areola of the left breast with no nipple retraction or discharge. Axillary lymph nodes were not palpable and exam of the right breast was unremarkable.

Digital mammography demonstrated a well-circumscribed, rounded, 2.5 cm hyperdense mass underlying the left nipple, and mild gynecomastia (Fig. 2). Ultrasound of the left breast lump demonstrated a well-circumscribed, mostly cystic, complex mass with a solid nodular component along one wall, measuring 2.4 by 1.4 by 2.4 cm (Fig. 3). On Doppler, blood flow was present within the nodular component (Fig. 4).

Ultrasound-guided core-needle biopsy of the left breast lesion revealed grade II papillary carcinoma. Myoepithelial cell marker stains of smooth muscle myosin, p63, calponin and cytokeratin 5/6 were negative, supporting the diagnosis. The specimen was estrogen receptor positive at 100% and progesterone receptor positive at 80%. Her2/Neu FISH testing revealed no evidence of amplification of the HER2 gene. The patient underwent left simple mastectomy with left axillary sentinel lymph node biopsy. The left axillary sentinel lymph node removed was negative for metastatic disease. Left breast mastectomy confirmed the diagnosis of grade II non-invasive intracystic papillary carcinoma.

Intracystic Papillary Carcinoma in a Man with Gynecomastia

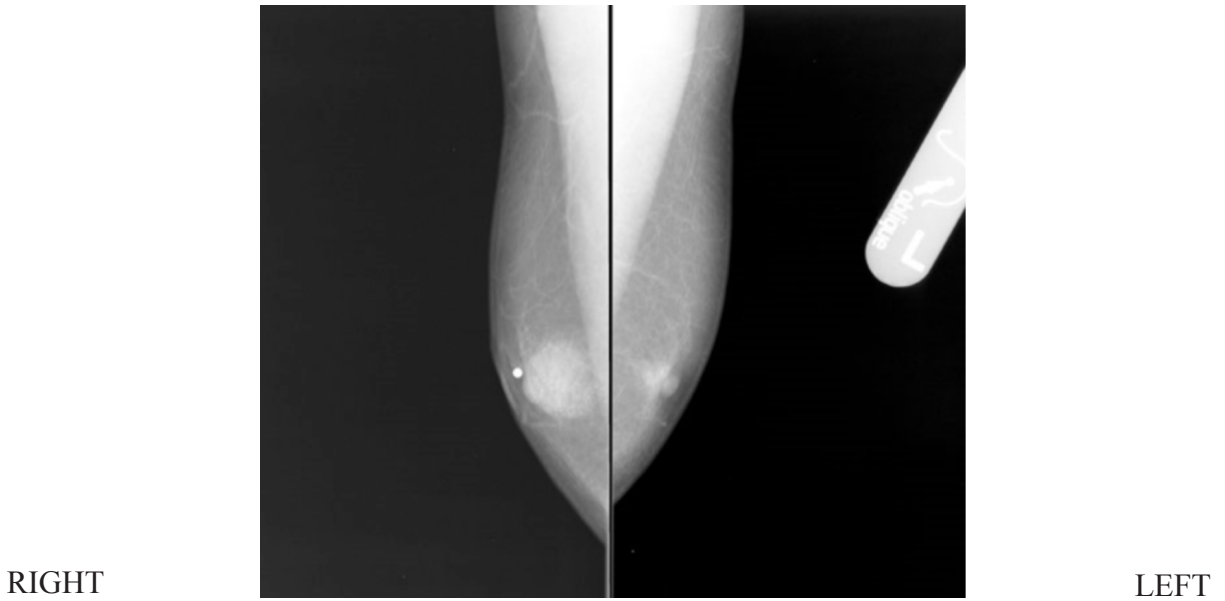


Figure 1B. 70-year-old man with intracystic papillary carcinoma. Eight years prior to presentation, MLO mammogram revealed bilateral gynecomastia, with right greater than left.

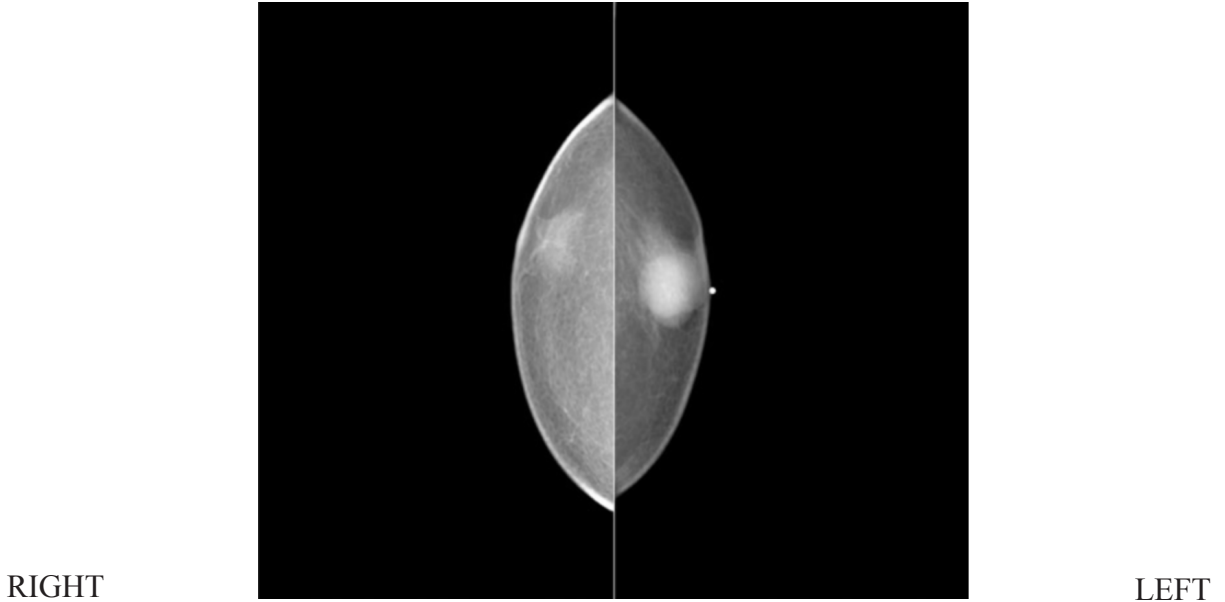
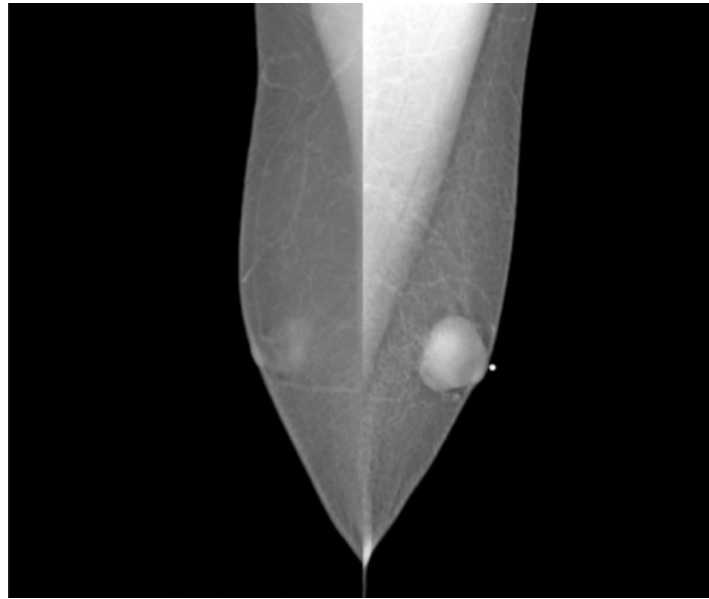


Figure 2A. 70-year-old man with intracystic papillary carcinoma. At presentation, CC mammogram revealed a well-circumscribed hyperdense mass under the nipple of the left breast.

Intracystic Papillary Carcinoma in a Man with Gynecomastia



RIGHT

LEFT

Figure 2B. 70-year-old man with intracystic papillary carcinoma. At presentation, MLO mammogram revealed a well-circumscribed hyperdense mass under the nipple of the left breast.

Discussion

Almost all diagnostic imaging of the male breast is for evaluation of a palpable lump, breast enlargement, or tenderness [6], which are nonspecific for gynecomastia or male breast cancer. Imaging studies contribute helpful information in ultimately making a correct diagnosis with mammography generally performed first, with reported 90% sensitivity and specificity in discriminating between benign and malignant disease [7]. The glandular development of the breast in gynecomastia is readily apparent on mammography, extending back from the nipple often described as a triangular or flame-shaped density [8]. Ultrasound of gynecomastia reveals various amounts of hypoechoic subareolar ducts with varying amounts of periductal fibrous tissue, depending on the phase the gynecomastia is in [9]. With intracystic papillary carcinoma, mammography reveals a circumscribed mass, representing the cyst and associated solid malignant component [10]. A circumscribed mass on mammography in a male is suspicious and should not be classified BIRADS 3, probably benign, as there is a decreased incidence of benign cysts, fibroadenomas, or

other benign round masses in the male. Given a circumscribed mass, which is not consistent with gynecomastia, ultrasound is warranted [9]. Ultrasound of intracystic papillary carcinoma demonstrates a complex solid and cystic mass; Doppler may demonstrate intratumoral blood flow or large feeding vessels [10]. In regards to biopsy, ultrasound guided core-needle biopsy has shown utility in successfully diagnosing intracystic papillary carcinoma and is preferred over fine-needle aspiration [5,11]. It also proves to be easier and more reliable given the small size of male breasts.

Gynecomastia is associated with conditions with low testosterone levels, high testosterone conversion to estrogen, high estrogen levels, or high sex hormone binding globulin levels [5]. Some examples include certain drugs, exogenous hormones, certain tumors, and genetic factors. Male breast cancer risk is increased with androgen deficiency, a family history of breast cancer, and certain gene mutations such as BRCA1 and BRCA2 [5]. Those with Klinefelter syndrome, a condition with high estrogen levels, have increased risk for both gynecomastia and male breast cancer. Yet, a connection between gynecomastia and subsequent male breast cancer is controversial.

The prevalence of gynecomastia demonstrates a wide range depending on patient age, with the prevalence for neonates at 65-90%, adolescents at 40%, ages 16-20 at 19%, ages 25-45 at 33-41%, and age over 50 at 55-60%

Intracystic Papillary Carcinoma in a Man with Gynecomastia

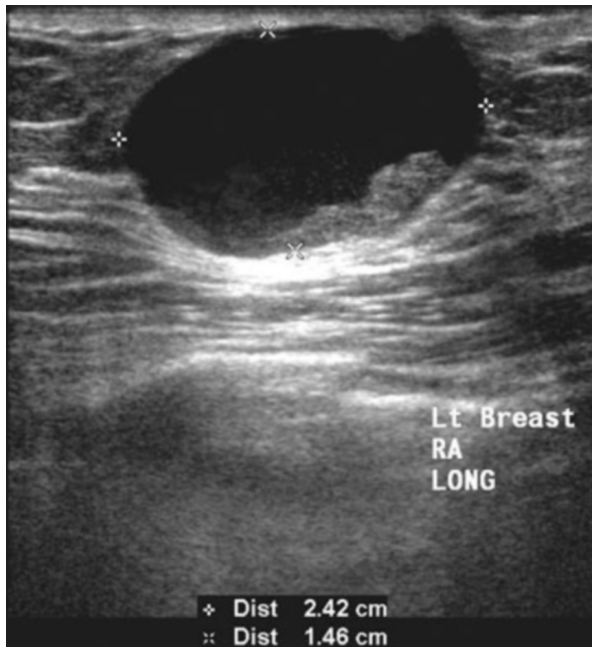

Figure 3A. 70-year-old man with intracystic papillary carcinoma. At presentation, long-axis sonogram of left breast mass demonstrated a complex mass with a solid nodular component.

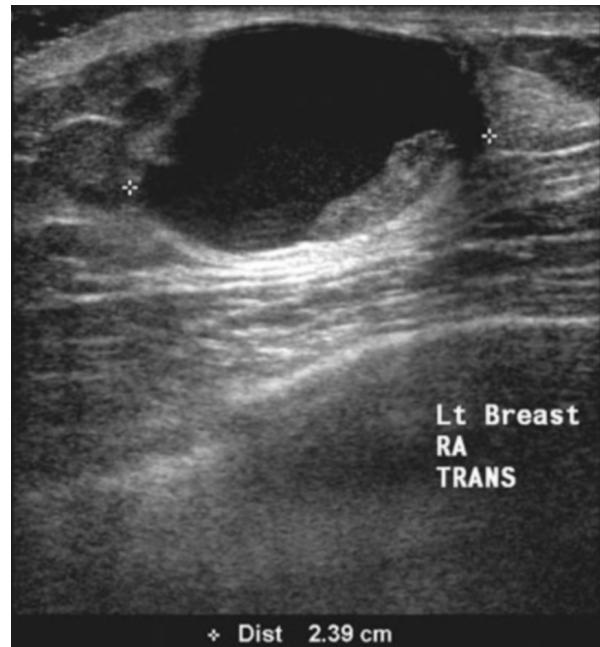

Figure 3B. 70-year-old man with intracystic papillary carcinoma. At presentation, transverse-axis sonogram of left breast mass demonstrated a complex mass with a solid nodular component.

[5]. One study reported the incidence of gynecomastia to be 40-55%, determined at autopsy [12]. Several studies have shown the incidence of gynecomastia in male breast cancer patients to be consistent with or lower than baseline population levels [12,13], indicating no increased risk for breast cancer. However, the risk for gynecomastia and the risk for male breast cancer are both linked to a prolonged elevation of the estrogen-to-androgen ratio and many consider gynecomastia a risk factor for developing male breast cancer given the high estrogen and low testosterone state associated with it [14]. In patients with longstanding gynecomastia, it is plausible that a correlation may exist between the duration of gynecomastia and the ultimate development of male breast cancer, but this relationship will likely remain unresolved given the small number of annual cases of male breast cancer and the broad prevalence of gynecomastia.

The presence of gynecomastia mammographically is considered diagnostic in explaining a retroareolar lump or tenderness, with additional work-up by ultrasound

reported unnecessary, or even discouraged, according to a standard text [15]. Ultrasound has been reported to have utility in distinguishing between gynecomastia and carcinoma and should be utilized [16], but only if suspicious features are present on physical exam or imaging. If there are suspicious findings, ultrasound of a male breast lump may be just as valuable as in the evaluation of a female breast lump [6,17]. While it is conceivable that a small breast cancer could be obscured by overlying gynecomastia on mammography and visible on ultrasound, this problem has not been documented in the imaging literature. The high incidence of gynecomastia, the low incidence of male breast cancer, and the absence of documented mammographically occult male breast cancer associated with gynecomastia, provide the rationale for not routinely performing breast ultrasound if gynecomastia is found mammographically.

Pathologically, intracystic carcinomas have been considered variants of ductal carcinoma in situ (DCIS). In recent years, the demonstration of myoepithelial cells by the immunohistochemical stains for smooth muscle

Intracystic Papillary Carcinoma in a Man with Gynecomastia

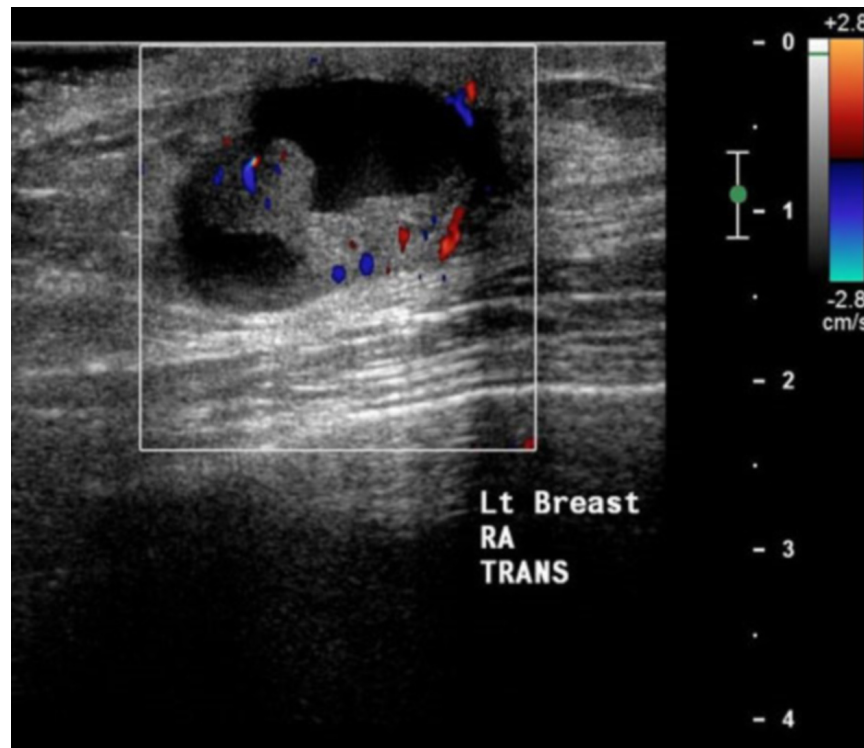


Figure 4. 70-year-old man with intracystic papillary carcinoma. At presentation, Doppler sonogram of left breast mass demonstrated blood flow in the nodular component.

myosin, calponin, p63, and cytokeratin 5/6 around a neoplasm has become the major objective criterion used to distinguish in situ from invasive carcinomas of the breast [18,19,20]. A recent study of 22 intracystic papillary carcinomas failed to demonstrate myoepithelial cells at the periphery of the tumor nodules, implying an invasive carcinoma classification [3]. It may be that at least some lesions categorized as non-invasive intracystic papillary carcinoma in the past using conventional histologic criteria actually represent invasive papillary carcinoma. Regardless of whether these lesions are in situ or invasive carcinomas, available outcome data demonstrate an excellent prognosis with adequate local therapy alone and management for intracystic papillary carcinoma should continue to mirror that for patients with DCIS [3].

In conclusion, intracystic papillary carcinoma in the male breast associated with gynecomastia is rare, and both mammography and ultrasound provide key

information in leading to a correct diagnosis. Conditions linked to prolonged elevation of the estrogen-to-androgen ratio are associated with both male breast cancer and gynecomastia, yet a link between the two remains unclear. While intracystic papillary carcinomas have traditionally been considered a variant of DCIS, there is new immunohistochemical evidence that at least some of these represent invasive cancer, although outcome data indicates a favorable prognosis with the current management of local therapy alone.

References

1. Jemal A, Siegel R, Ward E, et al. Cancer Statistics, 2008. *CA Cancer J Clin.* 2008 Mar-Apr;58(2):71-96. Epub 2008 Feb 20. [PubMed]
2. Rosen PP. Carcinoma of the Male Breast. In: Rosen's Breast Pathology. 2nd ed. Philadelphia, PA: Lippincott Williams & Wilkins; 2001:713-728.
3. Collins LC, Carlo VP, Hwang H, et al. Intracystic papillary carcinomas of the breast: a reevaluation using

Intracystic Papillary Carcinoma in a Man with Gynecomastia

- a panel of myoepithelial cell markers. *Am J Surg Pathol*. 2006 Aug;30(8):1002-7. [PubMed]
4. Mulligan AM, O'Malley FP. Papillary lesions of the breast: a review. *Adv Anat Pathol*. 2007 Mar;14(2):108-19. [PubMed]
 5. Niewoehner CB, Schorer AE. Gynaecomastia and breast cancer in men. *BMJ*. 2008 Mar 29;336(7646):709-13. [PubMed]
 6. Chen L, Chantra PK, Larsen LH, et al. Imaging characteristics of malignant lesions of the male breast. *Radiographics*. 2006 Jul-Aug;26(4):993-1006. [PubMed]
 7. Evans GF, Anthony T, Turnage RH, et al. The diagnostic accuracy of mammography in the evaluation of male breast disease. *Am J Surg*. 2001 Feb;181(2):96-100. [PubMed]
 8. Dershaw DD. Male mammography. *AJR Am J Roentgenol*. 1986 Jan;146(1):127-31. [PubMed]
 9. Stavros AT. Evaluation of the Male Breast. In: *Breast Ultrasound*. 1st ed. Philadelphia, PA: Lippincott Williams & Wilkins; 2004:712-741.
 10. Soo MS, Williford ME, Walsh R, Bentley RC, Kornguth PJ. Papillary carcinoma of the breast: imaging findings. *AJR Am J Roentgenol*. 1995 Feb;164(2):321-6. [PubMed]
 11. Pacelli A, Bock BJ, Jensen EA, Heerden JA, Reynolds C. Intracystic papillary carcinoma of the breast in a male patient diagnosed by ultrasound-guided core biopsy: a case report. *Breast J*. 2002 Nov-Dec;8(6):387-90. [PubMed]
 12. Andersen JA, Gram JB. Male breast at autopsy. *Acta Pathol Microbiol Immunol Scand [A]*. 1982 May;90(3):191-7. [PubMed]
 13. Sasco AJ, Lowenfels AB, Pasker-de Jong P. Review article: epidemiology of male breast cancer. A meta-analysis of published case-control studies and discussion of selected aetiological factors. *Int J Cancer*. 1993 Feb 20;53(4):538-49. [PubMed]
 14. Meguerditchian AN, Falardeau M, Martin G. Male breast carcinoma. *Can J Surg*. 2002 Aug;45(4):296-302. [PubMed]
 15. Kopans DB. The Male Breast. In: *Breast Imaging*. 3rd ed. Philadelphia, PA: Lippincott Williams & Wilkins; 2007:671-690.
 16. Jackson VP, Gilmor RL. Male breast carcinoma and gynecomastia: comparison of mammography with sonography. *Radiology*. 1983 Nov;149(2):533-6. [PubMed]
 17. Günhan-Bilgen I, Bozkaya H, Ustün EE, Memiş A. Male breast disease: clinical, mammographic, and ultrasonographic features. *Eur J Radiol*. 2002;43(3):246-55. [PubMed]
 18. Lerwill MF. Current practical applications of diagnostic immunohistochemistry in breast pathology. *Am J Surg Pathol*. 2004 Aug;28(8):1076-91. [PubMed]
 19. Wang NP, Bing BC, Skelly M, et al. Antibodies to novel myoepithelium-associated proteins distinguish benign lesions and carcinoma in situ from invasive carcinoma of the breast. *Appl Immunohistochem*. 1997;5:141-51. doi:10.1097/00022744-199709000-00002
 20. Yaziji H, Gown AM, Sneige N. Detection of stromal invasion in breast cancer: the myoepithelial markers. *Adv Anat Pathol*. 2000 Mar;7(2):100-9. [PubMed]