



**Arab Journal of Urology**  
(Official Journal of the Arab Association of Urology)

www.sciencedirect.com



**ANDROLOGY/SEXUAL MEDICINE**

**ORIGINAL ARTICLE**

# The use of an acellular collagen matrix in penile augmentation: A pilot study in Saudi Arabia

Alaa A. Tealab <sup>a,c,\*</sup>, Aref M. Maarouf <sup>c</sup>, Mohamed Habous <sup>a</sup>, David J. Ralph <sup>b</sup>, Safwat Abohashem <sup>c</sup>

<sup>a</sup> Elaj Medical Centre, Jeddah, Saudi Arabia

<sup>b</sup> St Peter's Andrology, London, UK

<sup>c</sup> Urology Department, Faculty of Medicine, Zagazig University, Zagazig, Egypt

Received 11 January 2013, Received in revised form 30 January 2013, Accepted 16 February 2013

Available online 22 March 2013

## KEYWORDS

Dysmorphophobia;  
Penile augmentation;  
Collagen matrix

**Abstract Objectives:** To assess the use of an acellular collagen matrix (Pelvicol, Bard Medical, Covington, GA, USA), a successful agent for reconstructive surgery, for enhancing penile girth.

**Patients and methods:** Between June and December 2011, 18 patients (mean age 24 years, range 19–38) had their penis augmented with Pelvicol; the mean (range) penile circumference was 9.2 (7–13) cm before treatment. They were divided into two groups; the first (10 patients) had a Pelvicol sheet of 8 × 12 cm inserted through a V–Y suprapubic incision and wrapped around the shaft in a bilayer under the dartos fascia, but not covering the urethra, with division of the suspensory ligament. The second group of eight patients had the Pelvicol inserted through a subcoronal degloving incision and placed in one layer. The penile circumference was measured at 6 and 12 months after surgery. Patient satisfaction at 1 year after surgery was assessed as ‘poor’, ‘unsatisfied’, ‘moderately satisfied’, ‘highly satisfied’, or ‘excellent’.

\* Corresponding author address: Urology Department, Faculty of Medicine, Zagazig University, Zagazig 12345, Egypt. Tel.: +966594084879; fax: +966048157060.

E-mail addresses: dralaa71@gmail.com, dralaa\_71@yahoo.com (A.A. Tealab).

Peer review under responsibility of Arab Association of Urology.



Production and hosting by Elsevier

**Results:** The mean (range) increase in girth (circumference) was 2.8 (2–3.2) cm in group 1 and 1.7 (1.2–2) cm in group 2. In group 1, two patients were highly satisfied, four moderately satisfied and four unsatisfied; in group 2, three were moderately satisfied and five unsatisfied. Complications were common in both groups, with five patients in group 1 and three in group 2 developing severe penile oedema and ischaemic shaft ulcers. Removal of the graft was required in two patients in each group.

**Conclusion:** This pilot study shows that Pelvicol is not an ideal option for enhancing penile girth, and the method of placement did not apparently influence the result.

© 2013 Production and hosting by Elsevier B.V. on behalf of Arab Association of Urology.

## Introduction

Men are often worried about the size of their penis, and sometimes seek enhancement to improve their self-esteem or to satisfy and/or impress their partners [1]. As the perception of penile size is subjective it does not necessarily coincide with the true dimensions of the organ, and thus men with penile hypoplasia might report a satisfactory sexual life, while others, who are considered normal, might demand augmentation for an altered perception of penile size [1,2]. This condition is called ‘penile dysmorphismophobia’; it might be an aesthetic issue in a patient with a normal penis who is not satisfied with its dimensions when flaccid, or a functional issue in a patient with a normal penis who is not satisfied with its size during erection [1,3]. The concerns about penile size might represent an underlying social anxiety, or some other clinical problem such as erectile dysfunction [2–7]. Currently the increasing influence of the media on sexual issues has created an interest in phallic enlargement [8], although penile augmentation has been reported since the 19th century [9,10].

A variety of exogenous materials has been used in procedures to enhance the penile girth, but to date none of them has achieved a universal consensus. Injectable materials have been tried by both medical professionals and lay persons [10]. Autologous fat [11], silicone [12–15], and hyaluronic acid gel [16] were tried. Graft implantation procedures were also tried, e.g. dermal fat grafts, and Spyropoulos et al. [8] achieved a greater enhancement of girth with this method than when injecting fat. Allografts in the form of an acellular inert dermal matrix derived from donated human skin tissue have also been used for penile girth procedures [17], but with a higher local complication rate [18]. Tissue-engineered porcine dermal acellular grafts were tried by Alei et al. [2], with promising long-term results in 69 patients. An acellular collagen matrix (Pelvicol®, CR Bard, Inc., Covington, GA, USA) was used successfully in pelvic reconstructive surgery [19], and in grafting of the tunica in surgery for Peyronie’s disease [20].

The aim of the present study was to assess the outcome of using Pelvicol as a new method of enhancing penile girth. (see Table 1).

## Patients and methods

From June to December 2011 we used augmentation phalloplasty with Pelvicol in 18 men (mean age at the time of surgery was 24 years, range 19–38). The indications for augmentation were either the perception of a short penis, seeking more sexual pleasure, or a combination of both.

### Patient assessment

Candidates for surgery were selected according to a screening protocol, including a medical history, physical examination, and sex hormone profiles, psychosexual assessment, supplemented with a locally formulated questionnaire in Arabic language which was interpreted by a psychiatrist and consisted of 10 questions stressing on patient perception of his problem and whether it is related to girth or length, how it affects his self-esteem. This questionnaire was not concluded with a score, but it only helps in deeper and more detailed psychosexual assessment.

Penile length was measured from the pubo-penile junction to the tip of the glans in the dorsal surface, and girth was measured as the circumference at the mid-penile shaft in the flaccid state. The mean value of penile length was 8.9 cm during flaccidity. Penis circumference ranged from 7 to 13 cm (mean value 9.2 cm) during flaccidity. A cutoff girth value for exclusion was not adopted, giving great importance to the psychiatric/psycho-sexual assessment results. Participants were thoroughly informed about the nature of the surgical procedure, and a written consent was obtained from all participants before surgery.

### Surgical technique

In 10 patients the penis was both lengthened and the shaft enhanced (group 1) and in eight only the shaft was enhanced (group 2). In all patients the penile girth was augmented with Pelvicol matrix (8 × 12 cm), and in group 1 the Pelvicol was folded on itself and used as a double-layered wrap around the penile circumference, sparing the urethra. In the patients in group 2

**Table 1** Patients satisfaction score.

Score	Rate
1	Poor result
2	Unsatisfied
3	Moderately satisfied
4	Highly satisfied
5	Excellent satisfied

the Pelvicol was used in one layer, wrapped in a similar way.

Under spinal (epidural) anaesthesia, a circumferential subcoronal incision was used for penile degloving in group 2, and a V-Y suprapubic incision, that allowed for suspensory ligament division, in group 1. The incision was deepened through the skin, Colles' fascia, and down to Buck's fascia, which was preserved. The shaft was then degloved down to the root of the penis. The Pelvicol graft was wrapped around the penile shaft from the coronal sulcus to the root. The graft was then sutured to Buck's fascia, with 2/0 polyglycolic acid, starting distally. A vacuum drain was fixed and left *in situ* for 24–48 h. A 5-cm crepe bandage was used to wrap the penis, without squeezing or compression, exclusively around the shaft, leaving the glans free. Antibiotic prophylaxis began the night before surgery and was continued for 1 week after surgery. Patients were instructed not to have sexual intercourse for the first 3 weeks after surgery.

#### Postoperative assessment

Patients were instructed to report at 1 week after surgery, with further follow-up visits planned at 4 weeks, 6 months and 1 year. In patients with complications, follow-up visits were planned at closer intervals according to the patient's condition. The penile circumference was measured at 6 months and 1 year after surgery. At 1 year, the patients rated their satisfaction as 'poor', 'unsatisfied', 'moderately satisfied', 'highly satisfied', or 'excellent' Table 2.

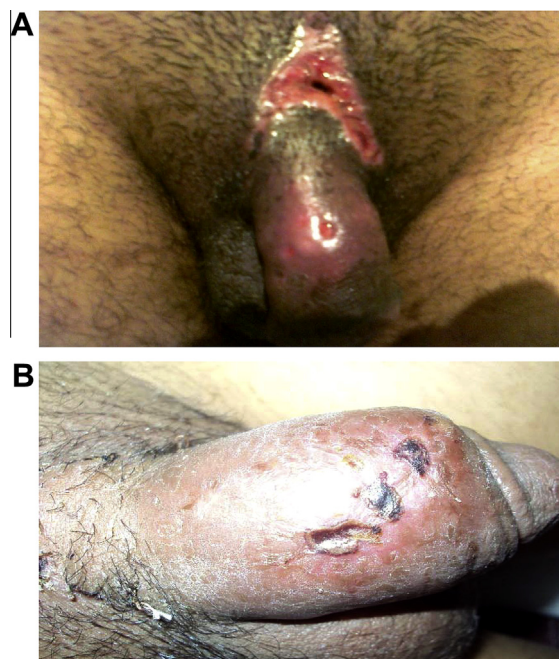
The results were analysed statistically using the Chi-square test to assess any differences in complication rate and patient satisfaction between the groups, with  $P < 0.05$  considered to indicate significance.

The study was approved by the local ethics committee of the Elaj Medical Centre, Jeddah, Saudi Arabia, and fully informed written consent was obtained from the

**Table 2** Early complications in both groups.

Complications	Group 1	Group 2
No complications	5	5
Complications managed conservatively	3	1
Complications mandate pelvicol removal	2	2

\*  $p$  Value = 0.675.

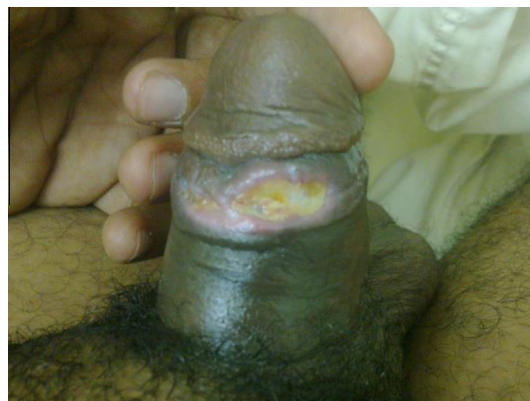

**Figure 1** A, B. Surgical wound infection with a subcutaneous purulent collection and infection of the graft; this patient required immediate surgical exploration and removal of the infected graft.

patients, who were informed about all the possible sequelae of such surgery.

#### Results

In the first 2 weeks after surgery there was no significant morbidity in all patients, apart from a mild inflammatory reaction manifested as penile skin oedema and bruising. Five patients in each group continued with no complications. At 3 weeks after surgery there were dramatic local changes in five patients in group 1, who developed severe penile oedema with ischaemic dorsal



**Figure 2** Superficial wound dehiscence at the level of the subcoronal incision; this patient was managed conservatively with broad-spectrum antibiotics.

**Table 3** Patients satisfaction in both groups.

Patient satisfaction	Group 1	Group 2
Highly satisfied	2 (20%)	–
Moderately satisfied	4 (40%)	3 (37.5%)
Unsatisfied	4 (40%)	5 (62.5%)

\*  $p$  Value = 0.358.

ulcers, and these changes continued through the fourth week (Fig. 1A and B). Conservative management was successful in three of these five patients, while in the other two the Pelvicol implant had to be removed to control the inflammatory process. In group 2, three patients had a similar reaction that required removal of the Pelvicol in two. There was no statistical difference in the complication rate between the groups ( $P = 0.675$ ). (see Fig. 2).

The penile circumference measured at 6 and 12 months after surgery showed no significant difference between the groups. At the 1-year follow-up the mean (range) increase in penile circumference in group 1 was 2.8 (2–3.2) cm, and in group 2 it was 1.7 (1.2–2) cm. At the 1-year follow-up the mean increase in penile length was 1.7 (1.2–2) cm in group 1 (suspensory ligament division). At the 6-month visit, two patients in each group reported decreased penile sensation, which persisted in only one patient in group 1 at the 1-year follow-up.

At the 1-year follow-up, in group 1 two patients were highly satisfied, four moderately satisfied and four unsatisfied; in group 2, three were moderately satisfied and five unsatisfied. Thus most patients in both groups were not or only moderately satisfied with the results of surgery ( $P = 0.358$ ). (see Table 3).

## Discussion

In the present study the Pelvicol acellular matrix was deemed to be unsuitable for enhancing penile girth, due to the high complication rate reported after using it for augmentation, either as a single or double layer. The complication rate and severity of complications were such that we stopped using this technique. (see Table 2).

Augmentation phalloplasty is usually used in cases of micropenis associated with true hypoplasia or, more commonly, in cases of penile dysmorphophobia. Whether aesthetic or functional, such surgery has a strong psychological effect on patients [2,3,5,18]. Especially in Arab countries, men requesting penile augmentation have unrealistic expectations of such surgery, and this was very evident during the present psychosexual assessment, and emphasises the role of a proper assessment and counselling. Enhancing penile girth using autologous lipo-filling and autologous dermal-fat grafting was associated with a limited positive result, which was not permanent in most of the cases [1,21–23].

Enhancing penile girth by wrapping the penile shaft with exogenous material was tried by Perovic et al. [24,25], who used biodegradable scaffolds enriched with expanded autologous scrotal dartos cells in 12 patients. They reported that it was a promising method for increasing penile width, and that it generated the progressive accumulation of a stable, collagen-rich, highly vascularised tissue matrix that closely resembles the deep dartos fascia. Recently, Alei et al. [2] used porcine dermal acellular grafts for penile augmentation in 69 candidates, followed for more than 1 year, and reported a 40% increase in penile girth during flaccidity, and 22% during erection, with no major complications. Added to this was the beneficial psychosocial effect of such surgery in most of their patients.

In the present study we used Pelvicol acellular collagen matrix for enhancing penile girth, and to our knowledge we are the first to use Pelvicol for this purpose in Saudi Arabia. The procedure was simple and reproducible. Enhancing penile girth with Pelvicol grafts has several advantages over autologous dermal-fat grafts, including the absence of donor-site morbidity and a significantly quicker operation than when using 'on-shelf' grafts. This was in agreement with the results reported by Alei et al. [2]. However, in the present study there was a high rate of surgical-site morbidity, whether Pelvicol was used as a single (three of eight patients) or double layer (five of 10), and we had to remove the graft in two patients in each group to control the severe inflammatory process. We believe that such a high complication rate might be related to our initial learning experience with Pelvicol, and few patients in each group. Patient satisfaction did not favour Pelvicol, as most patients were either only moderately satisfied or unsatisfied after surgery Table 3. The cause of dissatisfaction was a combination of the unpleasant effects of complications, an inadequate girth after the procedure, and a reduced penile sensation. This was in contrast to the study of Alei et al. [2], who reported higher satisfaction rates in their patients. Despite achieving an adequate girth as assessed by the surgeon, this was not always considered adequate by some patients, who were expecting a greater enhancement. Thus patients must be made aware before surgery of the expected enhancement in girth, and that they might have some degree of inflammatory reaction which can lead to a poor cosmetic and functional result, or even removal of the implant.

Despite these serious sequelae there is some relevant information from this study, as it provides data on the usefulness of Pelvicol for enhancing penile girth, and provides a warning to others before trying the same material in a similar field. Our study is similar to other trials in this field, as we tested a new material and stopped using it when the complication rates reached a critical level.

The limitation of the present study was that it included relatively few patients, possibly resulting in a

type II statistical error, and thus the results and conclusions must be considered provisional until other studies confirm or refute them.

In conclusion, this pilot study showed that despite the few successful cases, Pelvicol was associated with a high complication rate and poor patient satisfaction. Thus Pelvicol is not an ideal option for enhancing penile girth, also the method of placing it did not influence the results.

### Conflict of interest

None.

### Funding

None.

### References

- [1] Yoram VA, Yaron HB, Tamir GB, Ilan GAA. Critical analysis of penile enhancement procedures for patients with normal penile size. Surgical techniques, success, and complications. *Eur Urol* 2008;**54**:1042–50.
- [2] Alei G, Letizia P, Ricottilli F, Simone P, Alei L, Massoni F, et al. Original technique for penile girth augmentation through porcine dermal acellular grafts: results in a 69-patient series. *J Sex Med* 2012;**9**:1945–53.
- [3] Austoni E, Guarneri A, Cazzaniga A. A new technique for augmentation phalloplasty. Albugineal surgery with bilateral saphenous grafts – Three years of experience. *Eur Urol* 2002;**42**: 245–53.
- [4] Alter JG. Augmentation phalloplasty. *Urol Clin North Am* 1995;**22**:887–902.
- [5] Alter JG. Penile enlargement surgery. *Tech Urol* 1998;**4**:70–6.
- [6] Spyropoulos E, Borousas D, Mavrikos S, Dellis A, Bourounis M, Athanasiadis S. Size of external genital organs and somatometric parameters among physically normal men younger than 40 years old. *Urology* 2002;**60**:485–9.
- [7] Austoni E, Guarneri A, Gatti G. Penile elongation and thickening a myth? Is there a cosmetic or medical indication? *Andrologia* 1999;**31**:45–51.
- [8] Evangelos S, Charalambos C, Dimitrios B, Stamatios M, Michael A, Sotirios A. Augmentation phalloplasty surgery for penile dysmorphism in young adults. Considerations regarding patient selection, outcome evaluation and techniques applied. *Eur Urol* 2005;**48**:121–8.
- [9] Silberstein J, Downs T, Goldstein I. Penile injection with silicone. Case report and review of the literature. *J Sex Med* 2008;**5**:2231–7.
- [10] Shamsodini A, Al-Ansari AA, Talib RA, Alkhafaji HM, Shokeir C, Toth C. Complications of penile augmentation by use of nonmedical industrial silicone. *J Sex Med* 2012;**12**:3279–83.
- [11] Panfilov DE. Augmentative phalloplasty. *Plast Surg* 2006;**30**: 183–97.
- [12] Hexsel DM, Hexsel CL, Iyengar V. Liquid injectable silicone. History, mechanism of action, indications, technique, and complications. *Semin Cutan Med Surg* 2003;**22**:107–14.
- [13] Wassermann RJ, Greenwald DP. Debilitating silicone granuloma of the penis and scrotum. *Ann Plast Surg* 1995;**35**:505–10.
- [14] Christ JE, Askew JB. Silicone granuloma of the penis. *Plast Reconstr Surg* 1982;**69**:337–9.
- [15] Orentreich DS. Liquid injectable silicone: techniques for soft tissue augmentation. *Clin Plast Surg* 2000;**27**:596–612.
- [16] Kim JJ, Kwak TI, Jeon BG, Cheon J, Moon DG. Human glans penis augmentation using injectable hyaluronic acid gel. *Int J Impot Res* 2003;**15**:439–43.
- [17] Whitehead ED. Allograft dermal matrix graft (Alloderm1) for pericavernosal penile widening in normal men. Abstract. First World Congress on Aesthetic Medicine; March 15–17, 2004, Rio de Janeiro, Brazil.
- [18] Bruno JJ, Senderoff DM, Fracchia JA, Armenakas NA. Reconstruction of penile wounds following complications of AlloDerm-based augmentation phalloplasty. *Plast Reconstr Surg* 2007;**119**:1e–4e.
- [19] Liguori P, Ripoli R. Repair of posterior vaginal wall defects with Pelvicol™ implant anchored to iliococcygeus. *Int Urogynecol J* 2006;**1**:13–29.
- [20] Kalsi J, Garaffa G, Christopher N, Muneer A, Minhas S, Ralph D. A comparative study using Pelvicol collagen or saphenous vein in plaque incision grafting in Peyronie's Disease. *J Sex Med* 2009;**6**:428.
- [21] Yuksel E. Increased free fat graft survival with the long term, local delivery of insulin, insulin-like growth factor-1, and basic fibroblast growth factor by PLGA/PEG microspheres. *Plast Reconstr Surg* 2000;**105**:1712–20.
- [22] Chajchir Q, Benzaquen I, Moretti E. Comparative experimental study of autologous adipose tissue processed by different techniques. *Plast Surg* 1993;**17**:113–5.
- [23] Wood D, Southgate J. Current status of tissue engineering in urology. *Curr Opin Urol* 2008;**18**:564–9.
- [24] Perovic SV, Byun JS, Scheplev P, Djordjevic ML, Kim JH, Bubanj T. New perspectives of penile enhancement surgery: tissue engineering with biodegradable scaffolds. *Eur Urol* 2006;**49**: 139–47.
- [25] Perovic SV, Sansalone S, Djinic R, Ferlosio A, Vespasiani G, Orlandi A. Penile enhancement using autologous tissue engineering with biodegradable scaffold: a clinical and histomorphometric study. *J Sex Med* 2010;**7**:3206–15.