

# The Correlation Between Preoperative Findings of High-Resolution Computed Tomography (HRCT) and Intraoperative Findings of Chronic Otitis Media (COM)

Mariam Aljehani<sup>1</sup>  and Rayan Alhussini<sup>2</sup>

<sup>1</sup>Department of Otorhinolaryngology, Head and Neck surgery, Ohud Hospital, Madinah, Saudi Arabia.

<sup>2</sup>Department of Otolaryngology, Neurotology and Skull base surgery, Ohud Hospital, Madinah, Saudi Arabia.

Clinical Medicine Insights:

Ear, Nose and Throat

Volume 12: 1–5

© The Author(s) 2019

Article reuse guidelines:

sagepub.com/journals-permissions

DOI: 10.1177/1179550619870471



## ABSTRACT

**OBJECTIVES:** The aim of this study was to investigate the correlation between the preoperative findings of high-resolution computed tomography (HRCT) of temporal bone in chronic otitis media (COM) and the intraoperative findings.

**METHODS:** This retrospective study was conducted in the ORL-HNS Unit at Ohud Hospital, Medina, Saudi Arabia, during the period from January to September 2018. We included all patients with COM, and an informed consent was obtained from all participants. The HRCT images were studied in comparison with the intraoperative findings. The parameters of comparison were tympanic membrane, middle ear structures, and the status of cholesteatoma.

**RESULTS:** A total of 39 patients were included in the analysis: 14 male and 25 female patients. The age range was 9 to 50 years. As a result of the comparison between HRCT findings and intraoperative observations, we found that incus erosion through computed tomography (CT) was the same as during surgical observation in 12 cases (30.8%). Malleus appeared eroded on CT in 1 case (2.6%); however, 5 cases were seen with that observation during operation (12.8%). Cholesteatoma was similarly seen in the CT scan and during surgery with a significant relation between intraoperative cholesteatoma extending and HRCT findings of the disease (95% confidence level,  $P$ -value = 0.001). The sensitivity, specificity, positive predictive value, and negative predictive value were 100% for detecting sigmoid plate erosion, dura exposure, incus erosion, stapes erosion, and malleus-incus joint discontinuity through preoperative CT.

**CONCLUSIONS:** Intraoperative findings and HRCT have shown better results with good correlation of diagnostic value regarding the comparisons between recorded observations, especially in detecting sigmoidal plate erosion, dural exposure, incus and stapes erosion, and malleus-incus joint discontinuity. Preoperative CT scan is beneficial and contributory in the decision of indicating surgery to patients.

**KEYWORDS:** Temporal bone, chronic otitis media, computed tomography

**RECEIVED:** June 12, 2019. **ACCEPTED:** July 27, 2019.

**TYPE:** Original Research

**FUNDING:** The author(s) received no financial support for the research, authorship, and/or publication of this article.

**DECLARATION OF CONFLICTING INTERESTS:** The author(s) declared no potential conflicts of interest with respect to the research, authorship, and/or publication of this article.

**CORRESPONDING AUTHOR:** Mariam Aljehani, Department of Otorhinolaryngology, Ohud Hospital, Salam District, Madinah 42354, Saudi Arabia. Email: marim\_2012@hotmail.com

## Introduction

Chronic otitis media (COM) that results in hearing loss remains a significant health problem of prevalence, economics, and sequels. Short- and long-term outcomes of otitis media may be devastating but can be considered preventable if recognized early and treated properly with early surgical intervention to limit the disease.<sup>1</sup> The existence, site, and extent of the disease along with the presence of any complications determine the surgical approach to be followed. As such, imaging plays an important role in providing crucial information to the surgeon in this regard.<sup>2,3</sup>

High-resolution computed tomography (HRCT), a modification of the routine computed tomography (CT), provides a direct visual window into the temporal bone providing vision of unavailable minute structural details. Computed tomography scan findings of an acquired cholesteatoma of the temporal bone consist of homogeneous soft tissue mass with local bone erosion, scutum erosion, erosion of the ossicles, middle ear pacification, and labyrinthine

fistula extending to tympanum and widening of audits and antrum.<sup>2</sup> The purpose of the study is primarily to determine the correlation of CT in diagnosis and detection of various pathological changes occurring in the temporal bone in a case of chronic suppurative otitis media (CSOM). Moreover, facial canal dehiscence (FCD), lateral semicircular canal (LSC) dehiscence, and dural plate defect can be seen in patients who have COM with or without cholesteatoma.<sup>4,5</sup> Although LSC dehiscence increases the risk of developing labyrinthitis, dural plate dehiscence raises the probability of spreading the pathology to the brain. Having preoperative comprehensive knowledge of the anatomy and anomalies of the facial nerve (i.e. FCD) is crucial for preventing postoperative morbidity in patients who require surgery due to middle ear disorders.<sup>6</sup> Meanwhile, preoperative imaging obtained using HRCT may prove extremely beneficial for surgeons, and thus we conducted this current investigation to compare the preoperative findings of the HRCT with the intraoperative findings.



**Table 1.** Sociodemographic status of study participants.

SEX	FREQUENCY	%
Men	14	35.9
Women	25	64.1
Total	39	100

## Methods

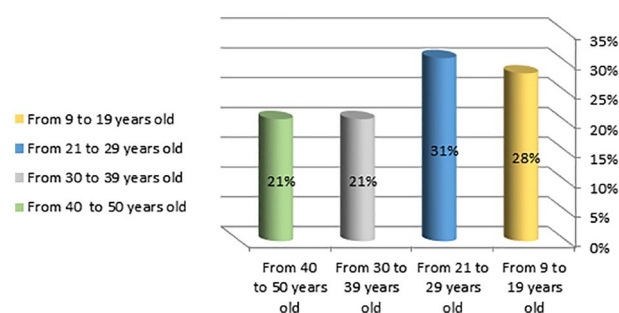
This retrospective, analytical study was primarily conducted in patients with COM presenting at the ORL-HNS Unit at Ohud Medina Hospital, Saudi Arabia, during the time period from January 2018 to September 2018. All patients with COM and records of preoperative HRCT imaging of the diseases ear were considered eligible for participation. A written informed consent was obtained from each study participant prior to conducting the study. Patients who were unfit for surgery or for anesthesia or did not have a CT preoperatively were excluded from this study. The study protocol was conducted according to the World Medical Association Declaration of Helsinki and was approved by our corresponding Institutional Review Board (IRB).

The CT imaging without contrast was performed at the radiology department prior to surgery in different slices in 1 and 5 minutes. The slices were 5 mm in thickness with the thin slice cuts and images being obtained in all planes. Furthermore, they were uploaded into the system and reported by the radiologist. The margin of imaging was taken from external auditory meatus up to the bony margin of the superior semicircular canal. The images were studied to compare the temporal bone HRCT findings and the intraoperative findings. The surgical findings were documented by Otoneuro-laryngologist skull-base surgeon.

For diagnostic accuracy, the parameters of comparison between preoperative HRCT findings and the intraoperative ones were calculated by using sensitivity, specificity, negative predictive value (NPV), and positive predictive value (PPV). The operative approach was post-auricle with a V-shaped cut and elevation of the annulus. The procedure was modified radical mastoidectomy, tympanoplasty, or ear exploration.

## Statistical Analysis

The differences in the findings of preoperative HRCT and intraoperative ones were estimated in numbers and proportions. Chi-square test would be used to detect any statistically significant difference in the findings in these 2 categories. A *P*-value of less than 0.05 was considered the cutoff point for statistical significance. Meanwhile, to determine the performance of each category, a correlation between preoperative and intraoperative findings was performed using sensitivity, specificity, NPV, and PPV. The parameters of comparison were tympanic membrane perforation, middle ear mucosa, mastoid

**Figure 1.** The distribution of this study participants according to various age groups.

segment, dura, sigmoid sinus, facial canal, facial recess, ossicular status and joint status, the extent of cholesteatoma or granulation tissue to epitympanum, mesotympanum, or hypotympanum, and eustachian tube status.

## Results

We conducted this study based on the Strengthening the Reporting of Observational Studies in Epidemiology (STROBE) Statement guidelines for reporting observational studies. A total of 39 patients were included in the final analysis in which 14 (35.9%) were male patients and 25 (64.1%) were female patients undergoing surgery belonging to the age range of 9 to 50 years. The mean age of the analyzed patients was 28 years. The sociodemographic data of the included patient are summarized in Table 1 and Figure 1.

On comparing the preoperative findings of the HRCT with the intraoperative findings, tympanic perforation was reported on the CT of 11 patients (28.2%); however, 13 patients with tympanic perforation were observed intraoperatively (33.3%). Regarding facial canal erosion, it was reported in the CT of just 1 case (2.6%), whereas it was seen intraoperatively in 2 cases (5.1%). As for sigmoid plate erosion, there was similar observation in both preoperative CT and the intraoperative findings with 6 patients (15.4%) presenting with that findings. In the same context, exposure of the dura was reported similarly during both assessments with 3 cases (7.7%) presenting with exposed dura preoperatively in the CT report and during operation. Meanwhile, edema of the middle ear mucosa was documented based on the preoperative CT imaging in 3 cases (7.7%), whereas only 1 case (2.6%) showed intraoperative edematous mucosa. Furthermore, malleus appeared eroded in the CT in 1 case (2.6%), whereas the intraoperative observation showed that 5 cases had eroded malleus (12.8%). On the contrary, eroded incus was observed in 12 cases (30.8%) based on CT and similarly intraoperatively. Similarly, erosion of the stapes was seen in 6 cases (15.4%) during both assessments. Regarding malleus-incus (M-I) joint discontinuity, the preoperative CT documented 15 cases with this condition (38.5%) and the same was observed intraoperatively. The comparison parameters between preoperative findings of the CT and the intraoperative findings are reported in detail in Table 2.

**Table 2.** Comparison between preoperative CT findings and intraoperative observations.

INTRAOPERATIVE FINDING	INTRAOPERATIVE FINDINGS, N (%)	HRCT FINDINGS, N (%)	SE%	SP%	PPV (%)	NPV (%)	P-VALUE
TM perforation	13 (33.3)	11 (28.2)	100	21.2	54	100	0.075
Facial canal erosion	2 (5.1)	1 (2.6)	97.8	77.6	93.9	40	0.077
Sigmoid plate erosion	6 (15.4)	6 (15.4)	100	100	100	100	0.001
Dura exposed	3 (7.7)	3 (7.7)	100	100	100	100	0.001
Meddle ear mucosa edematous	3 (7.7)	1 (2.6)	96.	81	97	75	0.103
Malleus erosion	5 (12.8)	1 (2.6)	78	96	95	21	0.348
Incus erosion	12 (30.8)	12 (30.8)	100	100	100	100	0.001
Stapes erosion	6 (15.4)	6 (15.4)	100	100	100	100	0.002
M-I joint discontinuous	15 (38.5)	15 (38.5)	100	100	100	100	0.002
I-S joint discontinuous	14 (32.8)	10 (28.8)	88	70	98	77	0.345
Eustachian tube granulation	10 (25.6)	5 (15.4)	96	77	95.5	75	0.567

Abbreviations: HRCT, high-resolution computed tomography; I-S, Incus Stapes; M-I, malleus-incus; NPV, negative predictive value; PPV, positive predictive value; Se, sensitivity; Sp, specificity; TM, tympanic membrane.

**Table 3.** Total number of cholesteatoma status intraoperatively and on HRCT.

TOTAL NUMBER OF CHOLESTEATOMA FINDING INTRAOPERATIVE AND ON HRCT, N (%)		TOTAL, N (%)
ABSENT	PRESENT	
23 (59.0)	16 (41.0)	39 (100.0)

Abbreviation: HRCT, high-resolution computed tomography.

Table 2 also shows the sensitivity (Se), specificity (Sp), PPV, and NPV of the HRCT findings in comparison with the intraoperative observations. There is significant relation between incus erosion intraoperative and incus erosion on CT with a confidence level of 95% and a *P*-value of 0.001. This was also observed between the intraoperative M-I joint finding and M-I joint on CT with a confidence level of 95% and a *P*-value of 0.001.

Tables 3 shows the presentation of the status of cholesteatoma in both the preoperative CT and during operation. Moreover, a significant relation between intraoperative cholesteatoma extension and its HRCT findings of the disease was found with a confidence level of 95% and a *P*-value of 0.001 (Table 4).

## Discussion/Conclusions

High-resolution computed tomography of the temporal bone is considered the most crucial imaging technique for assessing the hypotympanum, facial recess, and the condition of the labyrinthine canal, which cannot be evaluated by otomicroscopy and for the possible variations and prevention of potential complications, as well as the detection of cholesteatoma within the temporal bone.<sup>7-9</sup> Although HRCT provides a direct visual window into the temporal bone providing visualization of

unavailable minute structural details before surgery including cases of otitis media, surgical visualization of the anatomy and pathology of the temporal bone is confirmed during surgery. That being said, HRCT shows a marked guiding quality for surgeons, especially for complex cases and revision surgery.<sup>10,11</sup> Noteworthy, many reports have shown the various consistency levels between CT findings regarding the presence of FCD and the perioperative findings, which are considered as the gold standard.<sup>3,12-14</sup>

Based on our observations, the most common eroded ossicle was the incus. There was a significant relation between incus erosion intraoperative and incus erosion on CT, with a confidence level of 95% and a *P*-value of 0.001 and between intraoperative M-I joint discontinuity and M-I joint discontinuity on CT, with a confidence level of 95% and a *P*-value of 0.001. These findings go in line with those of Karki et al,<sup>3</sup> who studied the correlation between preoperative HRCT findings and the surgical findings in cases with CSOM.

As for the findings of the middle ear bony ossicles, we found that malleus was eroded in only 1 case based on preoperative CT scan; however, during operation there were 5 cases with that observation. This finding highlights the high specificity of CT in detecting malleus erosion with a specificity of 96%; however, the sensitivity was markedly low (78%). On the contrary, erosion of either the incus or the stapes was detected by the preoperative CT scan with high accuracy; it showed 100% sensitivity, specificity, NPV, and PPV for both findings, although incus erosion was a more common finding compared with stapes erosion (12 cases vs 6 cases, respectively). However, based on the observations of Rogha et al,<sup>5</sup> they found that the accuracy of preoperative CT for stapes erosion was very minimal in addition to the low specificity of CT in the detection of incus erosions. They

**Table 4.** Status of cholesteatoma extending during preoperative CT imaging and intraoperatively.

	CHOLESTEATOMA EXTENDING IN INTRAOPERATIVE				TOTAL
	MESOTYMPANUM-HYPOTYMPANUM	IN MESOTYMPANUM	IN MESOTYMPANUM AND EPITYMPANUM	NO CHOLESTEATOMA	
Cholesteatoma extending in HRCT					
Mesotympanum-hypotympanum					
Count	10	0	0	0	10
% of total	25.60	0.00	0.00	0.00	25.60
In mesotympanum					
Count	0	4	0	0	4
% of total	0.00	10.30	0.00	0.00	10.30
In mesotympanum and epitympanum					
Count	0	0	2	0	2
% of total	0.00	0.00	5.10	0.00	5.10
Total					
Count	10	4	2	23	39
% of total	25.60	10.30	5.10	59.00	100.00

Abbreviations: CT, computed tomography; HRCT, high-resolution computed tomography.

hypothesized that this finding was the net result of the small size of the bone itself and the fine slices of 2 to 3 mm of temporal bone CT used during the study, and they further added that even finer cuts would improve such observations.<sup>5,15</sup> However, in our case we used 5 mm slices and were able to detect stapes and incus erosions with an accuracy of 100%. In contrast to our findings, multiple observations in the literature show that malleus is the ossicle whose presence can be predicted with greatest accuracy.<sup>16,17</sup> Moreover, Datta et al<sup>16</sup> and Rogha et al<sup>5</sup> found that the stapes was not consistently visualized by the preoperative CT; however, when it is seen it usually appeared as a structure of soft tissue density in the oval window niche. Subsequently, it was not possible for them to distinguish whether the stapes was eroded or was merely enveloped by soft tissue and this could explain the discrepancy in the observations. The reported minimal accuracy for stapes could be the result of the small size of the bone. Therefore, finer slices of the temporal bone CT of 2 to 3 mm are thought to help detect the status of the stapes.<sup>15</sup>

The sensitivity of observed tympanic perforation was 100% intraoperative in correlation with the finding of the CT reports. The most reported finding in cases of COM was M-I joint discontinuity. Computed tomography findings correlated very well with the surgical observations (100%) in cases of cholesteatoma. All cases reported as cholesteatoma in CT were confirmed at surgery with a sensitivity of 100% and a specificity of 100%. Similarly, we found the same result in another literature as they reported that preoperative CT scan findings correlated very well with the surgical findings for cholesteatoma.<sup>4</sup> Moreover, we found a very impressive 100%

sensitivity, specificity, NPV, and PPV of CT and intraoperative observation to detect sigmoid plate erosion. This finding goes in line with that of Rogha et al,<sup>5</sup> who studied the correlation between preoperative CT findings and surgical observation in COM cases. They found that the radiosurgical correlation was excellent for the sigmoidal plate erosion with a kappa statistic (*K*) of 1. A similar result was also noted in the literature.<sup>18</sup>

On the contrary, some CT findings such as tympanic membrane perforation, facial canal erosion, middle ear edematous mucosa, and Eustachian tube granulation did not show high accuracy in detecting them preoperatively; however, they showed very high sensitivity in comparison with the markedly low specificity in certain findings. Variable results have been reported in the literature regarding this matter as shown in Rogha et al's<sup>5</sup> study.

Noteworthy, this study has some limitations, the main of which is the small sample size of study participants which was 39 patients with COM at the end of the study. Also, patients who did not have CT scan during the preoperative period were excluded and that could have affected our sample size and the reliability of our findings as a result. Furthermore, we also believe that finer cuts than the 5 mm cuts used in this study would be of beneficial impact in the case of comparison of preoperative and intraoperative HRCT findings.

In conclusion, HRCT has shown good results with significant correlation of diagnostic value in comparison with the findings during surgery. Preoperative CT scan is beneficial and contributory in relation to diagnosis and decision-making in indicating operation to patients with COM. The significant correspondence

between HRCT and clinical findings may lead to a better diagnosis of probable problems before surgery and improves the success rate of cholesteatoma surgeries. Limitations of HRCT should be considered and improved by newer radiologic modalities.

### Acknowledgements

The authors would like to thank Ohud Hospital for providing us with the necessary access and tools in making this manuscript.

### Author Contributions

MA and RA contributed to the design, implementation and presentation of the research. MG and CK contributed to the analysis of the results and the writing of the manuscript.

### ORCID iD

Mariam Aljehani  <https://orcid.org/0000-0002-5826-2586>

### REFERENCES

- Nadol JB. Revision mastoidectomy. *Otolaryng Clin N Am.* 2006;39:723-740.
- Kangsarak J, Foonant S, Ruckphaopunt K, Navacharoen N, Teotrakul S. Extracranial and intracranial complications of suppurative otitis media. Report of 102 cases. *J Laryngol Otol.* 1993;107:999-1004.
- Karki S, Pokharel M, Suwal S, Poudel R. Correlation between preoperative high resolution computed tomography (CT) findings with surgical findings in chronic otitis media (com) squamosal type. *Kathmandu Univ Med J (KUMJ).* 2017;15:84-87.
- Majeed J, Sudarshan Reddy L. Role of CT mastoids in the diagnosis and surgical management of chronic inflammatory ear diseases. *Indian J Otolaryngol.* 2017;69:113-120.
- Rogha M, Hashemi SM, Mokhtarinejad F, Eshaghian A, Dadgostar A. Comparison of preoperative temporal bone CT with intraoperative findings in patients with cholesteatoma. *Iran J Otorhinolaryngol.* 2014;26:7-12.
- Vallabhaneni R, Srinivasa Babu C. HRCT temporal bone findings in CSOM: our experience in rural population of South India. *IOSR J Dent Med Sci.* 2016;15:49-53.
- Sagar NJ, Devasamudra CR. Clinical study of correlation between preoperative findings of HRCT with intra-operative findings of cholesteatoma in cases of CSOM. *Indian J Anatomy Surgery Head, Neck Brain.* 2017;3:1-5.
- Shah C, Shah P, Shah S. Role of HRCT temporal bone in preoperative evaluation of cholesteatoma. *Int J Med Sci Pub Heal.* 2014;3:69-73.
- Van de Water TR, Staecker H. *Otolaryngology: Basic Science and Clinical Review.* New York, NY: Thieme; 2006.
- Swartz JD, Goodman RS, Russell KB, Marlowe FI, Wolfson RJ. High-resolution computed tomography of the middle ear and mastoid. Part II: tubotympanic disease. *Radiology.* 1983;148:455-459.
- Watts S, Flood LM, Clifford K. A systematic approach to interpretation of computed tomography scans prior to surgery of middle ear cholesteatoma. *J Laryngol Otol.* 2000;114:248-253.
- Alzoubi FQ, Odat HA, Al-Balas HA, Saeed SR. The role of preoperative CT scan in patients with chronic otitis media. *Eur Arch Otorhinolaryngol.* 2009;266:807-809.
- Kanotra S, Gupta R, Gupta N, Sharma R, Gupta S, Kotwal S. Correlation of high-resolution computed tomography temporal bone findings with intra-operative findings in patients with cholesteatoma. *Indian J Otol.* 2015;21:280.
- Rai T. Radiological study of the temporal bone in chronic otitis media: prospective study of 50 cases. *Indian J Otol.* 2014;20:48.
- Sethom A, Akkari K, Dridi I, et al. [Preoperative CT scan in middle ear cholesteatoma]. *Tunis Med.* 2011;89:248-253.
- Datta G, Mohan C, Mahajan M, Mendiratta V. Correlation of preoperative HRCT findings with surgical findings in Unsafe CSOM. *J Dental Med Sci.* 2014;13:120-125.
- O'Donoghue G. Imaging the temporal bone. *Clin Otolaryngol Allied Sci.* 1987;12:157-160.
- Khavasi P, Malashetti S, SH CS. An evaluation of preoperative high resolution computed tomography of temporal bone in cholesteatoma. *Int J Otorhinolaryngol Head Neck Surg.* 2018;4:413-417.