

Correlation of Patient Symptoms With Labral and Articular Cartilage Damage in Femoroacetabular Impingement

Trevor Grace,* MD, Michael A. Samaan,[†] PhD, Richard B. Souza,^{†‡} PT, PhD, Thomas M. Link,[†] MD, PhD, Sharmila Majumdar,[†] PhD, and Alan L. Zhang,^{*§} MD

Investigation performed at the University of California–San Francisco, San Francisco, California, USA

Background: Femoroacetabular impingement (FAI) can lead to labral and articular cartilage injuries as well as early osteoarthritis of the hip. Currently, the association of patient symptoms with the progression of labral and articular cartilage injuries due to FAI is poorly understood.

Purpose: To evaluate the correlation between patient-reported outcome (PRO) scores and cartilage compositional changes seen on quantitative magnetic resonance imaging (MRI) as well as cartilage and labral damage seen during arthroscopic surgery in patients with FAI.

Study Design: Cohort study; Level of evidence, 3.

Methods: Patients were prospectively enrolled before hip arthroscopic surgery for symptomatic FAI. Patients were included if they had cam-type FAI without radiographic arthritis. All patients completed PRO scores, including the Hip disability and Osteoarthritis Outcome Score (HOOS) and a visual analog scale for pain. MRI with mapping sequences ($T_{1\rho}$ and T_2) on both the acetabular and femoral regions was performed before surgery to quantitatively assess the cartilage composition. During arthroscopic surgery, cartilage and labral injury grades were recorded using the Beck classification. Pearson and Spearman correlation coefficients were then obtained to evaluate the association between chondrolabral changes and PRO scores.

Results: A total of 46 patients (46 hips) were included for analysis (mean age, 35.5 years; mean body mass index [BMI], 23.9 kg/m²; 59% male). Increasing BMI was correlated with a more severe acetabular cartilage grade ($\rho = 0.37$; 95% CI, 0.08-0.65). A greater alpha angle was correlated with an increased labral tear grade ($\rho = 0.59$; 95% CI, 0.37-0.82) and acetabular cartilage injuries ($\rho = 0.61$; 95% CI, 0.42-0.80). With respect to PRO scores, increasing femoral cartilage damage in the anterosuperior femoral head region, as measured on quantitative MRI using $T_{1\rho}$ and T_2 mapping, correlated with lower (worse) scores on the HOOS Activities of Daily Living ($r = 0.35$; 95% CI, 0.06-0.64), Symptoms ($r = 0.32$; 95% CI, 0.06-0.57), and Pain ($r = 0.31$; 95% CI, 0.06-0.55) subscales. There was no correlation between PRO scores and acetabular cartilage damage or labral tearing found on quantitative MRI or during arthroscopic surgery.

Conclusion: Femoral cartilage damage, as measured on $T_{1\rho}$ and T_2 mapping, appears to have a greater correlation with clinical symptoms than acetabular cartilage damage or labral tears in patients with symptomatic FAI.

Keywords: hip; femoroacetabular impingement; hip arthroscopic surgery; magnetic resonance imaging; biology of cartilage

Femoroacetabular impingement (FAI) is a condition that involves abnormal morphology of the hip joint, and it has been shown to predispose patients to the early development of degenerative hip arthritis.^{1,10,15,30} The pathogenesis of FAI, initially described by Ganz et al,¹⁴ is thought to involve bony abutment of a mismatched acetabulum and femur during physiological motion, resulting in labral impaction and cartilage shearing that can culminate in advanced joint damage.³

This causal relationship between FAI, particularly cam type, and hip arthritis has fueled the use of minimally invasive hip procedures in recent years that aim to stabilize soft tissue damage and correct hip deformities to improve symptoms and possibly delay the progression to arthritis.^{4,6,33}

Classically, FAI manifests with the slow onset of groin pain that is intermittently exacerbated by high-impact activities, excessive demand on the hip, or prolonged flexion of the hip such as during sitting.²⁶ Patients who present with symptomatic FAI refractory to conservative treatment have generally been considered for either arthroscopic or open surgical intervention to correct the bony deformity

The Orthopaedic Journal of Sports Medicine, 6(6), 2325967118778785
DOI: 10.1177/2325967118778785
© The Author(s) 2018

This open-access article is published and distributed under the Creative Commons Attribution - NonCommercial - No Derivatives License (<http://creativecommons.org/licenses/by-nc-nd/4.0/>), which permits the noncommercial use, distribution, and reproduction of the article in any medium, provided the original author and source are credited. You may not alter, transform, or build upon this article without the permission of the Author(s). For reprints and permission queries, please visit SAGE's website at <http://www.sagepub.com/journalsPermissions.nav>.

and soft tissue/chondral injuries. These techniques have been shown to improve symptoms in patients with FAI, as indicated on multiple patient-reported outcome (PRO) scores including the Western Ontario and McMaster Universities Osteoarthritis Index (WOMAC), the University of California–Los Angeles (UCLA) activity score, the 36-Item Short Form Health Survey (Short Form–36) physical and mental component summaries, and the Merle d'Aubigné clinical score.^{5,13,28} Although symptoms improve after surgical intervention, it remains unclear how preoperative symptoms correlate with the natural progression of labral and articular cartilage injuries seen in these patients.

Although asymptomatic patients with bony deformities consistent with FAI have an increased likelihood of developing structural damage to the hip, such as labral lesions, cartilage thinning, and impingement pits,³⁰ many never develop symptoms or go on to develop advanced hip arthritis.³² As the rate of progression of joint degeneration varies considerably, identifying patients who would benefit most from surgical intervention for this deformity can be challenging. Understanding the correlation between clinical symptom severity and the progression of chondrolabral damage would better educate patients on the natural history of their condition and whether surgical intervention should be considered.

The present study aimed to correlate PRO scores of symptoms with magnetic resonance imaging (MRI)–based measures of the cartilage composition and gross structural damage in patients undergoing hip arthroscopic surgery for symptomatic FAI. The goal was to improve the understanding of how progressive structural injuries to the articular cartilage and labrum are associated with clinical symptoms. We hypothesized that higher grades of cartilage and labral damage seen intraoperatively as well as increasing $T_{1\rho}$ and T_2 cartilage relaxation times in the hip joint will correlate directly with more severe clinical symptoms.

METHODS

Patient Cohort

A power analysis was performed a priori using data from a preliminary cohort of patients with FAI before surgery at a single institution; these data were analyzed for correlations between $T_{1\rho}/T_2$ relaxation times in the anterosuperior sub-compartment and patient-reported Hip disability and Osteoarthritis Outcome Score (HOOS) results. Based on the correlation with the HOOS Pain subscale ($r = 0.36$) and HOOS Activities of Daily Living (ADL) subscale ($r = 0.32$), a 1-tailed analysis with $\alpha = 0.05$ and $\beta = 0.80$

revealed a required sample size of 40 patients to identify a significant relationship, should one exist. Patients were then prospectively enrolled from the institution's hip preservation clinic after obtaining institutional review board approval.

Patient age, body mass index (BMI), and sex were recorded. Patients were eligible for inclusion if they were aged 18 to 50 years, had a BMI $<30 \text{ kg/m}^2$, had a lateral center-edge angle (LCEA) $>20^\circ$, and were diagnosed with symptomatic cam-type or cam-predominant mixed-type FAI that was refractory to at least 6 weeks of conservative treatment including activity modification, physical therapy, and/or corticosteroid injections. While limited evidence exists on the ideal period of time to implement conservative interventions before considering hip arthroscopic surgery for FAI, 6 weeks was used in multiple previous high-quality studies, and as such, this threshold was utilized in the present analysis.^{21,22} Cam-type or cam-predominant mixed-type FAI was the focus for this analysis because of the strong association of cam lesions with labral tears and articular cartilage lesions.^{3,30} A cam lesion was defined as an alpha angle $\geq 55^\circ$ on a 45° Dunn lateral radiograph.¹¹ Patients who had evidence of progressive arthritic change (Tönnis grade ≥ 2) on preoperative radiographs were excluded from this analysis. Patients with a history of hip surgery were also excluded.

Imaging

Before surgery, radiographs, including anteroposterior, frog lateral, and 45° Dunn lateral views, were obtained on all patients. These were analyzed for calculation of the Tönnis grade, alpha angle (on Dunn lateral radiographs), and LCEA (on anteroposterior pelvis radiographs). All patients also underwent preoperative imaging of the affected hip using a 3-T MRI scanner and an 8-channel cardiac coil (GE Healthcare).

Imaging Analysis

The imaging protocol used in this study has been reported previously and included a 3-dimensional Spoiled Gradient Echo (SPGR) (Multi-Echo Data Image Combination [MERGE]) sequence for semiautomatic cartilage segmentation and a combined $T_{1\rho}$ and T_2 mapping sequence for assessing the cartilage composition.^{18,20,27} All imaging postprocessing was performed using custom-written MATLAB programs (The MathWorks), and femoral and acetabular cartilage regions were segmented using a semi-automated region of interest–based algorithm that relies on Bézier splines and edge detection.⁸

[§]Address correspondence to Alan L. Zhang, MD, Department of Orthopaedic Surgery, University of California–San Francisco, 1500 Owens Street, Box 3004, San Francisco, CA 94158, USA (email: alan.zhang@ucsf.edu).

^{*}Department of Orthopaedic Surgery, University of California–San Francisco, San Francisco, California, USA.

[†]Musculoskeletal and Quantitative Imaging Research Group, Department of Radiology and Biomedical Imaging, University of California–San Francisco, San Francisco, California, USA.

[‡]Department of Physical Therapy and Rehabilitation Science, University of California–San Francisco, San Francisco, California, USA.

One or more of the authors has declared the following potential conflict of interest or source of funding: This study was funded by the American Orthopaedic Society for Sports Medicine (YIG-2016-1) and the National Institute of Arthritis and Musculoskeletal and Skin Diseases (P50 AR060752 and F32 AR069458). A.L.Z. is a consultant for Stryker, has received educational support from Arthrex, and has received research support from Zimmer. T.M.L. has served on the Scientific Advisory Board for Pfizer (2015 and 2016), Regeneron Pharmaceuticals (2016), and GE Healthcare (2016).

This study was approved by the University of California–San Francisco Institutional Review Board (#14-14736).

Self-reported Outcomes

Preoperatively, patients were asked to complete validated PRO scores that included the HOOS and as well as a visual analog scale (VAS) for pain, which have previously been used to assess clinical symptoms in patients with FAI.^{17,24,37}

Surgical Protocol

Hip arthroscopic surgery was performed on each patient as indicated by his or her inclusion diagnosis. After standard arthroscopic portals were established, diagnostic hip arthroscopic surgery was conducted, during which the femoral and acetabular articular cartilage as well as labral tears were assessed and graded using the classification reported by Beck et al.⁷ The surgical procedure was then completed as standard of care based on the abnormality, with all patients undergoing femoroplasty and labral repair and patients undergoing chondroplasty or microfracture if a high-grade articular cartilage injury was present. Focal acetabuloplasty was performed in cases of mixed-type FAI in conjunction with femoroplasty.

Statistical Analysis

Correlation analyses were then performed to evaluate the association between PRO scores and articular cartilage injury grades as well as PRO scores and labral injury grades as assessed during arthroscopic surgery. Correlation analyses were also performed between PRO scores and quantitative MRI values obtained for the anterosuperior quadrant of the acetabulum and femur, which is a region known to suffer damage as a result of cam-type FAI.^{7,35} Pearson correlation coefficients (r) were obtained for correlations between continuous variables such as $T_{1\rho}/T_2$ relaxation times and PRO scores. Spearman correlation coefficients (ρ) were obtained for correlations between ordinal and continuous variables such as cartilage injury grades and PRO scores. Outcomes were also compared by sex using a 2-sample Student t test for continuous variables and a Wilcoxon signed-rank test for ordinal variables. All statistical analyses were performed on STATA software (version 15.0; StataCorp), with significance set to $P < .05$. The 95% CIs on all calculated correlation coefficients were included wherever possible.

RESULTS

Patient Cohort

A total of 46 patients (46 hips) were enrolled before hip arthroscopic surgery for symptomatic cam-type FAI (58.7%) or cam-predominant mixed-type FAI (41.3%), set by the power analysis. The cohort included 27 men (59%) and 19 women (41%), who had a mean age of 35.5 ± 9.8 years and a mean BMI of 23.9 ± 3.0 kg/m². There were 28 patients with Tönnis grade 0 hips (60.9%) and 18 patients with Tönnis grade 1 hips (39.1%). The mean alpha angle was $61.8^\circ \pm 4.8^\circ$ (range, 55° - 75°) (Table 1). The indication for surgery in all 46 patients was refractory hip pain,

TABLE 1

Demographics and Characteristics (N = 46 Patients)^a

Age, y	35.5 ± 9.8
BMI, kg/m ²	23.9 ± 3.0
Male, %	59
Alpha angle, deg	61.8 ± 4.8
LCEA, deg	33.3 ± 6.0
Labral tear grade	3 (2-3)
Tönnis grade	0 (0-1)
Acetabular cartilage grade	3 (2-3)
Femoral cartilage grade	1 (1-1)

^aData are shown as mean ± SD or median (interquartile range) unless otherwise specified. BMI, body mass index; LCEA, lateral center-edge angle.

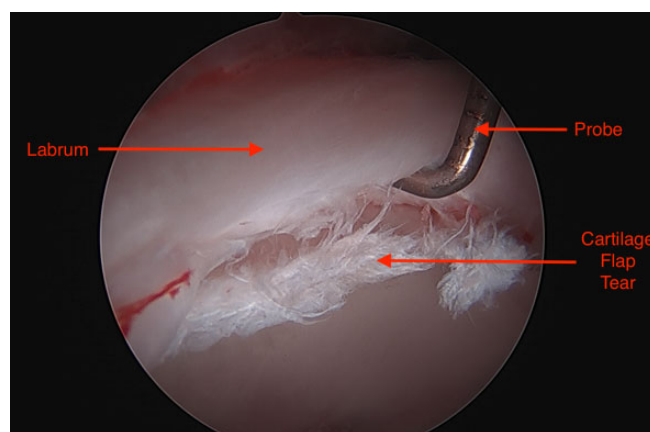


Figure 1. Arthroscopic view of a grade 2 cartilage injury at the anterosuperior acetabulum caused by cam-type femoroacetabular impingement. A probe is reflecting the labrum to reveal a cartilage flap tear at the chondrolabral junction.

despite at least 6 weeks of conservative treatment such as weight loss, physical therapy, anti-inflammatory drugs, and activity modification.

Correlations With Arthroscopic Findings

During hip arthroscopic surgery, 47.4% of patients were found to have a grade 2 labral tear, and 52.6% of patients were found to have a grade 3 labral tear. The majority of patients were found to have grade 2 (32.6%) or grade 3 (47.8%) acetabular cartilage damage, whereas femoral cartilage most commonly constituted grade 1 (54.4%) damage. Increasing BMI ($\rho = 0.37$; 95% CI, 0.08-0.65; $P = .01$) and increasing alpha angles ($\rho = 0.61$; 95% CI, 0.42-0.80; $P < .001$) correlated with higher grades of anterosuperior acetabular cartilage injuries seen intraoperatively (Figures 1 and 2 and Table 2). Increasing alpha angles ($\rho = 0.59$; 95% CI, 0.37-0.82; $P < .001$) also correlated with increasing grades of labral tears. Male patients were found to have higher median grades of acetabular cartilage injuries (3 vs 2, respectively; $P < .001$) and labral tears (3 vs 2, respectively; $P < .001$) compared with female patients (Table 2).

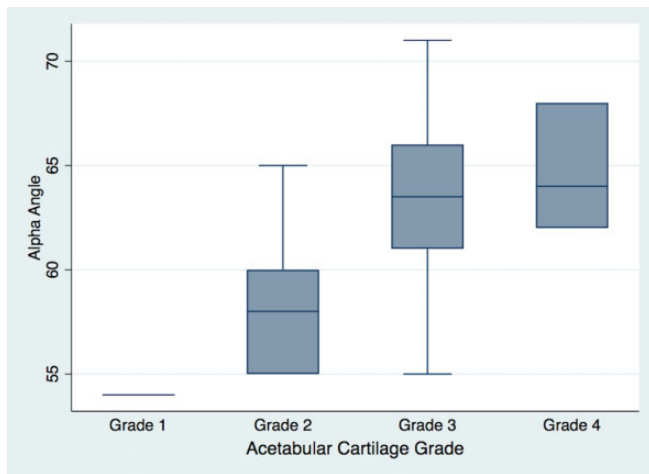


Figure 2. Distribution of intraoperative acetabular cartilage injury grades visualized during arthroscopic surgery based on alpha angles measured on preoperative radiographs. Increased alpha angles (in degrees) were correlated with higher grades of acetabular cartilage injuries. Values are presented as median (line), interquartile range (box), and 95% CI (error bars).

Correlations With PRO Scores

With respect to PRO scores, lower (worse) scores on the HOOS ADL subscale ($R = 0.35$, $P = .018$; 95% CI, 0.06-0.64), HOOS Symptoms subscale ($R = 0.32$, $P = .02$; 95% CI, 0.06-0.57), and HOOS Pain subscale ($R = 0.31$, $P = .01$; 95% CI, 0.06-0.55) were correlated with progressive femoral cartilage damage, as indicated by increasing $T_{1\rho}$ and T_2 relaxation times in the anterosuperior femoral head region (Figure 3 and Appendix Table A1). PRO scores did not demonstrate any correlations with acetabular cartilage damage or labral tearing found on quantitative MRI or during arthroscopic surgery, with no correlation of HOOS or VAS scores to acetabular $T_{1\rho}$ or T_2 values (Appendix Table A1).

A lower LCEA correlated with lower scores on the HOOS Symptoms subscale ($R = 0.30$, $P = .02$; 95% CI, 0.05-0.55). Increasing BMI was found to correlate with higher (worse) VAS pain scores ($R = 0.42$, $P = .005$; 95% CI, 0.13 to 0.71), HOOS Symptoms scores ($R = -0.31$, $P = .037$; 95% CI, -0.59 to -0.02), and HOOS ADL scores ($R = -0.32$, $P = .04$; 95% CI, -0.62 to -0.01).

DISCUSSION

FAI, particularly cam type, involves morphological abnormalities in the hip joint that predispose patients to labral and chondral damage during physiological motion.^{1,26} In addition to demonstrating that larger cam deformities correlate with increasingly severe labral and cartilage damage, the results of this study reveal that biochemical cartilage alterations in the femoral articular cartilage have a greater correlation with the severity of patient symptoms

than acetabular cartilage alterations or arthroscopically verified chondrolabral damage. To our knowledge, this is the first study to correlate patient-reported symptoms with intra-articular structural injuries in FAI, as seen both during hip arthroscopic surgery and on quantitative MRI.

Quantitative MRI with $T_{1\rho}$ and T_2 mapping is increasingly utilized for the detection of biochemical changes in articular cartilage before the development of obvious morphological damage.^{2,29} In particular, $T_{1\rho}$ sequences are sensitive to the proteoglycan content of hip and knee articular cartilage,^{2,19} and an inverse relationship has been demonstrated between $T_{1\rho}$ relaxation times and proteoglycan content in hyaline cartilage.¹² These imaging modalities are therefore useful in characterizing the natural history of FAI, as they detect the reduction in proteoglycan content that occurs in the early stages of arthritis before macroscopic cartilage damage.⁹ Multiple prior studies have reported on the prevalence and structural consequences of FAI in an asymptomatic population.^{16,30,38} However, the present study is the first to assess how the severity of clinical symptoms correlate with quantitative MRI changes in patients with symptomatic FAI undergoing surgery. The results of this study do not show a correlation between acetabular $T_{1\rho}$ or T_2 values and PRO scores, but lower scores on the HOOS Pain, Symptoms, and ADL subscales were found to correlate with femoral cartilage damage, as reflected by increasing $T_{1\rho}$ or T_2 relaxation times particularly in the anterosuperior aspect of the femoral head, where impingement occurs.

The HOOS is a reliable measure of a patient's hip function, originally used to assess outcomes after hip replacement.²⁵ It has since been validated for use in patients undergoing hip arthroscopic surgery¹⁷ and has been expanded to patients with FAI, who have consistently demonstrated lower scores than non-FAI controls.^{31,36} The correlation of lower HOOS scores with femoral-sided biochemical compositional changes, as shown in this study, may suggest that patients are more sensitive to the occurrence of femoral-sided damage in FAI. In addition, the location of this degeneration in the anterolateral region of the femoral head/neck junction is consistent with prior studies in showing that this is a common area of injuries in FAI and is often the area most under physiological stress from cam lesions.^{7,35}

The findings in this study further show that higher grade labral tearing on arthroscopic surgery correlated with male sex and increased alpha angles. In addition, higher grade acetabular cartilage damage correlated with male sex, increased alpha angles, and increased BMI. Our findings are supported by previous studies that similarly demonstrated that male sex, older age, and elevated alpha angles were independently associated with the presence of acetabular damage during hip arthroscopic surgery.^{23,34,38} Despite these findings, labral tearing and chondral damage seen intraoperatively did not correlate with PRO scores. While these results may seem counterintuitive, they are consistent with the findings of Westermann et al,³⁶ who showed that HOOS scores did not correlate well with macroscopic findings of damage during hip arthroscopic surgery for patients with FAI and that these scores correlated better with mental health, activity levels, and smoking status.

TABLE 2
Correlations With Arthroscopic Cartilage and Labral Findings^a

	Femoral Cartilage Grade		Acetabular Cartilage Grade		Labral Tear Grade	
	ρ Value	P Value	ρ Value	P Value	ρ Value	P Value
Age	0.23 (−0.11 to 0.57)	.12	−0.05 (−0.25 to 0.36)	.75	0.24 (−0.09 to 0.56)	.15
BMI	0.23 (−0.04 to 0.51)	.13	0.37 (0.08 to 0.65)	.01	0.11 (−0.24 to 0.45)	.54
Alpha angle	0.24 (−0.05 to 0.52)	.12	0.61 (0.42 to 0.80)	<.001	0.59 (0.37 to 0.82)	<.001
LCEA	0.01 (−0.32 to 0.34)	.96	−0.27 (−0.53 to 0.14)	.26	0.00 (−0.33 to 0.33)	>.99
Sex (male vs female), median grade	1 vs 1 (P = .64)		3 vs 2 (P < .001)		3 vs 2 (P < .001)	

^a95% CI in parentheses. BMI, body mass index; LCEA, lateral center-edge angle.

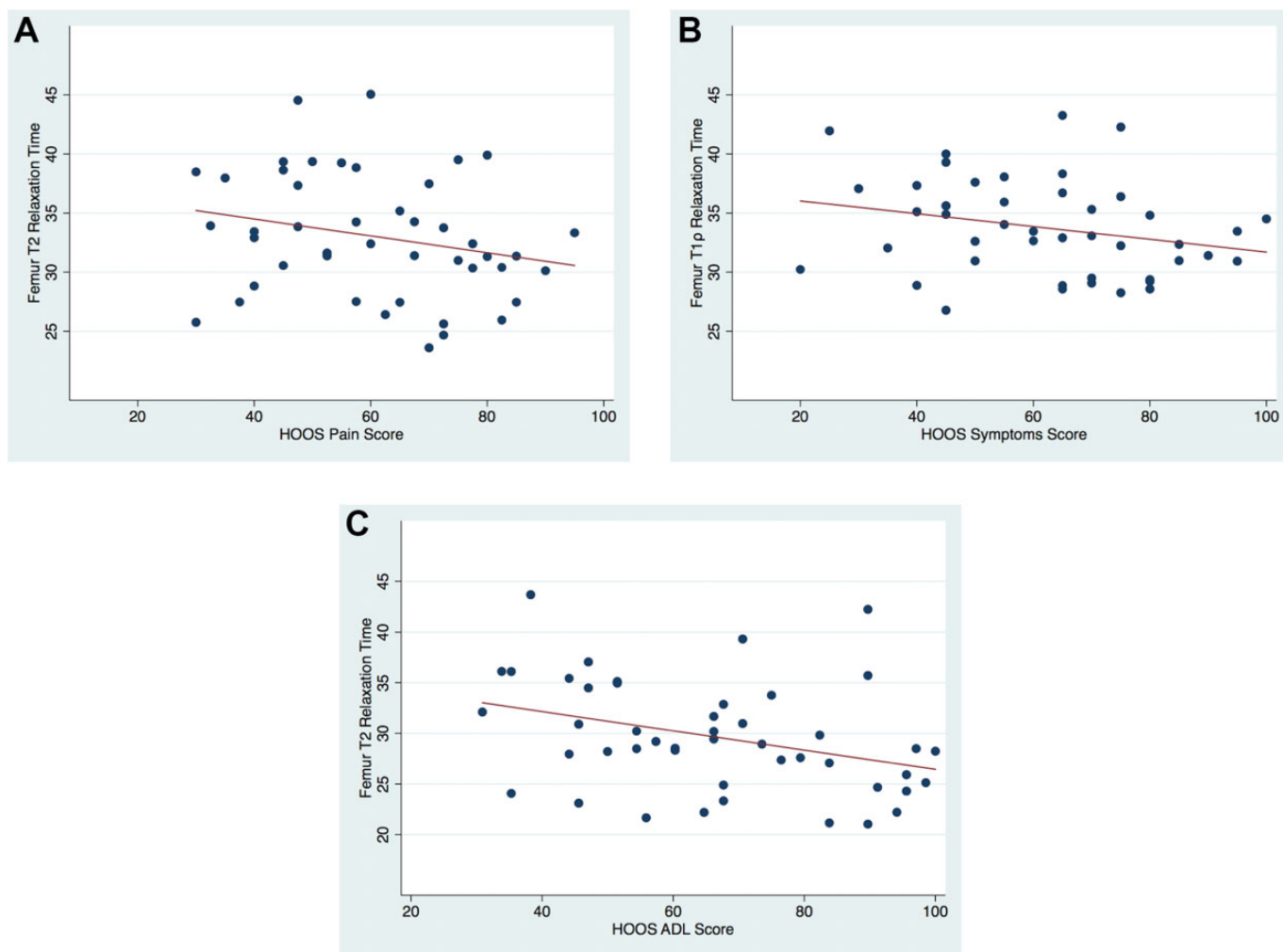


Figure 3. Correlation of patient-reported outcome scores: (A) Hip disability and Osteoarthritis Outcome Score (HOOS) Pain, (B) HOOS Symptoms, and (C) HOOS Activities of Daily Living (ADL) with T_{1ρ} or T₂ relaxation times (in milliseconds) in the anterosuperior femoral head region. Increased relaxation times correlated with lower (worse) scores.

Considering the poorly defined relationship between structural damage to the hip and clinical symptoms in patients with FAI, the application of quantitative MRI to this population as a compositional cartilage-imaging biomarker is diagnostically useful. The present study reveals that while higher grade injuries to the labrum or

acetabular cartilage do not consistently correlate with more severe clinical symptoms, progressive biochemical changes to the femoral cartilage, as demonstrated on quantitative MRI, may reflect the stage of the disease at which symptoms progress. This sequence suggests that damage to the labrum and acetabular cartilage as a result of the cam

deformity in FAI may thus occur at subclinical levels for a period of time before pain develops, and the progression of damage beyond the labrum and acetabular cartilage to the femoral cartilage may represent the threshold above which patient symptoms are most correlative. However, these findings are novel, and further research is needed to ascertain the true natural history of this condition and the effects of surgical treatment for FAI on both patient-reported symptoms as well as articular cartilage damage.

The strengths of the present study include the analysis of a large cohort of patients with symptomatic FAI. These patients underwent surgical management by the same surgeon (A.L.Z.), which minimizes the variability in data collection with respect to intraoperative grading and preoperative imaging. The study also adds quantitative MRI to the characterization of FAI, which expands on prior studies that only correlated findings on radiographs or standard MRI sequences with patient symptoms.

The limitations of the study include the inability to assess morphological changes over time in FAI and the fact that we did not include postoperative follow-up data. As these patients were studied before arthroscopic surgery, they were all experiencing symptoms to some scale, and a truly asymptomatic control group was not available. However, the goal of this study was to correlate the severity of patient symptoms with the extent and location of labral and articular cartilage injuries, which could be studied in a symptomatic cohort. Another limitation is that the correlations found in this study are moderate, with Pearson and Spearman correlation coefficients lying between 0.3 and 0.5 for the majority of relationships. However, the actual population correlation coefficients for patients with FAI may be moderate, considering the heterogeneous and multifactorial cause and pathogenesis of this condition. Further studies that involve higher numbers of patients will likely improve the precision of the correlation coefficients and narrow the 95% CIs; future studies should also involve preoperative and postoperative data as well as longer follow-up data to better characterize the long-term consequences of this condition. Last, while $T_{1\rho}$ and T_2 values are increasingly used to measure the cartilage composition in vivo, relaxation times are an estimate of the biochemical composition of cartilage and may inaccurately reflect the true extent of degeneration.

CONCLUSION

The severity of patient-reported symptoms caused by FAI correlates with femoral-sided articular cartilage damage, as measured on quantitative MRI by $T_{1\rho}$ and T_2 mapping, suggesting that femoral cartilage changes may have a greater influence on patient symptoms than labral tears or acetabular cartilage damage in FAI.

ACKNOWLEDGMENT

The authors acknowledge Hatef Mehrabian and Jasmine Rossi-Devries for their help with image acquisition and data processing.

REFERENCES

1. Agricola R, Heijboer MP, Bierma-Zeinstra SM, Verhaar JA, Weinans H, Waarsing JH. Cam impingement causes osteoarthritis of the hip: a nationwide prospective cohort study (CHECK). *Ann Rheum Dis*. 2013; 72(6):918-923.
2. Akella SV, Regatte RR, Gougoutas AJ, et al. Proteoglycan-induced changes in T1rho-relaxation of articular cartilage at 4T. *Magn Reson Med*. 2001;46(3):419-423.
3. Anderson LA, Peters CL, Park BB, Stoddard GJ, Erickson JA, Crim JR. Acetabular cartilage delamination in femoroacetabular impingement: risk factors and magnetic resonance imaging diagnosis. *J Bone Joint Surg Am*. 2009;91(2):305-313.
4. Beaulé PE, Allen DJ, Clohisey JC, Schoenecker P, Leunig M. The young adult with hip impingement: deciding on the optimal intervention. *J Bone Joint Surg Am*. 2009;91(1):210-221.
5. Beaulé PE, Le Duff MJ, Zaragoza E. Quality of life following femoral head-neck osteochondroplasty for femoroacetabular impingement. *J Bone Joint Surg Am*. 2007;89(4):773-779.
6. Beaulé PE, Speirs AD, Anwender H, et al. Surgical correction of cam deformity in association with femoroacetabular impingement and its impact on the degenerative process within the hip joint. *J Bone Joint Surg Am*. 2017;99(16):1373-1381.
7. Beck M, Kalhor M, Leunig M, Ganz R. Hip morphology influences the pattern of damage to the acetabular cartilage: femoroacetabular impingement as a cause of early osteoarthritis of the hip. *J Bone Joint Surg Br*. 2005;87(7):1012-1018.
8. Carballido-Gamio J, Link TM, Li X, et al. Feasibility and reproducibility of relaxometry, morphometric, and geometrical measurements of the hip joint with magnetic resonance imaging at 3T. *J Magn Reson Imaging*. 2008;28(1):227-235.
9. Dijkgraaf LC, de Bont LG, Boering G, Liem RS. The structure, biochemistry, and metabolism of osteoarthritic cartilage: a review of the literature. *J Oral Maxillofac Surg*. 1995;53(10):1182-1192.
10. Doherty M, Courtney P, Doherty S, et al. Nonspherical femoral head shape (pistol grip deformity), neck shaft angle, and risk of hip osteoarthritis: a case-control study. *Arthritis Rheum*. 2008;58(10):3172-3182.
11. Domayer SE, Ziebarth K, Chan J, Bixby S, Mamisch TC, Kim YJ. Femoroacetabular cam-type impingement: diagnostic sensitivity and specificity of radiographic views compared to radial MRI. *Eur J Radiol*. 2011;80(3):805-810.
12. Duvvuri U, Kudchodkar S, Reddy R, Leigh JS. T(1rho) relaxation can assess longitudinal proteoglycan loss from articular cartilage in vitro. *Osteoarthritis Cartilage*. 2002;10(11):838-844.
13. Espinosa N, Rothenfluh DA, Beck M, Ganz R, Leunig M. Treatment of femoro-acetabular impingement: preliminary results of labral refixation. *J Bone Joint Surg Am*. 2006;88(5):925-935.
14. Ganz R, Gill TJ, Gautier E, Ganz K, Krugel N, Berlemann U. Surgical dislocation of the adult hip a technique with full access to the femoral head and acetabulum without the risk of avascular necrosis. *J Bone Joint Surg Br*. 2001;83(8):1119-1124.
15. Gregory JS, Waarsing JH, Day J, et al. Early identification of radiographic osteoarthritis of the hip using an active shape model to quantify changes in bone morphometric features: can hip shape tell us anything about the progression of osteoarthritis? *Arthritis Rheum*. 2007;56(11):3634-3643.
16. Hack K, Di Primio G, Rakhra K, Beaulé PE. Prevalence of cam-type femoroacetabular impingement morphology in asymptomatic volunteers. *J Bone Joint Surg Am*. 2010;92(14):2436-2444.
17. Kemp JL, Collins NJ, Roos EM, Crossley KM. Psychometric properties of patient-reported outcome measures for hip arthroscopic surgery. *Am J Sports Med*. 2013;41(9):2065-2073.
18. Kumar D, Wyatt CR, Lee S, et al. Association of cartilage defects, and other MRI findings with pain and function in individuals with mild-moderate radiographic hip osteoarthritis and controls. *Osteoarthritis Cartilage*. 2013;21(11):1685-1692.

19. Li X, Kuo D, Theologis A, et al. Cartilage in anterior cruciate ligament-reconstructed knees: MR imaging T1 ρ and T2. Initial experience with 1-year follow-up. *Radiology*. 2011;258(2):505-514.
20. Li X, Wyatt C, Rivoire J, et al. Simultaneous acquisition of T1 ρ and T2 quantification in knee cartilage: repeatability and diurnal variation. *J Magn Reson Imaging*. 2014;39(5):1287-1293.
21. Mansell NS, Rhon DI, Marchant BG, Slevin JM, Meyer JL. Two-year outcomes after arthroscopic surgery compared to physical therapy for femoroacetabular impingement: a protocol for a randomized clinical trial. *BMC Musculoskelet Disord*. 2016;17:60.
22. Mansell NS, Rhon DI, Meyer J, Slevin JM, Marchant BG. Arthroscopic surgery or physical therapy for patients with femoroacetabular impingement syndrome: a randomized controlled trial with 2-year follow-up. *Am J Sports Med*. 2018;46(6):1306-1314.
23. Nepple JJ, Carlisle JC, Nunley RM, Clohisey JC. Clinical and radiographic predictors of intra-articular hip disease in arthroscopy. *Am J Sports Med*. 2011;39(2):296-303.
24. Newman JT, Briggs KK, McNamara SC, Philippon MJ. Revision hip arthroscopy: a matched-cohort study comparing revision to primary arthroscopy patients. *Am J Sports Med*. 2016;44(10):2499-2504.
25. Nilsdotter AK, Lohmander LS, Klassbo M, Roos EM. Hip disability and Osteoarthritis Outcome Score (HOOS): validity and responsiveness in total hip replacement. *BMC Musculoskelet Disord*. 2003;4:10.
26. Parvizi J, Leunig M, Ganz R. Femoroacetabular impingement. *J Am Acad Orthop Surg*. 2007;15(9):561-570.
27. Padoia V, Gallo MC, Souza RB, Majumdar S. Longitudinal study using voxel-based relaxometry: association between cartilage T1 ρ and T2 and patient reported outcome changes in hip osteoarthritis. *J Magn Reson Imaging*. 2017;45(5):1523-1533.
28. Philippon MJ, Briggs KK, Yen YM, Kuppersmith DA. Outcomes following hip arthroscopy for femoroacetabular impingement with associated chondrolabral dysfunction: minimum two-year follow-up. *J Bone Joint Surg Br*. 2009;91(1):16-23.
29. Rakhra KS, Lattanzio PJ, Cardenas-Blanco A, Cameron IG, Beaulé PE. Can T1- ρ MRI detect acetabular cartilage degeneration in femoroacetabular impingement? A pilot study. *J Bone Joint Surg Br*. 2012;94(9):1187-1192.
30. Reichenbach S, Leunig M, Werlen S, et al. Association between cam-type deformities and magnetic resonance imaging-detected structural hip damage: a cross-sectional study in young men. *Arthritis Rheum*. 2011;63(12):4023-4030.
31. Samaan MA, Schwaiger BJ, Gallo MC, et al. Joint loading in the sagittal plane during gait is associated with hip joint abnormalities in patients with femoroacetabular impingement. *Am J Sports Med*. 2017;45(4):810-818.
32. Sankar WN, Nevitt M, Parvizi J, Felson DT, Agricola R, Leunig M. Femoroacetabular impingement: defining the condition and its role in the pathophysiology of osteoarthritis. *J Am Acad Orthop Surg*. 2013;21(suppl 1):S7-S15.
33. Sing DC, Feeley BT, Tay B, Vail TP, Zhang AL. Age-related trends in hip arthroscopy: a large cross-sectional analysis. *Arthroscopy*. 2015;31(12):2307-2313.
34. Suarez-Ahedo C, Gui C, Rabe SM, Chandrasekaran S, Lodhia P, Domb BG. Acetabular chondral lesions in hip arthroscopy: relationships between grade, topography, and demographics. *Am J Sports Med*. 2017;45(11):2501-2506.
35. Tannast M, Goricki D, Beck M, Murphy SB, Siebenrock KA. Hip damage occurs at the zone of femoroacetabular impingement. *Clin Orthop Relat Res*. 2008;466(2):273-280.
36. Westermann RW, Lynch TS, Jones MH, et al. Predictors of hip pain and function in femoroacetabular impingement: a prospective cohort analysis. *Orthop J Sports Med*. 2017;5(9):2325967117726521.
37. White BJ, Patterson J, Herzog MM. Bilateral hip arthroscopy: direct comparison of primary acetabular labral repair and primary acetabular labral reconstruction. *Arthroscopy*. 2018;34(2):433-440.
38. Wyles CC, Norambuena GA, Howe BM, et al. Cam deformities and limited hip range of motion are associated with early osteoarthritic changes in adolescent athletes: a prospective matched cohort study. *Am J Sports Med*. 2017;45(13):3036-3043.

APPENDIX

TABLE A1
Correlations With Patient-Reported Outcome Scores^a

	HOOS Pain		HOOS Symptoms		HOOS ADL		HOOS Sports		HOOS QOL		VAS for Pain	
	r/ ρ	P	r/ ρ	P	r/ ρ	P	r/ ρ	P	r/ ρ	P	r/ ρ	P
Age	-0.16	.31	0.16	.23	-0.10	.52	0.08	.58	0.05	.73	-0.02	.91
	(-0.47 to 0.15)		(-0.10 to 0.42)		(-0.40 to 0.20)		(-0.20 to 0.36)		(-0.23 to 0.32)		(-0.31 to 0.27)	
BMI	-0.19	.23	-0.31	.037	-0.32	.04	-0.17	.27	-0.23	.072	0.42	.005
	(-0.51 to 0.12)		(-0.59 to -0.02)		(-0.62 to -0.01)		(-0.48 to 0.13)		(-0.47 to 0.02)		(0.13 to 0.71)	
Alpha angle	0.17	.27	-0.02	.93	0.09	.55	-0.03	.82	-0.15	.16	0.16	.39
	(-0.13 to 0.47)		(-0.35 to 0.32)		(-0.21 to 0.40)		(-0.30 to 0.24)		(-0.37 to 0.06)		(-0.20 to 0.52)	
LCEA	0.08	.60	0.30	.02	0.10	.47	0.24	.11	0.19	.13	-0.02	.91
	(-0.22 to 0.38)		(0.05 to 0.55)		(-0.18 to 0.38)		(-0.05 to 0.54)		(-0.06 to 0.44)		(-0.32 to 0.28)	
Femoral cartilage grade	-0.27	.07	-0.11	.46	-0.25	.10	-0.20	.16	-0.03	.87	-0.07	.65
	(-0.58 to 0.02)		(-0.41 to 0.18)		(-0.55 to 0.05)		(-0.47 to 0.08)		(-0.33 to 0.28)		(-0.39 to 0.24)	
Acetabular cartilage grade	-0.21	.17	-0.25	.09	-0.25	.08	-0.25	.08	-0.17	.26	0.23	.09
	(-0.52 to 0.09)		(-0.53 to 0.04)		(-0.54 to 0.03)		(-0.53 to 0.03)		(-0.47 to 0.13)		(-0.03 to 0.49)	
Labral tear grade	-0.02	.92	-0.01	.94	-0.06	.73	-0.10	.54	-0.07	.66	0.23	.14
	(-0.34 to 0.31)		(-0.35 to 0.33)		(-0.38 to 0.27)		(-0.41 to 0.21)		(-0.40 to 0.25)		(-0.08 to 0.53)	
T ₁ ρ of femur	-0.21	.08	-0.32	.02	-0.30	.053	-0.18	.19	-0.17	.26	0.12	.44
	(-0.45 to 0.02)		(-0.57 to -0.06)		(-0.59 to 0.004)		(-0.44 to 0.09)		(-0.47 to 0.13)		(-0.19 to 0.42)	
T ₂ of femur	-0.31	.01	-0.26	.04	-0.35	.018	-0.26	.056	-0.17	.18	0.11	.50
	(-0.55 to -0.06)		(-0.52 to -0.01)		(-0.64 to -0.06)		(-0.53 to 0.01)		(-0.43 to 0.08)		(-0.21 to 0.43)	
T ₁ ρ of acetabulum	0.09	.50	-0.13	.35	-0.23	.10	-0.17	.24	-0.23	.061	-0.02	.90
	(-0.17 to 0.35)		(-0.41 to 0.15)		(-0.50 to 0.04)		(-0.44 to 0.10)		(-0.47 to 0.01)		(-0.31 to 0.27)	
T ₂ of acetabulum	-0.07	.60	-0.21	.15	-0.06	.74	-0.21	.18	-0.25	.053	0.05	.73
	(-0.32 to 0.19)		(-0.50 to 0.07)		(-0.40 to 0.28)		(-0.51 to 0.09)		(-0.51 to 0.003)		(-0.23 to 0.33)	
Sex (male vs female), median score ^b	65.0 vs 56.3 (P = .25)		65 vs 65 (P = .85)		67.7 vs 64.7 (P = .67)		31.3 vs 37.5 (P = .90)		18.8 vs 25.0 (P = .32)		4 vs 3 (P = .22)	

^a95% CI in parentheses. ADL, Activities of Daily Living; BMI, body mass index; HOOS, Hip disability and Osteoarthritis Outcome Score; LCEA, lateral center-edge angle; QOL, Quality of Life; VAS, visual analog scale.

^bLower scores on the HOOS and higher scores on the VAS indicate worse outcomes.