

Minimally invasive open reduction combined with proximal femoral hollow locking plate in the treatment of Pauwels type III femoral neck fracture

Gang Wang^{1,2,*}, Yong Tang^{2,3,*}, Bin Wang¹ and Huilin Yang¹ 

Abstract

Objective: This study was performed to investigate the clinical effects of minimally invasive open reduction and internal fixation with a proximal femoral hollow locking plate on Pauwels type III femoral neck fractures.

Methods: The clinical data of 45 patients aged 32.0 ± 8.1 years (range, 19–45 years) with Pauwels type III femoral neck fractures treated from March 2012 to August 2016 were retrospectively analyzed. All patients underwent anterolateral minimally invasive open reduction and proximal femoral hollow locking plate fixation of the hip joint. Garden's index was used to evaluate the quality of fracture reduction. Complications and fracture healing were recorded in all patients. At the last follow-up, the functional outcome was recorded using the Harris hip score.

Results: No complications such as femoral neck shortening, internal fixation loosening, or refracture occurred. However, three patients required reoperation (one with nonunion and two with femoral head necrosis). At the last follow-up, the mean Harris hip score was 92.1 ± 4.5 (range, 76–98). The rate of excellent and good Harris hip scores was 93.3%.

Conclusion: The herein-described strategy for Pauwels type III femoral neck fractures is advantageous in terms of high reduction quality, firm fixation, and prevention of neck shortening.

¹Department of Orthopaedics, The First Affiliated Hospital of Soochow University, Suzhou, Jiangsu, China

²Department of Orthopaedics, No. 98 Hospital of PLA, Huzhou, Zhejiang, China

³Department of Orthopaedics, Southwest Hospital, Third Military Medical University, Chongqing, China

*These authors contributed equally to this work.

Corresponding author:

Huilin Yang, Department of Orthopaedics, The First Affiliated Hospital of Soochow University, No. 899 Pinghai Road, Suzhou, Jiangsu 215006, China.

Email: suzhouyangl@163.com



Keywords

Minimally invasive, open reduction, proximal femoral hollow locking plate, Pauwels type III femoral neck fracture, Harris hip score, functional outcome

Date received: 13 December 2018; accepted: 25 April 2019

Introduction

Femoral neck fractures are the most common and destructive injury in clinical orthopedics, and such fractures reduce lower limb movement and seriously affect patients' quality of life.¹ Bone nonunion and necrosis of the femoral head are the most common complications of femoral neck fractures.² The reason for these complications is the relatively poor blood supply to the femoral head, which is mainly supplied by the branches of the internal and external femoral artery.³ The treatment of femoral neck fractures is particularly difficult in young adults because of the extremely high incidence of femoral head necrosis, which is known as the "unsolved fracture" among doctors in the field of orthopedic trauma.⁴ The Garden and Pauwels classification systems are still recognized as the clinical mainstays for femoral neck fractures and can guide surgery and treatment. Garden type III and IV fractures typically occur in young adults as a result of high-energy trauma.⁵ However, some experts believe that the Pauwels classification is more accurate in evaluation of the severity of fracture injuries. Displaced Pauwels type III femoral neck fractures are quite common in young adults. Surgical options include open or closed reduction plus internal fixation and hip arthroplasty.⁶ For this fracture pattern, orthopedic surgeons widely agree that anatomical reduction and effective internal fixation is the most effective treatment.^{7,8} Hip preservation surgery is usually chosen for young adults, but this procedure is

associated with many potential complications, including femoral neck shortening, bone nonunion, and femoral head necrosis. Although various internal fixation methods have been developed for this type of fracture, none can completely avoid the occurrence of the above complications.

Placement of three hollow screws is currently one of the most common clinical methods for fixation of femoral neck fractures. However, this technique has a high failure rate for Pauwels type III femoral neck fractures because of high shear stress and poor biomechanical stability.⁵ Therefore, the screw-plate system is thought to be superior for fixation of Pauwels type III femoral neck fractures.^{9,10} A proximal femoral hollow locking plate is a new internal fixation system for femoral neck fractures and is designed according to the anatomical structure and biomechanical characteristics of the femoral neck¹¹ (Figure 1). The three hollow locking screws are arranged in a triangle with strong stability, and the diameter of the screw thread at the end of the hollow locking screws changes from small to large, which has a certain pressure effect during step-by-step locking. In addition, a femoral shaft locking hole is present at the lower end of the plate; this allows for combination of the plate, femoral neck, and femoral shaft, enhancing mechanical conduction and dispersion. Therefore, the proximal femoral hollow locking plate has the strong advantage of stable mechanical support.

We have treated Pauwels type III femoral neck fractures using the proximal femoral triangular locked plate system. Based on



Figure 1. Triangular locking plate internal fixation system.

our experience, we hypothesized that surgical internal fixation can be performed as a minimally invasive operation with little damage and few complications. It may be more effective than the traditional technique involving three hollow locking screws. In the present retrospective study, we analyzed patients with refractory Pauwels type III femoral neck fractures who were treated with minimally invasive open reduction and a proximal femoral triangular locked plate system from March 2012 to August 2016. This article summarizes the key technical aspects of this internal fixation method.

Patients and methods

The ethics committee of the First Affiliated Hospital of Soochow University approved this retrospective study, and informed consent was obtained from all patients. This study included patients with Pauwels type III femoral neck fractures who underwent fixation with a proximal femoral hollow locking plate (Double Engine Medical Material Co., Ltd., Xiamen, China) from March 2012 to August 2016. The Pauwels classification is based on the angle between the fracture line of the distal fragment and the horizontal line to determine the shear stress and compressive force.¹² A Pauwels type III femoral neck fracture refers to an angle of $>50^\circ$.¹² All fracture types were

evaluated and recorded according to the Garden classification system, anatomical site, and Pauwels classification system.

The inclusion criteria were a displaced Pauwels type III femoral neck fracture, treatment with the minimally invasive Watson–Jones approach and fixation with a proximal femoral hollow locking plate, and an age of 18 to 50 years. The exclusion criteria were an injury duration of >3 weeks or combination with other multiple traumas; osteoporosis or severe underlying diseases such as diabetes mellitus, hypertension, or previous cerebrovascular event; hip deformities such as rheumatoid arthritis, ankylosing spondylitis, or acetabular dysplasia; a history of ipsilateral hip or femur fracture; and a follow-up time of <12 months.

Surgical protocol

General anesthesia or epidural anesthesia was used during surgery, and the patients were laid in the supine position. Reduction was finished in the traction bed. If more than three attempts at reduction failed to achieve satisfactory results, we performed open reduction. The minimally invasive Watson–Jones approach was adopted,¹³ with an approximately 4- to 5-cm surgical incision extending from the anterior superior iliac spine to the anterior inferior iliac spine, 1 cm from the leading edge of the

anterior femoral trochanter. The joint capsule was exposed along the gap between the tensor fascia latae and the gluteus medius muscle. According to the position of the fracture line, a T-type minimally invasive incision was performed to partially open the anterior joint capsule. At this time, we needed to pay attention to the basilar artery ring and remove congestion and blood clots. First, two Kirschner needles were drilled into the femoral head to assist in reduction (Figure 3(c)). The assistant contributed to traction, abduction, and internal rotation of the affected limb to achieve anatomical reduction at the fracture end. Two Kirschner needles were drilled into the superior trochanter to temporarily stabilize

the fracture end (Figure 3(d)). Next, a longitudinal incision was made downward at the greater trochanter of the femur, about 4 to 5 cm in length. The skin, subcutaneous tissue, and fascia latae were cut in turn to expose the lateral femur. The proximal femoral hollow locking plate was firmly placed under the greater trochanter. The guide needle was drilled into the locating hole, and a C-arm X-ray machine was used to observe whether the locating guide needle was in the proper position. The steel plate was fixed on the bone surface by transverse locking nails at the farthest end of the drilling hole, and the third, second, and first hollow locking compression nails were then screwed in sequence by drilling holes

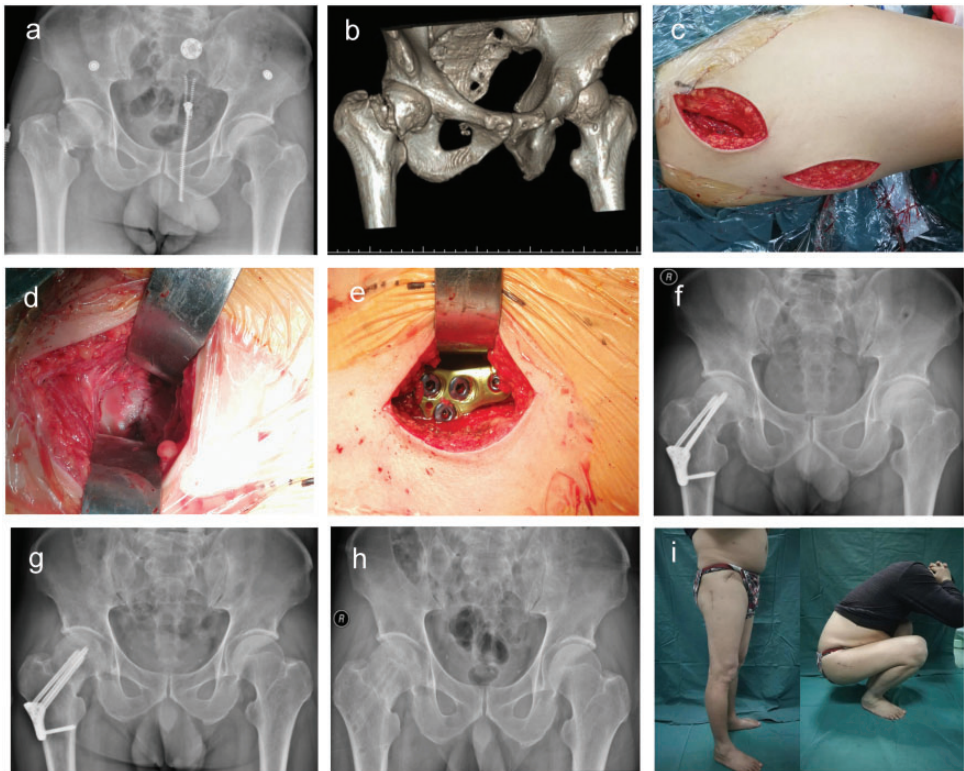


Figure 2. Male patient, 42 years old, Pauwels type III femoral neck fracture (right). (a) Preoperative X-rays. (b) Preoperative computed tomography. (c) Incision. (d) Fracture reduction. (e) Triangular locked plate fixation. (f) Postoperative X-rays (3 days). (g) X-rays showing bone union after 14 months. (h) X-rays after removal of internal fixation. (i) Hip motion.

(Figure 2(c)–(e)). Finally, the Kirschner wire was extracted, the fracture reduction and internal fixation positions were confirmed by the C-arm X-ray machine again, and the incision was sutured.

Postoperative management and evaluation

Postoperative analgesia, anticoagulation, and infection prevention were routinely performed. The injured limb was fixed with antirotation shoes. Isometric contraction exercises of the quadriceps femoris and active and passive flexion and extension exercises of the ankle could be carried out on the second day after surgery. Non-weight-bearing flexion and extension exercises of the knee and hip joint were gradually performed after the incisional pain had been relieved in a later stage.

Oral rivaroxaban tablets were taken at 10 mg/day for 2 weeks after the operation to prevent thrombosis. All patients were followed up on site at the outpatient

clinic. Partial weight training exercises were gradually performed beginning 2 to 3 months after the operation according to the radiographic evidence of fracture healing. The degree of bone remodeling and fracture healing were assessed by computed tomography 6 months after surgery to determine whether to start total weight training exercise.

The patients were required to return to the hospital for follow-up at 1, 3, 6, 9, and 12 months after surgery and then once per year thereafter (Figure 2(f), (g); Figure 3(e)–(g)). Garden's index¹⁴ was used to evaluate the quality of fracture reduction. The anteroposterior X-ray of a normal person showed an angle of 160° between the internal margin of the femoral shaft and the pressure trabecula of the medial femoral head and an angle of 180° between the axis of the femoral head and the axis of the femoral neck in the lateral X-ray. Garden's index was divided into the following three levels: grade I, anatomical reduction with a normal Garden's index; grade II, acceptable reduction with an

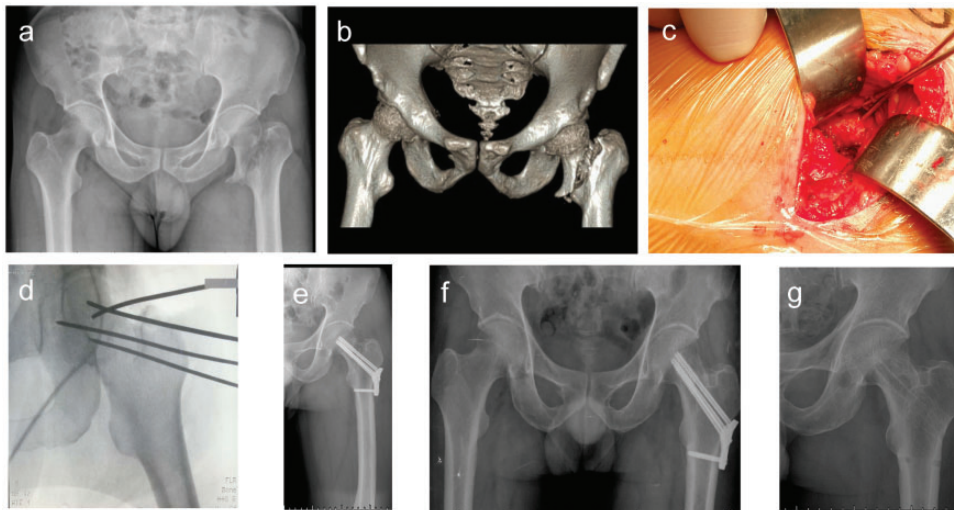


Figure 3. Male patient, 28 years old, Pauwels type III femoral neck fracture (left). (a) Preoperative X-rays. (b) Preoperative computed tomography. (c) Fracture reduction. (d) C-arm X-ray fluoroscopy. (e) Postoperative X-rays (3 days). (f) X-rays showing bone union after 12 months. (g) X-rays after removal of internal fixation.

anteroposterior and lateral Garden's index of 155° to 180° ; and grade III, unsatisfactory reduction with an anteroposterior Garden's index of $<155^\circ$ or lateral Garden's index of $>180^\circ$.

The healing of the femoral neck fracture, shortening of the femoral neck, femoral head necrosis, tip–apex distance of all hollow nails, and internal fixation were evaluated by X-ray and computed tomography scans.¹⁵ At the last follow-up, the functional outcome was recorded using the Harris hip score (Figure 2(h), (i)).¹⁶ The Harris hip score was considered excellent at 90 to 100, good at 80 to 89, fair at 70 to 79, and poor at <70 . All patients' outcomes were assessed by the same two observers.

Results

In total, 45 patients (25 men, 20 women) with femoral neck fractures were enrolled in this study. Their mean age was 32.0 ± 8.1 years (range, 19–45 years). According to the Garden classification, 34 fractures were Garden type III and 11 were Garden type IV. According to the anatomical site classification, 19 patients had subcapital femoral neck fractures and 26 had transcervical fractures. All patients had Pauwels type III femoral neck fractures with a mean Pauwels angle of $78.4^\circ \pm 3.9^\circ$ (Figure 2(a), (b); Figure 3(a), (b)). All patients had closed fractures and were treated with tibial tubercle traction after admission. The mean interval between the injury and operation was 1.6 ± 1.7 days (range, 1–6 days).

All patients successfully underwent open reduction and internal fixation with a proximal femoral hollow locking plate using the minimally invasive Watson–Jones approach. The mean operative time was 75.4 ± 12.3 minutes (range, 60–95 minutes), and the mean intraoperative blood loss was 90.0 ± 12.3 mL (range, 78–105 mL). All 45 patients were followed up for 25.7

± 4.2 months (range, 14–31 months). The tip–apex distance of all hollow nails was measured and ranged from approximately 11 to 26 mm. No complications, such as femoral neck shortening, internal fixation loosening, or refracture, occurred in this study. However, three patients required a reoperation (one with nonunion and two with necrosis of the femoral head). The fracture union rate of this treatment was high at 93.3% (Table 1). The mean Harris hip score was 92.1 ± 4.5 (range, 76–98). Thirty-two patients had an excellent outcome and 10 had a good outcome on the Harris scale. Therefore, the rate of excellent and good Harris hip scores was 93.3%. No perioperative complications occurred,

Table 1. Patient demographics

| Variable | |
|-------------------------------------|----------------------------|
| Age, years | |
| Mean | 32.0 ± 8.1 |
| Range | 19–45 |
| Sex | |
| Male | 25 |
| Female | 20 |
| Classification | |
| Garden type III | 34 |
| Garden type IV | 11 |
| Anatomical site classification | |
| Subcapital femoral neck fractures | 19 |
| Transcervical fractures | 26 |
| Average Pauwels angle | $78.4^\circ \pm 3.9^\circ$ |
| Follow-up, months | |
| Mean | 25.7 ± 4.2 |
| Range | 14–31 |
| Harris hip score | 92.1 ± 4.5 |
| Union | 93.3% |
| Femoral neck shortening | 0 |
| Secondary displacement and nonunion | 1 |
| Avascular necrosis | 2 |
| Bed rest-related complications | 0 |
| 1-year mortality | 0 |
| Reoperation | 3 |

such as deep vein thrombosis, pulmonary embolism, or urinary tract infection.

Discussion

Femoral neck fractures are often caused by high-energy injuries in young adults. As a result, fracture displacement is obvious, and most are Pauwels type III fractures, which are difficult to reduce. Because of the high vertical shear stress and poor stability of this type of fracture, bone nonunion and femoral head ischemic necrosis readily occur.^{17–19} The occurrence of femoral head necrosis is significantly related to the degree of fracture displacement and the quality of fracture reduction.^{20,21} Nonunion and avascular necrosis of the femoral head can be significantly reduced by high-quality reduction and internal fixation. Therefore, the aim of treatment of femoral neck fractures in young adults is to achieve anatomical reduction and stable fixation, prevent femoral neck shortening, reduce the risk of complications, and retain the femoral head.²²

The choice of open versus closed reduction treatment is controversial.^{22,23} Some studies have emphasized that closed reduction and internal fixation should be the routine treatment strategy for femoral neck fractures. Open reduction should be given priority only when closed reduction fails because closed reduction and internal fixation with a C-arm X-ray machine can avoid destruction of the blood supply of the femoral head. Therefore, this method can maximize the protection of the blood supply and reduce the risk of bleeding and postoperative infection. Anatomical reduction is difficult to achieve by closed reduction, especially in cases of anterior and posterior displacement, which cannot be completely corrected. The main reasons are the difficulty in controlling the rotation of the femoral head and in achieving anatomical reduction through longitudinal traction, which is the

main hurdle in approaching anatomical reduction. Bone compression at the fracture end is another factor affecting reduction and bone healing. The projection angle error generated by the C-arm X-ray machine has a certain impact on the judgment of intraoperative fracture reduction, especially the shielding effect caused by the great rotor during lateral projection. Therefore, the concept of “refractory femoral neck fracture” has been proposed, which refers to fractures that are highly likely to fail in closed reduction and require open reduction.²⁴ Many studies have stressed the use of open reduction and internal fixation through the Watson–Jones approach for displaced femoral neck fractures in young adults. This could effectively be achieved by capsulotomy and decompression and thus facilitate restoration of the blood supply to the femoral head.²⁵ In the present study, 45 displaced Pauwels type III femoral neck fractures were treated with open reduction and internal fixation via the minimally invasive Watson–Jones approach. The length of the incision was about 4 to 5 cm, which is significantly shorter than that in the traditional lateral Watson–Jones approach. According to Garden’s index, the reduction quality of all cases was grade I. This quality of reduction was significantly better than that achieved with closed reduction. The incidence of postoperative nonunion and femoral head necrosis was also lower. These findings indicate that open reduction might not increase the risk of complications, and the results of our study are consistent with those of similar recent studies.^{26,27}

No consensus has been reached on the optimal internal fixation method for Pauwels type III femoral neck fracture. Historically, three hollow screws were routinely used to treat femoral neck fractures, and good clinical results were achieved.^{28–30} The three hollow screws could tighten the fracture end and promote fracture healing

by sliding compression that relies on contraction of the hip muscles and the weight of the injured limb. Placement of these three hollow screws is relatively easy, the learning curve is short, and the operation is less traumatic for the patient. Moreover, the hollow structure of the screws can reduce the pressure in the joint cavity. However, many disadvantages of the use of three hollow screws have become increasingly obvious. The incidences of loosening of the internal fixation and shortening of the femoral neck are relatively high, especially in patients with Pauwels type III femoral neck fractures. This is because bone resorption occurs at the fracture end during fracture healing, and the design of the hollow screw (half-thread) cannot maintain the length of the femoral neck. In particular, the screw tail is located outside of the femoral trochanter, where the bone is relatively loose, the supporting force is weak, and the holding force of the fracture block is inadequate, resulting in a high risk of loosening of the internal fixation.³¹ Shortening of the femoral neck has a significant effect on gait and muscle strength and is thus closely related to a poor functional prognosis.^{32,33} Furthermore, the nonunion rate of using three hollow screws for treatment of Pauwels type III femoral neck fractures in young adults is high at 19%.³⁴ Biomechanical analyses have shown that the compression direction is consistent with the longitudinal direction of the screw, which is considered the main reason for the high failure of fixation by three hollow screws.⁹ With the development of internal fixation materials, Pauwels type III fractures are being treated increasingly more often by application of the dynamic hip screw, the dynamic hip screw combined with a hollow screw, femoral proximal bone plate, and intramedullary fixation system (such as the Gamma nail [Stryker Corp., Kalamazoo, MI, USA]).

Many articles have reported that Garden type III and IV femoral neck fractures and Pauwels type II and III femoral neck fractures are particularly suitable for fixation with a nail-plate system because of their poor biomechanical stability and high failure rate of internal fixation.^{9,35,36} The proximal femoral hollow locking plate is a mechanical fixation system that combines three hollow screws with a fixed angle and one cortical locking screw perpendicular to the femoral shaft with the plate through locking fixation technology. This system has many advantages. For example, the hollow screws enhance the support of the fractured end, and the stability is obviously improved. This system can reportedly reduce the incidence of complications such as loosening of the internal fixation, failure of fixation, and shortening of the femoral neck.^{11,37} This design also helps to disperse the stress through the plate, avoiding loosening of the single nail caused by excessive stress. The angle between the direction of the three hollow screws and the femoral shaft is 130°, which is close to the normal angle of the femoral neck shaft and meets the requirements of biomechanics. According to the anatomical characteristics of the femoral neck, the three holes at the proximal end of the locking plate were designed to be in an inverted triangle distribution, ensuring the accuracy of hollow nail placement. Another advantage of screw fixation is that although the three locking hollow screw nuts were designed for locking, the range of the thread diameter from small to large can also achieve a certain degree of compression of the fracture end. Optimizing the stability of internal fixation for femoral neck fractures, such as increasing the length of the fixator, using implants at new fixation angles, and similar measures, has been shown to be crucial to the outcome.³⁸ All fractures in the present study were fixed with a proximal femoral hollow locking plate. No complications

such as shortening of the femoral neck, internal fixation loosening, or refracture occurred after the operation. However, three patients required a reoperation (one with nonunion and two with necrosis of the femoral head). The fracture union rate of this treatment was high at 93.3%. Most patients were able to perform early non-weight training exercise and partial weight training exercise with no complications related to loosening of the internal fixation, rupture, or deep venous thrombosis. The final follow-up Harris hip score was 92.1 ± 4.5 (range, 76–98); 32 patients had an excellent score and 10 had a good score. The rate of excellent and good scores was high at 93.3%.

This study also has some limitations. First, it was a long-term retrospective study; recall bias was inevitable and might have impacted the results. Second, to obtain a sufficient sample size, the follow-up time ranged from 14 to 31 months (mean, 25 months). Because some patients were only followed up for 14 months, we could not exclude the possibility of ischemic necrosis of the femoral head in the later stage. More accurate elucidation of the clinical outcomes requires a comprehensive study involving a large sample size, multiple centers, and long-term follow-up.

Conclusion

Minimally invasive open reduction and internal fixation with a proximal femoral hollow locking plate for the treatment of Pauwels type III femoral neck fractures has great advantages in terms of high reduction quality, firm fixation, prevention of neck shortening, and prevention of coxa vara deformity. All of these features can significantly improve the fracture healing rate and reduce the occurrence of fracture complications.

Declaration of conflicting interest

The authors declared no potential conflicts of interest with respect to the research, authorship, and/or publication of this article.

Funding

This research received no specific grant from any funding agency in the public, commercial, or not-for-profit sectors.

ORCID iD

Huilin Yang  <https://orcid.org/0000-0001-9679-2759>

References

1. Gjertsen JE, Engesaeter LB, Furnes O, et al. The Norwegian Hip Fracture Register: experiences after the first 2 years and 15,576 reported operations. *Acta Orthop* 2008; 79: 583–593.
2. Davidovitch RI, Jordan CJ, Egol KA, et al. Challenges in the treatment of femoral neck fractures in the nonelderly adult. *J Trauma* 2010; 68: 236–242.
3. Gurusamy K, Parker MJ and Rowlands TK. The complications of displaced intracapsular fractures of the hip: the effect of screw positioning and angulation on fracture healing. *J Bone Joint Surg Br* 2005; 87: 632–634.
4. Dickson JA. The unsolved fracture; a protest against defeatism. *J Bone Joint Surg Am* 1953; 35-A: 805–822.
5. Panteli M, Rodham P and Giannoudis PV. Biomechanical rationale for implant choices in femoral neck fracture fixation in the non-elderly. *Injury* 2015; 46: 445–452.
6. Florschutz AV, Langford JR, Haidukewych GJ, et al. Femoral neck fractures: current management. *J Orthop Trauma* 2015; 29: 121–129.
7. Ly TV and Swiontkowski MF. Management of femoral neck fractures in young adults. *Indian J Orthop* 2008; 42: 3–12.
8. Liu C, Liu MT, Li P, et al. Efficacy evaluation for the treatment of subcapital femoral neck fracture in young adults by capsulotomy reduction and closed reduction. *Chin Med J (Engl)* 2015; 128: 483–488.

9. Aminian A, Gao F, Fedoriw WW, et al. Vertically oriented femoral neck fractures: mechanical analysis of four fixation techniques. *J Orthop Trauma* 2007; 21: 544–548.
10. Nowotarski PJ, Ervin B, Weatherby B, et al. Biomechanical analysis of a novel femoral neck locking plate for treatment of vertical shear Pauwel's type C femoral neck fractures. *Injury* 2012; 43: 802–806.
11. Wang Z, Yin Y, Li Q, et al. Comparison of early complications between the use of a cannulated screw locking plate and multiple cancellous screws in the treatment of displaced intracapsular hip fractures in young adults: a randomized controlled clinical trial. *J Orthop Surg Res* 2018; 13: 201.
12. Bartonicek J. Pauwels' classification of femoral neck fractures: correct interpretation of the original. *J Orthop Trauma* 2001; 15: 358–360.
13. de Jong L, Klem T, Kuijper TM, et al. The minimally invasive anterolateral approach versus the traditional anterolateral approach (Watson-Jones) for hip hemiarthroplasty after a femoral neck fracture: an analysis of clinical outcomes. *Int Orthop* 2018; 42: 1943–1948.
14. Garden RS. Malreduction and avascular necrosis in subcapital fractures of the femur. *J Bone Joint Surg Br* 1971; 53: 183–197.
15. Baumgaertner MR, Curtin SL, Lindskog DM, et al. The value of the tip-apex distance in predicting failure of fixation of peritrochanteric fractures of the hip. *J Bone Joint Surg Am* 1995; 77: 1058–1064.
16. Harris WH. Traumatic arthritis of the hip after dislocation and acetabular fractures: treatment by mold arthroplasty. An end-result study using a new method of result evaluation. *J Bone Joint Surg Am* 1969; 51: 737–755.
17. Slobogean GP, Sprague SA, Scott T, et al. Complications following young femoral neck fractures. *Injury* 2015; 46: 484–491.
18. Luttrell K, Beltran M and Collinge CA. Preoperative decision making in the treatment of high-angle “vertical” femoral neck fractures in young adult patients. An expert opinion survey of the Orthopaedic Trauma Association's (OTA) membership. *J Orthop Trauma* 2014; 28: e221–e225.
19. Zhang YL, Chen S, Ai ZS, et al. Osteonecrosis of the femoral head, non-union and potential risk factors in Pauwels grade-3 femoral neck fractures: a retrospective cohort study. *Medicine* 2016; 95: e3706.
20. Haidukewych GJ, Rothwell WS, Jacofsky DJ, et al. Operative treatment of femoral neck fractures in patients between the ages of fifteen and fifty years. *J Bone Joint Surg Am* 2004; 86-A: 1711–1716.
21. Alberts KA and Jervaeus J. Factors predisposing to healing complications after internal fixation of femoral neck fracture. A stepwise logistic regression analysis. *Clin Orthop Relat Res* 1990; (257): 129–133.
22. Ghayoumi P, Kandemir U and Morshed S. Evidence based update: open versus closed reduction. *Injury* 2015; 46: 467–473.
23. Pauyo T, Drager J, Albers A, et al. Management of femoral neck fractures in the young patient: a critical analysis review. *World J Orthop* 2014; 5: 204–217.
24. Su Y, Chen W, Zhang Q, et al. An irreducible variant of femoral neck fracture: a minimally traumatic reduction technique. *Injury* 2011; 42: 140–145.
25. Ly TV and Swiontkowski MF. Treatment of femoral neck fractures in young adults. *Instr Course Lect* 2009; 58: 69–81.
26. Upadhyay A, Jain P, Mishra P, et al. Delayed internal fixation of fractures of the neck of the femur in young adults. A prospective, randomised study comparing closed and open reduction. *J Bone Joint Surg Br* 2004; 86: 1035–1040.
27. Wang T, Sun JY, Zha GC, et al. Analysis of risk factors for femoral head necrosis after internal fixation in femoral neck fractures. *Orthopedics* 2014; 37: e1117–e1123.
28. Yang JJ, Lin LC, Chao KH, et al. Risk factors for nonunion in patients with intracapsular femoral neck fractures treated with three cannulated screws placed in either a triangle or an inverted triangle configuration. *J Bone Joint Surg Am* 2013; 95: 61–69.
29. Basso T. Internal fixation of fragility fractures of the femoral neck. *Acta Orthop Suppl* 2015; 86: 1–36.
30. Zhang GZ, Wang MY and Jiang XY. [Three nonparallel screws for the treatment of

- femoral neck fractures]. *Zhongguo Gu Shang* 2012; 25: 1002–1004.
31. Parker MJ and Stedtfeld HW. Internal fixation of intracapsular hip fractures with a dynamic locking plate: initial experience and results for 83 patients treated with a new implant. *Injury* 2010; 41: 348–351.
 32. Slobogean GP, Stockton DJ, Zeng BF, et al. Femoral neck shortening in adult patients under the age of 55 years is associated with worse functional outcomes: analysis of the prospective multi-center study of hip fracture outcomes in China (SHOC). *Injury* 2017; 48: 1837–1842.
 33. Zielinski SM, Keijsers NL, Praet SF, et al. Femoral neck shortening after internal fixation of a femoral neck fracture. *Orthopedics* 2013; 36: e849–e858.
 34. Nair N, Patro DK and Babu TA. Role of muscle pedicle bone graft as an adjunct to open reduction and internal fixation in the management of neglected and ununited femoral neck fracture in young adults: a prospective study of 17 cases. *Eur J Orthop Surg Traumatol* 2014; 24: 1185–1191.
 35. Zhu Q, Shi B, Xu B, et al. Obtuse triangle screw configuration for optimal internal fixation of femoral neck fracture: an anatomical analysis. *Hip Int* 2019; 29: 72–76.
 36. Xue W, Guan XL, Wang ZP, et al. [Treatment of displaced femoral neck fracture in young adults with close reduction and femoral neck locking plate fixation]. *Zhongguo Gu Shang* 2016; 29: 645–647.
 37. Zlowodzki M, Jonsson A, Paulke R, et al. Shortening after femoral neck fracture fixation: is there a solution? *Clin Orthop Relat Res* 2007; 461: 213–218.
 38. Ye Y, Hao J, Mauffrey C, et al. Optimizing stability in femoral neck fracture fixation. *Orthopedics* 2015; 38: 625–630.