

Autosomal recessive bestrophinopathy with macular hole

Raj Shri Hirawat, C K Nagesha¹, Megha M Divakar¹

Key words: Autosomal recessive inheritance, best's disease, macular hole

A 22-year-old male was evaluated for both eye poor vision. Right eye BCVA was 2/60 and left eye was 6/60 with + 3.25DS

Access this article online	
Quick Response Code:	Website: www.ijo.in
	DOI: 10.4103/ijo.IJO_1346_19

Consultant, Gomabai Netralaya, Neemach, Madhya Pradesh,
¹Department of Vitreo-Retina, B. W. Lions Eye Hospital, Bengaluru, Karnataka, India

Correspondence to: Dr. C K Nagesha, Consultant, Department of Vitreo-Retina, B. W. Lions Eye Hospital, Bengaluru - 560 002, Karnataka, India. E-mail: drnageshck_2006@yahoo.com

Received: 22-Jul-2019

Revision: 01-Nov-2019

Accepted: 14-Dec-2019

Published: 25-May-2020

distance correction. Fundus examination of both eyes showed bilateral subretinal yellow deposits extending up to arcades [Fig. 1a and b] with macular hole in right eye and subretinal fibrosis in left eye [Fig. 1c and d]. Electroretinogram (ERG) was near normal in both eyes [Fig. 2] and electrooculogram (EOG) showed light-peak absence [Fig. 3]. Parents of proband had normal fundi and EOG. Diagnosis of autosomal recessive bestrophinopathy complicated by macular hole in one eye was made. Further confirmation was limited by the lack of genetic testing in the present case.

Autosomal recessive bestrophinopathy is a recently described disorder caused by either compound heterozygous or homozygous null mutations in the BEST1 gene compared to missense mutation in more common dominant variant. Eyes with autosomal recessive best's variant are usually hyperopic with co-existing narrow angles.^[1] They tend to have poor vision owing to the development of subretinal fibrosis and risk of angle-closure glaucoma.^[2] Formation of a macular hole is rare and caused further deterioration of vision in the present

This is an open access journal, and articles are distributed under the terms of the Creative Commons Attribution-NonCommercial-ShareAlike 4.0 License, which allows others to remix, tweak, and build upon the work non-commercially, as long as appropriate credit is given and the new creations are licensed under the identical terms.

For reprints contact: reprints@medknow.com

Cite this article as: Hirawat RS, Nagesha CK, Divakar MM. Autosomal recessive bestrophinopathy with macular hole. Indian J Ophthalmol 2020;68:1173-5.

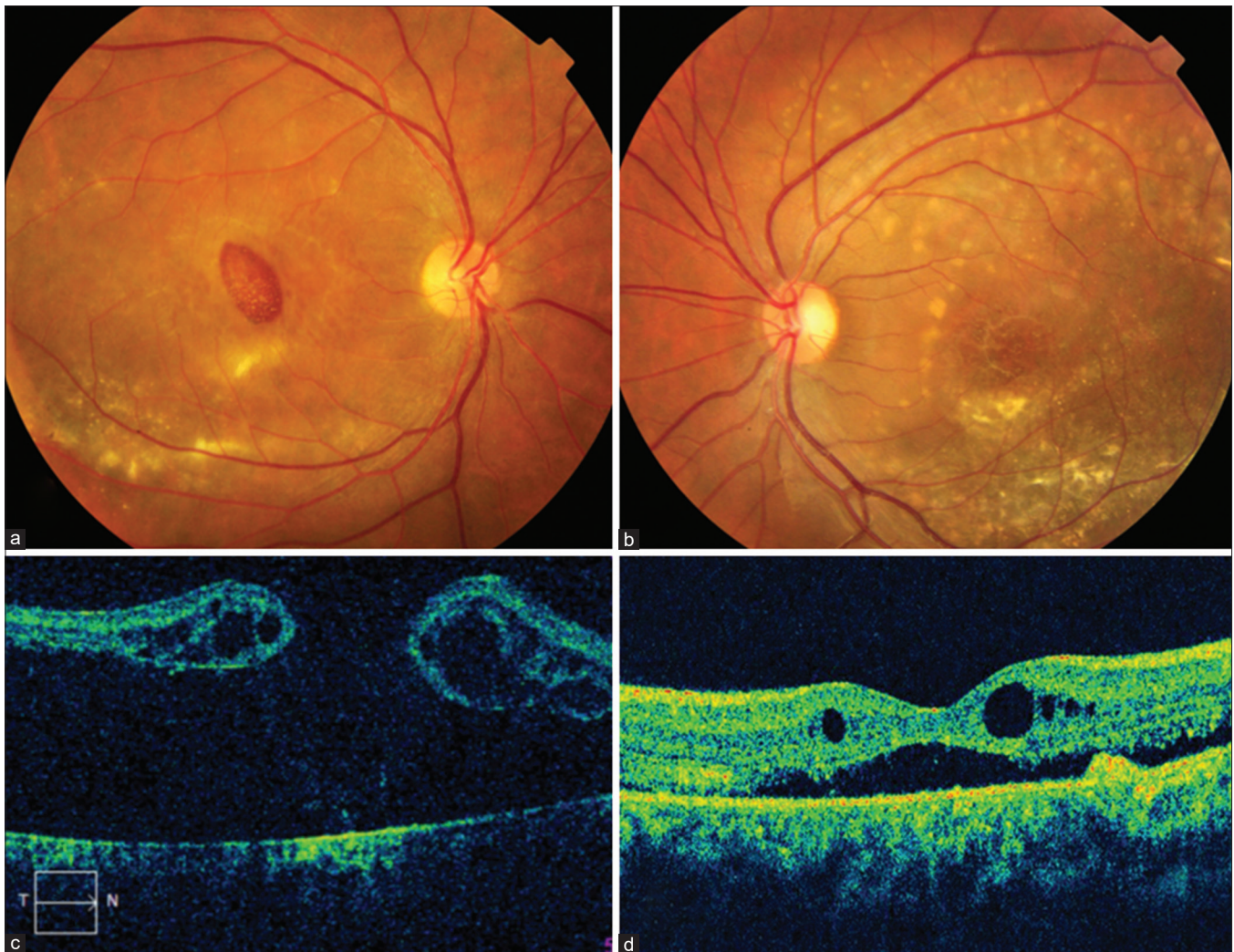


Figure 1: Composite figure showing bilateral subretinal deposits (a and b); full-thickness macular hole in right eye (c) and intraretinal and subretinal fluid collection in left eye (d)

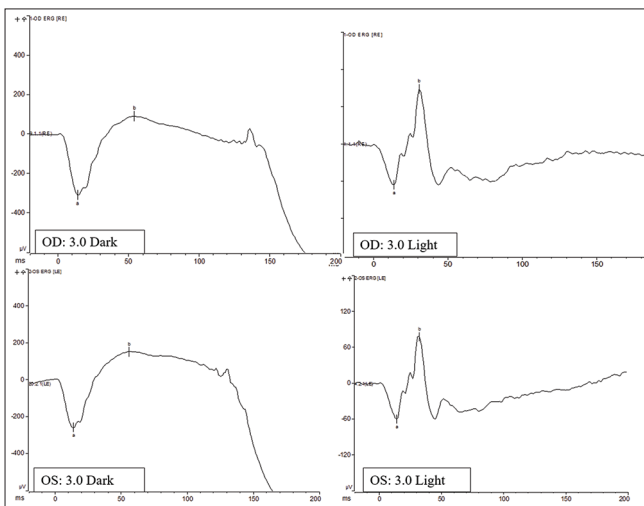


Figure 2: Full flash electroretinogram showing of right and left eye waveforms under light and dark adaptations

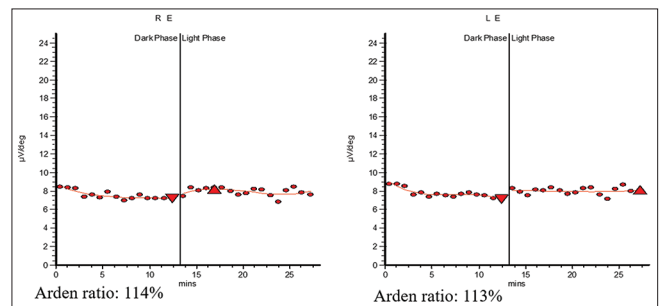


Figure 3: Electrooculogram of right and left eye with Arden ratio

case. ERG can be normal or subnormal due to widespread and progressive photoreceptor dysfunction in autosomal recessive variant and EOG is markedly affected in this variant.^[3]

This entity should be differentiated from central serous chorioretinopathy which reveals focal leaks on fluorescein angiography, Juvenile X-linked retinoschisis where ERG

shows negative waveforms and normal EOG and multifocal best vitelliform macular dystrophy in which genetic analysis and screening of parents establishes a correct diagnosis. Early recognition and monitoring are essential to prognosticate and foresee complications associated with this variant.

Declaration of patient consent

The authors certify that they have obtained all appropriate patient consent forms. In the form the patient(s) has/have given his/her/their consent for his/her/their images and other clinical information to be reported in the journal. The patients understand that their names and initials will not be published and due efforts will be made to conceal their identity, but anonymity cannot be guaranteed.

Financial support and sponsorship

Nil.

Conflicts of interest

There are no conflicts of interest.

References

1. Borman AD, Davidson AE, O'Sullivan J, Thompson DA, Robson AG, De Baere E, *et al.* Childhood-onset autosomal recessive bestrophinopathy. *Arch Ophthalmol* 2011;129:1088-93.
2. Boon CJ, van den Born LI, Visser L, Keunen JE, Bergen AA, Booij JC, *et al.* Autosomal recessive bestrophinopathy: Differential diagnosis and treatment options. *Ophthalmology* 2013;120:809-20.
3. Nakanishi A, Ueno S, Hayashi T, Katagiri S, Kominami T, Ito Y, *et al.* Clinical and genetic findings of autosomal recessive bestrophinopathy in Japanese cohort. *Am J Ophthalmol* 2016;168:86-94.