

Clinical Article

Surgical Outcomes of Post-Fusion Lumbar Flatback Deformity with Sagittal Imbalance

Jin Seong Kim, M.D., Sung Min Kim, M.D., Ph.D.

Department of Neurosurgery, Kyung Hee University Hospital at Gangdong, Seoul, Korea

Objectives : To review surgical results of post-fusion lumbar flatback treated with pedicle subtraction osteotomy (PSO) or Smith-Petersen osteotomies (SPOs).

Methods : Twenty-eight patients underwent osteotomies. Radiological outcomes by sagittal vertical axis (SVA), and pelvic tilt (PT), T1 pelvic angle (T1PA), and pelvic incidence (PI)-lumbar lordosis (LL) at preoperative, postoperative 1 month, and final were evaluated. Oswestry Disability Index (ODI), visual analog scale (VAS) score of back pain/leg pain, and Scoliosis Research Society-22 score (SRS-22r) were analyzed and compared. Patients were divided into 2 groups (SVA \leq 5 cm : normal, SVA $>$ 5 cm : positive) at final and compared outcomes.

Results : Nineteen patients (68%) had PSO and the other 9 patients had SPOs with anterior lumbar interbody fusions (ALIFs) (Mean age : 65 years, follow-up : 31 months). The PT, PI-LL, SVA, T1PA were significantly improved at 1 month and at final ($p < 0.01$). VAS score, ODI, and SRS-22r were also significantly improved at the final ($p < 0.01$). 23 patients were restored with normal SVA and the rest 5 patients demonstrated to positive SVA. SVA and T1PA at 1 month and SVA, PI-LL, and T1PA at final were significantly different ($p < 0.05$) while the ODI, VAS, and SRS-22r did not differ significantly between the groups ($p > 0.05$). Common reoperations were early 4 proximal junctional failures (14%) and late four rod fractures.

Conclusion : Our results demonstrate that PSO and SPOs with ALIFs at the lower lumbar are significantly improves sagittal balance. For maintenance of normal SVA, PI-LL might be made negative value and T1PA might be less than 11° even though positive SVA group was also significantly improved clinical outcomes.

Key Words : Post-fusion flatback deformity · Pedicle subtraction osteotomy · Smith-Petersen osteotomy · Anterior lumbar interbody fusion.

INTRODUCTION

Post-fusion lumbar flatback deformity with global sagittal imbalance causes gait disturbances, chronic low back and referred leg pain, and reduced quality of life. The incidence of patients requiring lumbar corrective osteotomy for post-fusion lumbar flatback deformity with sagittal imbalance is increasing as the numbers of spine fusion surgeries and overall average life expectancy increases^{1,2}. In patients with sagittal imbalance, adequate correction to restore an ideal lumbar lordosis relative to pelvic incidence (PI) in the sagittal plane is very important during corrective osteotomy³. According to Schwab et al.¹⁵, corrective osteotomy for adult spinal deformity (ASD) leads to good sagittal spinal balance if the range of correction is within lumbar lordosis (LL)=PI \pm 9°, pelvic tilt (PT)<20°, and sagittal vertical axis (SVA)<5 cm. However, patients with post-fusion lumbar flatback are generally osteoporotic, elderly females who

have poor paraspinal muscle condition due to fatty degenerative changes, atrophy of the back muscles, and thinning of the paraspinal and psoas muscles. Therefore, restoration of lumbar lordosis below the PI value might result in another (or secondary) postoperative or delayed sagittal imbalance due to the lack of the compensatory roles from these paraspinal muscles. Two previous studies reported theoretical values for PT and LL related to PI. These studies suggested that ideal lumbar lordosis consists of 67% LL at L4-S1, 85% LL at L3-S1, and 97% LL at L2-S1. The degree of PI was categorized into 6 groups (I to VI), and theoretical LL and PT values were recommended for each group^{1,4}. In this study, radiographical outcomes of post-fusion lumbar flatback patients treated with pedicle subtraction osteotomy (PSO) or Smith-Petersen osteotomies (SPOs) with ALIFs were analyzed and compared at preoperative, postoperative 1 month, and at the final follow up and achieved mean PSO angles were evaluated. Clinical outcomes by Oswestry Disability

• Received : September 30, 2016 • Revised : October 11, 2016 • Accepted : October 11, 2016

• Address for reprints : Sung Min Kim, M.D., Ph.D.

Department of Neurosurgery, Kyung Hee University Hospital at Gangdong, 892 Dongnam-ro, Gangdong-gu, Seoul 05278, Korea
Tel : +82-2-440-6286, Fax : +82-2-440-8404, E-mail : spinekim@khu.ac.kr

• This is an Open Access article distributed under the terms of the Creative Commons Attribution Non-Commercial License (<http://creativecommons.org/licenses/by-nc/3.0>) which permits unrestricted non-commercial use, distribution, and reproduction in any medium, provided the original work is properly cited.

Index (ODI), visual analog scale (VAS) score of back pain/leg pain, and Scoliosis Research Society-22 score (CRS-22r) were analyzed and compared. At the final follow-up, all patients were divided into 2 groups (SVA ≤ 5 cm : normal SVA, SVA > 5 cm : positive SVA) and compared with both groups by according to radiological and clinical outcome parameters.

MATERIALS AND METHODS

Patient population

This was a retrospective study of patients with post-fusion lumbar deformity with sagittal imbalance. Twenty-eight patients (24 women and 4 men) who underwent corrective osteotomies for post-fusion lumbar flatback deformity between 2008 and 2014 at our institution were enrolled. The mean age at the time of surgery was 65 ± 8 years (range, 47–75 years). The mean follow-up period was 30 ± 18 months (range, 12–72 months). The inclusion criterion was corrective fusion surgery that involved more than 4 intervertebral levels. To obtain adequate lumbar lordosis in the patients with post-fusion lumbar flatback deformity, PSO or multilevel SPOs with lower lumbar ALIFs were performed. All surgical treatments were performed with the staged posterior-anteriorposterior (P-AP), anteriorposterior (AP), or posterior (P) only approach. Upper instrumented vertebra (UIV) were at T7 (1 case), T8 (4), T9 (4), T10 (6), T11 (7), T12 (4), and L1 (2). Lower instrumented vertebra (LIV) were at L5 (1), S1 (10), and the iliac (17). PSO was performed in 19 of the 28 cases (Fig. 1) at L2 (4), L3 (8), and L4 (7). The achieved mean angle of PSO was $30.1 \pm 4.8^\circ$ (21° to 40°) (Fig. 1). The other 9 cases underwent posterior lower lumbar polysegmental SPOs followed by anterior lower lumbar ALIFs (Fig. 2) (Table 1).

Data collection and classification

The data collected consisted of health-related quality of life (HRQOL) questionnaires and demographic, radiographic, and clinical information. Sagittal spinal and pelvic parameters on whole spine standing X-rays were measured at baseline, post-

operative one month, and final follow-up. The following parameters were assessed : pelvic measurements, including PI, PT, and sacral slope; regional measurements, including thoracic kyphosis (TK : T5 to T12), thoracolumbar Cobb angle (TL : T10 to L2), and lumbar lordotic angle (LL : L1 to S1); and global measures, including the SVA, T1 pelvic angle (T1PA), and PI-LL. The PI, TK, TL, LL and SVA, PI-LL, T1PA at preoperative, postoperative 1 month, and at the final follow up were assessed. achieved mean PSO angles were also evaluated.

At the final follow-up, all patients were divided into 2 groups (SVA ≤ 5 cm : normal SVA, SVA > 5 cm : positive SVA) and compared with both global sagittal and clinical outcome parameters. Clinical outcomes were evaluated with the ODI and a VAS for back and leg pain, and the SRS-22r questionnaire. Complications were categorized into early perioperative or late complication, and revision surgeries were reviewed.

Statistical analysis

Means and standard deviations were calculated and compared for continuous variables among preoperative, postoperative one month, and at the final follow-up periods. Comparison of parameters between the normal and positive SVA groups was performed using Mann-Whitney test. Non parametric tests including Wilcoxon signed rank test and Frideman test were used for comparing radiological parameter over time and health-related quality of life between the preoperative and final. *p*-values less than 0.05 were considered statistically significant. All statistical analyses were performed using SPSS 18.0 (IBM Co, NY, USA).

RESULTS

As for the overall radiological outcome for total 28 patients, the mean PI was $53 \pm 9^\circ$. The TK, LL, PT, PI-LL, SVA, and T1PA were significantly improved both immediate postoperatively and on the final follow-up ($p < 0.05$). TK improved from $10 \pm 17^\circ$ kyphosis preoperatively to $31 \pm 9^\circ$ at postoperative one month and was well maintained through the final follow-up ($37 \pm 8^\circ$).

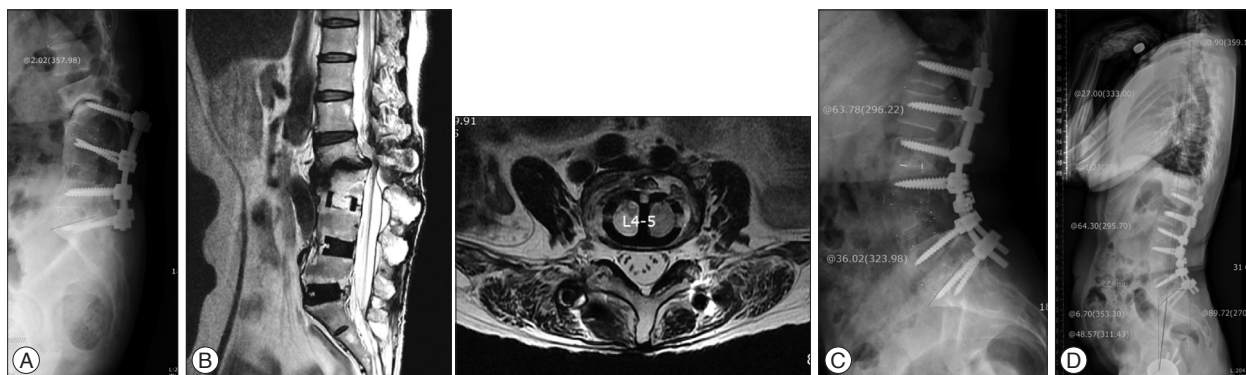


Fig. 1. L4 pedicle subtraction osteotomy (PSO) in a 56-year-old woman with post-fusion lumbar flatback deformity. A : Preoperative lumbar lateral X-ray. B : lumbar MRI showing hypolordotic fusion from L2 to S1 and severe adjacent segment degeneration with sclerosis at L2–3 level. There was also paraspinal and psoas muscle atrophy and fatty infiltration around L4–5 level. The patient underwent L4 PSO with L2–3 TLIF. C and D : The patient was improved and well maintained spinal and spinopelvic balance at 31 months postoperatively : PI-LL, -15° ; SVA, -27 mm; PT, 7° ; achieved angle by L4 PSO of 36° . SVA : sagittal vertical axis, PT : pelvic tilt, PI : pelvic incidence, LL : lumbar lordosis, TLIF : transforaminal lumbar interbody fusion.

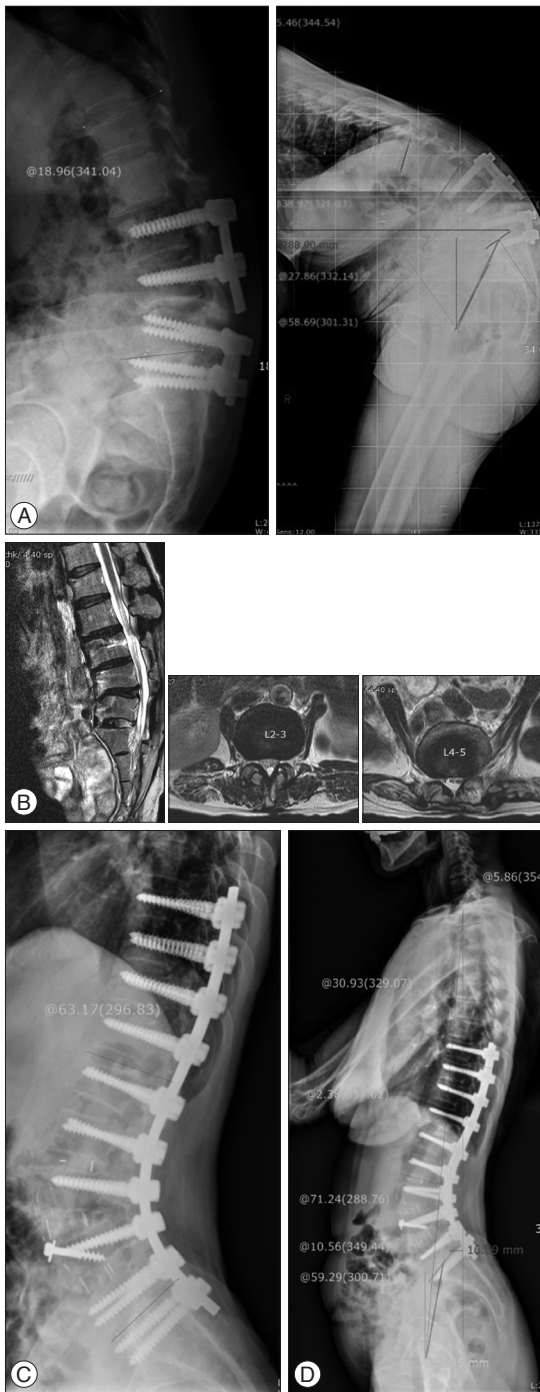


Fig. 2. Lower lumbar SPOs with ALIFs were performed in a 54-year-old woman with post-fusion lumbar flatback deformity. A : Preoperative lumbar and whole spine lateral X-ray. B : Lumbar MRI. Very positive sagittal imbalance with nonunion and rod fracture at the lower lumbar was detected. MRI showed multilevel lower lumbar disc degeneration with severe paraspinous and psoas muscle atrophy. C and D : The patient underwent lower lumbar SPOs with ALIFs at L3–4–5 and PLIF at L2–3 by the P-AP approaches. The patient was very satisfied with well maintained global spinal balance at 32 months postoperatively : PI-LL, -12° ; SVA, -17 mm; PT, 11° at the postoperative 32-month lumbar, whole spine X-ray. SPO : Smith-Petersen osteotomy, ALIF : anterior lumbar interbody fusion, P-AP : posterior-anteriorposterior, SVA : sagittal vertical axis, PT : pelvic tilt, PI : pelvic incidence, LL : lumbar lordosis, PLIF : posterior lumbar interbody fusion.

The LL improved from $2\pm 23^\circ$ kyphosis preoperatively to $-60\pm 8^\circ$ lordosis at postoperative one month and maintained $-53\pm 23^\circ$ at the final. As for the changes in the PI-LL mismatch, SVA, and PT over the due clinical courses (preoperative, postoperative one month, and final follow-up), the PI-LL improved from $55\pm 24^\circ$ preoperatively to $-6\pm 6^\circ$ at postoperative one month and this improvement was well maintained through the final follow up ($-4\pm 7^\circ$). The SVA was 194 ± 81 mm preoperatively, 7 ± 27 mm at postoperative 1 month, and 19 ± 35 mm at the final follow up. The T1PA improved from $43\pm 14^\circ$ preoperatively to $11\pm 7^\circ$ at postoperative one month and this improvement was maintained into $13\pm 7^\circ$ at final follow up. Similarly, the PT was $30\pm 11^\circ$ preoperatively, $14\pm 7^\circ$ at postoperative one month, and $17\pm 7^\circ$ at the final follow up (Table 2).

As for the clinical outcomes for this series between preoperative and final follow-up, all investigated parameters including ODI, VAS score, and SRS-22r score were significantly improved ($p<0.05$). ODI improved from 66 ± 10 preoperatively to 28 ± 14 at final. VAS of the back pain/leg pain were improved from $8.0\pm 1.0/7.5\pm 1.2$ preoperatively to $2.5\pm 1.4/2.3\pm 1.5$ at final. Mean SRS-22r score was improved from 2.1 ± 0.4 preoperatively to 3.6 ± 0.4 at final (Function; from 2.1 ± 0.5 to 3.3 ± 0.5 : Pain; from 2.1 ± 0.5 to 3.9 ± 0.5 : Self-image; from 2.0 ± 0.6 to 3.5 ± 0.5 : Mental health; from 2.3 ± 0.6 to 3.7 ± 0.5) (Table 3).

The SVA values at the final follow up were categorized as normal SVA [≤ 50 mm, $n=23$ (82%)] and positive SVA [>50 mm, $n=5$ (18%)]. The mean SVA was 7 ± 26 mm for the normal SVA group and 73 ± 11 mm for the positive SVA group, a statistically significant difference between groups ($p=0.001$). The PI-LL was $-5\pm 6^\circ$ for the normal SVA group and $3\pm 7^\circ$ for the positive SVA group ($p<0.05$). The T1PA was $11\pm 6^\circ$ for normal SVA group and $22\pm 8^\circ$ for the positive SVA group ($p<0.05$). However, the PT did not differ significantly between groups (Table 4). On the contrary, there were no significant differences in clinical outcome measures such as ODI, VAS score of the back pain/leg pain, and

Table 1. Characteristics of patients who underwent corrective osteotomy in post-fusion flatback deformity

Patient demography	Findings
Enrollment period	From 2008 to 2014
No. of patients	28 (F : 24, M : 4)
Mean age (years)	65 ± 8 (47–75)
Mean F/U (months)	30 ± 18 (12–72)
Common upper vertebral body level (no.)	T9 (4) : T10 (6) : T11 (7) : T12 (4)
Lower vertebral body level (no.)	L5 (1) : S1 (10) : Iliac (17)
Mobilization procedures	P-AP, AP, or P only approach
Pedicle subtraction osteotomy	19 cases (68%) : L2 (4 cases), L3 (8 cases), L4 (7 cases) • Mean angle of PSO : 30° (21° to 40°)
Lumbar SPOs with ALIFs	9 cases

SPO : Smith-Petersen osteotomy, P-AP : posterior-anteriorposterior, AP : anterior-posterior, P : posterior, PSO : pedicle subtraction osteotomy

Table 2. Radiological outcomes by LL, PT, PI-LL, SVA, and T1PA in post-fusion flatback deformity

Variables	Pre op	Post op 1M	p-value	Final	p-value
TK (°)	10±17	31±9	p<0.001	37±8	p<0.001
TL (°)	11±18	9±7	0.466	10±9	0.839
LL (°)	2±23	-60±8	p<0.001	-53±23	p<0.001
PT (°)	30±11	14±7	p<0.001	17±7	p<0.001
PI (°)	53±9	54±9	0.178	54±8	0.972
SVA (mm)	194±81	7±27	p<0.001	19±35	p<0.001
PI-LL (°)	55±24	-6±6	p<0.001	-4±7	p<0.001
T1PA (°)	43±14	11±7	p<0.001	13±7	p<0.001

PI : pelvic incidence, LL : lumbar lordosis, PT : pelvic tilt, SVA : sagittal vertical axis, T1PA : T1 pelvic angle, TK : thoracic kyphotic angle, TL : thoracolumbar Cobb angle

Table 3. Clinical outcomes by ODI, VAS score for back pain/leg pain, and SRS-22r and its domains in post-fusion flatback deformity

Variables	Pre OP	Final	p-value
ODI	66±10	28±14	p<0.001
VAS (back)	8.0±1.0	2.5±1.4	p<0.001
VAS (leg)	7.5±1.2	2.3±1.5	p<0.001
SRS-22r	2.1±0.4	3.6±0.4	p<0.001
Function	2.1±0.5	3.3±0.5	p<0.001
Pain	2.1±0.5	3.9±0.5	p<0.001
Self-image	2.0±0.6	3.5±0.5	p<0.001
Mental health	2.3±0.6	3.7±0.5	p<0.001
Satisfaction with management		3.8±0.6	

ODI : Oswestry Disability Index, VAS : visual analog scale, SRS-22r : Scoliosis Research Society-22 Patient

Table 4. Comparison of radiological parameters between normal SVA (≤5 cm) and positive SVA (>5 cm) groups

Variables	Pre op			Post 1m			Final		
	≤5 cm	>5 cm	p-value	≤5 cm	>5 cm	p-value	≤5 cm	>5 cm	p-value
TK (°)	10±18	10±11	0.881	30±8	34±11	0.416	36±8	41±7	0.149
TL (°)	12±19	8±14	0.787	9±8	10±4	0.696	10±10	10±6	0.857
LL (°)	2±24	5±17	0.471	-60±8	-58±9	0.764	-54±25	-52±6	0.133
PT (°)	29±10	34±13	0.241	14±7	17±7	0.307	16±7	22±9	0.229
PI (°)	53±9	55±12	0.810	53±8	55±13	0.928	53±8	55±11	0.880
SVA (mm)	189±86	218±52	0.509	0±22	39±27	0.009	7±26	73±11	0.001
PI-LL (°)	54±26	60±17	0.368	-7±6	-3±6	0.195	-5±6	3±7	0.030
T1PA (°)	43±14	44±13	0.568	10±7	17±6	0.035	11±6	22±8	0.006

TK : thoracic kyphotic angle, TL : thoracolumbar Cobb angle, PI : pelvic incidence, LL : lumbar lordosis, PT : pelvic tilt, SVA : sagittal vertical axis, T1PA : T1 pelvic angle

SRS-22r score including 5 main domains between the two groups at the final follow-up. All clinical outcome parameters were significantly improved for both groups on the final follow up from baseline (Table 5).

Perioperative complication was 29% (8 cases) and early reoperation were 18% (5 cases). Among them, 4 acute proximal junctional failures occurred ; 2 UIV fractures, one UIV+1 fracture, and one proximal screw loosening. The other perioperative complications included 4 cases (14%). 3 cases of deep vein thrombosis and one focal neurological deficit in spite of 3 times of neural decompression and exploration surgery of a left L3 nerve root compression after L3 PSO occurred. Late complications were 46% (13 cases) and late revision surgery were 29% (8 cases). 4 rod fracture were reoperated with rod change with/

without additional 3 or 4 rods techniques. 3 fusion extension due to delayed proximal junctional kyphosis and one nonunion at L5S1 level were reoperated. Among 3 cases of proximal junctional kyphosis, one patient with delayed UIV+1 chronic compression fracture who had severe neurological deficit was addressed with neural decompression and fusion extension up to UIV+4. In addition, there were 5 cases of long-term complications; one distal screw loosening, 3 proximal junctional kyphosis, and one asymptomatic rod fracture.

DISCUSSION

It is well known that post-fusion lumbar flatback deformity is caused by hypolordotic lumbar fusion, adjacent segment dis-

Table 5. Comparison of clinical outcomes between normal SVA (≤ 5 cm) and positive SVA (> 5 cm) groups

Variables	Pre op			Final		
	≤ 5 cm	> 5 cm	<i>p</i> -value	≤ 5 cm	> 5 cm	<i>p</i> -value
ODI	67 \pm 10	62 \pm 11	0.672	27 \pm 15	31 \pm 7	0.383
VAS (back)	8.0 \pm 1.0	8.4 \pm 0.9	0.330	2.4 \pm 1.4	3.2 \pm 1.3	0.189
VAS (leg)	7.5 \pm 1.1	7.4 \pm 1.8	0.926	2.1 \pm 1.5	2.8 \pm 1.3	0.414
SRS-22r	2.1 \pm 0.4	2.1 \pm 0.6	0.741	3.7 \pm 0.4	3.4 \pm 0.4	0.266
Function	2.2 \pm 0.5	2.0 \pm 0.7	0.483	3.4 \pm 0.5	3.2 \pm 0.6	0.396
Pain	2.2 \pm 0.5	1.9 \pm 0.7	0.216	3.9 \pm 0.5	3.7 \pm 0.5	0.409
Self-image	2.0 \pm 0.6	2.0 \pm 0.5	0.628	3.6 \pm 0.5	3.3 \pm 0.5	0.192
Mental health	2.3 \pm 0.6	2.3 \pm 0.5	0.928	3.7 \pm 0.5	3.6 \pm 0.6	0.784
Satisfaction with management				3.9 \pm 0.5	3.4 \pm 0.4	0.088

SVA : sagittal vertical axis, ODI : Oswestry Disability Index, VAS : visual analog scale, SRS-22r : Scoliosis Research Society-22 Patient

ease after lumbar fusion, non-union with or without insufficient anterior column support, and post-laminectomy fusion. In addition to these conditions, atrophy or fatty degeneration in the paraspinal muscles might cause global sagittal imbalance in the lumbar spine that leads to increased fatigue and pain. To diagnose post-fusion lumbar flatback deformity, clinicians should review the patient's history, AP and lateral whole spine standing X-rays, and CT and MRI of the spine. The patient's history may include difficulty in standing upright and complaints of back or leg pain, difficulty in standing during large load bearing, difficulty bending, and frequently relying on the knee as buttress during gait or stair climbing. In whole spine standing X-rays, more than 5 cm of SVA, loss of lumbar lordosis, PI-LL mismatch of more than 10 degrees, a large PT of more than 20°, and an increase in the T1-pelvic angle of more than 15 degrees can be measured, and paraspinal muscle atrophy and fatty infiltration, including thinning and stretching of the psoas muscles and back extensor muscle atrophy, can be detected on lumbar spine MRI. Spine angiography 3-dimensional CT is very useful to confirm the condition of major abdominal vessels, including the abdominal aorta, inferior vena cava, and iliac vessels, as well as the previous bony fusion state, facet changes, intradiscal vacuum changes, and adjacent segment pathology.

Accordingly, the initial radiological parameters included in this series of post-fusion lumbar flatback deformity demonstrated similar phenomena; PI, 53 \pm 9°; LL, 2 \pm 22° kyphosis; PI-LL, 55 \pm 24°; SVA, 194 \pm 80 mm; T1PA, 43 \pm 13°, and PT : 30 \pm 10°.

The aim of surgery for correction of post-fusion lumbar flatback deformity is to achieve a stable, well-balanced lumbar spine centered over the pelvis. Surgical treatment involves correction of lordotic spinal alignment in the flat or kyphotic lumbar spine by corrective osteotomies, such as PSO or lower lumbar SPOs with ALIFs. In patients with post-fusion flatback whose main pathology was hypolordotic lumbar fusion (19 cases), PSO were performed at L2 in 4 cases, L3 in 8 cases, and L4 in 7 cases. The others 9 patients were corrected with lower lumbar SPOs with ALIFs. The posterior only approach, including PSO, was done by one-stage operation, but lower lumbar SPOs with multilevel ALIFs were usually segmented as staged opera-

tions with initial posterior lower lumbar SPOs followed by anterior ALIFs and rod placement posteriorly (9 cases). Regarding surgical methods and indications, posterior only approach (PSO) was performed in patients with evidence of satisfactory fusion at previous surgical levels on radiological follow ups whereas cases lacking the assured evidence of fusion, anterior approach such as ALIFs was combined for proper fusion achievement as well as restoration of lordosis. Similarly, in those cases in which satisfactory fusion up to S1 level was evident, LIV was not extended to iliac level. On the other hand in patients with insufficient fusion at L4-5 and L5S1 level, iliac screw fixation procedure was performed to augment L5S1 interbody fusion.

Several different methods exist for preoperative measurement for aimed correction⁹⁾. Most of these methods are geometrical and merely take into account the numerical amount of correction angles required to shift the location of the head properly over the pelvis. However, recent studies have shown that sagittal spinopelvic parameters among patients with spinal deformity play a role in clinical outcomes. These studies rated the severity of adult spinal deformity using the Scoliosis Research Society (SRS)-Schwab ASD classification and compared the results to HRQOL, PI-LL mismatch, SVA, and PT values¹⁹⁾. The radiological parameters are important, as they can predict the patients' prognosis and satisfaction levels. Among these parameters, LL can be modified through surgical intervention, but PI is a constant value that is fixed for each individual¹⁰⁾. Similarly, the PI-LL mismatch can adversely affect HRQOL, regardless of actual surgical performance^{15-17,19)}. Schwab et al.¹⁴⁾ reported threshold values for sagittal spinopelvic alignment to achieve during reconstructive surgery for improved HRQOL. Surgical outcomes are generally measured using PI-LL values. According to the SRS-Schwab classification, good surgical outcomes are achieved if the PI-LL value ranges within \pm 10°. According to Schwab, the equation $LL=PI+9^\circ (\pm 9)$ is a basic calculation in asymptomatic adults. He suggested that realignment objectives in the sagittal plane should aim for a postoperative SVA < 50 mm, PT $< 20^\circ$, and $LL=PI+9^\circ$ to achieve spinopelvic realignment¹⁴⁾. Lafage et al.⁵⁾ have proposed that SVA is associated with HRQOL and pelvic retroversion. Berjano et al.²⁾ have suggested that the rule

LL=- (PI+10°) can be used to plan for good alignment. However, the authors note that is not easy to predict optimal alignment when correcting deformity¹³.

Due to the variability of SVA value according to the different degree of pelvic retroversion or knee flexion even in a single subject, the T1PA value has been frequently cited and well acclaimed as a reliable, consistent radiological parameter that could be correlated with surgical outcome recently. This T1PA value accounts for both SVA and pelvic tilt, and according to the several references, this might be reduced to less than 10° in order to achieve optimal surgical outcome both radiologically and clinically^{8,11}. The representability of T1PA instead of SVA was also reflected in our series; 11° for the normal SVA group and 22° for positive SVA group even after correction.

The authors' concept or suggestion according to past several years of surgical experiences in post-fusion lumbar flatback deformity would be that postoperative LL in these cases should be greater than PI to restore and maintain normal sagittal spinal balance. Because Asian patients with post-fusion lumbar flatback are generally osteoporotic, elderly females with poor paraspinal muscle condition due to fatty degenerative changes, atrophy of the back muscles, and thinning of the paraspinal and psoas muscles, the compensatory role from the paraspinal muscles is insufficient. There is an obvious difference in the volume of the paraspinal muscles between Asian and Western populations and since its volume is usually smaller for Asians, even if the initial or background PI-LL value might be similar, loading on the spine would be relatively higher. Paraspinal muscle atrophy due to surgery should be considered, as well^{6,7}. Therefore, restoration of lumbar lordosis below the PI value might result in another or secondary postoperative or delayed sagittal imbalance consequently. Roussouly^{1,10} and Barrey et al.¹ have also suggested theoretical values for PT and LL related to pelvic incidence. They categorized PI into 6 groups (I to VI) and recommended theoretical LL and PT in each PI group.

In this study, at the final follow-up, the normal SVA group (82%) had SVA of 7 mm, while the positive SVA group had SVA of 73 mm, a significant difference between groups. The PI-LL was -5° for the normal SVA group and 3° for the positive SVA group and T1PA was 11° for the normal SVA group and 22° for positive SVA group. The PI-LL, SVA, and T1PA were significantly different between groups. This pattern was exceptional for the PT. At the final follow-up, the ODI score, VAS scores for back and leg pain, and SRS-22r score showed improvement in all 28 patients. But between two groups for comparison, there were no significant differences in ODI, VAS score of the back pain/leg pain, and SRS-22r score including 5 main domains.

Due to the intense, multilevel- involving, corrective procedure in revisional fashion, the expected occurrences of untoward consequence could surge during the management of this post-fusion lumbar flatback deformity [in our series, the reoperation rate was 46% (13 patients)] compared to other spinal procedures. Most of these necessity of revisional procedure were re-

lated to the proximal junctional problems (UIV or UIV+1 fractures) or instrument failure frequently brought up at the UIV level during early postoperative period except one case of severe neurological deficit. Fortunately, a positive prognosis through revision surgery was anticipated in most of compromised cases.

In addition, patients with all early revision and late revisions due to rod fractures or nonunion did not change significantly in the SVA, only delayed PJK patients progressed positive SVA.

Despite the slightly higher complication rate, most of patients were categorized as improved clinical outcomes with higher satisfaction, in accordance with radiological parameter improvements.

Limitation

Due to the limited number of patients undergoing corrective osteotomy for post-fusion lumbar flatback deformity, this series might not fulfill statistical power with probable yield of beta error. Therefore, future studies should focus on statistical analyses based on large study population. Nevertheless this study has analyzed population with long follow up period and hence bears significance.

Additionally, concomitant presence of atrophic changes of the paraspinal muscles along with hypolordotic fusion, adjacent segment disease, and non-union with or without anterior column insufficiency probably resulted in post-fusion flatback deformity in our current study. Several studies have suggested that the volume of lumbar back muscles has a significant effect on the degenerative kyphosis of patients¹⁸. But we did not perform any evaluations regarding the muscle volumes and their effect which can be regarded as one of the limitations. Therefore, we believe that the volume of paraspinal muscles is an important determining factor and should be further evaluated to predict the patient's condition or prognosis in post-lumbar fusion.

CONCLUSION

Fixed sagittal imbalance after lumbar spinal fusion could limit or disable quality of life. PSO or SPOs combined with multilevel ALIFs at the lower lumbar spine are significantly improves sagittal balance in post-fusion lumbar flatback patients with sagittal imbalance. For restoration and maintenance of normal sagittal spinal balance in these patients, PI-LL might be made negative value and T1PA might be less than 11° even though positive SVA group was also significantly improved clinical outcomes.

References

1. Barrey C, Darnis A : Current strategies for the restoration of adequate lordosis during lumbar fusion. *World J Orthop* 6 : 117-126, 2015
2. Berjano P, Langella F, Ismael MF, Damilano M, Scopetta S, Lamartina C : Successful correction of sagittal imbalance can be calculated on the basis of pelvic incidence and age. *Eur Spine J* 23 Suppl 6 : 587-596, 2014
3. Jang JS, Lee SH, Min JH, Maeng DH : Changes in sagittal alignment after restoration of lower lumbar lordosis in patients with degenerative flat back syndrome. *J Neurosurg Spine* 7 : 387-392, 2007

4. Janik TJ, Harrison DD, Cailliet R, Troyanovich SJ, Harrison DE : Can the sagittal lumbar curvature be closely approximated by an ellipse? *J Orthop Res* 16 : 766-770, 1998
5. Lafage V, Schwab F, Patel A, Hawkinson N, Farcy JP : Pelvic tilt and trun- cal inclination : two key radiographic parameters in the setting of adults with spinal deformity. *Spine (Phila Pa 1976)* 34 : E599-E606, 2009
6. Motosuneya T, Asazuma T, Tsuji T, Watanabe H, Nakayama Y, Nemoto K : Postoperative change of the cross-sectional area of back musculature after 5 surgical procedures as assessed by magnetic resonance imaging. *J Spinal Disord Tech* 19 : 318-322, 2006
7. Pourtaheri S, Issa K, Lord E, Ajiboye R, Drysch A, Hwang K, et al. : Para- spinal muscle atrophy after lumbar spine surgery. *Orthopedics* 39 : e209- e214, 2016
8. Protosaltis T, Schwab F, Bronsard N, Smith JS, Klineberg E, Mundis G, et al. : The T1 pelvic angle, a novel radiographic measure of global sagit- tal deformity, accounts for both spinal inclination and pelvic tilt and cor- relates with health-related quality of life. *J Bone Joint Surg Am* 96 : 1631- 1640, 2014
9. Rose PS, Bridwell KH, Lenke LG, Cronen GA, Mulconrey DS, Buchows- ki JM, et al. : Role of pelvic incidence, thoracic kyphosis, and patient factors on sagittal plane correction following pedicle subtraction osteot- omy. *Spine (Phila Pa 1976)* 34 : 785-791, 2009
10. Roussouly P, Gollogly S, Berthonnaud E, Dimnet J : Classification of the normal variation in the sagittal alignment of the human lumbar spine and pelvis in the standing position. *Spine (Phila Pa 1976)* 30 : 346-353, 2005
11. Ryan DJ, Protosaltis TS, Ames CP, Hostin R, Klineberg E, Mundis GM, et al. : T1 pelvic angle (TPA) effectively evaluates sagittal deformity and assesses radiographical surgical outcomes longitudinally. *Spine (Phila Pa 1976)* 39 : 1203-1210, 2014
12. Schwab F, Dubey A, Gamez L, El Fegoun AB, Hwang K, Pagala M, et al. : Adult scoliosis : prevalence, SF-36, and nutritional parameters in an el- derly volunteer population. *Spine (Phila Pa 1976)* 30 : 1082-1085, 2005
13. Schwab F, Lafage V, Patel A, Farcy JP : Sagittal plane considerations and the pelvis in the adult patient. *Spine (Phila Pa 1976)* 34 : 1828-1833, 2009
14. Schwab F, Patel A, Ungar B, Farcy JP, Lafage V : Adult spinal deformity- postoperative standing imbalance : how much can you tolerate? An overview of key parameters in assessing alignment and planning correc- tive surgery. *Spine (Phila Pa 1976)* 35 : 2224-2231, 2010
15. Schwab FJ, Blondel B, Bess S, Hostin R, Shaffrey CI, Smith JS, et al. : Ra- diographical spinopelvic parameters and disability in the setting of adult spinal deformity : a prospective multicenter analysis. *Spine (Phila Pa 1976)* 38 : E803-E812, 2013
16. Smith JS, Klineberg E, Schwab F, Shaffrey CI, Moal B, Ames CP, et al. : Change in classification grade by the SRS-Schwab Adult Spinal Defor- mity Classification predicts impact on health-related quality of life mea- sures : prospective analysis of operative and nonoperative treatment. *Spine (Phila Pa 1976)* 38 : 1663-1671, 2013
17. Smith JS, Singh M, Klineberg E, Shaffrey CI, Lafage V, Schwab FJ, et al. : Surgical treatment of pathological loss of lumbar lordosis (flatback) in patients with normal sagittal vertical axis achieves similar clinical im- provement as surgical treatment of elevated sagittal vertical axis : clinical article. *J Neurosurg Spine* 21 : 160-170, 2014
18. Takemitsu Y, Harada Y, Iwahara T, Miyamoto M, Miyatake Y : Lumbar degenerative kyphosis. Clinical, radiological and epidemiological stud- ies. *Spine (Phila Pa 1976)* 13 : 1317-1326, 1988
19. Terran J, Schwab F, Shaffrey CI, Smith JS, Devos P, Ames CP, et al. : The SRS-Schwab adult spinal deformity classification : assessment and clini- cal correlations based on a prospective operative and nonoperative co- hort. *Neurosurgery* 73 : 559-568, 2013