

# Endoscopic Endonasal Transodontoid Treatment of a Ruptured Anterior Spinal Artery Aneurysm

Edwin S. Kulubya<sup>1</sup> Tejas Karnati<sup>1</sup> Bart Thaci<sup>1</sup> David Cua<sup>2</sup> Huy Duong<sup>3</sup>

<sup>1</sup>Department of Neurological Surgery, University of California Davis, Sacramento, California, United States

<sup>2</sup>Department of Otolaryngology, The Kaiser Permanente Medical Group, Sacramento, California, United States

<sup>3</sup>Department of Neurological Surgery, The Kaiser Permanente Medical Group, Sacramento, California, United States

**Address for correspondence** Edwin S. Kulubya, MD, Department of Neurological Surgery, UC Davis, 4860 Y St., Suite 3740, Sacramento, CA 95817, United States (e-mail: ekulubya@ucdavis.edu).

J Neurol Surg Rep 2022;83:e67–e71.

## Abstract

Isolated spinal artery aneurysms are a rare cause of intracranial subarachnoid hemorrhage (SAH). A 49-year-old female presented with severe headache. Initial imaging showed SAH and intraventricular hemorrhage (IVH), but no clear source of bleeding was identified. One week into being observed in the intensive care unit, she reported another severe headache. Computed tomography head showed more SAH and IVH. A second angiogram revealed a ruptured small anterior spinal artery (ASA) aneurysm at the craniocervical junction. She underwent a C1–2 fusion followed by an endoscopic endonasal transodontoid approach and wrapping of the ASA aneurysm. At 2 years' follow-up, there was no sign of aneurysm growth or rupture. This is the first reported case of an endoscopic endonasal transodontoid approach to an aneurysm.

## Keywords

- ▶ anterior spinal artery aneurysm
- ▶ endoscopic endonasal transodontoid

## Background and Importance

Isolated spinal artery aneurysms are a rare cause of intracranial subarachnoid hemorrhage (SAH).<sup>1,2</sup> Spinal artery aneurysms are usually associated with arteriovenous malformations (AVMs), arteriovenous (AV) fistulas, coarctation of the aorta, bilateral vertebral artery occlusion, or moyamoya disease.<sup>1,3–5</sup> Ruptured spinal artery aneurysms have been treated conservatively or with surgical clipping when amenable.<sup>6,7</sup> Endovascular treatment is rare due to technical difficulty and risk of cord infarction.<sup>1</sup> Anterior spinal artery (ASA) aneurysms located at the craniocervical junction are even more rare and present a technical challenge for surgical treatment. The anterior craniocervical junction can be approached through a transoral, transcranial, or endonasal approach.<sup>8–10</sup> We present the first case of a ruptured ASA aneurysm in the cervical spine

treated through an endoscopic endonasal transodontoid approach.

## Clinical Presentation

### History and Examination

A 49-year-old female with a history of hypertension presented with sudden-onset severe headache and nausea. Upon admission, she was a Hunt and Hess 3 and her Glasgow Coma Scale score was 13 with no focal neurological deficits. A computed tomography (CT) scan revealed mild hydrocephalus, intraventricular hemorrhage (IVH), and SAH in the premedullary cistern and she was classified as Fisher Grade 4 (▶ **Fig. 1**). Soon after, her mental status declined requiring intubation and an external ventricular drain was placed. Initial digital subtraction angiogram (DSA) revealed no intracranial cerebral aneurysms. She was eventually extubated

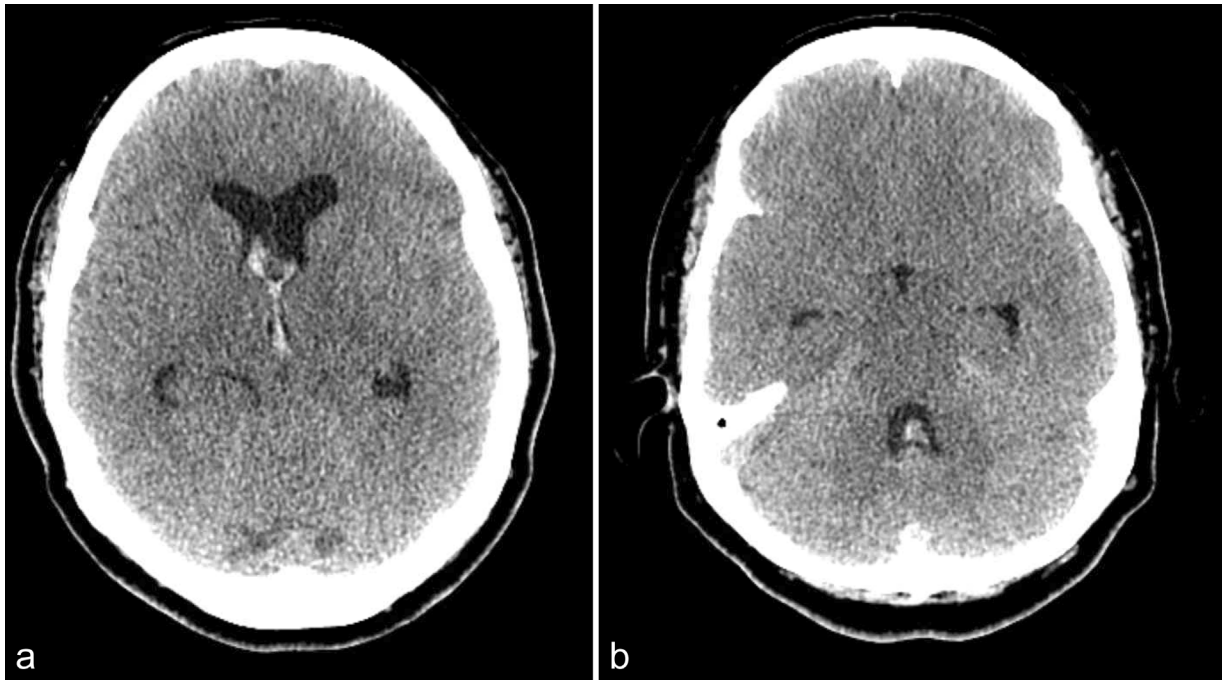
received  
February 26, 2021  
accepted  
October 19, 2021

DOI <https://doi.org/10.1055/s-0042-1751040>.  
ISSN 2193-6358.

© 2022. The Author(s).

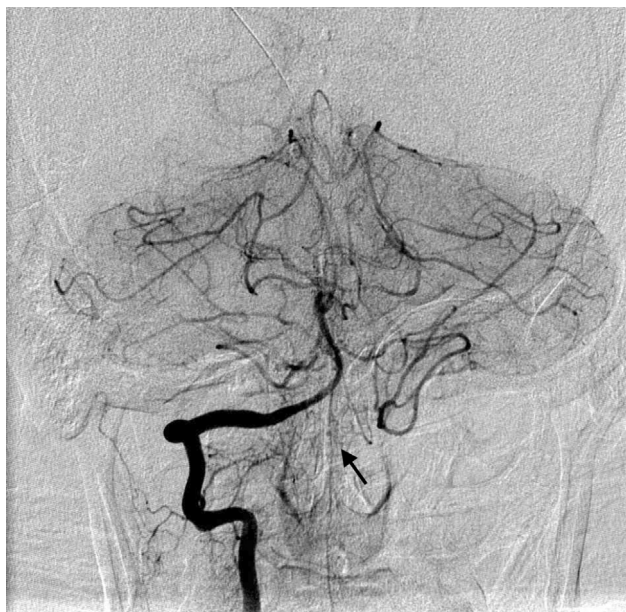This is an open access article published by Thieme under the terms of the Creative Commons Attribution-NonDerivative-NonCommercial-License, permitting copying and reproduction so long as the original work is given appropriate credit. Contents may not be used for commercial purposes, or adapted, remixed, transformed or built upon. (<https://creativecommons.org/licenses/by-nc-nd/4.0/>)

Georg Thieme Verlag KG, Rüdigerstraße 14, 70469 Stuttgart, Germany



**Fig. 1** Computed tomography (CT) head demonstrating acute intraventricular hemorrhage involving the anterior horns of the lateral ventricles as well as the third and fourth ventricles. Almost all basal cisterns are effaced.

and observed in the intensive care unit (ICU). Seven days after her initial presentation she reported a severe headache. CT with angiogram showed new IVH in the fourth ventricle as well as posterior circulation vasospasm. A follow-up DSA revealed a small ( $1 \times 1 \times 1.3$  mm) aneurysm arising from the proximal ASA as well as angiographic vasospasm (**Fig. 2**). Due to her symptoms and rerupture of the aneurysm,

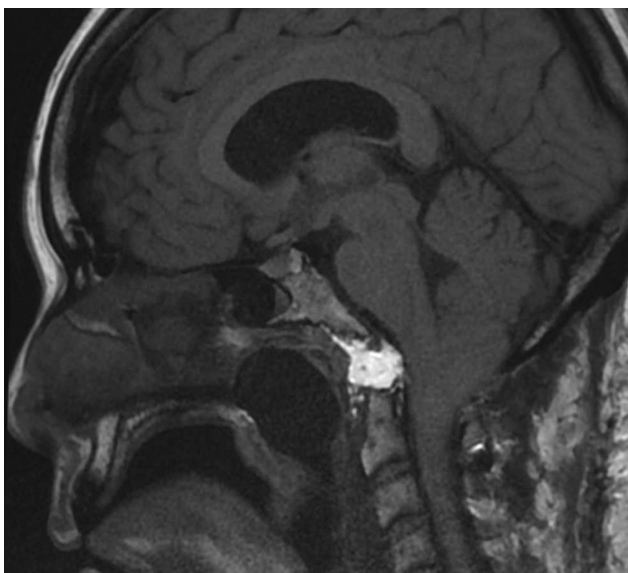


**Fig. 2** Angiography demonstrates a 1.3-mm diameter aneurysm arising from the anterior spinal artery at the C1 level (black arrow). There is mild-moderate vasospasm of the posterior circulation related to the patient's prior subarachnoid hemorrhage. There is no other supply to the anterior spinal artery from the more proximal right vertebral artery or from the left vertebral artery.

surgical intervention was proposed. A decision was made to first undergo C1 to C2 posterior instrumented fusion and then undergo an anterior endonasal transodontoid approach to the ASA aneurysm.

#### Operative Technique

The patient was positioned supine and general endotracheal anesthesia was induced. The head placed in a Mayfield fixation device with pins and the head slightly tilted to the left. Stryker image guidance (Kalamazoo, Michigan, United States) was used. A 0-degree endoscope (Karl Storz, Germany) was used and a nasoseptal flap (NSF) was raised from the right nasoseptal mucosa and reflected superiorly, a reverse flap was raised on the left side then reflected to the right side and held down with 4-0 chromic suture. The posterior nasal septum was removed from the sphenoid rostrum and a wide sphenoidotomy was performed. The fossa of Rosenmuller was directly visualized with the eustachian tubes laterally and soft palate caudally. The nasopharyngeal fascia was peeled down from the sphenoid floor down to the inferior clivus, then over toward the anterior arch of C1. A flap was created in the nasopharynx to expose the paraspinal muscles. After dissecting off the fascia and reflecting the paraspinal muscles laterally, the C1 anterior arch was visualized and drilled down until the odontoid process was seen. The odontoid process was then drilled down with a high-speed diamond burr to the C2 vertebral body. The inferior aspect of the C1 anterior arch was left behind so that the pharyngobasilar fascia could be buttressed and secured inferiorly. The tectorial membrane was removed using a Tru-Cut and 2 mm Kerrison rongeurs. The dura was then visualized and was translucent enough that the ASA aneurysm could be seen through it.



**Fig. 3** Postoperative T1 magnetic resonance imaging (MRI) showing postoperative corridor and fat graft.

After confirming with Doppler, the dura was opened and reflected inferiorly. The ASA aneurysm was identified along the inferior aspect of the C1 arch. The arachnoid was opened around the aneurysm. The aneurysm was too small to be clipped. The decision was made to wrap the aneurysm with wisps of cotton. The cotton was then secured using a fibrin sealant (Tisseel).

Reconstruction was done in a multilayer fashion. The dura was repaired with a collagen dural substitute (DuraGen) placed intradurally followed by an extradural DuraGen onlay. An abdominal fat graft was harvested and packed into the skull base defect. The pharyngobasilar fascia was then reflected up over the fat graft and sutured superiorly using 4-0 vicryl. The fascia and surrounding mucosa were cauterized to create a raw surface. The NSF was then laid over the raw surface of the clivus and pharyngobasilar fascia. Surgicel was laid down followed by Tisseel. The entire construct was then buttressed with Nasopore followed by a nasal Foley balloon. The patient tolerated the procedure well and was extubated.

#### Postoperative Course

The patient was extubated and discharged home a few weeks later. Follow-up magnetic resonance imaging showed no growth of aneurysm or rehemorrhage (→ Fig. 3). At 2 years postrupture the patient was clinically doing well without neurological deficit.

## Discussion

### Pathogenesis

Spinal artery aneurysms are rare due to the small caliber of the vessel and they are usually not affected by atherosclerosis.<sup>11</sup> In comparison to intracranial aneurysms, they tend to occur along the course of an artery, rather than branch points.<sup>5,12</sup> Cases have reported spinal artery

aneurysms caused by infectious or inflammatory diseases such as pseudoxanthoma elasticum, fibromuscular dysplasia, Behcet's disease, systemic candidiasis, and rheumatoid arthritis, which weaken the vascular wall.<sup>13</sup> Hemodynamic stress related to AVMs, coarctation of the aorta, and in one case bilateral vertebral artery occlusion have also caused spinal artery aneurysms.<sup>2</sup> Typically, spinal artery aneurysms are actually pseudoaneurysms and rupture due to dissection.<sup>5,14,15</sup>

High cervical and thoracolumbar levels are the most common sites of isolated spinal artery aneurysms.<sup>12</sup> Cervical spinal artery aneurysms tend to present with neck pain, 6th nerve palsies, loss of consciousness, hemiparesis, or quadriplegia, whereas thoracolumbar level aneurysm ruptures present with sudden back pain and lower extremity motor or sensory deficit.<sup>12</sup>

### ASA Aneurysm Treatment

The first descriptions of a ruptured ASA aneurysm in the high cervical cord were described in the early 1980s. Yonas et al described an anomalous ASA in a 42-year-old woman who presented with headache and SAH and was treated with external ventricular drainage but reruptured and died.<sup>16</sup> Vincent described a 30-year-old woman who also presented with headache, then had focal neurologic deficits related to vasospasm and underwent successful clipping.<sup>17</sup> The surgical approach was not described but this was the first report of successful surgical treatment. Soon after, Moore et al described a partially blind clipping of a C1 level ASA aneurysm through a posterior approach with transection of the dentate ligament and fluoroscopic localization to place the clip.<sup>18</sup>

Many cases of SAH secondary to spinal artery aneurysms are managed conservatively. Gutierrez Romero et al described a case where a 37-year-old female presented with headaches and posterior fossa SAH from a ruptured T3 radiculomedullary branch aneurysm that was feeding the ASA which spontaneously resolved at follow-up.<sup>1</sup> Karakama et al also presented a case of an ASA aneurysm at the C1 level managed conservatively due to concern that the blood flow to the parent artery would be disturbed in any treatment attempt. Follow-up angiography at the 108th day showed no aneurysm.<sup>12</sup> The delayed approach to treatment appears reasonable in stable patients. Aneurysms also related to an underlying vasculitis or noninflammatory vasculopathy are more likely to self-resolve with treatment of the underlying condition.<sup>19</sup>

The first case of a ruptured spinal artery aneurysm embolized with Onyx was just recently described in a patient with ruptured thoracic ASA fusiform aneurysm who presented with paraplegia. Due to the patient's already complete spinal cord injury the parent vessel was deconstructed and the aneurysm occluded to prevent a higher cervical injury.<sup>14</sup> Overall, endovascular treatment options are limited due to the small caliber of vessels and risk of reflux of embolization material or coils into the parent artery.

In our case, while our patient was being managed conservatively with observation in the ICU and an external ventricular drain for hydrocephalus and IVH, she experienced a second



rupture of her aneurysm. This prompted surgical treatment. Surgery has been described in the literature through various approaches. Posterior spinal artery aneurysms, though more rare, are more easily treated surgically due to their position and direct access with laminectomy.<sup>13</sup> Massand et al presented four cases of isolated thoraco-lumbar spinal artery aneurysms all successfully treated surgically.<sup>20</sup> Chen et al also described lateral spinal artery aneurysms in the cervical spine, one treated endovascularly with coils and was complicated by posterior inferior cerebellar artery stroke and the other through a suboccipital craniotomy.<sup>21</sup>

More recent cases describe clipping via a lateral suboccipital approach.<sup>22,23</sup> Mansour et al described a case involving an ASA aneurysm related to an AV fistula utilized a novel fluorescence image-guided system and an endoscope to help clip the aneurysm.<sup>3</sup> This highlights the difficulty in being able to directly observe the medial side of an ASA aneurysm through standard approaches.

### Endoscopic Endonasal Transodontoid Approach

The endoscope has revolutionized the field of skull base surgery. The first case of an endoscopic endonasal approach and odontoid resection was described by Kassam et al for a patient with rheumatoid arthritis and cervicomedullary junction compression.<sup>24</sup> The morbidities of transoral approach caused by palatal splitting, tongue retraction, and an oropharyngeal incision are avoided with endoscopic endonasal approach.<sup>8,24</sup>

The endoscopic endonasal approach can provide direct access for surgical treatment of rare and properly selected intracranial aneurysms.<sup>25</sup> Kassam et al described an endonasal approach to the craniocervical junction to clip and resect partially thrombosed vertebral artery aneurysm.<sup>26</sup> In our case, we had direct access to the C1 arch and odontoid, which lied directly in front of the aneurysm.

The risk of cerebrospinal fluid (CSF) leak has been greatly minimized with the use of NSFs in expanded endonasal approaches.<sup>27</sup> In addition to this our buttress with fat graft and Tisseel proved adequate to prevent CSF leak.

### Aneurysm Wrapping

Wrapping aneurysms deemed unclippable is safe and protects against aneurysmal growth or SAH.<sup>28</sup> The most common wrapping agents are cotton and muslin, followed by muscle, gauze, and oxidized cellulose variously combined with ethyl cyanoacrylate, Histoacryl, and adhesives (fibrin glue and Biobond).<sup>29</sup>

Deshmukh et al reviewed the largest series of unclippable wrapped intracranial aneurysms.<sup>28</sup> The most common variant of unclippable aneurysms were small aneurysms without an adequate reconstructable neck, similar to spinal artery aneurysms. In their series, 61 aneurysms were wrapped with cotton with a mean follow-up of 44 months and no change in aneurysm size or configuration was seen.

In the spine, Vishteh et al described the successful muslin wrapping of a fusiform aneurysm of the intradural portion of the artery of Adamkiewicz.<sup>30</sup> With wrapping, there is a small risk of ischemic complications and granuloma formation.<sup>29</sup>

In our case, the size of the aneurysm and the lack of a 90-degree clip applicator for our endoscope made this aneurysm unclippable. Wrapping conferred the most benefit versus leaving the aneurysm untreated or performing a dangerous clip maneuver.

### Conclusion

Spinal artery aneurysms are rare but should be considered in cases of intracranial SAH when no other source is found. The endoscopic endonasal transodontoid route provides an effective corridor to the craniocervical junction and ventral spinal cord. In this case the rare pathology of a ruptured ASA aneurysm was able to be treated effectively through this anterior approach. Cotton wrapping with fibrin sealant was enough to protect against aneurysm growth or rerupture with 2 years of follow-up.

Endoscopic endonasal approaches for aneurysm repair are an effective option for aneurysms that are difficult to access via standard open approaches and cannot be fully treated endovascularly. The ASA aneurysm located at the craniocervical junction provided a unique opportunity for this approach to be utilized.

### Funding

None.

### Conflict of Interest

None declared.

### Acknowledgments

None.

### References

- Gutierrez Romero D, Batista AL, Gentic JC, Raymond J, Roy D, Weill A. Ruptured isolated spinal artery aneurysms. Report of two cases and review of the literature. *Interv Neuroradiol* 2014;20(06):774–780
- Rengachary SS, Duke DA, Tsai FY, Kragel PJ. Spinal arterial aneurysm: case report. *Neurosurgery* 1993;33(01):125–129, discussion 129–130
- Mansour A, Endo T, Inoue T, et al. Clipping of an anterior spinal artery aneurysm using an endoscopic fluorescence imaging system for craniocervical junction epidural arteriovenous fistula: technical note. *J Neurosurg Spine* 2019;31(02):1–6
- Jiarakongmun P, Chewit P, Pongpech S. Ruptured anterior spinal artery aneurysm associated with coarctation of aorta. Case report and literature review. *Interv Neuroradiol* 2002;8(03):285–292
- Gonzalez LF, Zabramski JM, Tabrizi P, Wallace RC, Massand MG, Spetzler RF. Spontaneous spinal subarachnoid hemorrhage secondary to spinal aneurysms: diagnosis and treatment paradigm. *Neurosurgery* 2005;57(06):1127–1131, discussion 1127–1131
- Roka YB. Isolated cervical anterior spinal artery aneurysm: case report. *Br J Neurosurg* 2019;33(05):568–569
- Pahl FH, de Oliveira MF, Rotta MAC, Dias GMS, Rezende AL, Rotta JM. Spontaneous resolution of an isolated cervical anterior spinal artery aneurysm after subarachnoid hemorrhage. *Surg Neurol Int* 2014;5:139(Supplement)
- Alfieri A, Jho HD, Tschabitscher M. Endoscopic endonasal approach to the ventral cranio-cervical junction: anatomical study. *Acta Neurochir (Wien)* 2002;144(03):219–225, discussion 225

- 9 Liu JK, Patel J, Goldstein IM, Eloy JA. Endoscopic endonasal transclival transodontoid approach for ventral decompression of the craniovertebral junction: operative technique and nuances. *Neurosurg Focus* 2015;38(04):E17
- 10 Baird CJ, Conway JE, Sciubba DM, Prevedello DM, Quiñones-Hinojosa A, Kassam AB. Radiographic and anatomic basis of endoscopic anterior craniocervical decompression: a comparison of endonasal, transoral, and transcervical approaches. *Neurosurgery* 2009;65(6, Suppl):158–163, discussion 63–64
- 11 Leech PJ, Stokes BAR, ApSimon T, Harper C. Unruptured aneurysm of the anterior spinal artery presenting as paraparesis. Case report. *J Neurosurg* 1976;45(03):331–333
- 12 Karakama J, Nakagawa K, Maehara T, Ohno K. Subarachnoid hemorrhage caused by a ruptured anterior spinal artery aneurysm. *Neurol Med Chir (Tokyo)* 2010;50(11):1015–1019
- 13 Geibprasert S, Krings T, Apitzsch J, Reinges MHT, Nolte KW, Hans FJ. Subarachnoid hemorrhage following posterior spinal artery aneurysm. A case report and review of the literature. *Interv Neuroradiol* 2010;16(02):183–190
- 14 Cobb M, Griffin A, Karikari I, Gonzalez LF. Endovascular treatment of ruptured enlarging dissecting anterior spinal artery aneurysm. *World Neurosurg* 2020;139:e658–e662
- 15 Toyota S, Wakayama A, Fujimoto Y, Sugiura S, Yoshimine T. Dissecting aneurysm of the radiculomedullary artery originating from extracranial vertebral artery dissection in a patient with rheumatoid cervical spine disease: an unusual cause of subarachnoid hemorrhage. Case report. *J Neurosurg Spine* 2007;7(06):660–663
- 16 Yonas H, Patre S, White RJ. Anterior spinal artery aneurysm. Case report. *J Neurosurg* 1980;53(04):570–573
- 17 Vincent FM. Anterior spinal artery aneurysm presenting as a subarachnoid hemorrhage. *Stroke* 1981;12(02):230–232
- 18 Moore DW, Hunt WE, Zimmerman JE. Ruptured anterior spinal artery aneurysm: repair via a posterior approach. *Neurosurgery* 1982;10(05):626–630
- 19 Berlis A, Scheufler K-M, Schmahl C, Rauer S, Götz F, Schumacher M. Solitary spinal artery aneurysms as a rare source of spinal subarachnoid hemorrhage: potential etiology and treatment strategy. *AJNR Am J Neuroradiol* 2005;26(02):405–410
- 20 Massand MG, Wallace RC, Gonzalez LF, Zabramski JM, Spetzler RF. Subarachnoid hemorrhage due to isolated spinal artery aneurysm in four patients. *AJNR Am J Neuroradiol* 2005;26(09):2415–2419
- 21 Chen CC, Bellon RJ, Ogilvy CS, Putman CM. Aneurysms of the lateral spinal artery: report of two cases. *Neurosurgery* 2001;48(04):949–953, discussion 953–954
- 22 Kawamura S, Yoshida T, Nonoyama Y, Yamada M, Suzuki A, Yasui N. Ruptured anterior spinal artery aneurysm: a case report. *Surg Neurol* 1999;51(06):608–612
- 23 Pollock JM, Powers AK, Stevens EA, Sanghvi AN, Wilson JA, Morris PP. Ruptured anterior spinal artery aneurysm: a case report. *J Neuroimaging* 2009;19(03):277–279
- 24 Kassam AB, Snyderman C, Gardner P, Carrau R, Spiro R. The expanded endonasal approach: a fully endoscopic transnasal approach and resection of the odontoid process: technical case report. *Neurosurgery* 2005;57(1, Suppl):E213, discussion E213
- 25 Gardner PA, Vaz-Guimaraes F, Jankowitz B, et al. Endoscopic endonasal clipping of intracranial aneurysms: surgical technique and results. *World Neurosurg* 2015;84(05):1380–1393
- 26 Kassam AB, Mintz AH, Gardner PA, Horowitz MB, Carrau RL, Snyderman CH. The expanded endonasal approach for an endoscopic transnasal clipping and aneurysmorrhaphy of a large vertebral artery aneurysm: technical case report. *Neurosurgery* 2006;59(01, Suppl 1):E162–E165, discussion E162–E165
- 27 Patel MR, Stadler ME, Snyderman CH, et al. How to choose? Endoscopic skull base reconstructive options and limitations. *Skull Base* 2010;20(06):397–404
- 28 Deshmukh VR, Kakarla UK, Figueiredo EG, Zabramski JM, Spetzler RF. Long-term clinical and angiographic follow-up of unclippable wrapped intracranial aneurysms. *Neurosurgery* 2006;58(03):434–442, discussion 434–442
- 29 Perrini P, Montemurro N, Caniglia M, Lazzarotti G, Benedetto N. Wrapping of intracranial aneurysms: single-center series and systematic review of the literature. *Br J Neurosurg* 2015;29(06):785–791
- 30 Vishteh AG, Brown AP, Spetzler RF. Aneurysm of the intradural artery of Adamkiewicz treated with muslin wrapping: technical case report. *Neurosurgery* 1997;40(01):207–209