



Bilateral distal femoral epiphyseal detachment in a young adult: a case report

Armand Yepie, MD ^{ID}, Moctar Traore, MD ^{ID}, Mensah Yaovi, MD ^{ID}, Michel Anoumou, MD ^{ID}

Department of Orthopedic Surgery, Treichville Teaching Hospital, Abidjan, Côte d'Ivoire

Received: February 28, 2023

Revised: May 29, 2023

Accepted: June 7, 2023

Correspondence to

Armand Yepie, MD

Department of Orthopedic Surgery,
Treichville Teaching Hospital, BPV 03
Abidjan 01, Côte d'Ivoire

Tel: +225-0707693064

Email: armandyepie@gmail.com

Epiphyseal dislocations and fractures frequently occur in children and adolescents. However, these injuries seldom involve the distal femur, and bilateral cases are even rarer. We present an unusual case of bilateral epiphyseal detachment of the femur in a 21-year-old man who was involved in a traffic accident. Open reduction and fixation surgery were performed 5 days after the incident. The patient experienced favorable progress, with consolidation occurring at 3 months. No lower limb length discrepancies were observed at the 20-month follow-up. In summary, bilateral distal femoral epiphyseal detachment is an uncommon condition that can be effectively treated through surgical intervention.

Keywords: Epiphyseal detachment; Growth plate; Young adult; Case reports

INTRODUCTION

Epiphyseal detachments are common injuries in children and adolescents, accounting for 30% of fractures observed in this age group [1]. Because these injuries involve the growth plate, they are associated with a high risk of growth disturbance, leg length discrepancies, and angular deformities. Furthermore, distal femoral physeal fractures have a high incidence of growth arrest [2].

Unilateral or bilateral distal femoral physeal fractures and fracture dislocations are relatively rare, accounting for only 2% to 4% of all cartilage injuries [1,3]. Furthermore, young adults nearing the end of the growth phase are typically not affected by these types of injuries [4]. In this report, we present a case of bilateral distal femoral epiphyseal detachment in a healthy young man.

CASE REPORT

A 21-year-old young adult worker with no prior medical history presented to the emergency room. He had experienced closed trauma to both knees due to a road accident occurring 48 hours earlier. The patient had been struck by an oncoming vehicle, with the mechanism of injury being a posterior-anterior impact to the knees while he was standing, causing hyperextension. Consequently, the patient became trapped between two vehicles and experienced pain and complete functional impairment of the lower limbs. Upon initial clinical examination, painful bilateral swelling of the knees with abduction and external rotation was observed (Fig. 1).

Upon clinical examination at the hospital, no skin or vascular complications were observed. Standard radiographs revealed a bilateral distal femoral epiphyseal detachment, with a Salter I

fracture on the left and a Salter II fracture on the right. Additionally, an anterior tilt of the distal fragment was noted (Fig. 2).

No attempt had been made at reduction prior to the patient's admission to our unit. Routine laboratory tests and blood calci-

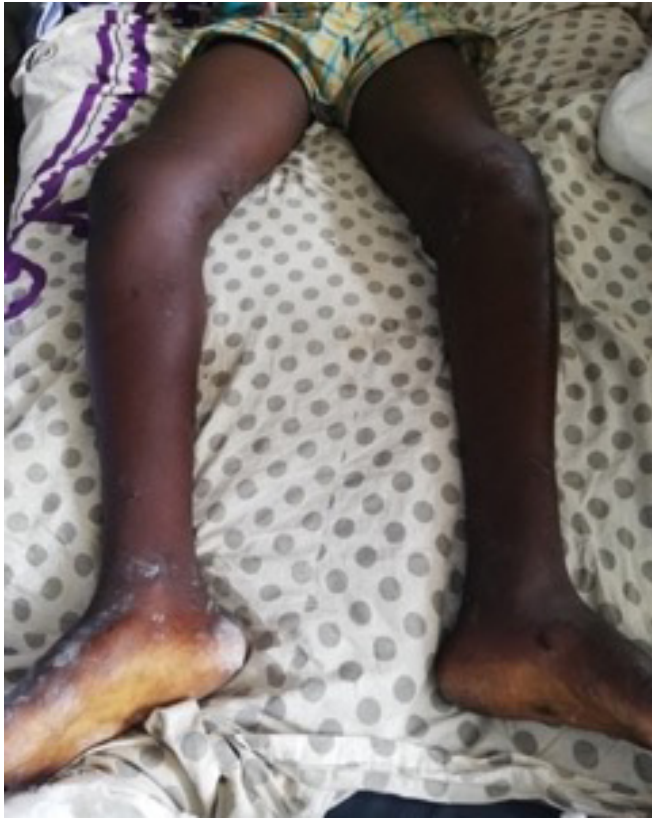

Fig. 1. Frontal view of the pelvic limbs. Note the swelling associated with abduction and external rotation.

um levels were found to be normal. An open reduction was carried out 5 days after admission. The procedure took place in the operating room under general anesthesia, utilizing a lateral approach to the femur. Following the open reduction, double cross-pinning was performed, and immobilization was then achieved using a posterior plaster cast. Postoperative x-rays revealed a satisfactory reduction (Fig. 3).

Following surgery, a brace was applied for 6 weeks. The patient received analgesic treatment, antibiotics, and antithrombosis prophylaxis. He remained in the hospital for 10 days and continued to receive local care as an outpatient. Rehabilitation began at 6 weeks, involving mobilizations and physiotherapy, with full weight-bearing permitted at 3 months. At 20 months posttrauma, the patient exhibited good consolidation, bilateral painless support, and no limb length inequality. However, there was a limitation in knee flexion and a residual valgus estimated at 10° in the right knee (Fig. 4).

Ethics statement

Informed consent for the publication of research details and clinical images was obtained from the patient.

DISCUSSION

Epiphyseal detachments and fractures are common injuries in children and adolescents [4,5]. Few cases have been reported of bilateral femoral epiphyseal detachment in healthy young adults. In adults, these injuries are typically associated with metabolic disorders [6]. Peterson et al. [4] described two cases of epiphyseal detachments in patients over 20 years old, but both had endo-

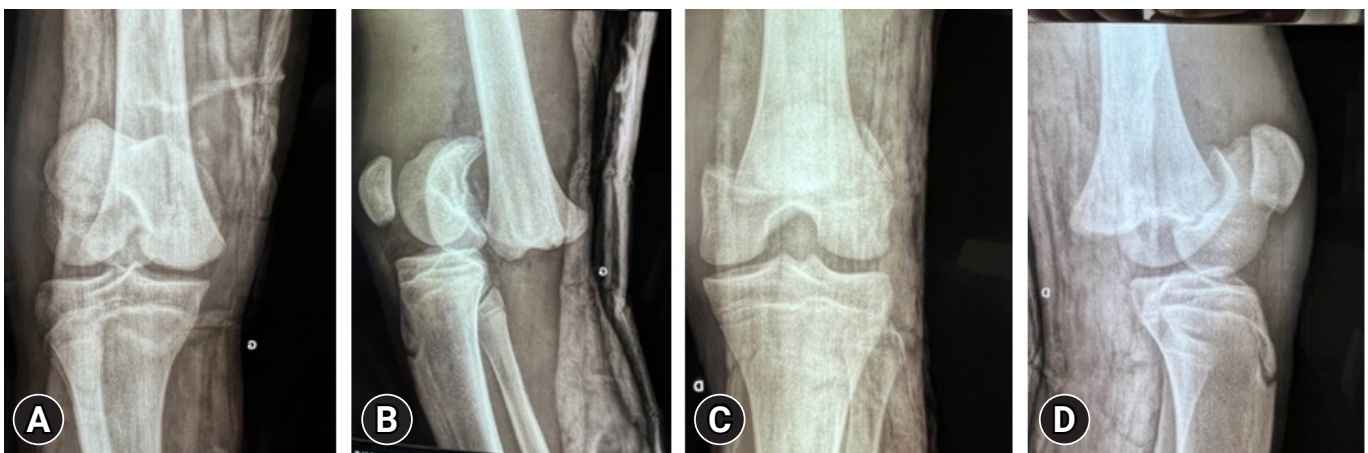


Fig. 2. Knee x-rays depicting epiphyseal lesions. (A) Frontal and (B) lateral x-ray of the left knee displaying a Salter I distal femoral epiphyseal detachment. (C) Frontal and (D) lateral x-ray of the right knee displaying a Salter II distal femoral epiphyseal detachment.

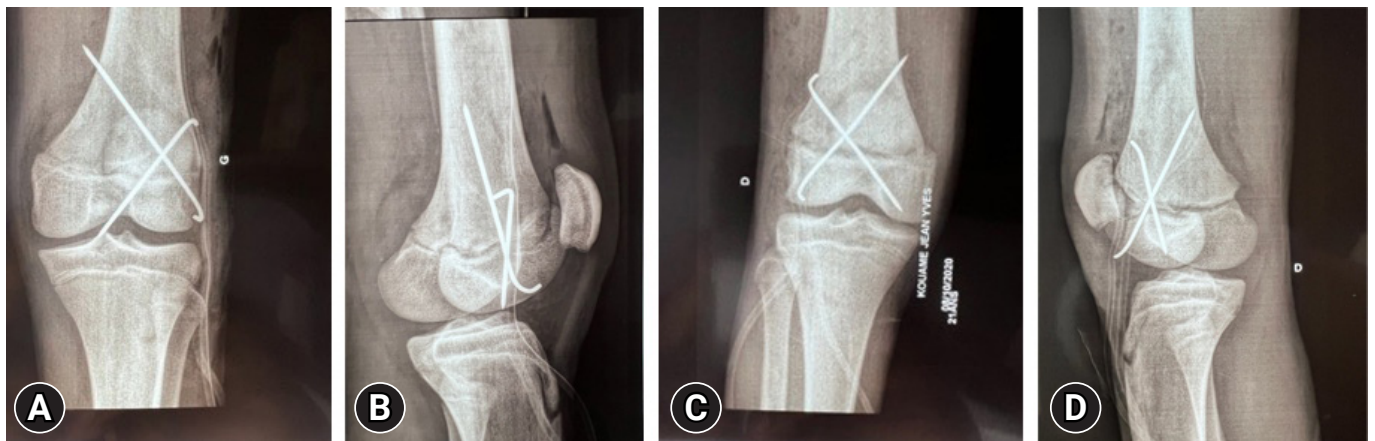


Fig. 3. Postoperative control radiographs. (A) Frontal and (B) lateral x-ray of the left knee. (C) Frontal and (D) lateral x-ray of the right knee.



Fig. 4. Standing limb appearance at 20-month posttreatment. Note the right valgus knee.

crine pathologies. Our patient had no notable medical history, suggesting that the bilateral detachment was likely due to the injury mechanism of direct back-to-front impact in a standing individual with late physeal fusion. Closed reduction using external movements and pinning is the treatment method most commonly recommended to minimize the risk of complications [7–10]. However, this closed-focus approach should be performed promptly to ensure its effectiveness. The relatively long delay in managing the patient necessitated an open reduction and pin-

ning instead. In fact, we could not achieve reduction without exposing the fracture site and directly manipulating the fragments. We chose pinning because it provides stable fixation and helps prevent complications related to the growth plate, such as physeal damage [9]. This delay was due to the patient’s financial difficulties, as he lacked health insurance. Despite these challenges, our chosen method allowed for anatomical reduction and proper stabilization, leading to successful healing. The progression of distal femoral detachment fractures is characterized by a substantial risk of growth disorders, angular deviations, and joint stiffness due to the high growth potential of the affected area [5,11]. Salter II and IV fractures carry a higher risk of growth failure than other injury types [3]. This was confirmed in our patient, who had a Salter II fracture on the right side and subsequently developed an axis defect and mobility limitations during the course of the disease. These issues were likely related to the type of injury and delayed postoperative mobilization. Although the patient’s functional discomfort was not severe, it is important to recognize the potential for complications in the progression of these injuries, even with appropriate treatment.

In conclusion, bilateral distal femoral epiphyseal detachment is an uncommon injury. It typically occurs in young adults due to severe trauma and is associated with delayed closure of the growth plate. Although attentive treatment can result in recovery, considerable risk of functional complications exists.

ARTICLE INFORMATION

Author contributions

Conceptualization: AY; Data curation: MT, MY; Formal analysis: MT; Methodology: AY; Project administration: MA; Writing-

original draft: AY; Writing–review & editing: all authors. All authors read and approved the final manuscript.

Conflicts of interest

The authors have no conflicts of interest to declare.

Funding

The authors received no financial support for this study.

Data availability

Data sharing is not applicable as no new data were created or analyzed in this study.

REFERENCES

1. Mann DC, Rajmaira S. Distribution of physeal and nonphyseal fractures in 2,650 long-bone fractures in children aged 0-16 years. *J Pediatr Orthop* 1990;10:713–6.
2. Ponseller PD, Stanitski CL. Distal femoral epiphyseal fractures. In: Beaty JH, Kasser JR, editors. *Rockwood and Wilkins' fractures in children*. 5th ed. Lippincott Williams & Wilkins; 2001. p. 982–1010.
3. Young EY, Stans AA. Distal femoral physeal fractures. *J Knee Surg* 2018;31:486–9.
4. Peterson HA, Madhok R, Benson JT, Ilstrup DM, Melton LJ 3rd. Physeal fractures: part 1. Epidemiology in Olmsted County, Minnesota, 1979-1988. *J Pediatr Orthop* 1994;14:423–30.
5. Eid AM, Hafez MA. Traumatic injuries of the distal femoral physis: retrospective study on 151 cases. *Injury* 2002;33:251–5.
6. Gupta S, Kanojia R, Jaiman A, Sabat D. Scurvy: an unusual presentation of cerebral palsy. *World J Orthop* 2012;3:58–61.
7. Arkader A, Warner WC Jr, Horn BD, Shaw RN, Wells L. Predicting the outcome of physeal fractures of the distal femur. *J Pediatr Orthop* 2007;27:703–8.
8. Mehtani A, Prakash J, Chand S, Sinha A, Singh A, Dev H. Bilateral traumatic distal femoral physeal slips: a very rare case presentation. *Int J Case Rep Images* 2014;5:334–8.
9. Garrett BR, Hoffman EB, Carrara H. The effect of percutaneous pin fixation in the treatment of distal femoral physeal fractures. *J Bone Joint Surg Br* 2011;93:689–94.
10. Docquier PL. Fracture du genou de l'enfant. In: Banse X, Barbier O, Docquier PL, editors. *Orthopédie et traumatologie pratique*. Université catholique de Louvain; 2014.
11. Davis TP, Mehta R, Agrawal A. Bilateral traumatic distal femoral transphyseal fracture in a 9-year-old male. *J Surg Case Rep* 2021;2021:rjaa572.