



SPECIAL ARTICLE

Consensus on the treatment of vitiligo – Brazilian Society of Dermatology^{☆,☆☆}



Gerson Dellatorre ^a, Daniela Alves Pereira Antelo ^b,
Roberta Buense Bedrikow ^c, Tania Ferreira Cestari ^d, Ivonise Follador ^e,
Daniel Gontijo Ramos ^f, Caio Cesar Silva de Castro ^{g,*}

^a Department of Dermatology, Santa Casa de Misericórdia de Curitiba, Curitiba, PR, Brazil

^b Department of Dermatology, Universidade do Estado do Rio de Janeiro, Rio de Janeiro, RJ, Brazil

^c Department of Dermatology, Santa Casa de Misericórdia de São Paulo, São Paulo, SP, Brazil

^d Department of Dermatology, Hospital de Clínicas de Porto Alegre, Porto Alegre, RS, Brazil

^e Private Clinic, Salvador, BA, Brazil

^f Department of Dermatology, Santa Casa de Misericórdia de Belo Horizonte, Belo Horizonte, MG, Brazil

^g Department of Dermatology, Faculty of Medicine, Pontifícia Universidade Católica do Paraná, Curitiba, PR, Brazil

Received 2 March 2020; accepted 15 May 2020

Available online 10 October 2020

KEYWORDS

Clinical protocols;
Combined modality
therapy;
Consensus;
Treatment outcome;
Vitiligo

Abstract

Background: Vitiligo is a muco-cutaneous, autoimmune, localized, or disseminated disease, which manifests through hypochromic or achromic macules, with loss in quality of life. The prevalence of vitiligo in Brazil was determined to be 0.54%. There is no on-label medication for its treatment. To date, no Brazilian consensus on the treatment of vitiligo had been written.

Objectives: The objective of this group of Brazilian dermatologists with experience in the treatment of this disease was to reach a consensus on the clinical and surgical treatment of vitiligo, based on articles with the best scientific evidence.

Methods: Seven dermatologists were invited, and each was assigned two treatment modalities to review. Each treatment (topical, systemic, and phototherapy) was reviewed by three experts. Two experts reviewed the surgical treatment. Subsequently, the coordinator compiled the different versions and drafted a text about each type of treatment. The new version was returned to all experts, who expressed their opinions and made suggestions for clarity. The final text was written by the coordinator and sent to all participants to prepare the final consensus.

[☆] How to cite this article: Dellatorre G, Antelo DAP, Bedrikow RB, Cestari TF, Follador I, Ramos DG, et al. Consensus on the treatment of vitiligo – Brazilian Society of Dermatology. An Bras Dermatol. 2020;95(S1):70–82.

^{☆☆} Study conducted at the Brazilian Society of Dermatology, Rio de Janeiro, RJ, Brazil.

* Corresponding author.

E-mail: caio.castro@pucpr.br (C.C. Silva de Castro).

Results/Conclusion: The experts defined the following as standard treatments of vitiligo: the use of topical corticosteroids and calcineurin inhibitors for localized and unstable cases; corticosteroid minipulse in progressive generalized vitiligo; narrowband UVB phototherapy for extensive forms of the disease. Surgical modalities should be indicated for segmental and stable generalized vitiligo. Topical and systemic anti-JAK drugs are being tested, with promising results.

© 2020 Sociedade Brasileira de Dermatologia. Published by Elsevier España, S.L.U. This is an open access article under the CC BY license (<http://creativecommons.org/licenses/by/4.0/>).

Introduction

Vitiligo is a muco-cutaneous disease, triggered by autoimmunity against melanocytes, which is manifested by hypochromic or achromic macules and patches. Lesions can be localized or disseminated and have a very negative impact on quality of life. The disease can appear with one or a few macules grouped in a non-segmental way (focal vitiligo) or even reach the entire tegument (universal vitiligo).

Vitiligo is classified into two groups: non-segmental (NSV), which comprises the focal, mucosal, acrofacial, common, and universal types, and the segmental group, which includes only the segmental type. This type usually affects only one hemibody and, in most cases, presents a slower response to non-surgical treatment than the NSV type. In segmental vitiligo, autoimmunity against melanocytes is also present, but it is believed that an autoimmune attack occurs only against a certain area of cutaneous mosaicism.¹ Vitiligo can also be chemically induced, mainly by phenolic derivatives.²

The prevalence of vitiligo in Brazil was determined to be 0.54%; the mean age of onset of vitiligo in Brazilian patients for segmental and common types was determined to be 13 and 22 years old, respectively.^{3,4}

The genetic influence on the onset of vitiligo has already been well determined; a recent genetic study identified an increased polygenic load of risk alleles identified by genome-wide association studies (GWAS) in patients from families with multiplex cases (with family history) when compared with simplex patients (no family history).⁵ The lesions are caused by effector autoreactive CD8⁺ T lymphocytes in the initial phase, and in the stable phase they are determined by recirculating CD8⁺ T lymphocytes, both responsible for destroying melanocytes through the cytotoxic action of the released granzymes and perforin.⁶

According to the definition of the Vitiligo Global Consensus, analysis of vitiligo stability or instability should include a combination of history, series of photographs, and clinical scores such as VASI or VETF; vitiligo is considered stable if no new lesions, enlargement of old macules, Köbner phenomenon, or perifollicular (confetti) depigmentation is observed.^{7,8}

There are no specific treatments for vitiligo – for instance, no medication has been developed and approved specifically for its treatment by the United States Food and Drug Administration (FDA). This article, written by seven Brazilian dermatologists, aimed to reach a consensus on clinical and surgical treatment of vitiligo based on a review of

the literature with the best scientific evidence available to date.

Methods

Seven dermatologists were invited, and each was assigned two treatment modalities to review. Three experts individually reviewed the literature and wrote the guidelines for topical, systemic, and phototherapy treatment. Two experts reviewed the surgical modality. Subsequently, the coordinator compiled the different versions and drafted a text about each type of treatment. The new version was returned to all experts, who expressed their opinions and made suggestions for clarity. The final text was written by the coordinator and sent to all participants to prepare the final consensus.

Topical therapies

The goal of vitiligo treatment is to halt the progression of the disease, stimulate pigmentation, and finally, maintain repigmentation, thus circumventing the psychosocial impact caused by this dermatosis.

For small areas or when other alternatives are not available, the treatment of choice is topical. Topical treatment combined with phototherapy is indicated in therapeutic failure or when more than 5% to 10% of the body surface is affected.⁹

Although other clinical and surgical treatments are available, topical treatment with corticosteroids and calcineurin inhibitors has a prominent role in the therapeutic arsenal of vitiligo.

Topical corticosteroids

Topical corticosteroids in monotherapy are the first line in the treatment of localized unstable vitiligo, and can also be used in combination with phototherapy in generalized lesions. Recent and facial lesions present the best response.¹⁰

The mechanism of action of corticosteroids in vitiligo has not yet been fully elucidated, but an immunohistochemical study with mometasone in vitiligo induced by Köbner phenomenon observed a significant decrease in the infiltration of CD4⁺ and CD8⁺ T lymphocytes.¹¹

In 1988, a meta-analysis concluded that the use of class III and IV corticosteroids resulted in over 75% of repigmentation when compared with placebo.¹² Other studies have shown that 0.05% clobetasol propionate is especially effective on the face and neck.^{13,14}

A prospective, randomized study was conducted to estimate the safe dose of high-potency corticosteroids in vitiligo. The authors demonstrated that weekly use of 50 g (or less) of 0.05% clobetasol propionate cream for 12 weeks is safe, with no evidence of adrenal insufficiency, although local effects may occur.¹⁵ To minimize the risk of side effects, topical corticosteroids should be limited to small areas, avoiding prolonged use on the face and flexures.

It is recommended that, after eight weeks of continuous topical corticosteroid application, another topical therapy (rotational therapy) is introduced.^{12,16} In practice, these therapeutic schemes appear to minimize side effects, although evidence-based studies to confirm this information are still lacking.⁹ If no repigmentation is observed after three months of application, this treatment should be interrupted. Six of the present reviewers voted that their use is safer when quantified in grams; and one was in favor of the product being used on less than 10% of the body surface.

Calcineurin inhibitors

Calcineurin inhibitors have been shown to be effective and safe in the treatment of vitiligo in both children and adults, although their use is considered off-label by the Brazilian National Health Surveillance Agency (ANVISA). A recent meta-analysis comparing the use of calcineurin inhibitors vs. topical corticosteroids of medium or high potency showed that calcineurin inhibitors are not inferior to topical corticosteroids for the treatment of vitiligo, especially in children.¹⁷

Tacrolimus and pimecrolimus are the main calcineurin inhibiting agents. Tacrolimus is a macrolide product of the bacterium *Streptomyces tsukubaensis*, which has immunomodulatory properties and acts by selective inhibition of the intracellular protein calcineurin. It is not known exactly what is the mechanism of action of tacrolimus in vitiligo, but in an immunohistochemical study with 0.1% tacrolimus in vitiligo induced by the Köbner phenomenon, a significant decrease was observed in the infiltration of CD4⁺ and CD8⁺ T lymphocytes.¹¹

The effectiveness of calcineurin inhibitors in vitiligo has been verified in a series of publications since 2002.^{18,19} The best results are observed on the face and in photoexposed areas.^{20,21} The efficacy of tacrolimus was compared with that of 0.05% clobetasol, a high-potency corticosteroid.²² Although pimecrolimus has a more acceptable presentation (cream), the vast majority of the studies address tacrolimus.²³

In a prospective, controlled study, 0.1% tacrolimus ointment used twice per day for one year led to the repigmentation of facial lesions in 81% of patients; in turn, repigmentation was minimal on the limbs. Its advantage is that it is well tolerated by children and adults, and can be used for prolonged periods of time without the undesirable effects of corticosteroid therapy, such as atrophy and telangiectasis.²⁴

Calcineurin inhibitors can be prescribed twice per week as a maintenance therapy, after repigmentation of lesions treated with phototherapy.²⁵

There are two presentations of tacrolimus: 0.03% (ointment; approved for use in children between 2 and 15 years)

and 0.1%. In 2013, a European consensus proposed that calcineurin inhibitors applied twice daily should be the first choice to treat head and neck lesions.²⁶

Topical calcineurin inhibitors are safe for continuous use, for short or prolonged periods, or intermittently.¹⁶ Their side effects include burning, irritation, ardency, and pruritus, which tend to subside over time.

The FDA included a black box warning on the medication package as a preventive measure, based on the theoretical risk of lymphoma and non-melanoma skin cancer, based on studies in animal models and the use of a systemic calcineurin inhibitor.¹⁶ An analysis of data from more than 20,000 clinical trials has found that, to date, there is no evidence to suggest an increased risk of lymphoma or non-melanoma skin cancer in children or adults.^{16,27,28}

There is concern regarding the induction of skin cancer when combining the topical use of calcineurin inhibitors with phototherapy. However, Tran et al. showed that 0.1% tacrolimus and 1% pimecrolimus can prevent DNA photodamage in mice, by reducing the production of thymine dimers triggered by UVB radiation.²⁹ Among the present authors, there was no consensus on how long to use topical tacrolimus. Likewise, no consensus was reached regarding maximum body area, due to lack of sufficient data in the literature.

Other topics

Calcipotriol, pseudocatalase, and khellin were mentioned by some of the present authors, but no consensus was reached regarding the indication for its use.

No consensus was reached among the panelists regarding indication of depigmentation with monobenzyl ether of hydroquinone in very extensive vitiligo, for the following reasons: it is not a treatment for vitiligo, but for normal skin; it is not sold or approved in Brazil; and there is a potential non-reversibility of skin color after use. The experts also unanimously advised against the use of lasers or phenol peels for permanent depigmentation, which are controversial, due to the possible irreversibility of the clinical picture and the advance of new drugs that are about to be launched.

Three new topical medications from the Janus kinase inhibitor (anti-JAK) class are being tested: topical ruxolitinib, in Phase III, and two systemic drugs inhibiting the JAK3/TEC and TYK2/JAK1 pathways, in Phase II.

<https://clinicaltrials.gov/ct2/show/NCT04057573?cond=vitiligo&draw=3&rank=18>; <https://clinicaltrials.gov/ct2/show/NCT04052425?cond=vitiligo&draw=3&rank=19>; <https://clinicaltrials.gov/ct2/show/NCT04103060?cond=vitiligo&draw=4&rank=22>.

Systemic therapies

Corticosteroids

Oral corticosteroids have a broad immunosuppressive spectrum and aim to contain the progression of lesions in patients with active disease. The primary objective is, therefore, to stop the onset of new lesions and, secondarily, to induce repigmentation. The mode of action of corticosteroids in vitiligo has not yet been elucidated. A single article demon-

strated a decrease in serum ICAM1 after using oral minipulse therapy (OMP) for vitiligo.³⁰ Its systemic use, most often prescribed in minipulses, has been evaluated in some studies, most of them open.³¹

The most widely used form of systemic corticosteroid therapy is the administration of oral minipulses of corticosteroids, usually of betamethasone or dexamethasone, in supra-pharmacological doses and intermittently, in order to reduce the side effects associated with daily administration. Doses range from 2.5 to 10 mg dexamethasone for two consecutive days/week for three to six months. Betamethasone is usually prescribed in this same dosage schedule, in doses between 5 to 7.5 mg. In theory, any oral corticosteroids could be used, respecting the equivalence. The number of patients in whom an interruption in the progression of vitiligo was observed varies little between studies, from 88% to 91.8%. In three studies, the onset of some degree of repigmentation was observed in 28% to 100% of patients.³²⁻³⁴ Studies comparing treatment with OMP with daily use of corticosteroids observed a lower incidence of systemic and skin adverse effects in the former.¹⁶ The OMP regimen can be combined with phototherapy in patients with progressive vitiligo, although controlled studies with long-term follow-up are still required.^{35,36}

The side effects of using OMP are generally mild (described in 69% of patients in the study by Radakovic-Fijan et al.). The following were mentioned: weight gain, insomnia, acne, increased appetite, agitation, hypertrichosis, headache, and lethargy. However, despite the frequent occurrence of adverse effects, they do not usually compromise treatment adherence and do not suppress the production of endogenous cortisol.^{32,33}

A consensus was reached regarding the recommendation of the use of OMP, the most used being dexamethasone and betamethasone; daily use of oral corticosteroids was not contraindicated by the present authors. The most frequently mentioned reason for not preferring continuous use was the smaller number of studies when compared with OMP, primarily because there is no standard of total treatment duration and dose reduction scheme.

Methotrexate

It is indicated to stop the progression of vitiligo whenever oral corticosteroids are contraindicated or to avoid their long-term risks. Studies show results in terms of halting disease progression. The mode of action of methotrexate in vitiligo is not yet known.

In a randomized comparative study, methotrexate 10 mg/week was compared with OMP (2.5 mg dexamethasone/day on two consecutive days per week) in patients with progressive vitiligo ($n=52$ patients), for 24 weeks. In both groups, the same percentage of reduction in disease activity and in unresponsive patients was observed (6/25 patients in the MTX group and 7/25 in the dexamethasone OMP group). Most studies suggest low doses, around 10–15 mg/week.^{37,38}

The authors did not reach a consensus regarding the use of methotrexate, and do not recommend it, mainly due to the lack of a defined adequate dose, and the lack of studies with larger populations. Some of the experts suggest that

the use of methotrexate has some scientific basis and spares the use of oral corticosteroids.

Azathioprine

A single randomized study was conducted comparing the effect of azathioprine, 50 mg twice daily, with 5 mg betamethasone OMP on two consecutive days. In the second month of treatment, vitiligo was stabilized in 19 of 23 patients treated with OMP and in four of 22 treated with azathioprine.³⁹ None of the authors indicated the use of this medication.

Oral antioxidants

Oxidative stress and free radicals play an important role in the pathogenesis of vitiligo.⁴⁰

A systematic review with an attempt at meta-analysis found that the trials with antioxidants had a small number of patients and a wide variety of compounds and protocols, which hindered the comparison of the studies. Thus, the effectiveness of antioxidants alone cannot be confirmed. The best evidence was demonstrated in three studies with *Ginkgo biloba* as monotherapy, demonstrating clinical benefits or decreased inflammation.⁴⁰

The action of antioxidants associated with phototherapy was analyzed in a systematic review and meta-analysis of four studies (PUVA: 1 study and UVB-FE: 3 studies) involving 91 patients who met the inclusion criteria; in two studies, *Polypodium leucotomos* was used, and in another, *Ginkgo biloba*. The association was shown to be more effective than phototherapy alone (relative risk = 1.87; 95% confidence interval: 1.10–3.17). Sensitivity analysis revealed that the result was robust and not dependent on any individual study.⁴¹

The present panel of authors highlighted evidence of the use of antioxidants in vitiligo, mainly associated with phototherapy, but there was no consensus for the use of these medications, primarily due to the lack of prospective studies with larger populations.

Modalities of phototherapy and laser

Exposure to the sun, associated with the ingestion or topical application of plant extracts, has been used as a therapeutic agent for vitiligo for over 3000 years. Over the decades, the use of phototherapy has been consolidated through scientific studies, evidence-based medicine, and clarification of the mechanisms of action of ultraviolet radiation (UVR) on human beings.⁴²

Phototherapy promotes skin repigmentation through various mechanisms, including the differentiation and migration of melanocytes from the hair follicle and the formation and transfer of melanosomes to keratinocytes, in addition to its immunosuppressive effect.⁴³

The immunosuppressive effects of narrowband ultraviolet B radiation (NB-UVB) are already well characterized: apoptosis of T cells, downregulation of inflammatory cytokines, upregulation of interleukin 10 (IL10), and depletion of Langerhans cells, with reduced presentation of

antigens. There is also the stimulation of tyrosinase with increased melanin synthesis.⁴²

The most used forms of phototherapy for vitiligo include NB-UVB, excimer laser (ExLs), excimer lamp (ExLp), and ultraviolet A with administration of oral and topical psoralens (PUVA). Many of these modalities have shown better results when associated with systemic or topical treatments.

Phototherapy

Regarding the indication of phototherapy in relation to disease activity, most studies do not specify whether or not the disease is active, or whether or not it is stable; phototherapy is used in both forms.

In unstable vitiligo, in which lesions are progressing, it is recommended to combine phototherapy with systemic corticosteroid therapy, preferably in the form of OMP, as described in the specific part of systemic treatment, as well as the association with oral antioxidants.

Topical medications, such as calcineurin inhibitors (tacrolimus and pimecrolimus) and corticosteroids, can be used in conjunction with phototherapy. The results are variable. Some studies suggest that the association of these topical medications with phototherapy increases the response; however, other studies failed to confirm this action.⁴²⁻⁴⁶

Although the use of a light source and tacrolimus is contraindicated in the package insert, due to the evidence presented, the group agreed that tacrolimus can be used in conjunction with phototherapy, except immediately before irradiation.

In stable vitiligo, phototherapy acts on repigmentation and can also be associated with the aforementioned oral antioxidants and topical medications, with some studies suggesting a better response with their association.^{16,43,47}

As for the clinical form and location of the lesions, rapidly progressive vitiligo accompanied by early poliosis and SV tend to be unresponsive to phototherapy;⁴⁸ however, a recent study has shown that patients with recent SV respond better to phototherapy than those with long-term illness.⁴⁹ It is well established that generalized vitiligo (or NSV) responds better than SV.⁵⁰

The hairy areas, and especially the face and neck areas, show better response rates to phototherapy, followed by the trunk, limbs, hands and feet.⁵¹⁻⁵³ Likewise, patients with phototypes above III usually have a better prognosis with phototherapy.

Previous history of diseases influenced by light and photosensitivity are potential contraindications to phototherapy, as well as the use of medications at risk of photosensitization.⁵⁴ In addition, it is contraindicated in patients with a history of keratinocytic skin cancer and melanoma.

For the treatment of extensive, generalized vitiligo lesions, phototherapy with NB-UVB or PUVA in cabins is indicated. In localized vitiligo, it is recommended to use emitters of NB-UVB or local UVA, aimed only at the lesions. ExLs and ExLp are also recommended for this type of localized lesion.^{55,56}

In children, it is necessary to ensure that there is a correct indication for this therapeutic modality. The level of

evidence for the use of NB-UVB in children is 4, but there is no consensus on the age of onset of topical or cabin NB-UVB. Topical PUVA can be performed on children and, for oral PUVA use, the British Photodermatology Group has established two criteria: a broader criterion, that states that it should be used only in those above 10 years, and another criterion that states PUVA should be used in those above 16 years.⁵⁷⁻⁵⁹

Regarding pregnancy, there is no evidence of a decrease in serum folic acid after exposure to UVA. Studies in patients undergoing NB-UVB have shown different results, potentially explained by the dose-dependent degradation of folate. An accumulated exposure of >40 J/cm² and >2 J/cm² per treatment session was associated with a 19-27% decrease in serum folic acid levels, while lower doses did not affect these levels.⁶⁰ There is no evidence that PUVA is teratogenic, and it should be considered as a second option in phototherapy, due to the need to use psoralen.⁵⁹ This group reached the consensus that pregnant women can be treated with NB-UVB.⁶¹

Regarding the radiation modality, the role of phototherapy in the treatment of vitiligo has been well established in the last decades and, from the 1990s onwards, studies have been showing advantages of phototherapy with NB-UVB in relation to PUVA phototherapy.^{62,63} While some studies failed to demonstrate clinical superiority, they found similar responses and operational advantages.⁶⁴ Several studies have demonstrated greater effectiveness of NB-UVB compared to PUVA, in addition to its ease of use, without the need for psoralen, which has made phototherapy with NB-UVB the first choice for the treatment of vitiligo.⁵² The NB-UVB phototherapy protocols will not be detailed here and should be the subject of another specific consensus.

Excimer laser

ExLs is characterized by a wavelength of 308 nm (generated using xenon and chlorine gases). Several studies demonstrate its applicability for the treatment of vitiligo and it is considered to have a similar result to NB-UVB and, in some studies, even higher, with a faster response.^{65,66} Due to its smaller emission area, ExLs reaches smaller areas and regions more difficult to access with standard emitters. However, this form of treatment is inappropriate for patients with more extensive affected areas or for multiple regions. Furthermore, the cost is higher than that of other phototherapy devices.

Excimer lamp

The monochromatic excimer light (ExLp) also emits light with a wavelength of 308 nm, with good results in inducing repigmentation. These lamps have a larger treatment field than ExLs, making it possible to treat larger areas in a shorter time. In addition, its costs are much lower than laser devices.⁶⁷

Several studies have compared the therapeutic efficacy of ExLs, ExLp, and NB-UVB in vitiligo.⁶⁸⁻⁷⁰ Recent meta-analyses have shown that the excimer treatment is more effective than NB-UVB, with a faster effect and a higher

degree of repigmentation.^{71,72} However, other authors question this greater effectiveness.⁷²

As for photocarcinogenesis, the risk of developing skin cancers in patients with vitiligo in the affected areas is rare, regardless of the type of phototherapy.⁷³

In vitiligo, PUVA treatment does not appear to be associated with the risk of non-melanoma skin cancer.^{74,75} There are no consolidated studies on the risk of photocarcinogenesis in NB-UVB phototherapy for vitiligo.⁷³

There is no concrete evidence that NB-UVB presents a greater risk of malignancy in the genital areas; nonetheless, it is recommended that no exposure be made.⁷⁶

Treatments with ExLs or ExLp showed good results in lesions of the genital area, especially in men.⁵³ However, the group agreed that the genital area should not be exposed to phototherapy, due to the previously reported risk of squamous cell carcinomas in patients undergoing phototherapy without adequate protection.⁷⁷

As for the number of therapeutic sessions, a recent study identified patterns of response to treatment with NB-UVB. After 24 sessions, the mean global improvement was 21.5% (579 patients), and these were divided into response time patterns: after 96 sessions, very fast responders presented 88% repigmentation; fast responders, 74.8%; medium responders, 58.4%; slow responders, 38.8%; and non-responders, 35.2%.

The maximum number of sessions recommended for PUVA treatment is 200, but to date there is no global consensus on the maximum number of NB-UVB sessions.^{59,73} Likewise, the present authors did not reach a consensus on the maximum number of sessions for NB-UVB for vitiligo.

To assess the effectiveness of phototherapy, a period of at least six months (approximately 48 sessions) of treatment is required.⁵² In vitiligo, in order to obtain the maximum response with phototherapy, a long treatment time is recommended, of at least one year (on average 96 sessions).⁵²

In one year (approximately 96 sessions) of phototherapy, a better response is observed on the face and neck, followed by the trunk, whereas the limbs (hands and feet) show little repigmentation of the lesions.⁵²

In conclusion, phototherapy is an excellent therapeutic tool for the treatment of vitiligo, if the correct indications, periodic monitoring, protocols, and individualized management are adopted.

Surgical treatments

Surgical treatment of vitiligo is indicated for stable cases that are refractory to clinical treatments.^{78,79} Although there is a tendency for a better response in cases of SV, any stable clinical type of the disease can be treated, although specific areas (such as lips, glans, and distal phalanges) present a much lower response to these treatments.^{80,81} If the patient has more than 10% of compromised body surface, even in case of stable and late evolution, surgery is not recommended unless melanocyte culture is available. However, in specific localized cases with more than 10% of affected area, surgical techniques can be used in more than one step. Cases of long-lasting SV (more than 12 months) tend to have less response to clinical treatments.⁴⁹ There-

fore, in these cases, surgical treatment can be used as the first therapeutic option.⁹

Vitiligo stability is defined as the absence of new lesions or absence of an increase in old lesions; the indicators of disease instability are Köbner phenomenon, trichromic macules, and confetti depigmentation.⁸² Although there are no definitive parameters on the duration of disease stability required before a surgical approach, it is a consensus among most authors that the mean stability time is 12 months.^{83,84}

Stability can be confirmed by the patient, by photographic comparison or validated systems such as Vitiligo Area Scoring Index (VASI), Vitiligo European Task Force Assessment (VETF), and Vitiligo Disease Activity (VIDA).⁹ In cases of difficulty in defining stability, the mini-grafting test must be performed.^{78,85,86}

Patients should be evaluated for a history of keloids, coagulopathies, infections, or other contraindications for surgery.⁸⁷ Moreover, they need to be aware of the need for occlusive dressing in the treated area for a period ranging from seven to 14 days. These accelerate the healing of the dermabraded areas, prevent bacterial contamination, and maintain the transplanted tissues or cells in the recipient areas.⁸⁸

The choice of the surgical modality to be used depends on some parameters, such as the size of the lesion, the anatomical area to be treated, and the surgeon's experience.⁷⁸ Cell suspension techniques, although simplified in recent decades, demand a greater learning curve due to the delicate acquisition of tissue from the recipient area, laboratory handling of the tissue, and preparation of the recipient area.⁸⁹

Surgical modalities can be classified into tissue and cellular techniques, according to the type of graft to be transplanted. Among them, tissue melanocyte transplantation, mini-grafting, suction blister epidermal grafting, partial skin grafts, and epidermal curettage are noteworthy. In turn, cellular techniques include melanocyte-keratinocyte transplant procedure (MKTP), suspension of epidermal cells of the follicular external sheath, and suspension of cultured cells.^{79,90}

The therapeutic response to the aforementioned techniques ranges from good to excellent (50–100% repigmentation) in more than 65% of patients treated with a single procedure, varying according to the technique used, anatomical area treated (facial areas present better response than acral areas), time of stability, and type of vitiligo (SV responds better than focal, which in turn responds better than generalized).^{87,91–99} Furthermore, cellular modalities have the advantage of using a 1:10 ratio between donor area and recipient area, while tissue techniques usually demand a ratio of up to 1:1.^{9,79}

Tissue transplantation, such as mini-grafting, has the advantage of being easier, without the need for laboratory equipment, and faster, as long as the area to be treated is small. Modifications of the technique, using motorized punch devices, have allowed the use of this technique in larger areas.^{98,100} Cellular cell transplant modalities, such as MKTP have the advantage of treating larger areas using a reduced donor area, with a lower incidence of side effects than those observed in tissue techniques, making it one of the gold standard techniques for the surgical treatment of vitiligo.^{9,79,91}

In turn, techniques that involve the cultivation of melanocytes, in spite of their high efficacy, require a complex laboratory structure and a specialized team and, therefore, have a high cost.⁷⁹ Although there are no reports of post-transplant malignancy outcomes, there are theoretical questions about the long-term behavior of cultured melanocytes, and this technique should initially be reserved for experimental studies with the approval of a local ethics council until studies with long follow-up periods are carried out.¹⁰¹

Before the procedures, it is recommended to obtain a signed consent form from all patients, since surgical techniques can culminate in unwanted effects such as Köbner's phenomenon, unsightly scars (both in the recipient and donor areas), infections, and allergic reactions.^{78,93} Especially in the case of mini-grafting, the cobblestone appearance in the recipient area can occur in about 18–33% of treated patients (lower incidence when using smaller diameter grafts), in addition to an aspect of heterogeneous repigmentation in 24–43%.^{98,99} The patient must also be informed about the possibility of recurrence of the disease on the treated area. A long-term follow-up study of patients treated with the non cultured epidermal cell suspension technique demonstrated that finger and toe involvement in patients treated in other regions and NSV are independent risk factors for recurrence.¹⁰²

For the patient to have an accurate expectation, he/she must be well informed that repigmentation and color homogenization can take from two months to even more than a year to occur, and that surgery is a treatment and not a cure, as there is always the possibility of disease recurrence.⁸⁰

There is evidence that the association of surgical transplantation techniques with adjuvant phototherapy provides better rates of repigmentation, which can be further improved when phototherapy is started before surgical treatment and continued after melanocyte transplantation.^{103,104}

Other repigmentation-inducing techniques

The number of studies (trials and case reports) involving repigmentation-inducing techniques (RIT) without melanocyte transplantation is increasing, with no direct comparative studies between the two modalities to date.

Among RIT, microneedling stands out. The studies already published present a highly variable response rate (0–100%), many of them pointing to a lower response or even failure of response in acral areas, which can be explained by the lack of a follicular reservoir of melanocytes in these anatomical areas.^{105–117}

Nonetheless, the technique is still considered incipient, albeit promising, similarly to the use of substances for drug delivery; therefore, it is prudent to await studies with a larger number of patients before its broad indication. It is important to note that, although the modality does not involve melanocyte transplantation, the same indication criteria adopted for the other surgical treatment modalities of vitiligo need to be respected, in order to avoid possible adverse effects.

Treatment in children, pregnant women, nursing mothers, and the elderly

Phototherapy

In the pediatric age group and in pregnant women, phototherapy with NB-UVB is preferable to PUVA therapy due to its greater effectiveness, lower incidence of side effects (no need for photosensitizing medication – risk category C in pregnancy), and lower chance of carcinogenesis.¹¹⁸ The decision to initiate phototherapy in children is based on little or no response to topical treatments, rapid progression of the disease, and the understanding of the patient to accept and collaborate with the treatment. This usually occurs at around 7–10 years of age. As far as possible, localized irradiation devices should be tried to avoid extensive and delayed damage.¹¹⁹

To date, studies with NB-UVB have not shown an increase in carcinogenesis in children with vitiligo, suggesting that its use may be safe from school age on.^{120–125} Regarding vitiligo and carcinogenesis, most studies show an inverse relationship between the disease and skin cancer, probably due to protective genetic and immunological mechanisms.¹²⁶ However, due to the absence of long-term prospective studies to certify the real safety of phototherapy in children, a long-term dermatological follow-up in treated patients and restriction of phototherapy to the treatment area, avoiding genital areas, is suggested.^{121,126}

It is also recommended that patients undergoing treatment or already treated reduce the environmental exposure to ultraviolet as much as possible and undergo regular examination of the entire tegument.¹²¹

As in adults, phototherapy combined with the topical use of calcineurin inhibitors can be indicated.¹²⁷ However, the possible carcinogenic potential of this association must be taken into account. Although analyses of clinical data have not proven this possibility, combined use should be assessed with caution in children.

No specific studies in the elderly were retrieved.

Oral corticosteroids

In children, the most common side effects of using oral corticosteroid therapy are vomiting, behavioral changes, and sleep disorders.¹²⁸ The use of oral corticosteroids is also linked to an increased incidence of fractures both in the pediatric age group and in elderly patients.^{129,130} Therefore, its use must be moderate and avoided in patients with moderate to high risk for fractures.

The literature review retrieved only one study of OMP prednisolone in children, a prospective and interventional study of 400 participants (children aged 18 months to 15 years), using two consecutive days of methylprednisolone for six months every week. In addition, patients used fluticasone cream once a day on the lesions. A response considered good to excellent was observed in 65.5% of the 343 patients who completed the study. There was an inverse correlation between disease duration and response to treatment.¹³¹

Although conflicting, some studies in pregnant women who used oral corticotherapy point to an increase in the incidence of cleft lip, preterm births, pre-eclampsia,

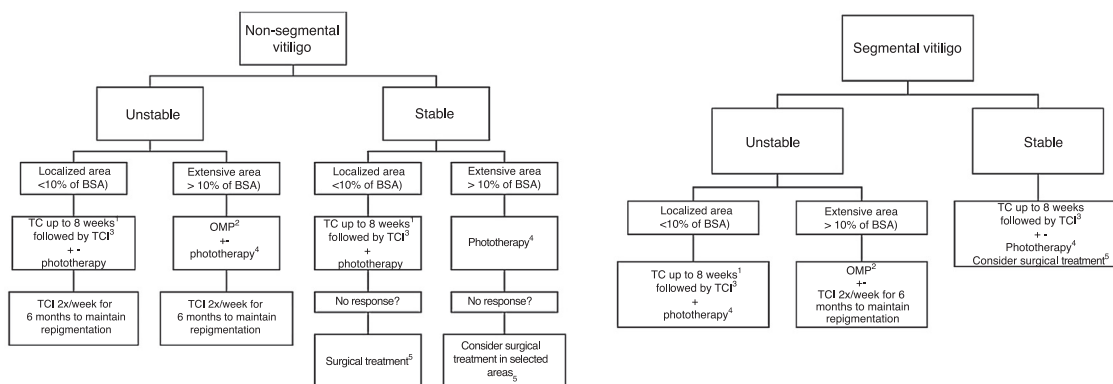


Figure 1 Flowchart of treatment.

BSA, Body Surface Area; TC, Topical corticoid; TCI, Topical Calcineurin Inhibitor (Tacrolimus or Pimecrolimus); OMP, Oral Corticoid Mini-pulse.

+-, Associated or not to.

¹ With clinical monitoring to evaluate local side effects, especially if in genital, facial or skinfold areas. Most reviewers agree that, if the use of TC is necessary, preference should be given to those with low and medium potency in genital, skinfold and facial areas. The use of high and very-high potency corticosteroids should be restricted to the other body areas. Also, in sensitive areas, the use of TCI can be prioritized to minimize the side effects of topical corticosteroids.

² In children and the elderly, evaluate the risk-benefit of using oral corticosteroid therapy, mainly due to the association between its use and growth deficit and increased fracture risk, in addition to comorbidities that can be triggered or aggravated by the medication use.

³ Tacrolimus (or Pimecrolimus) 2×/day.

⁴ Preferably NB-UVB, Excimer laser or Excimer light. Due to slow responders, a treatment lasting at least six months (2 to 3 weekly sessions) is suggested. In localized cases, give preference to phototherapy treatment that allows irradiation restricted to the lesion area. The association with oral anti-oxidants, TCI and TC during treatment can be considered. It was a consensus among the reviewers that the genital area should not be irradiated.

⁵ In the absence of Köbner phenomenon.

and low birth weight, being considered a risk category C medication.¹³² Therefore, its use should be avoided in the pregnant population.

In the only retrospective study detailing the treatment of late-onset vitiligo (above 50 years of age), 15.6% of the 359 patients were treated with oral corticosteroids.¹³³ That study cannot be extrapolated to the elderly age group, because many treated patients did not fit this age group.

Topical treatment

The choice of topical medication in children should take into account the anatomical area of application and extent of the disease, and should be avoided to a great extent, due to the possibility of systemic side effects.^{134,135} On the face, neck, and intertriginous areas, topical use of calcineurin inhibitors should be preferred (twice daily), due to their effectiveness and better safety profile.^{134,136}

According to the package insert, in Brazil, topical calcineurin inhibitors are indicated for children older than 2 years of age. However, these medications (tacrolimus 0.03% and pimecrolimus 1%) have already been studied in the age group of 6 to 24 months in patients with vitiligo, demonstrating efficacy and tolerability.¹³⁷

Topical medium- and high-potency corticosteroids are the first line therapy for pediatric vitiligo on the body, except for intertriginous and genital sites. Children, in particular those with a high phototype and facial lesions, respond better than older individuals with lower phototypes. They are

usually prescribed intermittently, with intervals of every two or three weeks, for a maximum of six months.¹³⁸ A retrospective study that included 101 children with vitiligo treated with moderate to high potency steroids reported lesion repigmentation in 64% of the sample.

Due to its already known adverse local and systemic side effects, in the body region (extra-facial, extra-cervical, and extra-intertriginous) the recommendation is for the use of low- and moderate-potency corticosteroids, or newer high-potency corticosteroids (class III), such as mometasone furoate and methylprednisolone aceponate, which have similar efficacy and less common side effects than clobetasol propionate, for example.¹³⁴

Systemic absorption is possible, especially in younger children, with the potential to suppress the hypothalamic-pituitary-adrenal axis and consequent iatrogenic Cushing's syndrome.¹³⁹ High-potency topical corticosteroids produce better results in pediatric patients with head and neck lesions, but are not necessarily better than tacrolimus.¹⁴⁰ Treatment plans that alternate periods of use with periods of pause (e.g., one week of use and one week of pause, or 15 days of treatment per month for six months) and that include monthly clinical follow-up to check for local side effects can be instituted. While in practice these treatment regimens reduce side effects, there are no comparative studies assessing their effectiveness.^{134,135}

The use of high and very high doses of topical corticosteroids during pregnancy has been linked to a higher incidence of low birth weight infants, especially in accu-

mulated doses of 300 g or more.¹⁴¹ Therefore, a prudent use (reduced time and area of treatment) of topical corticosteroids of mild to moderate potency would be more indicated in this population, as well as in lactating women.¹⁴²

There are no specific studies on the safety of using topical calcineurin inhibitors in pregnant and lactating women (Category C). However, the use of oral tacrolimus and even oral cyclosporine has already been studied in pregnant women who received solid organ transplants, showing no increased risk for congenital malformations. The risk of increased prematurity in these studies was possibly related to maternal-based disease.^{143,144}

Studies on the pharmacokinetics of topical tacrolimus in patients with atopic dermatitis (with greater permeability in the skin barrier than patients with vitiligo) have shown minimal systemic absorption of topical medication.^{145,146} Therefore, the off-label use of this medication can be suggested in pregnant or lactating vitiligo patients, but as a second line of treatment.

Retrospective studies, including one carried out in a Brazilian population, indicate a trend toward the stability of vitiligo during pregnancy in the majority of patients evaluated.^{147,148}

In a retrospective study involving 359 patients with late onset of the disease (>50 years), only 30.5% of those treated with topical monotherapy (corticosteroids or calcineurin inhibitors) achieved good repigmentation results (repigmentation>50%), while the majority (55.4%) of those treated with phototherapy associated with topical medication achieved good to excellent therapeutic results.¹⁴⁹ Thus, the present consensus recommends the latter combination therapy as a form of treatment for the elderly.

Discussion and Conclusion

The consulted experts defined as the standard treatment of vitiligo the use of corticosteroids and calcineurin inhibitors for unstable and localized cases, and corticosteroid OMP for unstable generalized vitiligo. The treatment of choice for repigmentation is NB-UVB phototherapy, which may or may not be associated with OMP and/or oral antioxidants in severe and unstable cases. Surgical modalities are used mainly in stable SV and generalized vitiligo, primarily associated with exposure to phototherapy before and after surgical treatment. To date, there are no specific topical or systemic drugs for vitiligo, but the main drugs being developed are topical and systemic anti-JAKs, which are between Phase II and III; trials with anti-IL-15 receptor immunobiologics are planned. Fig. 1 presents a treatment flowchart.

Financial support

None declared.

Authors' contributions

Gerson Dellatorre: Approval of the final version of the manuscript; design and planning of the study; elaboration and writing of the manuscript; collection, analysis, and

interpretation of data; effective participation in research orientation; critical review of the literature; critical review of the manuscript.

Daniela Alves Pereira Antelo: Approval of the final version of the manuscript; design and planning of the study; elaboration and writing of the manuscript, collection, analysis, and interpretation of data; effective participation in research orientation; critical review of the literature; critical review of the manuscript.

Roberta Buense Bedrikow: Approval of the final version of the manuscript; design and planning of the study; elaboration and writing of the manuscript; collection, analysis, and interpretation of data; effective participation in research orientation; critical review of the literature; critical review of the manuscript.

Tania Ferreira Cestari: Approval of the final version of the manuscript; design and planning of the study; elaboration and writing of the manuscript; collection, analysis, and interpretation of data; effective participation in research orientation; critical review of the literature; critical review of the manuscript.

Ivoniise Follador: Approval of the final version of the manuscript; design and planning of the study; elaboration and writing of the manuscript; collection, analysis, and interpretation of data; effective participation in research orientation; critical review of the literature; critical review of the manuscript.

Daniel Gontijo Ramos: Approval of the final version of the manuscript; design and planning of the study; elaboration and writing of the manuscript; collection, analysis, and interpretation of data; effective participation in research orientation; critical review of the literature; critical review of the manuscript.

Caio Cesar Silva de Castro: Approval of the final version of the manuscript; design and planning of the study; elaboration and writing of the manuscript; collection, analysis, and interpretation of data; effective participation in research orientation; critical review of the literature; critical review of the manuscript.

Conflicts of interest

None declared.

References

1. Taieb A, Morice-Picard F, Jouary T, Ezzedine K, Cario-Andre M, Gauthier Y. Segmental vitiligo as the possible expression of cutaneous somatic mosaicism: implications for common non-segmental vitiligo. *Pigment Cell Melanoma Res.* 2008;21:646–52.
2. Harris JE. Chemical-induced vitiligo. *Dermatol Clin.* 2017;35:151–61.
3. Cesar Silva de Castro C, Miot HA. Prevalence of vitiligo in Brazil – a population survey. *Pigment Cell Melanoma Res.* 2018;31:448–50.
4. Silva de Castro CC, do Nascimento LM, Olandoski M, Mira MT. A pattern of association between clinical form of vitiligo and disease-related variables in a Brazilian population. *J Dermatol Sci.* 2012;65:63–7.

5. Roberts GHL, Paul S, Yorgov D, Santorico SA, Spritz RA. Family clustering of autoimmune vitiligo results principally from polygenic inheritance of common risk alleles. *Am J Hum Genet.* 2019;105:364–72.
6. Riding RL, Harris JE. The role of memory CD8(+) T cells in vitiligo. *J Immunol.* 2019;203:11–9.
7. Ezzedine K, Lim HW, Suzuki T, Katayama I, Hamzavi I, Lan CC, et al. Revised classification/nomenclature of vitiligo and related issues: the vitiligo global issues consensus conference. *Pigment Cell Melanoma Res.* 2012;25:E1–13.
8. Zhang L, Chen S, Kang Y, Wang X, Yan F, Jiang M, et al. Association of clinical markers with disease progression in patients with vitiligo from China. *JAMA Dermatol.* 2020;156:288–95.
9. Vitiligo Working Group/Rodrigues M, Ezzedine K, Hamzavi I, Pandya AG, Harris JE. Current and emerging treatments for vitiligo. *J Am Acad Dermatol.* 2017;77:17–29.
10. Speeckaert R, van Geel N. Vitiligo: an update on pathophysiology and treatment options. *Am J Clin Dermatol.* 2017;18:733–44.
11. van Geel N, Speeckaert R, Mollet I, De Schepper S, De Wolf J, Tjin EP, et al. In vivo vitiligo induction and therapy model: double-blind, randomized clinical trial. *Pigment Cell Melanoma Res.* 2012;25:57–65.
12. Njoo MD, Spuls PI, Bos JD, Westerhof W, Bossuyt PM. Nonsurgical repigmentation therapies in vitiligo. Meta-analysis of the literature. *Arch Dermatol.* 1998;134:1532–40.
13. Falabella R, Barona MI. Update on skin repigmentation therapies in vitiligo. *Pigment Cell Melanoma Res.* 2009;22:42–65.
14. Kumari J. Vitiligo treated with topical clobetasol propionate. *Arch Dermatol.* 1984;120:631–5.
15. de la Fuente-Garcia A, Gomez-Flores M, Mancillas-Adame L, Ocampo-Candiani J, Welsh-Lozano O, Perez JZ, et al. Role of the ACTH test and estimation of a safe dose for high potency steroids in vitiligo: a prospective randomized study. *Indian Dermatol Online J.* 2014;5:117–21.
16. Felsten LM, Alikhan A, Petronic-Rosic V. Vitiligo: a comprehensive overview Part II: treatment options and approach to treatment. *J Am Acad Dermatol.* 2011;65:493–514.
17. Chang HC, Hsu YP, Huang YC. The effectiveness of topical calcineurin inhibitors compared with topical corticosteroids in the treatment of vitiligo: a systematic review and meta-analysis. *J Am Acad Dermatol.* 2020;82:243–5.
18. Grimes PE, Soriano T, Dytoc MT. Topical tacrolimus for repigmentation of vitiligo. *J Am Acad Dermatol.* 2002;47:789–91.
19. Smith DA, Tofte SJ, Hanifin JM. Repigmentation of vitiligo with topical tacrolimus. *Dermatology.* 2002;205:301–3.
20. Silverberg NB, Lin P, Travis L, Farley-Li J, Mancini AJ, Wagner AM, et al. Tacrolimus ointment promotes repigmentation of vitiligo in children: a review of 57 cases. *J Am Acad Dermatol.* 2004;51:760–6.
21. Travis LB, Weinberg JM, Silverberg NB. Successful treatment of vitiligo with 0.1% tacrolimus ointment. *Arch Dermatol.* 2003;139:571–4 [discussion 573].
22. Lepe V, Moncada B, Castanedo-Cazares JP, Torres-Alvarez MB, Ortiz CA, Torres-Rubalcava AB. A double-blind randomized trial of 0.1% tacrolimus vs 0.05% clobetasol for the treatment of childhood vitiligo. *Arch Dermatol.* 2003;139:581–5.
23. Mayoral FA, Gonzalez C, Shah NS, Arciniegas C. Repigmentation of vitiligo with pimecrolimus cream: a case report. *Dermatology.* 2003;207:322–3.
24. Kanwar AJ, Dogra S, Parsad D. Topical tacrolimus for treatment of childhood vitiligo in Asians. *Clin Exp Dermatol.* 2004;29:589–92.
25. Cavalie M, Ezzedine K, Fontas E, Montaudie H, Castela E, Bahadoran P, et al. Maintenance therapy of adult vitiligo with 0.1% tacrolimus ointment: a randomized, double blind, placebo-controlled study. *J Invest Dermatol.* 2015;135:970–4.
26. Taieb A, Alomar A, Bohm M, Dell’anna ML, De Pase A, Eleftheriadou V, et al. Guidelines for the management of vitiligo: the European Dermatology Forum consensus. *Br J Dermatol.* 2013;16:5–19.
27. Esfandiarpour I, Ekhlesi A, Farajzadeh S, Shamsadini S. The efficacy of pimecrolimus 1% cream plus narrow-band ultraviolet B in the treatment of vitiligo: a double-blind, placebo-controlled clinical trial. *J Dermatolog Treat.* 2009;20:14–8.
28. McCollum AD, Paik A, Eichenfield LF. The safety and efficacy of tacrolimus ointment in pediatric patients with atopic dermatitis. *Pediatr Dermatol.* 2010;27:425–36.
29. Tran C, Lubbe J, Sorg O, Doelker L, Carraux P, Antille C, et al. Topical calcineurin inhibitors decrease the production of UVB-induced thymine dimers from hairless mouse epidermis. *Dermatology.* 2005;211:341–7.
30. El Mofty M, Essmat S, Youssef R, Sobeih S, Mahgoub D, Ossama S, et al. The role of systemic steroids and phototherapy in the treatment of stable vitiligo: a randomized controlled trial. *Dermatol Ther.* 2016;29:406–12.
31. Boniface K, Seneschal J, Picardo M, Taieb A. Vitiligo: focus on clinical aspects, immunopathogenesis, and therapy. *Clin Rev Allergy Immunol.* 2018;54:52–67.
32. Pasricha JS, Khaitan BK. Oral mini-pulse therapy with betamethasone in vitiligo patients having extensive or fast-spreading disease. *Int J Dermatol.* 1993;32:753–7.
33. Radakovic-Fijan S, Furnsinn-Friedl AM, Honigsmann H, Tanew A. Oral dexamethasone pulse treatment for vitiligo. *J Am Acad Dermatol.* 2001;44:814–7.
34. Kanwar AJ, Mahajan R, Parsad D. Low-dose oral mini-pulse dexamethasone therapy in progressive unstable vitiligo. *J Cutan Med Surg.* 2013;17:259–68.
35. Lee J, Chu H, Lee H, Kim M, Kim DS, Oh SH. A retrospective study of methylprednisolone mini-pulse therapy combined with narrow-band UVB in non-segmental vitiligo. *Dermatology.* 2016;232:224–9.
36. Rath N, Kar HK, Sabhnani S. An open labeled, comparative clinical study on efficacy and tolerability of oral minipulse of steroid (OMP) alone, OMP with PUVA and broad/narrow band UVB phototherapy in progressive vitiligo. *Indian J Dermatol Venereol Leprol.* 2008;74:357–60.
37. Garza-Mayers AC, Kroshinsky D. Low-dose methotrexate for vitiligo. *J Drugs Dermatol.* 2017;16:705–6.
38. Abdelmaksoud A. Methotrexate for treatment of vitiligo. *Dermatol Ther.* 2017;30.
39. Patra S, Khaitan BK, Sharma VK, Khanna N. A randomized comparative study of the effect of betamethasone oral mini-pulse therapy versus oral azathioprine in progressive non-segmental vitiligo. *J Am Acad Dermatol.* 2019. S0190-9622(19)30439-6.
40. Speeckaert R, Dugardin J, Lambert J, Lapeere H, Verhaeghe E, Speeckaert MM, et al. Critical appraisal of the oxidative stress pathway in vitiligo: a systematic review and meta-analysis. *J Eur Acad Dermatol Venereol.* 2018;32:1089–98.
41. Jung HM, Jung YS, Lee JH, Kim GM, Bae JM. Antioxidant supplements in combination with phototherapy for vitiligo: a systematic review and meta-analysis of randomized controlled trials. *J Am Acad Dermatol.* 2018. S0190-9622(18)32739-7.
42. Zubair R, Hamzavi IH. Phototherapy for vitiligo. *Dermatol Clin.* 2020;38:55–62.
43. Bleuel R, Eberlein B. Therapeutic management of vitiligo. *J Dtsch Dermatol Ges.* 2018;16:1309–13.
44. Passeron T, Ostovari N, Zakaria W, Fontas E, Larrouy JC, Lacour JP, et al. Topical tacrolimus and the 308-nm excimer laser: a synergistic combination for the treatment of vitiligo. *Arch Dermatol.* 2004;140:1065–9.

45. Kawalek AZ, Spencer JM, Phelps RG. Combined excimer laser and topical tacrolimus for the treatment of vitiligo: a pilot study. *Dermatol Surg.* 2004;30 Pt 1:130–5.
46. Li R, Qiao M, Wang X, Zhao X, Sun Q. Effect of narrow band ultraviolet B phototherapy as monotherapy or combination therapy for vitiligo: a meta-analysis. *Photodermatol Photoimmunol Photomed.* 2017;33:22–31.
47. Daniel BS, Wittal R. Vitiligo treatment update. *Australas J Dermatol.* 2015;56:85–92.
48. Taieb A, Picardo M. Clinical practice. Vitiligo. *N Engl J Med.* 2009;360:160–9.
49. Park JH, Park SW, Lee DY, Lee JH, Yang JM. The effectiveness of early treatment in segmental vitiligo: retrospective study according to disease duration. *Photodermatol Photoimmunol Photomed.* 2013;29:103–5.
50. Anbar TS, Westerhof W, Abdel-Rahman AT, El-Khayyat MA. Evaluation of the effects of NB-UVB in both segmental and non-segmental vitiligo affecting different body sites. *Photodermatol Photoimmunol Photomed.* 2006;22:157–63.
51. Cui J, Shen LY, Wang GC. Role of hair follicles in the repigmentation of vitiligo. *J Invest Dermatol.* 1991;97:410–6.
52. Bae JM, Jung HM, Hong BY, Lee JH, Choi WJ, Lee JH, et al. Phototherapy for vitiligo: a systematic review and meta-analysis. *JAMA Dermatol.* 2017;153:666–74.
53. Khanna U, Khandpur S. What is new in narrow-band ultraviolet-B therapy for vitiligo? *Indian Dermatol Online J.* 2019;10:234–43.
54. Chen YT, Chen YJ, Hwang CY, Lin MW, Chen TJ, Chen CC, et al. Comorbidity profiles in association with vitiligo: a nationwide population-based study in Taiwan. *J Eur Acad Dermatol Venereol.* 2015;29:1362–9.
55. Welsh O, Herz-Ruelas ME, Gomez M, Ocampo-Candiani J. Therapeutic evaluation of UVB-targeted phototherapy in vitiligo that affects less than 10% of the body surface area. *Int J Dermatol.* 2009;48:529–34.
56. Lotti T, Prignano F, Buggiani G. New and experimental treatments of vitiligo and other hypomelanoses. *Dermatol Clin.* 2007;25:393–400.
57. Sokolova A, Lee A, Smith DS. The safety and efficacy of narrow band ultraviolet B treatment in dermatology: a review. *Am J Clin Dermatol.* 2015;16:501–31.
58. Halpern SM, Anstey AV, Dawe RS, Diffey BL, Farr PM, Ferguson J, et al. Guidelines for topical PUVA: a report of a workshop of the British photodermatology group. *Br J Dermatol.* 2000;142:22–31.
59. British Photodermatology Group guidelines for PUVA. *Br J Dermatol.* 1994;130:246–55.
60. Zhang M, Goyert G, Lim HW. Folate and phototherapy: what should we inform our patients? *J Am Acad Dermatol.* 2017;77:958–64.
61. Stern RS, Lange R. Outcomes of pregnancies among women and partners of men with a history of exposure to methoxsalen photochemotherapy (PUVA) for the treatment of psoriasis. *Arch Dermatol.* 1991;127:347–50.
62. Yones SS, Palmer RA, Garibaldinos TM, Hawk JL. Randomized double-blind trial of treatment of vitiligo: efficacy of psoralen-UV-A therapy vs Narrowband-UV-B therapy. *Arch Dermatol.* 2007;143:578–84.
63. Bhatnagar A, Kanwar AJ, Parsad D, De D. Comparison of systemic PUVA and NB-UVB in the treatment of vitiligo: an open prospective study. *J Eur Acad Dermatol Venereol.* 2007;21:638–42.
64. El Mofty M, Mostafa W, Esmat S, Youssef R, Azzam O, Hunter N, et al. Narrow band Ultraviolet B 311 nm in the treatment of vitiligo: two right-left comparison studies. *Photodermatol Photoimmunol Photomed.* 2006;22:6–11.
65. Passeron T, Ortonne JP. Use of the 308-nm excimer laser for psoriasis and vitiligo. *Clin Dermatol.* 2006;24:33–42.
66. Nicolaidou E, Antoniou C, Stratigos A, Katsambas AD. Narrow-band ultraviolet B phototherapy and 308-nm excimer laser in the treatment of vitiligo: a review. *J Am Acad Dermatol.* 2009;60:470–7.
67. Park KK, Liao W, Murase JE. A review of monochromatic excimer light in vitiligo. *Br J Dermatol.* 2012;167:468–78.
68. Hong SB, Park HH, Lee MH. Short-term effects of 308-nm xenon-chloride excimer laser and narrow-band ultraviolet B in the treatment of vitiligo: a comparative study. *J Korean Med Sci.* 2005;20:273–8.
69. Casacci M, Thomas P, Pacifico A, Bonneville A, Paro Vidolin A, Leone G. Comparison between 308-nm monochromatic excimer light and narrowband UVB phototherapy (311–313 nm) in the treatment of vitiligo – a multicentre controlled study. *J Eur Acad Dermatol Venereol.* 2007;21:956–63.
70. Le Duff F, Fontas E, Giaccherio D, Sillard L, Lacour JP, Ortonne JP, et al. 308-nm excimer lamp vs. 308-nm excimer laser for treating vitiligo: a randomized study. *Br J Dermatol.* 2010;163:188–92.
71. Sun Y, Wu Y, Xiao B, Li L, Chen HD, et al. Treatment of 308-nm excimer laser on vitiligo: a systemic review of randomized controlled trials. *J Dermatolog Treat.* 2015;26:347–53.
72. Lopes C, Trevisani VF, Melnik T. Efficacy and safety of 308-nm monochromatic excimer lamp versus other phototherapy devices for vitiligo: a systematic review with meta-analysis. *Am J Clin Dermatol.* 2016;17:23–32.
73. Rodrigues M. Skin cancer risk (nonmelanoma skin cancers/melanoma) in vitiligo patients. *Dermatol Clin.* 2017;35:129–34.
74. Harrist TJ, Pathak MA, Mosher DB, Fitzpatrick TB. Chronic cutaneous effects of long-term psoralen and ultraviolet radiation therapy in patients with vitiligo. *Natl Cancer Inst Monogr.* 1984;66:191–6.
75. Wildfang IL, Jacobsen FK, Thestrup-Pedersen K. PUVA treatment of vitiligo: a retrospective study of 59 patients. *Acta Derm Venereol.* 1992;72:305–6.
76. Mohammad TF, Al-Jamal M, Hamzavi IH, Harris JE, Leone G, Cabrera R, et al. The Vitiligo Working Group recommendations for narrowband ultraviolet B light phototherapy treatment of vitiligo. *J Am Acad Dermatol.* 2017;76:879–88.
77. Stern RS, Bagheri S, Nichols K, Study PFU. The persistent risk of genital tumors among men treated with psoralen plus ultraviolet A (PUVA) for psoriasis. *J Am Acad Dermatol.* 2002;47:33–9.
78. IADVL Dermatosurgery Task ForceParsad D, Gupta S. Standard guidelines of care for vitiligo surgery. *Indian J Dermatol Venereol Leprol.* 2008;74 Suppl:537–45.
79. Gupta S, Olsson MJ, Kanwar AJ, Ortonne J. Surgical management of vitiligo. Oxford, UK: Blackwell Publishing Ltd; 2006.
80. Silpa-Archa N, Griffith JL, Huggins RH, Henderson MD, Kerr HA, Jacobsen G, et al. Long-term follow-up of patients undergoing autologous noncultured melanocyte-keratinocyte transplantation for vitiligo and other leukodermas. *J Am Acad Dermatol.* 2017;77:318–27.
81. Van Geel N, Wallaey E, Goh BK, De Mil M, Lambert J. Long-term results of noncultured epidermal cellular grafting in vitiligo, halo naevi, piebaldism and naevus depigmentosus. *Br J Dermatol.* 2010;163:1186–93.
82. Aboul-Fettouh N, Hinojosa J, Tovar-Garza A, Pandya AG. The majority of patients presenting with vitiligo have a clinical sign of activity. *J Am Acad Dermatol.* 2017;77:774–5.
83. Parsad D, Sahni K. Stability in vitiligo: is there a perfect way to predict it? *J Cutan Aesthet Surg.* 2013;6:75–82.
84. Ezzedine K, Lim HW, Suzuki T, Katayama I, Hamzavi I, Lan CCE, et al. Revised classification/nomenclature of vitiligo and related issues: the Vitiligo Global Issues Consensus Conference. *Pigment Cell Melanoma Res.* 2012;25:E1–13.
85. Falabella R. The minigrafting test for vitiligo: validation of a predicting tool. *J Am Acad Dermatol.* 2004;51:672–3.

86. Falabella R, Arrunategui A, Barona MI, Alzate A. The minigrafting test for vitiligo: detection of stable lesions for melanocyte transplantation. *J Am Acad Dermatol.* 1995;32 Pt 1:228–32.
87. Mulekar SV, Isedeh P. Surgical interventions for vitiligo: an evidence-based review. *Br J Dermatol.* 2013;169 Suppl 3:57–66.
88. Al-Hadidi N, Griffith JL, Al-Jamal MS, Hamzavi I. Role of recipient-site preparation techniques and post-operative wound dressing in the surgical management of vitiligo. *J Cutan Aesthet Surg.* 2015;8:79–87.
89. Gauthier Y, Benzekri L. Non-cultured epidermal suspension in vitiligo: from laboratory to clinic. *Indian J Dermatol Venereol Leprol.* 2012;78:59–63.
90. Dellatorre G, Cafrune FE. Vitiligo surgical treatment. *Surg Cosmet Dermatol.* 2016;8:289–94.
91. Mulekar SV. Melanocyte-keratinocyte cell transplantation for stable vitiligo. *Int J Dermatol.* 2003;42:132–6.
92. Huggins RH, Henderson MD, Mulekar SV, Ozog DM, Kerr HA, Jabobsen G, et al. Melanocyte-keratinocyte transplantation procedure in the treatment of vitiligo: the experience of an academic medical center in the United States. *J Am Acad Dermatol.* 2012;66:785–93.
93. Ashique KT, Kaliyadan F. Long-term follow-up and donor site changes evaluation in suction blister epidermal grafting done for stable vitiligo: a retrospective study. *Indian J Dermatol.* 2015;60:369–72.
94. Ramos MG, Ramos DG, Ramos CG. Evaluation of treatment response to autologous transplantation of noncultured melanocyte/keratinocyte cell suspension in patients with stable vitiligo. *An Bras Dermatol.* 2017;92:312–8.
95. Wu K-J, Tang L-Y, Li J, Chen S-J, Lin J-R, Zhu Q-Y, et al. Modified technique of cultured epithelial cells transplantation on facial segmental vitiligo. *J Craniofac Surg.* 2017;28:1462–7.
96. Paul M. Autologous non-cultured basal cell-enriched epidermal cell suspension transplantation in vitiligo: Indian experience. *J Cutan Aesthetic Surg.* 2011;4:23–8.
97. Chen Y-F, Yang P-Y, Hu D-N, Kuo F-S, Hung C-S, Hung C-M. Treatment of vitiligo by transplantation of cultured pure melanocyte suspension: analysis of 120 cases. *J Am Acad Dermatol.* 2004;51:68–74.
98. Bae JM, Lee JH, Kwon HS, Kim J, Kim DS. Motorized 0.8-mm micropunch grafting for refractory vitiligo: a retrospective study of 230 cases. *J Am Acad Dermatol.* 2018;79, 720–7.e1.
99. Malakar S, Dhar S. Treatment of stable and recalcitrant vitiligo by autologous miniature punch grafting: a prospective study of 1,000 patients. *Dermatology.* 1999;198:133–9.
100. Chandrashekar BS, Madura C, Varsha DV. Autologous mini punch grafting: an experience of using motorized power punch in 10 patients. *J Cutan Aesthet Surg.* 2014;7:42–5.
101. BRASIL. Agência Nacional de Vigilância Sanitária (ANVISA). Resolução CNS/MS 466. Dezembro; 2012. [cited 22.10.19]. Available from: <http://conselho.saude.gov.br/resolucoes/2012/Reso466.pdf>.
102. Altalhab S, AlJasser MI, Mulekar SV, Al Issa A, Mulekar S, Diaz J, et al. Six-year follow-up of vitiligo patients successfully treated with autologous non-cultured melanocyte-keratinocyte transplantation. *J Eur Acad Dermatol Venerol.* 2019;33:1172–6.
103. Zhang DM, Hong WS, Fu LF, Wei XD, Xu AE. A randomized controlled study of the effects of different modalities of narrow-band ultraviolet B therapy on the outcome of cultured autologous melanocytes transplantation in treating vitiligo. *Dermatol Surg.* 2014;40:420–6.
104. Tawfik YM, Abd Elazim NE, Abdel-Motaleb AA, Mohammed RAA, Tohamy AM. The effect of NB-UVB on noncultured melanocyte and keratinocyte transplantation in treatment of generalized vitiligo using two different donor-to-recipient ratios. *J Cosmet Dermatol.* 2019;18:638–46.
105. Andrade Lima EV, Aandrade Lima MMD, Miot HA. Induction of pigmentation through microneedling in stable localized vitiligo patients. *Dermatol Surg.* 2020;46:434–5.
106. Attwa EM, Khashaba SA, Ezzat NA. Evaluation of the additional effect of topical 5-fluorouracil to needling in the treatment of localized vitiligo. *J Cosmet Dermatol.* 2020;19:1473–8.
107. BinSheikhan S, Al Abadie M. Improvement in moderate to severe vitiligo using a novel combination of 308 nm excimer laser and a surgical needling technique. *Clin Exp Dermatol.* 2017;42:363–6.
108. Elshafy Khashaba SA, Elkot RA, Ibrahim AM. Efficacy of NB-UVB, microneedling with triamcinolone acetonide, and a combination of both modalities in the treatment of vitiligo: a comparative study. *J Am Acad Dermatol.* 2018;79:365–7.
109. Ibrahim ZA, Hassan GF, Elgendy HY, Al-shenawy HA. Evaluation of the efficacy of transdermal drug delivery of calcipotriol plus betamethasone versus tacrolimus in the treatment of vitiligo. *J Cosmet Dermatol.* 2019;18:581–8.
110. Jha AK, Sonthalia S. 5-Fluorouracil as an adjuvant therapy along with microneedling in vitiligo. *J Am Acad Dermatol.* 2019;80:e75–6.
111. Korobko IV, Lomonosov KM. A pilot comparative study of topical latanoprost and tacrolimus in combination with narrow-band ultraviolet B phototherapy and microneedling for the treatment of nonsegmental vitiligo. *Dermatol Ther.* 2016;29:437–41.
112. Kumar A, Bharti R, Agarwal S. Microneedling with Dermalroller 192 needles along with 5-fluorouracil solution in the treatment of stable vitiligo. *J Am Acad Dermatol.* 2019;81:e67–9.
113. Lagrange S, Montaudié H, Fontas E, Bahadoran P, Lacour JP, Passeron T. Comparison of microneedling and full surface erbium laser dermabrasion for autologous cell suspension grafting in nonsegmental vitiligo: a randomized controlled trial. *Br J Dermatol.* 2019;180:1539–40.
114. Mina M, Elgarhy L, Al-saeid H, Ibrahim Z. Comparison between the efficacy of microneedling combined with 5-fluorouracil vs microneedling with tacrolimus in the treatment of vitiligo. *J Cosmet Dermatol.* 2018;17:744–51.
115. Shashikiran AR, Gandhi S, Muruges SB, Kusagur M, Sugareddy. Efficacy of topical 5% fluorouracil needling in vitiligo. *Indian J Dermatol Venereol Leprol.* 2018;84:203–5.
116. Stanimirovic A, Kovacevic M, Korobko I, Situm M, Lotti T. Combined therapy for resistant vitiligo lesions: NB-UVB, microneedling, and topical latanoprost, showed no enhanced efficacy compared to topical latanoprost and NB-UVB. *Dermatol Ther.* 2016;29:312–6.
117. Zawar VP, Karad GM. Needling in unresponsive stable vitiligo. *J Am Acad Dermatol.* 2016;75:e199–200.
118. Nicolaidou E, Mastrafitsi S, Tzanetakou V, Rigopoulos D. Childhood vitiligo. *Am J Clin Dermatol.* 2019;20:515–26.
119. Taieb A, Seneschal J, Mazereeuw-Hautier J. Special considerations in children with vitiligo. *Dermatol Clin.* 2017;35:229–33.
120. Raone B, Patrizi A, Gurioli C, Gazzola A, Ravaioli GM. Cutaneous carcinogenic risk evaluation in 375 patients treated with narrowband-UVB phototherapy. *Photodermatol Photoimmunol Photomed.* 2018;34:302–6.
121. Holme SA, Anstey AV. Phototherapy and PUVA photochemotherapy in children. *Photodermatol Photoimmunol Photomed.* 2004;20:69–75.
122. Percivalle S, Piccinno R, Caccialanza M, Forti S. Narrowband ultraviolet B phototherapy in childhood vitiligo: evaluation of results in 28 patients. *Pediatr Dermatol.* 2012;29:160–5.
123. Kanwar AJ, Dogra S. Narrow-band UVB for the treatment of generalized vitiligo in children. *Clin Exp Dermatol.* 2005;30:332–6.

124. Njoo M, Bos J, Westerhof W. Treatment of generalized vitiligo in children with narrow-band (TL-01) UVB radiation therapy. *J Am Acad Dermatol.* 2000;42 Pt 1:245–53.
125. Brazzelli V, Prestinari F, Castello M, Bellani E, Roveda E, Barbagallo T, et al. Useful treatment of vitiligo in 10 children with UV-B narrowband (311 nm). *Pediatr Dermatol.* 2005;22:257–61.
126. Rodrigues M. Skin cancer risk (nonmelanoma skin cancers/melanoma) in vitiligo patients. *Dermatol Clin.* 2017;35:129–34.
127. Dayal S, Sahu P, Gupta N. Treatment of childhood vitiligo using tacrolimus ointment with narrowband ultraviolet B phototherapy. *Pediatr Dermatol.* 2016;33:646–51.
128. Aljebab F, Choonara I, Conroy S. Systematic review of the toxicity of short-course oral corticosteroids in children. *Arch Dis Child.* 2016;101:365–70.
129. Van Staa TP, Leufkens HGM, Abenham L, Zhang B, Cooper C. Use of oral corticosteroids and risk of fractures. *J Bone Miner Res.* 2000;15:993–1000.
130. van Staa TP, Cooper C, Leufkens H, Bishop N. Children and the risk of fractures caused by oral corticosteroids. *J Bone Miner Res.* 2003;18:913–8.
131. Majid I, Masood Q, Hassan I, Khan D, Chisti M. Childhood vitiligo: response to methylprednisolone oral minipulse therapy and topical fluticasone combination. *Indian J Dermatol.* 2009;54:124–7.
132. Bandoli G, Palmsten K, Forbess Smith CJ, Chambers CD. A review of systemic corticosteroid use in pregnancy and the risk of select pregnancy and birth outcomes. *Rheum Dis Clin North Am.* 2017;43:489–502.
133. Kong YL, Ching VHL, Chuah SY, Thng TG. Retrospective study on the characteristics and treatment of late-onset vitiligo. *Indian J Dermatol Venereol Leprol.* 2017;83:625.
134. Taieb A, Alomar A, Böhm M, Dell' Anna ML, De Pase A, Eleftheriadou V, et al. Guidelines for the management of vitiligo: the European Dermatology Forum consensus. *Br J Dermatol.* 2013;168:5–19.
135. Ezzedine K, Silverberg N. A practical approach to the diagnosis and treatment of vitiligo in children. *Pediatrics.* 2016;138, e20154126-e.
136. Lepe V, Moncada B, Castanedo-Cazares JP, Torres-Alvarez MB, Ortiz CA, Torres-Rubalcava AB. A double-blind randomized trial of 0.1% tacrolimus vs 0.05% clobetasol for the treatment of childhood vitiligo. *Arch Dermatol.* 2003;139:581–5.
137. Hu W, Xu Y, Ma Y, Lei J, Lin F, Xu A-E. Efficacy of the topical calcineurin inhibitors tacrolimus and pimecrolimus in the treatment of vitiligo in infants under 2 years of age: a randomized. Open-Label Pilot Study. *Clin Drug Investig.* 2019;39:1233–8.
138. Cockayne SE, Messenger AG, Gawkrödger DJ. Vitiligo treated with topical corticosteroids: children with head and neck involvement respond well. *J Am Acad Dermatol.* 2002;46:964–5.
139. Kwinter J, Pelletier J, Khambalia A, Pope E. High-potency steroid use in children with vitiligo: a retrospective study. *J Am Acad Dermatol.* 2007;56:236–41.
140. Ho N, Pope E, Weinstein M, Greenberg S, Webster C, Krafchik BR. A double-blind, randomized, placebo-controlled trial of topical tacrolimus 0.1% vs. clobetasol propionate 0.05% in childhood vitiligo. *Br J Dermatol.* 2011;165:626–32.
141. Chi CC, Wang SH, Kirtschig G. Safety of topical corticosteroids in pregnancy. *JAMA Dermatol.* 2016;152:934–5.
142. Das A, Panda S. Use of topical corticosteroids in dermatology: an evidence-based approach. *Indian J Dermatol.* 2017;62:237–50.
143. Kainz A, Harabacz I, Cowrick IS, Gadgil SD, Hagiwara D. Review of the course and outcome of 100 pregnancies in 84 women treated with tacrolimus. *Transplantation.* 2000;70:1718–21.
144. Reitamo S, Wollenberg A, Schopf E, Perrot JL, Marks R, Ruzicka T, et al. Safety and efficacy of 1 year of tacrolimus ointment monotherapy in adults with atopic dermatitis. The European Tacrolimus Ointment Study Group. *Arch Dermatol.* 2000;136:999–1006.
145. Rubins A, Gutman R, Valdmane N, Stevenson P, Foster C, Undre N. Pharmacokinetics of 0.1% tacrolimus ointment after first and repeated application to adults with moderate to severe atopic dermatitis. *J Invest Dermatol.* 2005;125:68–71.
146. Undre NA, Moloney FJ, Ahmadi S, Stevenson P, Murphy GM. Skin and systemic pharmacokinetics of tacrolimus following topical application of tacrolimus ointment in adults with moderate to severe atopic dermatitis. *Br J Dermatol.* 2009;160:665–9.
147. Dellatorre G, Oliveira C, Chaves T, Linsingen R, Castro C. A study of the prognosis of vitiligo during pregnancy. *Surg Cosmet Dermatol.* 2013;5:37–9.
148. Webb KC, Lyon S, Nardone B, West DP, Kundu RV. Influence of pregnancy on vitiligo activity. *J Clin Aesthet Dermatol.* 2016;9:21–5.
149. Kong Y, Ching VL, Chuah S, Thng T. Retrospective study on the characteristics and treatment of late-onset vitiligo. *Indian J Dermatol Venereol Leprol.* 2017;83:625.