

Head and Neck Cancer

The Role of Modified Killian's Method in the Evaluation of Hypopharyngeal and Supraglottic Cancers

Priyanka Schilling Amar¹ Kamran Asif Syed¹ Rajiv C. Michael²

¹Department of Otorhinolaryngology, Christian Medical College, Vellore, Tamil Nadu, India

²Department of Head & Neck Surgery, Christian Medical College, Vellore, Tamil Nadu, India

Address for correspondence Priyanka Schilling Amar, MS, Department of Otorhinolaryngology and Head & Neck Surgery, Christian Medical College, Vellore – 632004, Tamil Nadu, India (e-mail: priyankaschilling@gmail.com).

South Asian J Cancer 2022;11(4):332–335.

Abstract



Priyanka Schilling Amar

Keywords

- ▶ diagnostic flexible laryngoscopy
- ▶ direct laryngoscopy
- ▶ hypopharyngeal and supraglottic cancers
- ▶ modified Killian's method
- ▶ Muroño's scale

Objectives Hypopharyngeal cancer is one of the upper aerodigestive tract malignancies with the poorest prognosis. The aim of this study was to assess the role of modified Killian's (MK) method in routine, outpatient-based flexible laryngoscopy to improve visualization and assess the extent of supraglottic and hypopharyngeal cancers.

Materials and Methods An observational study was conducted in a tertiary hospital in India where fifty consecutive patients who presented to the outpatient clinic with suspected hypopharyngeal and supraglottic malignancy underwent a conventional laryngoscopy as well as MK method. The site and extent of the tumor on endoscopy were recorded and the videos were graded independently by two investigators on Muroño's scale from 1 to 5. A subset of these patients who underwent direct laryngoscopy under general anesthesia was also scored with the above scale. The scores were compared to check the accuracy of flexible laryngoscopy with the MK method in staging cancer.

Statistical Analysis Descriptive statistics were given using mean (standard deviation [SD]) for continuous variables and frequency (percentage) for categorical variables. The difference between the mean scores was analyzed using the paired-t test. The agreement between the scales and the observer, that is, the inter- and intraobserver agreement, was presented with concordance rate and Kappa weighted analysis.

Results In this study, the mean scores of the Muroño's scale grading of the conventional method, MK method, and direct laryngoscopy were 1.42 (SD: 0.64), 2.94 (SD: 0.95), and 4.30 (SD: 1.49), respectively, which showed significant improvement in scores with MK method. In addition, the subset analysis demonstrated a significant agreement between direct laryngoscopy and MK method.

Conclusion The MK method is a good diagnostic test and a valuable adjunct to diagnostic flexible laryngoscopy in the evaluation and staging of hypopharyngeal and supraglottic cancers.

Flexible laryngoscopy using the Modified Killian's method is a good and easy diagnostic test for early evaluation of hypopharyngeal and supraglottic cancers by improving the visualization and the office evaluation of head and neck cancers.

DOI <https://doi.org/10.1055/s-0042-1754375> ISSN 2278-330X

How to cite this article: Amar PS, Syed KA, Michael RC, et al. The Role of Modified Killian's Method in the Evaluation of Hypopharyngeal and Supraglottic Cancers. South Asian J Cancer 2022;11(4):332–335.

© 2022. MedIntel Services Pvt Ltd. All rights reserved.

This is an open access article published by Thieme under the terms of the Creative Commons Attribution-NonDerivative-NonCommercial-License, permitting copying and reproduction so long as the original work is given appropriate credit. Contents may not be used for commercial purposes, or adapted, remixed, transformed or built upon. (<https://creativecommons.org/licenses/by-nc-nd/4.0/>)

Thieme Medical and Scientific Publishers Pvt. Ltd., A-12, 2nd Floor, Sector 2, Noida-201301 UP, India

Introduction

Early detection is the key determinant in the outcomes of hypopharyngeal cancer. It is regarded as one of the cancers with a poor outcome, secondary to diagnosis at an advanced stage.¹ Hypopharyngeal cancers are associated with a very poor prognosis that is partly due to the presence of rich lymphatic drainage and partly due to the magnitude of the operation required in its treatment, particularly when presentation is late.² Early lesions can be missed easily as the hypopharynx is often not visualized in its entirety on a routine fiberoptic endoscopic examination. It is established that the endoscopic screening in patients with squamous cell carcinoma (SCC) of the head and neck facilitates in early detection of second lesions.¹ Innovations in cancer diagnosis, namely narrow-band imaging system, have revolutionized the management of laryngeal and oropharyngeal cancers. However, the same could not be replicated in the treatment of hypopharyngeal and supraglottic cancers. The size and site of the tumor are the key factors to a successful outcome in both transoral laryngeal surgery and larynx preserving techniques.

Many researchers have devised strategies to enhance the visualization of the hypopharynx. However, none have compared it to the direct laryngoscopy, which is the gold standard.³⁻⁵ The objective of this study was to compare the degree of visualization of hypopharynx with conventional and “Modified Killian’s” (MK) methods. We have also compared the accuracy as well as the extent of visualization with MK method with direct laryngoscopy in staging supraglottic and hypopharyngeal lesions.

Methods

A prospective observational study was conducted for 19 months between November 2016 and June 2018 in the department of ear, nose, and throat at a tertiary hospital in India after the Institutional Review Board approval—IRB No: 10264[DIAGNO].

A total of 50 consecutive patients with a primary hypopharyngeal or supraglottic cancer, aged over 18 years, consenting to participate in the study were included. The subjects were excluded if they had malignancies of the oral cavity, oropharynx, nasopharynx, paranasal sinuses, unable to perform Valsalva maneuver, allergic to lignocaine or unstable cardiac disease with any respiratory distress.

After topicalization of the participants with 4% lignocaine, fiberoptic laryngoscopy was performed demonstrating the maneuvers using 3.7 mm ENF- P4 Olympus fiberoptic laryngoscope and camera (Storz Telecam Dx KARL STORZ SE & Co. KG- Tuttlingen, Germany). Once all the personal identifiable information was removed from the videos, these were graded by two blinded assessors.

Conventional laryngoscopy was performed in sitting position and subject asked to phonate and larynx visualized. The subject was then asked to bend forwards while in the sitting position with the fiberoptic laryngoscope in position. They were then asked to perform a Valsalva maneuver (→Fig. 1). The pyriform sinuses were then evaluated by turning

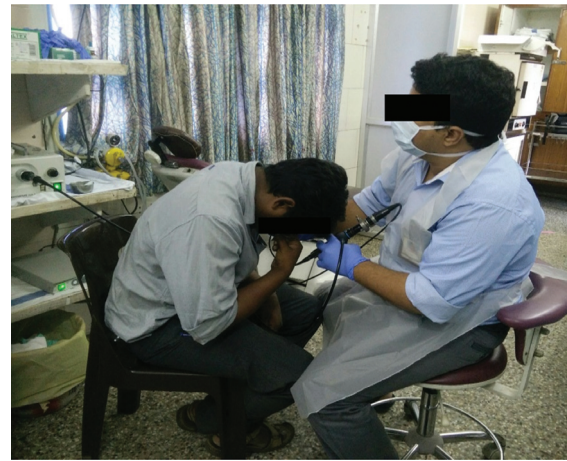

Fig. 1 Flexible laryngoscopy using modified Killian’s method in the outpatient department.

the head to the opposite sides. A subset of these patients underwent a direct laryngoscopy under general anesthesia and biopsy for histopathological confirmation of the diagnosis. Two independent and blinded assessors—experienced otorhinolaryngology professors, graded the deidentified videos. The extent of the tumor was noted in all techniques and the degree of the exposure of the hypopharynx was graded using Murono’s scale by each investigator independently. (→Supplementary Material S1, available online only).

The data was analyzed using STATA15.1 I/C software. The difference between the mean scores was analyzed using paired-t test along with subgroup analysis. The following variables were compared: patient age, gender, direct laryngoscopy done or not, and scores obtained based on visualization of tumors. The agreement between the scales and the observer, that is, the inter- and intraobserver agreement, was measured with concordance rate and Kappa weighted analysis. The agreement between raters (assessor 1 and 2) was analyzed using weighted Kappa as the scores on grade (→Supplementary Material S1, available online only).

Results

Majority of the patients were male and aged between 55 and 65 years of age (→Supplementary Material S1, available online only). Direct laryngoscopy is the gold standard with the best degree of visualization and this was reflected by high mean scores on Murono’s scale. MK method was the superior of the two fiberoptic laryngoscopy techniques with better degree of visualization (→Fig. 2). Paired *t*-test demonstrated a statistically significant difference in the Murono’s scores with MK method, in comparison to conventional method (p -value = 0.000). The direct laryngoscopy was superior to both conventional laryngoscopy and MK method (p = 0.0002 and p = 0.0064, respectively) (→Table 1 [see Note]).

Among the subsites that were assessed apex of pyriform sinus, lower posterior pharyngeal wall and postcricoid area were the least visualized subsites with conventional laryngoscopy but all these subsites showed improved visualization with MK method. Similarly, these were well visualized

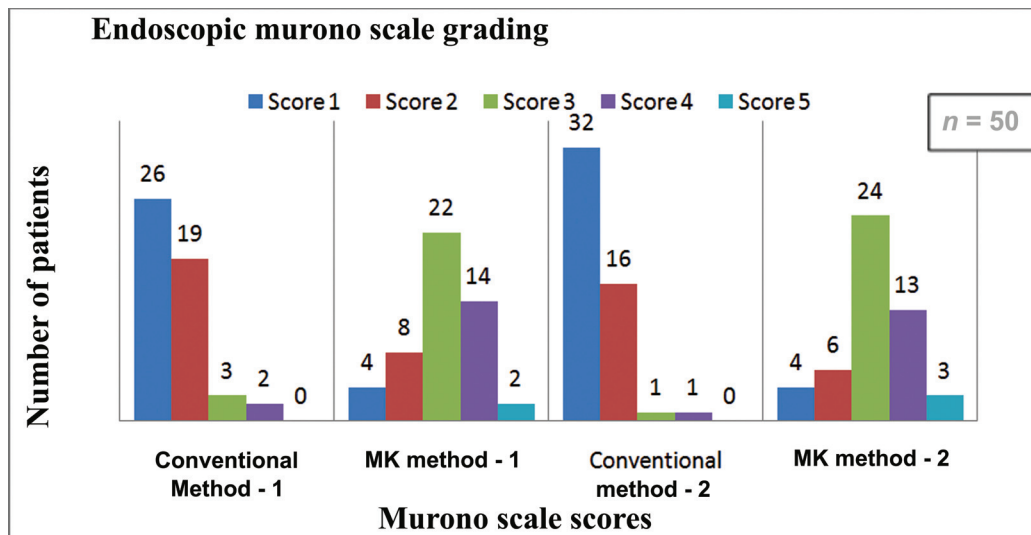


Fig. 2 Comparison of Murono's scale score between conventional method and modified Killian's (MK) method.

with direct laryngoscopy, previously which was difficult with fiberoptic techniques ([Supplementary Material S1](#), available online only). The extent of tumor could be visualized in entirety in only 2% of all the participants with conventional technique. However, the complete extent of the tumor was visualized in more than 60% of the participants with MK method by both assessors. ([Supplementary Material S1](#), available online only).

The inter-rater agreement for MK method was 94.27% with Kappa value of 0.77. The inter-rater agreement between conventional method of laryngoscopy by both assessors was 74% with a Kappa value above 0.48 ([Supplementary Material S1](#), available online only). We found low concordance between two methods in some subsites that were poorly visualized—apex of pyriform sinus, posterior surface of cricoid, and lower part of posterior pharyngeal wall. Most of the subsites were visualized by both assessors with higher concordance even in the difficult to visualize subsites as mentioned above. The concordance of MK methods between the assessors was more than 90% in most of the subsites visualized with Kappa value of more than 0.8 suggestive of almost perfect agreement ([Supplementary Material S1](#), available online only).

Discussion

The 5 years survival rate is 64%, and the rate for individual sites are 47% for supraglottic SCC, 79% for glottic SCC, and 30 to 50% for subglottic SCC.⁶

Hypopharyngeal cancers have one of the lowest survivals among all the head and neck cancers.

The advanced stage at the diagnosis, poor general condition, submucosal spread, and high propensity to lymphatic metastasis are the reasons for poor outcomes.⁷ The tendency to invade adjoining structures is high in hypopharyngeal cancers and early diagnosis is the key. Only less than 5% patients with hypopharyngeal cancer are in stage I at the time of diagnosis.⁸

Early and improved visualization of the mucosal disease holds key for early intervention, thus improving the overall outcome. Vocal cord mobility is an important sign for deep extension.⁹

In this study, hypopharyngeal and supraglottic cancer lesion were graded with a flexible laryngoscope using both conventional and MK method to compare the extent of visualization of the lesion. Since the tendency of most hypopharyngeal cancers is to spread in the inferior direction, the inferior extent of the tumor is better visualized with this additional maneuver during the flexible laryngoscopy.¹⁰ The MK method helped in visualizing the apex of the pyriform sinus in most of the participants; hence, the inferior extent of tumor was visualized at an early stage for the better management of hypopharyngeal cancers ([Supplementary Material S1](#), available online only).

Murono et al and Sakai et al studied the MK method as an adjunct to the endoscopic evaluation of hypopharyngeal and laryngeal cancers.^{3,4} The study found out that the MK

Table 1 Paired *t*-test among all three methods

Variable	<i>n</i>	Mean Murono's score	Standard error	Standard deviation
Conventional method	13	1.69	0.26	0.94
Modified Killian's (MK) method	13	2.92	0.28	1.03
Direct laryngoscopy	13	4.30	0.41	0.41

Note: The difference between the mean scores of Murono's scale between normal method and direct laryngoscopy among the subset sample was 2.61 with a significant *p*-value of 0.0002 and between MK method and direct laryngoscopy among the subset sample was 1.38 with a significant *p*-value of 0.0064.

method had improved the visualization of the hidden areas of hypopharynx namely the post cricoid and apex of pyriform sinuses, which are not routinely visualized during a conventional flexible laryngoscopy. Both the assessors were able to visualize the tumor extent in its entirety with the MK method as compared to conventional method.

In the study by Muroño et al, the mean scores of normal method of flexible laryngoscopy were 1.11 (standard deviation [SD]: 0.36) and MK method was 3.39 (SD: 0.94) with significant difference in mean score and *p*-value of less than 0.01.³ On analysis, we found that the mean scores on the Muroño's scale grading of the conventional method, MK method, and direct laryngoscopy were 1.42 (SD: 0.64), 2.94 (SD: 0.95), and 4.30 (SD: 1.49), respectively. Among the three methods, our study found a statistically significant difference in the mean scores was observed (*p*-value < 0.05). The MK method showed significant improvement in the grading of scores in all 50 participants in comparison to conventional method (**–Supplementary Material S1**, available online only).

This is the first study reporting inter-rater agreement for MK method of fiberoptic examination of larynx and hypopharynx where both assessors had a concordance of more than 90% in most subsites in MK method. Similarly, no study has compared the agreement between the two methods of fiberoptic laryngoscopy—conventional and MK method with the direct laryngoscopy, which is the gold standard. In addition to both fiberoptic laryngoscopy techniques, 13 patients also underwent direct laryngoscopy under general anesthesia. The rest either had a flexible laryngoscopy-guided biopsy under local anesthesia or already had a direct laryngoscopy previously done elsewhere.

The difference between the mean scores of Muroño's scale score of conventional method of laryngoscopy and direct laryngoscopy among the subset sample was 2.61 (*p*-value = 0.0002). On the contrary, there was a statistically significant correlation with the difference in mean scores of MK method and direct laryngoscopy was 1.38 (*p*-value = 0.0064).

The degree of visualization of tumors in the MK method was quite comparable to direct laryngoscopy that is the gold standard. Most patients were compliant with the MK method of flexible laryngoscopy. Four participants who could not perform Valsalva maneuver were excluded from the study.

Currently with the above results, we emphasize that the use of MK method as an adjunct to flexible fiberoptic laryngoscopy could be a helpful diagnostic tool in the early diagnosis and staging of hypopharyngeal and laryngeal cancers. It is simple and easy maneuver and can be done along with conventional method in an outpatient setting. Along with imaging, this method can aid in the early diagnosis and improve the treatment outcomes of hypopharyngeal and supraglottic cancers.

Conclusion

The MK method is a safe and reliable diagnostic tool that significantly improves the extent of visualization of the

primary hypopharyngeal and supraglottic cancer lesions; therefore, we recommend it as part of a routine fiberoptic laryngoscopy evaluation of patients with hypopharyngeal/supraglottic malignancies in the outpatient setting without any added cost.

Note

The study was approved by the Institutional Review Board under the category of study for diagnostic test.

Source(s) of Support

None.

Authors' Contributions

Priyanka Schilling Amar was involved in definition of intellectual content, literature search, clinical studies, data acquisition, data analysis, statistical analysis, and manuscript preparation. Kamran Asif Syed and Rajiv C. Michael contributed to conceptualization, designing, definition of intellectual content, data analysis, manuscript editing and review. Priyanka Schilling Amar provided the guarantee for this manuscript.

Conflict of Interests

None.

Acknowledgements

None.

References

- Shah SB, Sharma S, D'Cruz AK. Head and neck oncology: the Indian scenario. *South Asian J Cancer* 2016;5(03):104–105
- Gourin CG, Terris DJ. Carcinoma of the hypopharynx. *Surg Oncol Clin N Am* 2004;13(01):81–98
- Muroño S, Tsuji A, Endo K, Kondo S, Wakisaka N, Yoshizaki T. Evaluation of modified Killian's method: a technique to expose the hypopharyngeal space. *Laryngoscope* 2014;124(11):2526–2530
- Sakai A, Okami K, Sugimoto R, et al. A new technique to expose the hypopharyngeal space: the modified Killian's method. *Auris Nasus Larynx* 2014;41(02):207–210
- Ni X-G, Cheng R-R, Lai S-Q, et al. Novel laryngoscopic strategies to improve evaluation of the site and extent of primary hypopharyngeal tumours. *J Laryngol Otol* 2013;127(09):882–889
- Resnick JM, Uhlman D, Niehans GA, et al. Cervical lymph node status and survival in laryngeal carcinoma: prognostic factors. *Ann Otol Rhinol Laryngol* 1995;104(9 Pt 1):685–694
- Harrison DF. Pathology of hypopharyngeal cancer in relation to surgical management. *J Laryngol Otol* 1970;84(04):349–367
- Sewnaik A, Hoorweg JJ, Knegt PP, Wieringa MH, van der Beek JM, Kerrebijn JDF. Treatment of hypopharyngeal carcinoma: analysis of nationwide study in the Netherlands over a 10-year period. *Clin Otolaryngol* 2005;30(01):52–57
- Crosetti E, Pilolli F, Succo G. A new strategy for endoscopic staging of laryngeal carcinoma: multistep endoscopy. *Acta Otorhinolaryngol Ital* 2012;32(03):175–181
- Zbären P, Egger C. Growth patterns of piriform sinus carcinomas. *Laryngoscope* 1997;107(04):511–518