

**POSTER PRESENTATION**

**Open Access**

# Extracellular volume fraction mapping at 3T with non-rigid image co-registration

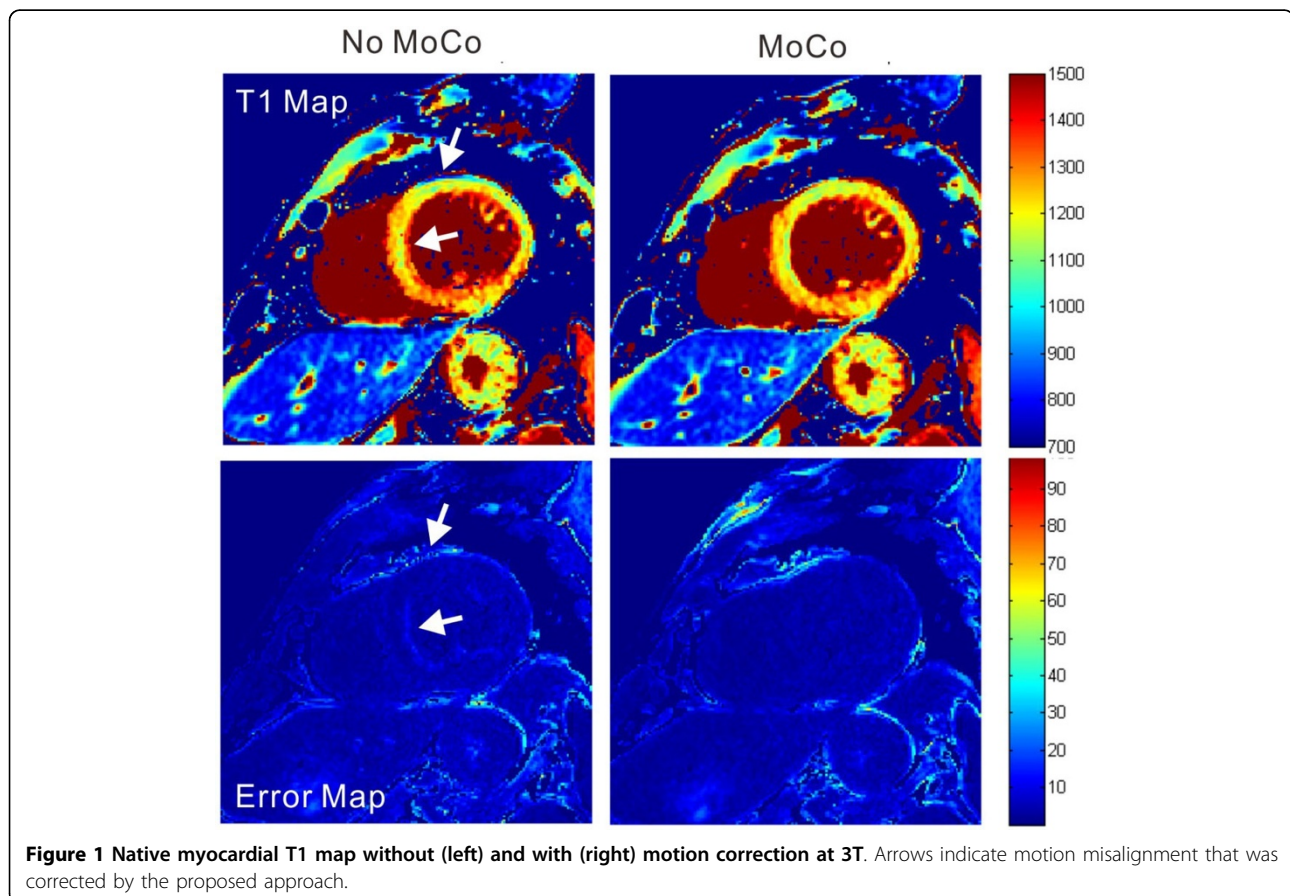
Thu Thao Le<sup>1</sup>, Shuo Zhang<sup>1,2\*</sup>, Sven Kabus<sup>3</sup>, Bao Ru Leong<sup>1</sup>, Yiyang Han<sup>1</sup>, Derek J Hausenloy<sup>1,4</sup>, Stuart Cook<sup>1,5</sup>, Ru San Tan<sup>1</sup>, Calvin W Chin<sup>2</sup>

From 19th Annual SCMR Scientific Sessions  
Los Angeles, CA, USA. 27-30 January 2016

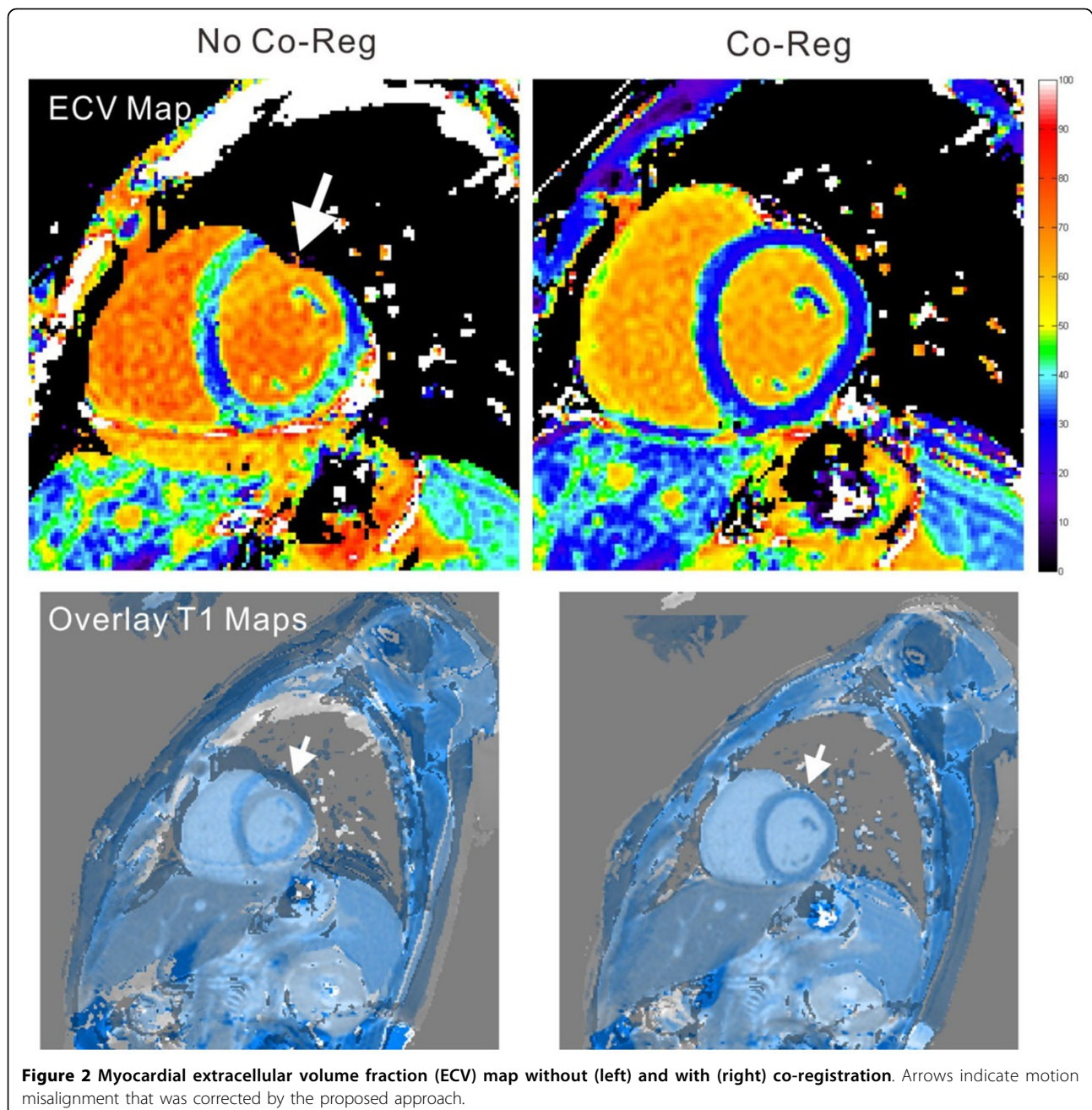
## Background

MOLLI-based T1-mapping is a robust method for myocardial tissue characterization. Extracellular volume

fraction (ECV), a marker of diffuse fibrosis, requires pre- and post-contrast T1 values. However, ECV mapping is not widely available because of complexities in



<sup>1</sup>National Heart Centre, Singapore, Singapore  
Full list of author information is available at the end of the article



motion correction and image co-registration. Here, we demonstrated ECV mapping using a novel approach for motion compensation at 3T.

### Methods

All patients underwent cardiovascular magnetic resonance (CMR) on a 3T system (Philips Ingenia). T1 maps were acquired in the basal and mid-cavity short-axis level, pre- and 20-min post-contrast (Gadovist 0.1 mmol/kg) with a 5s(3s)3s and 4s(1s)3s(1s)2s MOLLI acquisition scheme, respectively. A modified non-rigid,

non-parametric registration method consisting of elastic registration steps was applied to generate motion-corrected T1 maps and subsequent ECV maps [1]. T1 error maps and overlay images were used as an indication for quality control. Global ECV values were expressed as mean $\pm$ standard deviation (SD).

### Results

A total of 33 ECV maps were obtained in 18 patients (mean age 47 $\pm$ 19 years, 12 males): 10 with chronic myocardial infarction and 8 with dilated and hypertrophic

cardiomyopathies. 28 cases (85%) demonstrated clear improvement in image quality after motion correction and co-registration. Two examples are shown in Figures 1 and 2. Global ECV values in the patients with myocardial infarction and cardiomyopathies were 34.9+/-4.9% and 36.4+/-6.0%, respectively.

## Conclusions

Automated motion correction and co-registration improved the quality of T1 and ECV maps at 3T, making ECV mapping feasible for clinical application.

## Authors' details

<sup>1</sup>National Heart Centre, Singapore, Singapore. <sup>2</sup>Philips Healthcare, Singapore, Singapore. <sup>3</sup>Philips Research, Hamburg, Germany. <sup>4</sup>University College London, London, UK. <sup>5</sup>Imperial College London, London, UK.

Published: 27 January 2016

## Reference

1. Kabus: *WBIR* 2010.

doi:10.1186/1532-429X-18-S1-P32

**Cite this article as:** Le *et al.*: Extracellular volume fraction mapping at 3T with non-rigid image co-registration. *Journal of Cardiovascular Magnetic Resonance* 2016 **18**(Suppl 1):P32.

**Submit your next manuscript to BioMed Central and take full advantage of:**

- Convenient online submission
- Thorough peer review
- No space constraints or color figure charges
- Immediate publication on acceptance
- Inclusion in PubMed, CAS, Scopus and Google Scholar
- Research which is freely available for redistribution

Submit your manuscript at  
[www.biomedcentral.com/submit](http://www.biomedcentral.com/submit)

