

Case Report

Delayed traumatic parasternal hernia causes jejunal necrosis: A case report

Huimin Zhao*, Ru Gao, Donghui Jia, Aiming Li

Department of Thoracic Surgery, No. 1 Hospital of BaoDing City, China

ARTICLE INFO

Article history:

Accepted 21 May 2017

Available online 7 June 2017

Keywords:

Parasternal hernia

Obstruction

Jejunal necrosis

ABSTRACT

Diaphragmatic injury is a common clinical condition, and it may be difficult to avoid diaphragmatic hernia if detection and treatment is not timely. Parasternal hernia is mostly congenital. It is relatively rare in adults, and intestinal obstruction as a complication of intrathoracic intestinal herniation occurs only rarely. We treated a patient in whom parasternal hernia occurred 2 years after thoracic injuries. We present the plain radiography and computed tomography findings of this adult patient with acute abdomen symptoms caused by parasternal hernia.

© 2017 Department of Thoracic Surgery, No. 1 Hospital of BaoDing City, China. Published by Elsevier Ltd. This is an open access article under the CC BY-NC-ND license (<http://creativecommons.org/licenses/by-nc-nd/4.0/>).

Introduction

Parasternal hernia is a rare condition, accounting for about 3% of all surgical treatment of diaphragmatic hernia [1]. Most hernias of this type are congenital, and rarely caused by trauma. Although parasternal hernias are generally asymptomatic and frequently found coincidentally during routine diagnostic tests for other pathologies, they may rarely be symptomatic from intestinal obstruction or respiratory distress. We present parasternal hernia in an adult, which occurred 2 years after he sustained thoracic injuries, with acute abdominal symptoms secondary to jejunum herniation and intestinal obstruction that eventually led to necrosis of the jejunum.

Case report

A 46-year-old-man presented with a 1-day history of sudden abdominal pain. In the 4 h preceding admission, abdominal pain increased, with an onset of left chest pain and dyspnea. A right-sided thoracotomy had been performed for chest trauma 2 years previously. There were decreased breath sounds on the left side. Chest radiography showed left diaphragm elevation, and fluid with a stepladder pattern within the loops of the bowel (Fig. 1). Computed tomography (CT) of the chest revealed air-filled bowel in the left thorax, accompanied by pleural effusion (Fig. 2A, B). The patient was taken to the operating room immediately and thoracotomy was performed under general anesthesia. We found a 50-cm proximal segment of jejunal loop parasternal into the left thoracic cavity. The jejunum was black in color and there was an absence of bowel peristalsis. We judged necrosis to be present (Fig. 3), and repaired the diaphragm and removed the necrotic jejunum. The patient made a full recovery.

* Corresponding author at: Department of Thoracic Surgery, No. 1 Hospital of BaoDing City, Baihua East Road No. 933, Lianchi District, HeBei 071000, China.
E-mail address: mouth101@163.com (H. Zhao).

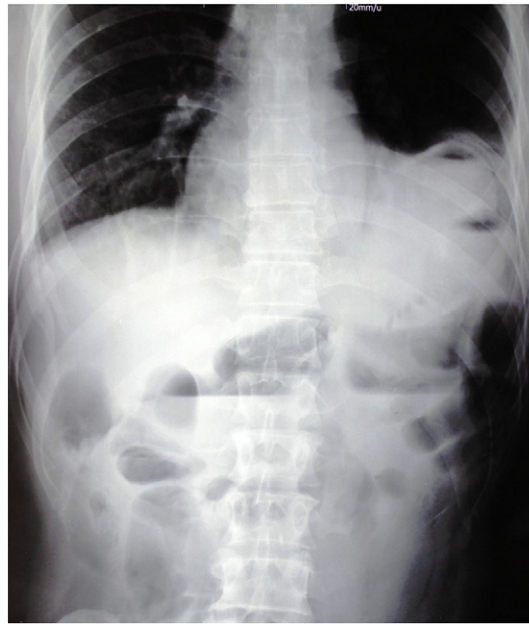

Fig. 1. Posteroanterior chest radiography, there are elevated left lung and a gas-filled intestinal loop on the left cardiophrenic angle and abdomen revealed air-fluid levels due to intestinal obstruction.

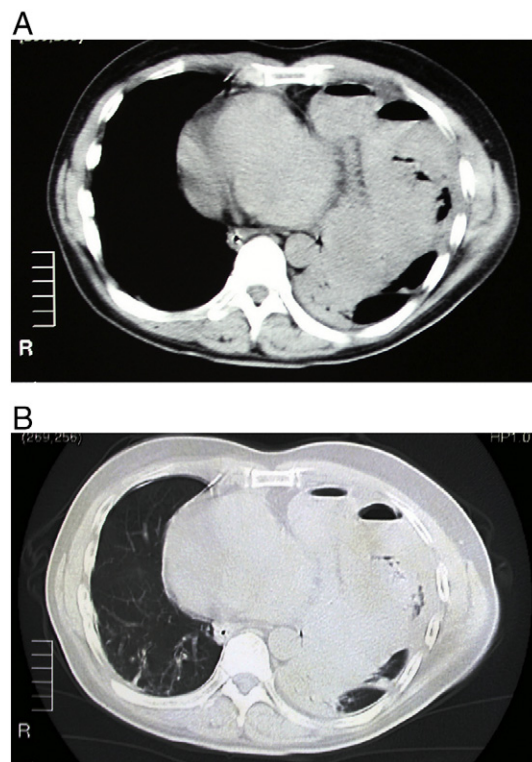


Fig. 2. A Chest CT scan showed air-filled bowel in the left thorax, accompanied by pleural effusion. B Chest CT scan showed intestinal inflation in the left chest, accompanied by pulmonary atelectasis.

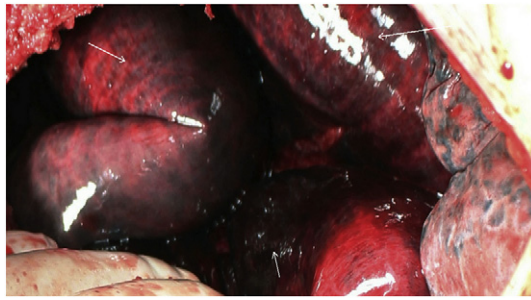


Fig. 3. Necrosis of the jejunum found during surgery.

Discussion

Traumatic diaphragmatic hernia was first described in 1541 by Sennertus [2]. In 1579, Paré described how “the stomach and intestines are sometimes drawn into the thoracic cavity” after an injury to the diaphragm [3]. He reported on an autopsy in which the left chest contained a strangulated loop of colon that had passed through a defect attributed to a stab wound 8 months previously. The first diagnosis and repair of an acute blunt diaphragmatic rupture was reported in 1900 by Walker [4], who treated a patient crushed by a falling tree.

The passage of abdominal contents into the thoracic cavity through an anterior retrosternal diaphragmatic defect has been known as a hernia of Morgagni, according to Morgagni's (1761) first description. There is, however, certain confusion on the name. Some authors apply Larrey's name to this type of hernia; others use Morgagni for right-sided hernia and Larrey's for left, while others use the names less discriminatingly. To clarify this apparent confusion it must be recalled that Larrey (1829) never described a hernia. He only developed a surgical approach to the pericardial cavity. Therefore, an anterior diaphragmatic hernia, whether right or left, should be referred to as a hernia of Morgagni, or hernia through Larrey's space. Other anatomical terms are used, such as subcostosternal hernia (Harrington, 1951), retrocostoxiphoid hernia (Denisart, 1951), retrosternal hernia (Warwick-Brown, 1953), parasternal hernia (Chin and Duchesne, 1955) or, simply, anterior diaphragmatic hernia (Dor and Eymery, 1956) [5].

Due to the movement of the diaphragm and its unique function and anatomical features, diaphragmatic injuries tend not to occur in isolation. Meyers and McCabe [6] report blunt diaphragmatic injury in 40% of individuals with pelvic fracture, in 25% with liver and spleen injuries, and in 5% with thoracic aortic injuries. Most blunt traumatic diaphragmatic hernias are caused by forceful indirect violence. On the right side of the diaphragm, a temporary blockage may occur because of the liver-diaphragm gap. This may be mistaken for right diaphragm elevation, lung contusion or consolidation, or pleural effusion. In addition, diaphragmatic injuries are often associated with complex injuries and are easily misdiagnosed. Right blunt traumatic diaphragmatic hernia does not present with specific characteristics and the use of different laboratory examinations is required to make a diagnosis. Spiral helical CT three-dimensional reconstruction imaging and MRI examinations show the relationship between the diaphragm and the lesion below the diaphragm more clearly, allowing clearer judgment of the continuity of the diaphragm. With the development of minimally invasive techniques, laparoscopy and thoracoscopy are being increasingly used to diagnose and treat diaphragmatic hernia. Accuracy of thoracic and laparoscopic diagnosis of diaphragmatic rupture is very high [7]. If the presence of technology and the patient's situation allows, early application of thoracoscopy is recommended. As well as enabling the clearing of pleural effusion and blood, thoracoscopy aids in the clear observation of whether abdominal hernia into the chest is present. Repair to lung laceration can be carried out simultaneously with diaphragmatic injury treatment, facilitating early diagnosis and early treatment of hernia. In our patient, diaphragmatic hernia presented late, and is likely to have been caused by the trauma sustained 2 years following which small diaphragm injuries remained undetected.

The diaphragm muscle constantly moves with breathing. If not promptly treated, what is initially only a small diaphragmatic injury will develop into a wider gap, further forming a complete or incomplete hernia of the abdominal contents. Heart and lung function may further be affected and so diaphragmatic muscle injuries, regardless of size, cannot self-heal. Early surgical repair is relatively simple and surgical treatment is advised in cases where symptoms are present. Either a transabdominal or transthoracic surgical approach may be performed. After time, diaphragmatic retraction or atrophy occurs, combined with adhesion formation, and delayed repair is relatively difficult, suggesting that once diaphragmatic hernia is diagnosed, surgery should be performed as soon as possible. However, such patients may have serious associated injuries, and often initial life-threatening injuries require management first, following which surgery for the diaphragm can be carried out, when the patient's condition stable. The repair method includes the use of an absorbable suture, an “8”-shaped horizontal mattress suture or overlapping full-thickness interrupted suture can be used, and repairs generally do not need artificial materials.

With a progressive increase in natural disasters and accidents, blunt traumatic diaphragmatic hernia incidence will also increase. Clinicians should be alert to the possibility of the existence of pericardial injury, and careful exploration and early surgical repair will improve the cure rate and reduce mortality.

Acknowledgement

We thank LetPub (www.letpub.com) for its linguistic assistance during the preparation of this manuscript. In addition, the anonymous reviewers have also contributed considerably to the publication of this paper. I would like to thank the anonymous reviewers who have helped to improve the paper.

References

- [1] M.L. Cullen, M.D. Klein, A.I. Philippart, Congenital diaphragmatic hernia, *Surg. Clin. North Am.* 65 (5) (1985) 1115–1138.
- [2] J. Reid, Diaphragmatic hernia, *Edin Med Surg J* 53 (1840) 104–107;
John F. Perry Jr., Blunt and penetrating abdominal injuries, *Curr. Probl. Surg.* 7 (5) (1970 May) 1–53.
- [3] W.B. Hamby, *The Case Reports and Autopsy Records of Ambroise Pare*, Charles C. Thomas, Springfield, IL, 1960.
- [4] E.W. Walker, Diaphragmatic hernia, with report of a case, *Int. J. Surg.* 13 (1900) 257–260.
- [5] F. Paris, V. Tarazona, M. Casilas, E. Blasco, A. Canto, J. Pastop, A. Acosta, Hernia of Morgagni, *Thorax* 28 (1973) 631–636.
- [6] B.F. Meyers, C.J. McCabe, Traumatic diaphragmatic hernia. Occult marker of serious injury, *Ann. Surg.* 218 (6) (1993 Dec) 783–790.
- [7] R.R. Ivatury, R.J. Simon, B. Weksler, et al., Laparoscopy in the evaluation of the intra thoracic abdomen after penetrating injury, *Trauma* 33 (1) (1992) 101–109.