

Anaphylaxis After the Covid-19 Vaccine in a Patient With Cholinergic Urticaria

*LCDR Hyun J. Park, MC, USN**; *CAPT Jay R. Montgomery, MC, USN (Ret.)†*;
*LCDR Nathan A. Boggs, USPHS**

ABSTRACT Cholinergic urticaria is a common disorder that has been associated with anaphylaxis. We report the events, workup, and eventual second dose vaccination of a patient at the Walter Reed National Military Medical Center, who had immediate anaphylaxis after administration of the first Pfizer-BioNTech Covid-19 (BNT162b2) vaccine dose. During the initial evaluation after anaphylaxis, the patient described a history of symptoms suspicious for cholinergic urticaria but had never had this condition confirmed with standardized testing. After the episode of anaphylaxis, we performed several studies including immediate hypersensitivity skin testing, which did not demonstrate vaccine or component sensitization. We then performed an exercise provocation challenge and confirmed the diagnosis of cholinergic urticaria. These results, combined with the patient history, suggested that the episode of anaphylaxis was most likely driven by a severe flare of cholinergic urticaria. After obtaining the patient's consent, she received and tolerated her second dose without any objective findings of anaphylaxis. We conclude that patients with mast cell disorders or anaphylaxis after their first Covid-19 immunization will benefit from referral to an allergist since receipt of their second Covid-19 immunization may be possible.

Published data support both efficacy and safety of the Pfizer-BioNTech Covid-19 (BNT162b2) vaccine and other Covid-19 vaccines.¹⁻³ Risk of anaphylaxis after any immunization is known to be rare, estimated at 1.31 events per million vaccine doses.⁴ Notably, studies investigating disorders beyond immunoglobulin E (IgE)-mediated allergy that may lead to immediate anaphylaxis after immunization have not yet been performed. Some patients with mast cell activation disorders may be more prone to immediate reactions following immunization. Specifically, anaphylaxis in patients with cholinergic urticaria has been reported although they are poorly characterized.⁵

We report a case of the first patient at the Walter Reed National Military Medical Center (WRNMMC), who had immediate anaphylaxis after administration of the Pfizer-BioNTech Covid-19 vaccine. We highlight that the patient never had an episode of anaphylaxis previously and had nonreactive skin testing for polyethylene glycol, polysorbate-containing vaccines, as well as the Covid-19 vaccine itself. Importantly, she had an underlying condition that predisposed her to non-IgE-mediated anaphylaxis.

Our case is a 34-year-old female healthcare professional, who presented to the Allergy and Immunology clinic for evaluation of an anaphylaxis event that occurred after

administration of the first dose of the Pfizer-BioNTech Covid-19 vaccine. The patient had negative SARS-CoV-2 nucleic acid tests 109 and 39 days before immunization. She noted in our interview to have been subjectively overheated while standing in line waiting to receive the first dose of the vaccine. Within 3 min of vaccine administration, she developed flushing, urticaria on her extremities and face, generalized pruritus, tongue swelling, nausea, light-headedness, racing pulse, and shortness of breath with absence of wheezing. Emergency medical personnel responded and administered intramuscular epinephrine and diphenhydramine. She noted substantial relief within minutes of administration of these medicines. The patient was transported to the emergency department for monitoring and had no further reaction. After discharge, she noted erythema and hives around the site of injection, which were nearly resolved by the time of our evaluation 2 days later.

Two years earlier, she noted a large hive at the site of injection that took days to resolve after receiving preservative-free quadrivalent influenza vaccine, Fluarix (Rockville, MD, GlaxoSmithKline) without associated systemic symptoms. Two months before the anaphylaxis event, she received Afluria (Summit, NJ, Seqirus), quadrivalent preservative-free influenza vaccine. Again, she noted a large local hive at the site of injection (Fig. 1) without a systemic reaction. She also described a history of childhood asthma and eczema, but had never had an episode of anaphylaxis. She lastly described a greater than 10-year history of inducible episodes of pruritus, swelling, and hives that were most notable at times of sweating (Fig. 1). She noted an inability to take warm showers as well as limitations with exercise due to pruritus and hives in what was suspicious for cholinergic urticaria.

We performed an examination, laboratory studies, and several procedures for evaluating her anaphylaxis episode. Laboratory evaluation showed elevation in c-reactive protein (CRP) (1.27 mg/dL) 2 days following immunization,

*Department of Allergy and Immunology, Walter Reed National Military Medical Center, Bethesda, MD 20892, USA

†Defense Health Agency Immunization Healthcare Division, Walter Reed National Military Medical Center, Bethesda, MD 20892, USA

The views expressed are solely those of the authors and do not reflect the official policy or position of the U.S. Army, the U.S. Navy, the U.S. Air Force, the Department of Defense, or the U.S. government.

doi:10.1093/milmed/usab138

Published by Oxford University Press on behalf of the Association of Military Surgeons of the United States 2021. This work is written by (a) US Government employee(s) and is in the public domain in the US.



FIGURE 1. Prior patient reactions and cholinergic urticaria exercise provocation test. Left Upper: Large local hive after influenza vaccine. Left Lower: Prior cholinergic urticaria around the cheeks triggered by heat. Middle: Baseline skin before cholinergic urticaria exercise provocation test. Right: Urticaria in face and arms after exercise provocation challenge.

negative chronic urticaria (CU) index (4.3), and IgE levels (74.98 IU/mL) within the reference range. Dermatographism was not present. Skin examination revealed no skin findings of cutaneous mastocytosis. Serum tryptase was 4.7 $\mu\text{g/L}$ and 5.4 $\mu\text{g/L}$ checked 7 and 26 days, respectively, after the event and was within reference range; tryptase was not checked before or during the event. The tryptase alpha/beta 1 (TPSAB1) copy number variation test did not reveal tandem duplication(s) of TPSAB1 by allele-specific PCR. Prick-puncture skin testing for polyethylene glycol, Prevnar 23 (Kenilworth, NJ, Merck), and Pfizer-BioNTech Covid-19 (New York, NY, Pfizer) was negative (Fig. 2).⁶ She scored 11 of 21 on the cholinergic urticaria disease severity standardized scale (Investigator Global Assessment), suggesting moderate level of the disease.⁷ We further confirmed cholinergic urticaria (Fig. 1) via exercise provocation challenge guided by a standardized protocol.⁷

Based on the history and findings, her systemic reaction after receiving the Covid-19 vaccine was most consistent with anaphylaxis from a severe episode of cholinergic urticaria. Cholinergic urticaria has a known association with anaphylaxis although most people usually have only cutaneous symptoms.⁵ Because of her newly diagnosed cholinergic urticaria and recent anaphylaxis episode, we recommended she carry an epinephrine auto-injector. We also recommended non-sedating antihistamine therapy for prevention of urticaria during bathing and exercise once she was done breastfeeding. Lastly, we recommended all vaccines including the second dose of the Covid-19 vaccine be administered under supervision in a cool room without excessive clothing. The protection data after a single dose of the vaccine was unclear at the time so administering a single dose was not considered ideal. Based on our evaluation and the patient's increased risk for SARS-CoV-2 exposure, she, after informed decision-making, accepted a second dose of the Pfizer-BioNTech Covid-19 vaccine. We recommended against pre-medications since we were able perform the challenge in a cool room and

confirm that she was not sweating or overheating. We also did not want to mask an IgE-mediated reaction in the event of false-negative skin testing. In addition, the patient did not want to use any antihistamines as her infant was not weaned and still breastfeeding. She tolerated her second dose, without premedication, exhibiting only transient, mild nausea and a sense of warmth, but without any objective findings.

Vaccines have an overall excellent safety profile^{4,8}; this includes data from Covid-19 vaccine clinical trials.¹⁻³ We highlight that our patient showed propensity for allergic reactions even before administration of the Covid-19 vaccine based on her localized reaction to the influenza vaccines and her history of cholinergic urticaria. It was important for us to evaluate whether IgE-mediated anaphylaxis might underlie her case. We showed that the patient had nonreactive skin testing with both 1:1 epicutaneous and 1:100 and 1:10 intradermal Covid-19 vaccine and drugs containing polysorbate 80 (Fig. 2).⁶ However, more data are needed to determine skin testing's role in predicting IgE-mediated Covid-19 vaccine allergy.

Likewise, evaluation of mast cell activation in addition to IgE-mediated allergy needs to be considered after any episode of anaphylaxis or potentially severe cutaneous reaction to Covid-19 vaccinations. Evaluations should include the evaluation of inducible urticaria disorders, hereditary alpha tryptasemia, mastocytosis, and idiopathic mast cell activation disorders. Assuming that immediate Covid-19 vaccine reactions correlate to an IgE-mediated allergy ignores other non-contraindicating etiologies and potentially erroneously denies patients the benefit of immunization.

Thus, the general public should be aware of immune conditions that may place a person at risk of anaphylaxis, but that these may not be specific to the Covid-19 vaccine. Distinctly, CDC guidance notes "If you had an immediate allergic reaction after getting a shot of a Covid-19 vaccine, you should not get a second shot of that vaccine, even if your allergic reaction was not severe enough to require emergency care."⁹

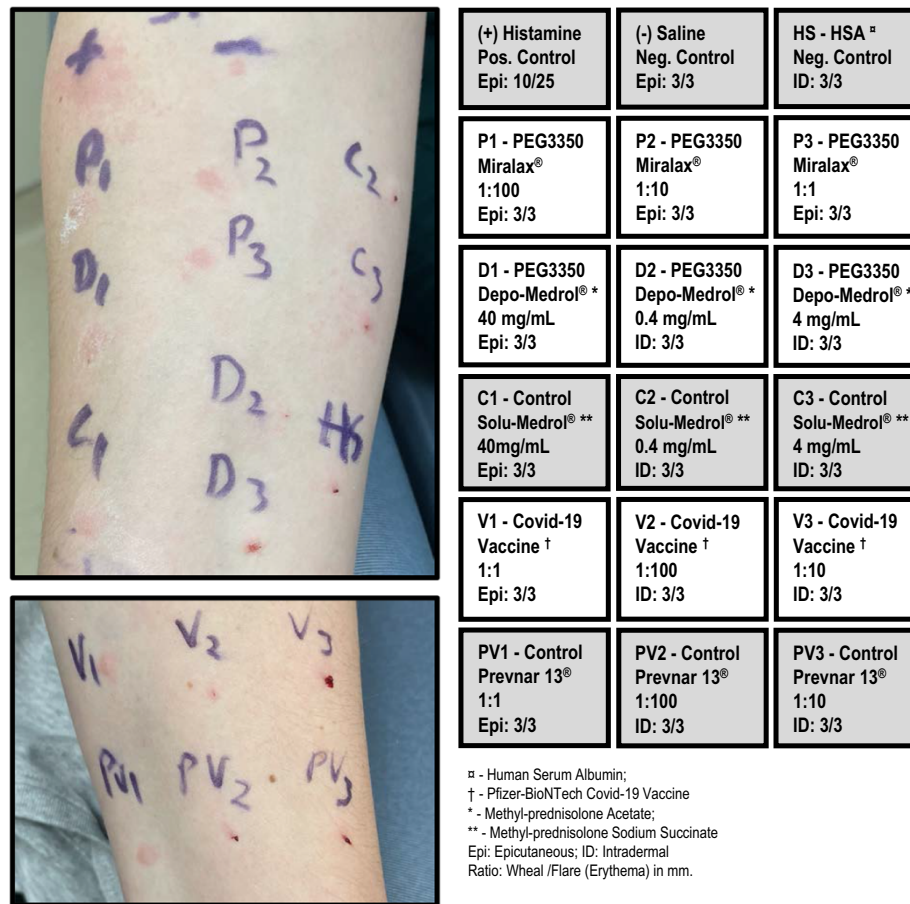


FIGURE 2. Skin test for Covid-19 vaccine and components. Left: Skin test results corresponding to components labels on right. Top Image is right arm. Bottom image is left arm. Right: Organized skin test panel with further component and administration details along with flare and wheal size. (Note: Actual test location varies to organized panel.).

The fact that our patient with a common mast cell disorder was able to safely receive the second dose of the Covid-19 vaccine following anaphylaxis suggests that anaphylaxis may not represent an absolute contraindication but validates the recommendation that these cases should be evaluated by an allergist and an immunologist for directed care and not be categorically denied the Covid-19 vaccine.

ACKNOWLEDGMENTS

The authors thank Dr. Jessica Wong-Flores, WRNMMC Investigational Pharmacy.

FUNDING

None declared.

CONFLICT OF INTEREST STATEMENT

None declared.

REFERENCES

1. Oliver SE, Gargano JW, Marin M, et al: The Advisory Committee on Immunization Practices' interim recommendation for use of Pfizer-BioNTech COVID-19 vaccine - United States, December 2020. MMWR Morb Mortal Wkly Rep 2020; 69(50): 1922-4.

2. Oliver SE, Gargano JW, Marin M, et al: The Advisory Committee on Immunization Practices' interim recommendation for use of Moderna COVID-19 vaccine - United States, December 2020. MMWR Morb Mortal Wkly Rep 2021; 69(5152): 1653-6.
3. Polack FP, Thomas SJ, Kitchin N, et al: Safety and efficacy of the BNT162b2 mRNA Covid-19 vaccine. N Engl J Med 2020; 383(27): 2603-15.
4. McNeil MM, Weintraub ES, Duffy J, et al: Risk of anaphylaxis after vaccination in children and adults. J Allergy Clin Immunol 2016; 137(3): 868-78.
5. Vadas P, Sinilaite A, Chaim M: Cholinergic urticaria with anaphylaxis: an underrecognized clinical entity. J Allergy Clin Immunol Pract 2016; 4(2): 284-91.
6. Banerji A, Wickner PG, Saff R, et al: mRNA vaccines to prevent COVID-19 disease and reported allergic reactions: current evidence and approach. J Allergy Clin Immunol Pract 2020 Online ahead of print.
7. Altrichter S, Salow J, Ardelean E, Church MK, Werner A, Maurer M: Development of a standardized pulse-controlled ergometry test for diagnosing and investigating cholinergic urticaria. J Dermatol Sci 2014; 75(2): 88-93.
8. Dudley MZ, Halsey NA, Omer SB, et al: The state of vaccine safety science: systematic reviews of the evidence. Lancet Infect Dis 2020; 20(5): e80-9.
9. Centers for Disease Control and Prevention: What to do if you have an allergic reaction after getting a COVID-19 vaccine. Available at <https://www.cdc.gov/coronavirus/2019-ncov/vaccines/safety/allergic-reaction.html>; accessed March 8, 2021.