



Endovascular Treatment of Iatrogenic Iliac Vein Rupture during Total Hip Arthroplasty: A Case Report

고관절치환술 중 발생한 의인성 장골 정맥 파열의
인터벤션 치료: 증례 보고

Dong Hyuk Yang, MD, Suyoung Park, MD*,
Jeong Ho Kim, MD, Jung Han Hwang, MD

Department of Radiology, Gil Medical Center, Gachon University College of Medicine, Incheon, Korea

Received January 7, 2024
Revised February 10, 2024
Accepted March 15, 2024
Published September 25, 2024

*Corresponding author
Suyoung Park, MD
Department of Radiology,
Gil Medical Center,
Gachon University College of Medicine,
21 Namdong-daero 774beon-gil,
Namdong-gu, Incheon 21565, Korea.

Tel 82-32-460-3063
Fax 82-32-460-3065
E-mail hwp20@gilhospital.com

This is an Open Access article distributed under the terms of the Creative Commons Attribution Non-Commercial License (<https://creativecommons.org/licenses/by-nc/4.0>) which permits unrestricted non-commercial use, distribution, and reproduction in any medium, provided the original work is properly cited.

We present a case of iatrogenic iliac vein rupture with venous thrombosis during total hip arthroplasty that was endovascularly treated with the insertion of covered and uncovered stents, aspiration, and balloon maceration of the thrombus. We describe in detail, with a schematic diagram, an endovascular treatment method that can be performed under local anesthesia alone and explain how to overcome the situation when the diameter of the covered stent is inadequate to cover the iliac vein.

Index terms Iatrogenic Disease; Endovascular Procedures; Arthroplasty; Hip Prosthesis

INTRODUCTION

Iatrogenic iliac vein injury during total hip arthroplasty (THA) is rare, but can be fatal (1). Clinical diagnosis may be delayed, especially when venous bleeding is insufficient to cause cardiovascular compromise (2). The injury can spontaneously heal through venous thrombus formation. However, urgent treatment may be required when conservative management is ineffective. In this report, we describe a case of iatrogenic iliac venous injury during THA treated with endovascular management, with procedural details.

CASE REPORT

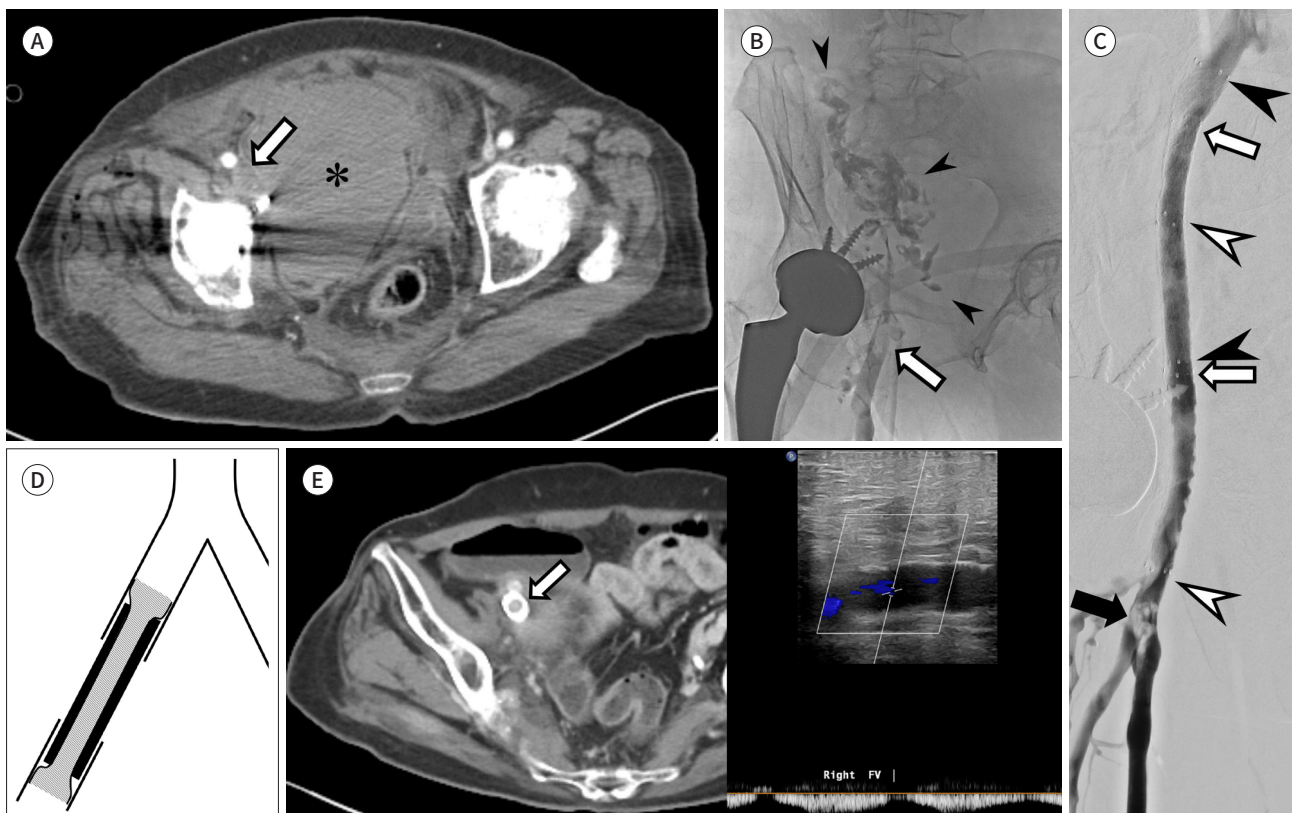
A 79-year-old female with right hip osteoarthritis underwent right THA. Her blood

pressure level decreased to 70/40 mmHg during surgery and did not fully recover despite fluid resuscitation therapy. Her serum hemoglobin concentration decreased from 11.7 to 7.7 g/dL. Contrast-enhanced abdominopelvic CT performed 1 day after surgery showed a large retroperitoneal hematoma in the right pelvic cavity, and venous thrombosis in the right external iliac vein (EIV) was suspected (Fig. 1A). Moreover, there was no evidence of contrast medium extravasation inside or around the hematomas. Although this may have been a state of extrinsic compression caused by the surrounding hematoma, considering the clinical findings, injury to the right EIV could not be excluded. Surgical exploration was considered; however, the patient refused additional surgical treatment. Therefore, an endovascular treatment was planned.

The patient was placed in the prone position in the angiography room of the interventional

Fig. 1. Interventional treatment of iatrogenic iliac venous injury in a 79-year-old female.

- A.** A preprocedural CT axial scan with a 70-sec delay contrast enhancement shows a large hematoma (asterisk) in the retroperitoneum of the right pelvic cavity and the absence of contrast filling in the right external iliac vein (arrow).
- B.** A 40-degree right posterior oblique venogram of the right common femoral vein shows contrast media extravasation into the pelvic cavity (arrowheads) and deep venous thrombosis (arrow) distal to the injured site, suggestive of iliac venous injury.
- C.** A digital subtraction venogram obtained just after the insertion of the stents shows improved venous drainage without evidence of contrast media extravasation. The ends of the covered stent are indicated by white arrows, whereas the ends of the proximal uncovered stent are marked with black arrowheads, and the ends of the distal uncovered stent are labeled with white arrowheads. Additionally, the remaining thrombus in the right femoral vein is indicated by a black arrow.
- D.** In the schematic diagram, the covered stent is indicated as a thick black line, and the uncovered bare-metal stents are indicated with a slash.
- E.** Six-month follow-up contrast-enhanced CT axial scan (left) and venous Doppler ultrasound (right) show a patent lumen (arrow) without evidence of stent migration.



radiology department. The right popliteal vein was punctured under ultrasonographic guidance, and a 9-Fr sheath (Glidesheath; Terumo Interventional Systems, Somerset, NJ, USA) was inserted. Venography showed massive contrast medium extravasation in the right EIV, but the right common iliac vein (CIV) and inferior vena cava (IVC) were not opacified, indicating complete rupture of the right EIV (Fig. 1B). Antegrade cannulation of the right CIV was unsuccessful, and retrograde cannulation through contralateral access was planned.

The left popliteal vein was punctured under ultrasonographic guidance, and along this route, a retrievable filter was inserted into the infrarenal IVC (Denali; BD, Tempe, AZ, USA) to prevent pulmonary artery embolism that might have occurred during the procedure. Retrograde cannulation of the right distal EIV failed and a rendezvous technique in the third space (retroperitoneum) was planned.

A guidewire was placed in the third space through the retrograde route, and a 10-mm loop snare and a 4-Fr snare catheter kit (Amplatz Goose Neck Snare Kit; Medtronic, North Plymouth, MN, USA) were placed in the same space through the antegrade route. By capturing the guidewire with a snare, the guidewire could pass through the lesion and enter the right CIV beyond the lesion in the EIV.

Through the guidewire, a 10-mm × 10-cm self-expandable covered stent (Covera; BD) was inserted to cover the rupture site of the right EIV, and then two 14-mm × 10-cm self-expandable uncovered bare-metal stents (E-luminexx; BD) were inserted into the right CIV, covered stent, and right distal common femoral vein (CFV) to prevent migration of the covered stent (Fig. 1C, D). The remaining small amount of thrombus was removed via aspiration thrombectomy using an 8-Fr guiding catheter (Mach 1; Boston Scientific, Natick, MA, USA) and balloon maceration using a 12-mm balloon catheter (Armada 35; Abbott Vascular, Abbott Park, IL, USA). Insertion of the two stents, balloon catheters, and guiding catheter was performed using the right popliteal vein access route. The venous flow improved, and completion venography revealed no venous bleeding (Fig. 1C). A 6-month follow-up CT venography and Doppler ultrasonography showed a patent stent lumen with no evidence of active bleeding (Fig. 1E).

This study was approved by the Institutional Review Board (IRB No. GDIRB2022-302).

DISCUSSION

This report describes the treatment of iliac venous injury using a combination of covered and bare-metal stents. Iatrogenic injury of the iliac vein during THA may be overlooked as it is rare and hemorrhage occurs in the retroperitoneal space (3), especially if venous bleeding is insufficient to cause cardiovascular compromise (2). If there is a partial venous rupture and the distal part can be selected with a guidewire, venous hypertension can be resolved by improving venous flow through the placement of an uncovered bare-metal stent (1, 4, 5). Additionally, case series regarding the insertion of covered or uncovered stents and prolonged balloon tamponade in partial iliac venous injuries have also been reported using various methods (6).

However, in our case, the rendezvous technique was performed using a snare, because the iliac vein was completely disrupted, and the distal part could not be selected. In this case, we inserted a covered stent because the area captured by the snare might have been outside the

iliac vein; therefore, the bare-metal stent could not prevent bleeding.

Raju et al. (7) reported that the optimal stent diameters in the common iliac, external iliac, and CFV segments were 16, 14, and 12 mm, respectively. Iliac vein stent migration is a rare complication that is likely to be underreported owing to publication bias (8). Known risk factors for iliac vein stent migration include a short length of 60 mm or less and a smaller diameter of 14 mm or less. However, there may be situations in various countries or hospitals in which it is not possible to use these large-diameter covered stents owing to insurance coverage or device supply issues. Furthermore, in our case, a 10-mm covered stent was inserted because a covered stent with a larger diameter was not available for emergent use. Therefore, additional procedures are needed to reduce the migration risk. For this reason, two uncovered bare-metal stents with a 14-mm diameter were inserted into the covered stent, covering the proximal and distal parts of the native vein (Fig. 1D), to form a stent resembling a double-bare, covered biliary stent (9). Although not performed in our case, there may be methods to prevent or minimize covered stent migration between the insertion of the covered and bare-metal stents. For example, balloon dilation at the right CIV before stent insertion may prevent stent migration into a central vein, such as the IVC. Additionally, balloon dilation at the right CFV could potentially block or significantly reduce venous flow, which could trigger stent migration, thereby reducing the risk of stent migration.

In conclusion, we successfully treated a patient with complete iatrogenic iliac venous rupture and venous thrombosis using the rendezvous technique, insertion of covered and uncovered stents, and subsequent aspiration thrombectomy and balloon maceration. This can be an alternative technique when there is a need to urgently insert a covered stent in the iliac vein, but a stent with an appropriate diameter is not available, necessitating the insertion of a smaller-caliber stent.

Author Contributions

Conceptualization, P.S.; resources, K.J.H., H.J.H.; writing—original draft, Y.D.H.; and writing—review & editing, P.S.

Conflicts of Interest

The authors have no potential conflicts of interest to disclose.

ORCID iDs

Dong Hyuk Yang  <https://orcid.org/0000-0002-2901-3775>

Suyoung Park  <https://orcid.org/0000-0001-9688-3239>

Jeong Ho Kim  <https://orcid.org/0000-0002-1404-2821>

Jung Han Hwang  <https://orcid.org/0000-0002-0872-0956>

Funding

None

REFERENCES

1. Kataoka Y, Maekawa K, Nishimaki H, Yamamoto S, Soma K. Iliac vein injuries in hemodynamically unstable patients with pelvic fracture caused by blunt trauma. *J Trauma* 2005;58:704-708; discussion 708-710
2. Ayob KA, Merican AM, Sulaiman SH, Hariz Ramli AR. The tale of two vessels, vascular complications following a breach of the pelvic inner table due to acetabular screws: a report of two cases. *Jt Dis Relat Surg* 2021; 32:239-244

3. Ohashi H, Kikuchi S, Aota S, Hakozaiki M, Konno S. Surgical anatomy of the pelvic vasculature, with particular reference to acetabular screw fixation in cementless total hip arthroplasty in Asian population. *J Orthop Surg (Hong Kong)* 2017;25:2309499016685520
4. Sofue K, Sugimoto K, Mori T, Nakayama S, Yamaguchi M, Sugimura K. Endovascular uncovered Wallstent placement for life-threatening isolated iliac vein injury caused by blunt pelvic trauma. *Jpn J Radiol* 2012;30:680-683
5. Cha JG, Lee SY, Hong J, Park JM, Lim KH, Kim D. Traumatic iliac vein rupture managed using a bare-metal stent. *Trauma Case Rep* 2021;37:100589
6. Schoeff JE, Israel TR, Green TJ, Weaver JS, Zarkowsky DS. Expedient endovascular hemorrhage control during anterior lumbar spinal exposure allows procedural completion in rescued patients. *Ann Vasc Surg* 2022;78:377.e5-377.e10
7. Raju S, Buck WJ, Crim W, Jayaraj A. Optimal sizing of iliac vein stents. *Phlebology* 2018;33:451-457
8. Sayed MH, Salem M, Desai KR, O'Sullivan GJ, Black SA. A review of the incidence, outcome, and management of venous stent migration. *J Vasc Surg Venous Lymphat Disord* 2022;10:482-490
9. Ogura T, Nishioka N, Yamada M, Yamada T, Higuchi K. Comparison study between double bare covered and fully covered metal stent during endoscopic ultrasound-guided choledochoduodenostomy (with video). *Dig Dis* 2021;39:165-170

고관절치환술 중 발생한 의인성 장골 정맥 파열의 인터벤션 치료: 증례 보고

양동혁 · 박수영* · 김정호 · 황정한

저자들은 고관절치환술 중 발생한 의인성 장골 정맥 파열과 정맥 혈전증을 커버드 스텐트(covered stent)와 언커버드 스텐트(uncovered stent 또는 bare metal stent)의 삽입과 혈전의 흡인 및 풍선 파쇄로 인터벤션 치료한 사례를 소개하고자 한다. 국소 마취만으로 시술할 수 있는 인터벤션 치료 방법에 대해 자세히 설명하고, 커버드 스텐트의 지름이 장골 정맥을 충분히 덮지 못하는 상황에 대한 극복 방법을 모식도와 함께 설명하였다.

가천대학교 의과대학 길병원 영상의학과