

# Gasless minimum incision access used for extracorporeal orthotopic bladder substitution after laparoscopic radical cystectomy

Vasilii N. Dubrovin, Alexey Tabakov, Alexander Egosin, Rustam Shakirov, Oleg Mihailovskiy, Valeriy Bashirov

State Financed Health Institution of the Republic of Mari El "Republican Clinical Hospital", Yoshkar-Ola, Russia

## Article history

Submitted: March 23, 2014

Accepted: June 14, 2014

## Correspondence

Vasilii Dubrovin  
 Republic Clinical Hospital  
 33, Osipenko Street  
 424000 Yoshkar-Ola,  
 Russia  
 phone: +79 613 793 500  
 vndubrovin@mail.ru

**Introduction** Radical cystectomy is the gold standard for treating invasive bladder cancer. We report our outcomes of gasless minimum incision access (GMIA) for extracorporeal orthotopic bladder substitution (ECOBS) after laparoscopic radical cystectomy.

**Material and methods** Radical surgery was performed in patients in the same hospital suffering from bladder cancer in T2N0M0 G1–2 stage. Group 1 included 11 patients aged 56.6 (42–72) years, which underwent laparoscopic radical cystectomy and ECOBS using GMIA. Group 2 included 18 patients aged 56.7 (41–76) years, which were operated by open radical cystectomy and orthotopic bladder substitution.

**Results** The average duration of operation was 492.0 ±85.7 minutes in Group 1 and 318.0 ±58.0 in Group 2 ( $p = 0.001$ ). Estimated blood loss was 290.0 ±120.0 and 613.2 ±359.0 ml in groups respectively. In the postoperative period, narcotic analgesics were used in the amount of 166.0 ±28.0 mg and 264.0 ±112.0 mg ( $p = 0.05$ ), intestinal function recovery was observed on 3.5 ±0.9 and 6.0 ±2.9 days after the operation ( $p = 0.05$ ) in the groups respectively. Minor postoperative complications were observed in 36.4% and 56.0%, major complications – in 9.1% and 11.2% in groups respectively. Median hospitalization time was 19.0 ±2.0 days in Group 1 and 24.9 ±6.5 in Group 2 ( $p = 0.01$ ).

**Conclusions** GMIA in ECOBS can be used as an effective surgical approach after laparoscopic radical cystectomy; this method requires further observation.

**Key Words:** laparoscopic radical cystectomy ◊ extracorporeal orthotopic bladder substitution ◊ gasless single-port access

## INTRODUCTION

Open radical cystectomy (ORC) and ortotopic bladder substitution is the gold standard of the treating muscle-invasive bladder cancer, although the operation itself may have long-term negative impact on intestinal loops that results in long-term paralytic ileus and small bowel obstruction in postoperative period [1, 2].

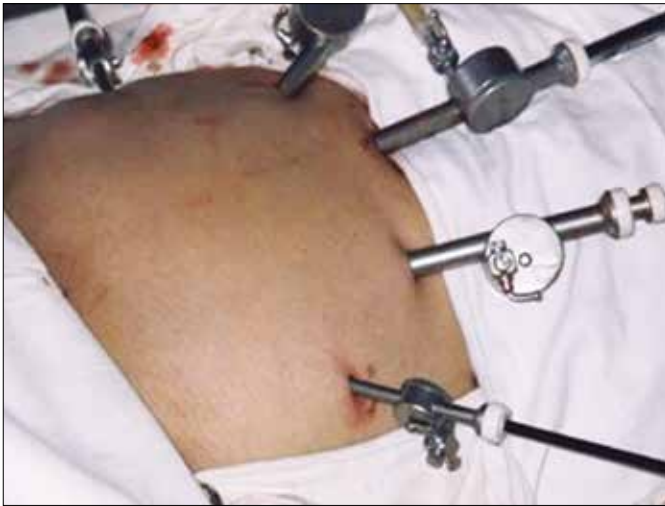Development oncurology laparoscopic surgery reduces the amount of certain complications including in the radical surgical treatment of invasive bladder cancer. Interest in laparoscopic radical cystectomy (LRC) is increasing at select centers worldwide. In

the literature discusses options for access for the bladder substitution after the LRC. The bladder substitution performed using extracorporeal or intracorporeal approach [3].

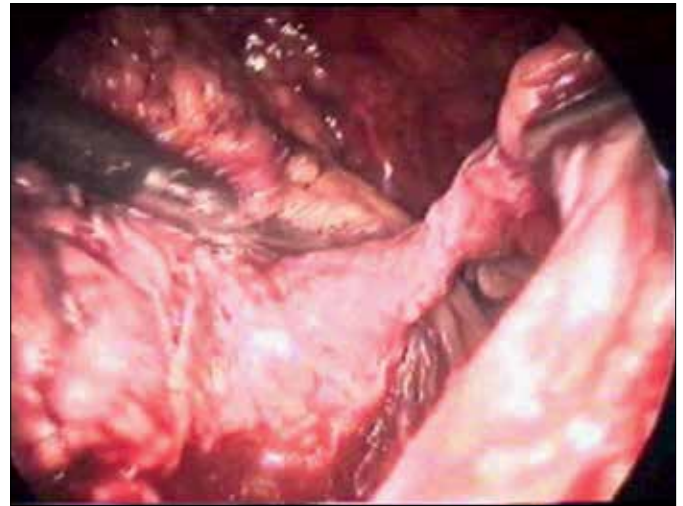In our work we used gassless minimum incision access (GMIA) for extracorporeal ortotopic bladder substitution (ECOBS) after LRC.

## MATERIAL AND METHODS

Between June 2004 and May 2012, we performed 11 LRC with ECOBS by Studer's method (Group 1) mean age of the patients was 56.6 (42–72) years. Results were retrospective compared with 18 open radi-



**Figure 1.** Installation of the trocars.



**Figure 2.** Prevesical segment of the ureter was mobilized.

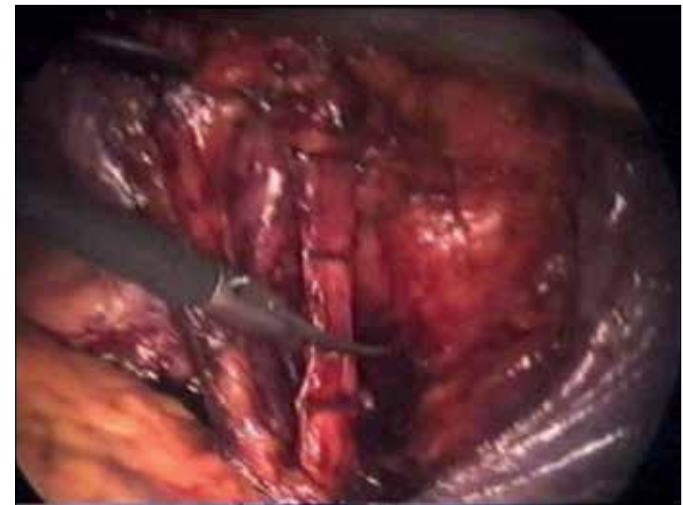cal cystectomy and Studer's ortotopic bladder substitution (Group 2), mean age was 56.7 (41–76) years. All patients were male, without signs of obesity.

Patients in all groups underwent standard clinical examination with the diagnosis of stage T2N0M0 G1–2 bladder cancer. The depth of tumor invasion in the bladder wall was detected by MR–imaging or computer tomography scan, the lesion in the prostatic urethra by transurethral resection. The patients included in the research didn't feature distant metastasis, lesion in the prostatic urethra or characters of ureteral obstruction. Both groups included patients with normal kidney function (serum creatinine with maximum 140 mmol/l), normal liver function, normal function of cardiovascular and respiratory system, as well as mental ability to live with neobladder. The patients had no obesity any stage of their life and operations on abdominal cavity organs in the medical history.

In the 1 group of patients urothelial cell carcinoma was present in all cases, Grade 1 in 10 (90.9%), Grade 2 – in 1 cases (9.1%). In the 2 group urothelial cell carcinoma was present in all cases too, Grade 1 – in 15 (83.3%) and Grade 2 – in 3 (16.7%) cases.

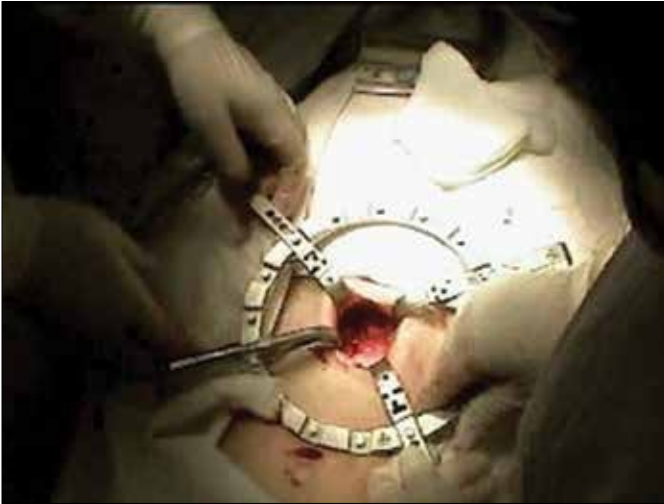
### Operation method

The operation was performed under general anesthesia with controlled respiration and prolonged epidural anesthesia. To perform laparoscopic radical cystectomy 5 trocars were used (3–10 mm and 2–5 mm) (Figure 1). After installation of trocars and creating carboxyperitoneum, taking into account the disease state a limited pelvic lymph node dissection proximally to the bifurcation of the common iliac vessels was performed. Further the lower segments of ureter were detected below the point of intersection with

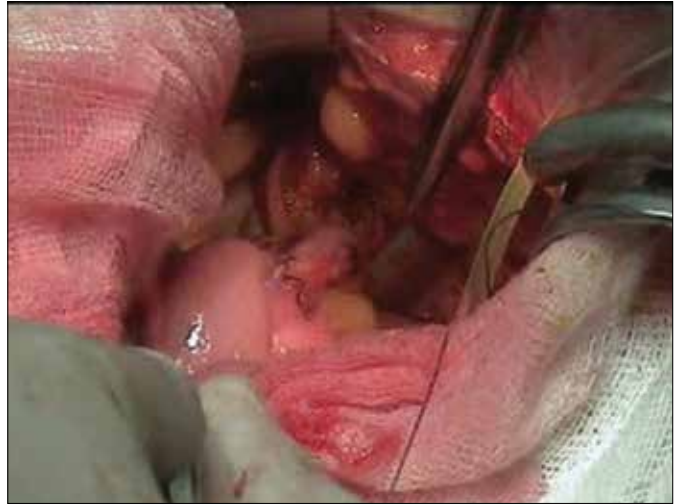

**Figure 3.** Bladder artery clipped with titanium clips.

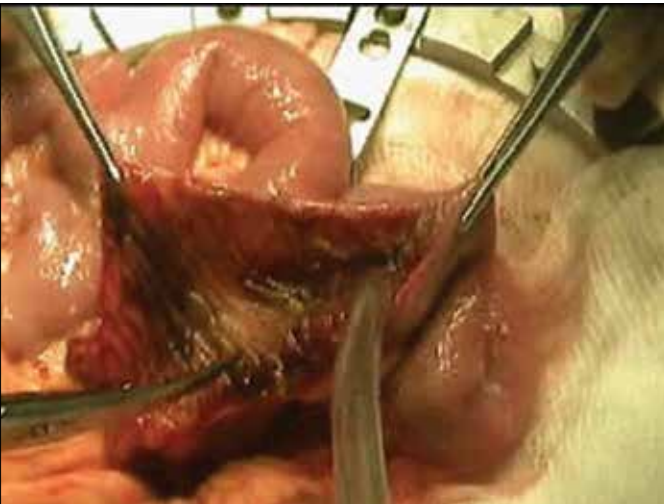common iliac vessels in prevesical segment. (Figure 2). Ureter was allocated, mobilized for the length of 10 cm, crossed, distal part of ureter wall was histopathologically examined. The Ductus deferens were transected, bladder vessels were allocated, clipped and crossed with “Harmonic” scalpel or clipped with titanium clips (Figure 3). Vessels of the bladder are allocated, clipped and crossed, bladder side walls were mobilized. After abdominal membrane opening between bladder and straight intestine the posterior bladder wall and seminal gland were detected. Prostate was mobilized, dorsal venous complex was stitched up and transected, urethra was transected. Further a neobladder was created by GMIA. Should the laparoscopic stage of operation exceed 4 hours the second stage of operation was performed by another team of surgeons.



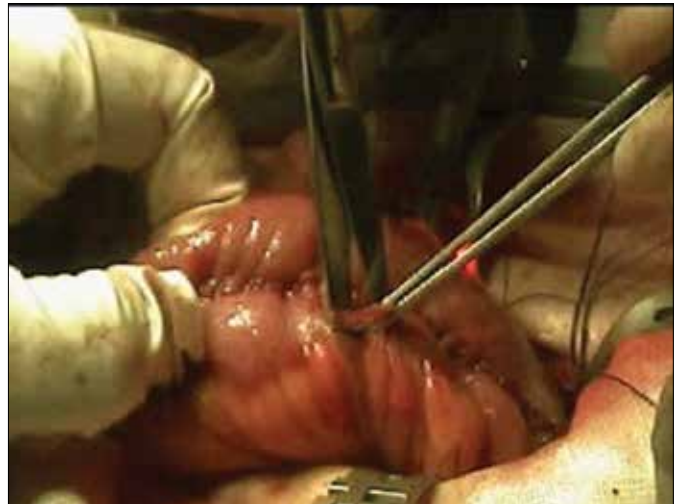**Figure 4.** Installation of the retractor for single port.



**Figure 6.** The ureteral-intestinal anastomoses.



**Figure 5.** Extracorporeal formation of neobladder.



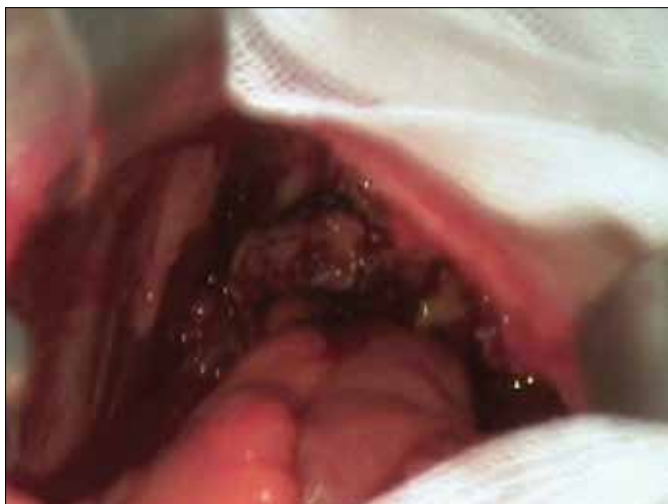**Figure 7.** Artificial bladder neck.

During the second stage of operation the tools for GMIA were used including circle-retractor with a set of spatula – expanders optimizing minimum incision access. One of spatulas was equipped with a light guide for illumination of the surgical space. To provide additional lightning a laparoscope was also used in single port. To perform an operation with minimum invasion a set of surgical instruments with a curve were used not to block the view of the surgical space for the surgeon. An inferomedian mini-laparotomy was performed with the length of incision of 4–5 cm and retractor was installed (Figure 4). The instruments for the minimum invasion were allocated, after which the bladder, prostate gland with spermatocyst were removed from abdominal cavity. The single port was used to input a loop of terminal section of ileum 40–50 cm long taken at

a distance of 40 cm from the cecum to form neobladder reservoir. To resume the intestine continuity the end-to-end entero-anastomosis suture was inserted and then the intestine was returned back into abdominal cavity. The selected segment was placed into the wound, partially dissected and using the single-layer continuous suture Studer's neobladder was formed (Figure 5). The reservoir was returned to the abdominal cavity and end-to-side ureteral-intestinal anastomoses without antireflux protection were performed (Figure 6).

Ureters were drained up to renal pelvis by means of ureteral catheter (5 Fr) which exteriorized through an opening of the neobladder wall meant for anastomosis with urethra (Figure 7). Then intestinal-urethral anastomosis was applied in one line with 5 interrupted sutures, ureteral catheters and Foley





**Figure 8.** *Intestinal–urethral anastomosis.*

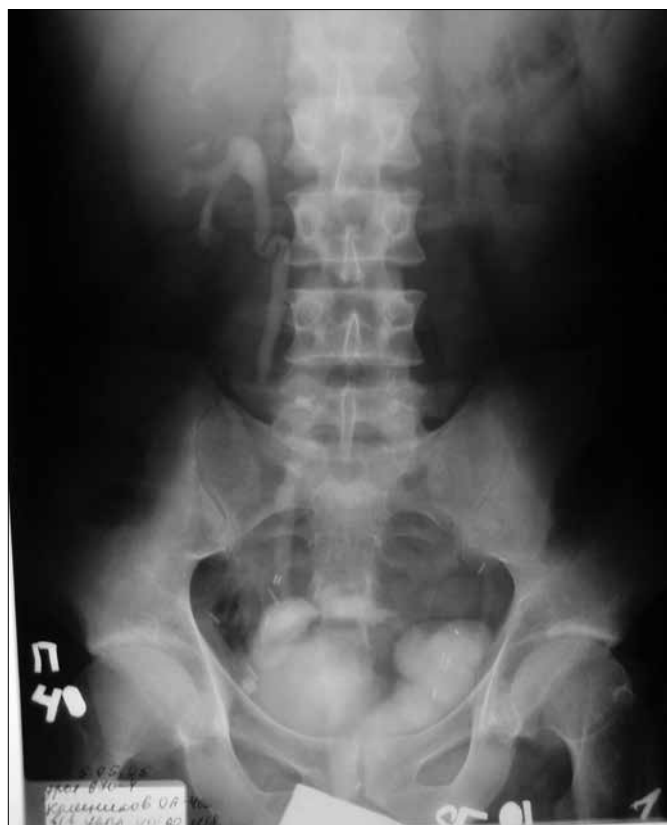catheter No 20–22 meant for neobladder drainage were installed through urethra (Figure 8).

The Group 2 included patients, sick with cancer in  $\square 2N0M0$  G1–2 stage who underwent traditional “open” operation – radical cystectomy and extracorporeal ortotopic Studer’s bladder substitution. The second group included 18 male patients. Traditional operation was performed by laparotomy and the basic stages of operation were the same as in classic radical cystectomy [4].

In postoperative period all the patients had antibacterial therapy, stimulation of intestinal peristaltic, fluid therapy, prevention of thromboembolism. Urethral drainage was removed on 14–16th day after the operation. To evaluate the functionality of urinary system the excretory urography was performed. The results of laparoscopic and open operations were evaluated by intraoperative (duration of operation, hemorrhage) and postoperative indicators (positive surgical margins, length and dosage of postoperative analgesia with narcotic analgesics, amount of blood transfusion during and after the operation, term of resuming the intestine peristaltic) with using Clavien’s system and hospitalization time after the operation.

## RESULTS

The average duration of operation in Group 1 was  $492.0 \pm 85.7$  (310–600) minutes, hemorrhage recorded on average in the amount of  $290.0 \pm 120.0$  (120–510) ml. Blood transfusions were performed in the average amount of  $183.0 \pm 168.4$  (0–340) ml. In postoperative period extended epidural anesthesia was applied using narcotic analgesic (sol. promedoli) on average  $166.0 \pm 28.0$  (140–220) mg were applied. Intestinal distention lasted for 3.5 (2–5) days. Drainage was



**Figure 9.** *Plain x–ray after LRC and ECOBS.*

removed from ureter on 12–14th day after the operation, Foley catheter was removed on 14–16th day after the operation (Figure 9). After removing urethral drainage all the patients resumed urination with continence function. The average hospitalization time after the operation was  $19.0 \pm 2.0$  (17–22) days. The average duration of open operation in Group 2 was  $318.0 \pm 58.0$  (240–440) min. Hemorrhage after such type of invasion was on average  $630.0 \pm 359.0$  (200–2000) ml. Blood transfusion was performed in the average amount of  $618.4 \pm 216.0$  (0–800) ml. Extended epidural anesthesia was applied for 3–5 days using narcotic analgesic (sol. promedoli) on average  $264.0 \pm 112.0$  (140–660) mg were applied. Intestinal distention lasted on average for  $6.0 \pm 2.9$  (4–9) days. The average hospitalization time after the operation in Group 2 patients was on average  $24.9 \pm 6.5$  (15–38) days. The compared mean values of the indicators under study are presented in Table 1.

In our study we had no positive surgical margins after surgery in all groups of the patients. In the 1 group stage pT2N0M0 was detected in 9 (81.8%) cases, pT3N0M0 – in 1 (9.1%), pT3N1M0 – in 1 (9.1%). In group 2 stage pT2N0M0 was detected in 12 (66.7%) cases, pT3N0M0 – in 4 (22.2%), pT3N1M0 – in 2 (11.1%) cases.

We studied and evaluated by Clavien's classification early complications within 90 days after surgery. In Group 1 there was no mortality cases recorded. One patient (9.1%) developed dehiscence of urethral intestinal anastomosis which required relaparotomy and reurethroenterostomy. One patient (9.1%) developed intestine reservoir failure cured by prolonged urethral drainage (18 days).

In Group 2 one patient (5.6%) died because of pulmonary embolus. One patient (5.6%) developed entero-enteroanastomosis failure cured by relaparotomy, reapplying entero-enteroanastomosis. One patient (5.6%) was reoperated for adhesive intestinal obstruction, one patient (5.6%) developed lower lobe pneumonia on the right side, one patient (5.6%) developed intestine reservoir failure resolved by prolonged urethral drainage (20 days). All complications after surgery in all Groups present in the table 2.

## DISCUSSION

The first reported laparoscopic radical cystectomy (LRC) for muscle-invasive bladder cancer with ileal conduit was performed by Sanchez de Badajoz et al. in 1995 [5]. M. Kozminski et al. (1992) reported about laparoscopic ileal conduit without cystectomy [6]. In 1995 Puppo et al. described five cases of a combined laparoscopic and transvaginal anterior pelvic exenteration for bladder cancer [7]. In 2001 Turk et al. used a completely intracorporeal LRC with a continent urinary diversion (rectal sigmoid pouch) in 5 cases [8]. Gill et al. performed the first purely laparoscopic ileal conduit urinary diversion surgery and the first purely laparoscopic orthotopic Studer neobladder reconstruction surgery in 2000 and 2002 [9]. Laparoscopic radical cystectomy (LRC) procedures are increasingly being performed as minimally invasive surgical approaches and seems to have excellent short-term surgical, pathological outcomes and satisfactory functional results. Authors reported, that LRS has the advantages of decreased blood loss, faster recovery of intestinal function, decrease in pain and analgesic use after surgery [2].

Since the first LRC there have been numerous descriptions of procedures with extracorporeal and intracorporeal bladder substitution with fewer cases of postoperative complications [10, 11, 12]. The most common types of urinary diversion techniques included orthotopic neobladder reconstruction (53%) and ileal conduit diversion (35%). The urinary diversion was performed extracorporeally in 89% and intracorporeally in 11% [13]. The advantages of intracorporeal method of bladder substitution were sufficiently described in literature, although this

**Table 1.** Comparative characteristics of indicators in Group 1 and Group 2

Mean values	Group 1 (n=11)	Group 2 (n=18)	Statistical significance, p
Duration of operation (min)	492.0 ±85.7 (310–600)	318.0 ±58.0 (240–440)	0.001
Hemorrhage (ml)	290.0 ±120.0 (120–510)	613.2 ±359.0 (200–2000)	0.01
Enteroparesis (days)	3.5 ±0.9 (2–5)	6.0 ±2.9 (4–9)	0.05
Blood transfusion (ml)	183.0 ±168.4 (0–340)	618.4 ±216.0 (0–800)	0.05
Narcotic analgesics (mg)	166.0 ±28.0 (160–320)	264.0 ±112.0 (140–660)	0.05
Length of hospitalization (days)	19.0 ±2.0 (17–22)	24.9 ±6.5 (15–38)	0.01
Mortality (abs/%)	0	1/5.6	–

### Complications in all Groups

Grade	Complications	Group 1 No. (%)	Group 2 No. (%)	Treatment
I	Wound infection (superficial)	–	1(5.6)	Conservative
	Lymphorrea	1 (9.1)	2 (11.2)	Conservative
	Paralytic ileus	1 (9.1)	2 (11.2)	Conservative
	Pyelonephritis	–	2 (11.2)	Antibacterial therapy
II	Metabolic acidosis	1 (9.1)	1 (5.6)	Medication
	Pneumonia	–	1 (5.6)	Antibacterial therapy
	Urine leak (pouch leak)	1 (9.1)	1 (5.6)	Prolonged drainage
III	Enteroanastomosis leak	–	1 (5.6)	Relaparotomy
	Small bowel obstruction	–	1 (5.6)	Relaparotomy
	Ureterointestinal leakage	1 (9.1)	–	Relaparotomy
V	Pulmonary embolus	–	1 (5.6)	Not applicable

method is more time consuming and requires the application of special tools and stapling instruments [9, 10]. In case of extracorporeal bladder substitution after laparoscopic stage of operation a standard laparotomy is required which reduces traumatic impact on intestine due to minimum invasive surgery [12]. Implementing gasless single-port surgical access in urology proved its efficiency when treating many illnesses including oncological ones [13]. The use of gasless single-port access allows perform extracorporeal bladder substitution after laparoscopic radical cystectomy [14]. Specific features of gasless sin-

gle–port access application are as follows: minimally invasive operation; application of special tools; additional lightning of operating room; absence of high CO<sub>2</sub> pressure in abdominal space and therefore no complications caused by this pressure occur [15].

In our study the results of 11 laparoscopic cystectomies with extracorporeal ortotopic bladder substitution performed by gasless single–port access (Group 1) were compared with 18 open cystectomies with intestinal neobladder (Group 2) provided patients selection. In both groups the method of Studer's bladder substitution was used. Due to preliminary selection of patients for procedure we didn't face any difficulties when performing all the stages of minimally invasive operations. Gasless single–port access provided with lightning of the surgery space and the use of special instruments which do not block the view for the surgeon provided good visual monitoring of manipulations which is especially important when applying anastomoses.

The length of mesentery in every case allowed to exteriorize the segment of intestine for forming neobladder. We used the approach of successive exteriorizing the part of intestine through gasless single–port access. Initially the intestine segment was exteriorized for entero–enteroanastomosis. After it was returned into the abdominal cavity a segment of intestine for forming the neobladder was exteriorized. Neobladder was formed by extracorporeal Studer's method and then returned back to the abdominal cavity to perform urethral–intestinal and intestinal–urethral anastomoses.

The method described allowed allocating transurethral and ureteral drainage and let them through the urethra. We consider it to be very important to drain upper urinary tracks and neobladder via urethra as it allows to form neobladder without additional openings for ureter catheters. This approach is always used in performing extracorporeal ortotopic bladder substitution.

Complications have been reported using Clavien's system. The Clavien's system for classifying surgical complications was originally developed in the 1990s for use in organ transplant surgery, and it was modified in 2004. Now, it probably represents the coming standard for both complications reporting and quality assessment. This system can be applied to all kinds of surgery in all parts of the world, and it has also been used in RC series [16, 17]. Postoperative complications were defined as complications occurring the first 90 days after surgery [1].

Observing short term and long term postoperative results proves the advantages of minimally invasive method which include: lower hemorrhage, smaller number of blood transfusions which results in the

**Table 2.** Complications in all groups

Grade	Complications	Group 1 No. (%)	Group 2 No. (%)	Treatment
I	Wound infection (superficial)	–	1 (5.6)	Conservative
	Lymphorrhea	1 (9.1)	2 (11.2)	Conservative
	Paralytic ileus	1 (9.1)	2 (11.2)	Conservative
II	Pyelonephritis	–	2 (11.2)	Antibacterial therapy
	Metabolic acidosis	1 (9.1)	1 (5.6)	Medication
	Pneumonia	–	1 (5.6)	Antibacterial therapy
III	Urine leak (pouch leak)	1 (9.1)	1 (5.6)	Prolonged drainage
	Enteroanastomosis leak	–	1 (5.6)	Relaparotomy
	Small bowel obstruction	–	1 (5.6)	Relaparotomy
	Ureterointestinal leakage	1 (9.1)	–	Relaparotomy
V	Pulmonary embolus	–	1 (5.6)	Not applicable

fact that video endoscopy provides a better view of the surgery space and thorough hemostasis is possible all through the operation [10].

In group 1 we found out that hemorrhage was lower in comparison with open cystectomy ( $290.0 \pm 120.0$  compared with  $613.2 \pm 359.0$ ;  $p = 0,01$ ), the amount of blood transfusions in group 1 is decreased in compared with a traditional operation ( $183.0 \pm 168.4$  and  $618.4 \pm 216.0$  respectively;  $p = 0.05$ ).

Careful intraoperative haemostasis is important, as is refinement in surgical techniques in order to decrease blood loss [18]. Most authors link reduce blood loss with better visualization during laparoscopic surgery and the use of modern methods of hemostasis, such as staplers, harmonic scalpel, bipolar cautery devices [19]. In our work we used harmonic scalpel, which provides good dissection and hemostasis in cystectomy. But we used the harmonic scalpel with operations in both groups of patients. Improving outcomes in group 1 explain better visualization during LRC.

Lawrentschuk N. et al. (2010) in collaborative review found 22.7% subileus and 7% small bowel obstruction after radical cystectomy with bowel bladder substitution. Shabsigh et al. proposed definition of ileus as inability to tolerate solid food by postoperative day five, the need to place a nasogastric tube or the need to stop oral intake due to abdominal distention, nausea or emesis. Paralytic ileus is a commonly observed within 3–5 d after major open ab-

dominal surgery. Modern concept of rapid recovery of small bowel motility and absorption within hours of surgery has propelled the early oral liquid diet, reducing the time of ileus [21].

We used the early administration of oral fluids (day 1) and, if successful, the early restoration of oral feeding in all groups of patients. In our study after minimum invasive operations (group 1) the patients normalized intestine functions after  $3.5 \pm 0.9$  days ( $6.0 \pm 2.9$  days in group 2;  $p = 0.05$ ), which is the result of low traumatic influence in operation on the intestinal loops.

After laparoscopic radical cystectomy and bladder substitution the postsurgical pain syndrome is less severe which reduced the order of narcotic analgesics ( $166.0 \pm 28.0$  in group 1 and  $264.0 \pm 112.0$  in group 2;  $p = 0.05$ ), that related to the low traumatic surgery. Among the postoperative complications considered minor complications – 1 – 2 categories and major complications – 3 – 5 categories by the Clavien classification. Demonstrated increase minor complications in Group 2, especially a significant increase was noted in the early minor complications: in the Group 1 – 36.4% with compared in Group 2 – 56.0%. Among the most significant minor complications we observed pouch leak in 1 (9.1%) of cases in group 1 and 1 (5.6%) – in group 2. Pouch leak were treated with prolonged drainage 18 and 20 days with positive effect.

Major complications that required reoperation in the early postoperative period, were more frequent in group 2 patients – in 2 (11.2%) patients and in group 1 in 1 (9.1%) patient. In the 1 group major early complication (ureterointestinal leak) we observed in 1 (9.1%) patient, relaparotomy was performed with good result. Enteroanastomosis leak was observed in 1 (5.6%) patient (group 2), we made relaparotomy, reanastomosis, with patient's recovery. Intestinal obstruction observed in 1 (5.6%)

in group 2, relaparotomy and separation of the intestine adhesions was performed with recovery of the patient. We use low-molecular-weight heparins and compression stockings as prophylactic treatment in all groups of the patients but 1 patient (5.6%) died of pulmonary embolism.

Faster post-operation recovery of internals and the function of urination improve patients' rehabilitation after minimally invasive operations. The average hospitalization time after minimum invasive operations is shorter than after analogous open procedures:  $19.0 \pm 2.0$  in group 1 and  $24.0 \pm 6.5$  in group 2 ( $p = 0.01$ ).

The method of LRC with GMIA to perform ECOBC has its disadvantages first of all connected with the necessity to select patients, as well as certain limitations of surgery itself (the method is not desirable to use in patients sings of obesity, in T3–T4 stages of cancer or on condition of local tumor metastasis). Long duration of laparoscopic cystectomy and minimally invasive bladder substitution in comparison with open operation is associated with manipulation difficulties in closed operational space, relatively low number of invasions, although as long as the surgeon gains experience the operation time reduces. Involving two teams of surgeons in performing one operation optimizes the surgery load.

## CONCLUSIONS

Combining laparoscopic cystectomy and extracorporeal bladder substitution using gasless single-port access allows use the advantages of minimum invasive operation, i.e. reducing intraoperative and postoperative complications, the use of narcotic analgesics, and hospitalization time in selected patients suffering from invasive bladder cancer. Further research is necessary to find out the long-term effect of the method described.

## References

- Gakis G, Efstathiou J, Lerner SP, Cookson MS, Keegan KA, Guru KA, et al. ICUD–EAU International Consultation on Bladder Cancer 2012: Radical cystectomy and bladder preservation for muscle-invasive urothelial carcinoma of the bladder. *Eur Urol.* 2013; 63: 45–57.
- Lawrentschuk N, Colombo R, Hakenberg OW, Lerner SP, Månsson W, Sagalowsky A, Wirth MP. Prevention and management of complications following radical cystectomy for bladder cancer. *Eur Urol.* 2010; 57: 983–1001.
- Haber G, Crouzet S, Gill IS. Laparoscopic and robotic assisted radical cystectomy for bladder cancer: a critical analysis. *Eur Urol.* 2008; 54: 54–62.
- Stenzl A, Nagele U, Kuczuk M, Sievert K-D, Anastasiadis A, Seibold J, Corvin S. Cystectomy – technical consideration in male and female patients. *EAU Update Series.* 2005; 3: 138–146.
- Sanchez de Badajos E, Gallego Perales JL, Reche Rosado A, Gutierrez de la Cruz JM, Jimenez Garrido A. Laparoscopic cystectomy and ileal conduit: case report. *J Endourol.* 1995; 9: 59–62.
- Kozminski M, Partamian KO. Case report of laparoscopic ileal conduit. *J Endourol.* 1992; 6: 147.
- Puppo P, Perachino M, Ricciotti G, Bozzo W, Gallucci M, Carmignani G. Laparoscopically assisted transvaginal radical cystectomy. *Eur Urol.* 1995; 27: 80–84.
- Turk I, Deger S, Winkelmann B, Schonberger B, Loening SA. Laparoscopic radical



- cystectomy with continent urinary diversion (rectal sigmoid pouch) performed completely intracorporeally: the initial 5 cases. *J Urol.* 2001; 165: 1863–1866.
9. Gill IS, Kaouk JH, Meraney AM, Desai MM, Ulchaker JC, Klein EA, et al. Laparoscopic radical cystectomy and continent orthotopic ileal neobladder performed completely intracorporeally: the initial experience. *J Urol.* 2002; 168: 13–18.
  10. Haber GP, Crouzet S, Gill IS. Laparoscopic and robotic assisted radical cystectomy for bladder cancer: a critical analysis. *Eur Urol.* 2008; 54: 54–62.
  11. Pruthi RS, Wallen EM. Robotic-assisted Laparoscopic radical cystoprostatectomy. *Eur Urol.* 2008; 53: 310–322.
  12. Vallancien G, Cathelineau X, Barret E, Rozet F. Laparoscopy in the treatment of urologic cancers. *Bull Cancer.* 2007; 94: 1072–1074.
  13. Kihara K, Kobayashi T, Kawakami S, Fujii Y, Kageyama Y, Masuda H. Minimum Incision Endoscopic Surgery (MIES) in Japanese Urology: Results of Adrenalectomy, Radical Nephrectomy and Radical Prostatectomy. *Aktuel Urol.* 2010; 41: S15–S19.
  14. Dubrovin V, Tabakov A, Egoshin A, Novoselova O, Sharov V, Shakirov R, Michailovskyi O. Laparoscopic Radical Cystectomy with Extracorporeal Neobladder in the Treatment of Invasive Bladder Cancer. *Urology.* 2009; 74, suppl 4A: 306.
  15. Kihara K, Kawakami S, Fujii Y, Masuda H, Koga F. Gasless single-port access endoscopic surgery in urology: Minimum incision endoscopic surgery, MIES. *Int J Urol.* 2009; 16: 791–800.
  16. Dindo D, Demartines N, Clavien PA. Classification of surgical complications: a new proposal with evaluation in a cohort of 6336 patients and results of a survey. *Ann Surg.* 2004; 240: 205–213.
  17. Hautmann RE, de Petriconi R, Gottfried HW, Kleinschmidt K, Mattes R, Paiss T. The ileal neobladder: complication and functional results in 363 patients after 11 years of follow up. *J Urol.* 1999; 161: 427–428.
  18. Chang SS, Smith JJ, Cookson MS. Decreasing blood loss in patients treated with radical cystectomy: a prospective randomized trial using a new stapling device. *J Urol.* 2003; 169: 951–954.
  19. Shabsigh A, Korets R, Vora KC, Brooks CM, Cronin AM, Savage C, et al. Defining early morbidity of radical cystectomy for patients with bladder cancer using a standardized reporting methodology. *Eur Urol.* 2009; 55: 164–176.
  20. Lantz AG, Saltel ME, Cagiannos I. Renal and functional outcomes following cystectomy and neobladder reconstruction. *Can Urol Assoc J.* 2010; 4: 328–331.
  21. Kulkarni JN, Pramesh CS, Rathi S, Pantvaitya GH. Long-term results orthotopic neobladder reconstruction after radical cystectomy. *BJU Int.* 2003; 91: 485–488. ■