

A Lasso-Loop Traction Technique for Arthroscopic Superior Capsular Reconstruction



Mikel Aramberri-Gutiérrez, M.D., Ph.D., Giovanni Tiso-D'Orazio, M.D.,
David Gómez-Garrido, M.D., Juan-Manuel Antequera-Cano, M.D.,
Jorge A. Murillo-González, M.D., Ph.D., and Iñaki Mediavilla-Arza, M.D., Ph.D.

Abstract: Irreparable rotator cuff tears (RCTs) cause shoulder pain and dysfunction. Management of RCT patients has classically been difficult due to few treatment options. Since Mihata et al. in 2013 introduced the superior capsular reconstruction (SCR) technique as a treatment option, it has become widespread among surgeons, especially for young active patients in whom reverse shoulder arthroplasty is not recommended. With SCR, a reduced humeral head can be maintained and superior displacement is avoided, improving shoulder pain and restoring active shoulder motion. A variety of grafts may be used, but the surgery can be technically complicated. An arthroscopic lasso-loop traction technique for SCR is described here, which simplifies graft shoulder reduction by traction from the anteromedial and posteromedial portals.

The management of patients with massive and irreparable rotator cuff tear (RCT) is a challenging clinical situation for orthopedic surgeons, especially with young active patients in whom a reverse shoulder arthroplasty is not recommended.¹ In these patients, repairs of massive RCT have high failure rates due to tendon inelasticity, poor tissue quality, and fatty infiltration typically present in these chronic retracted tears.² In the near past, other indications for such cases were a latissimus dorsi transfer or even a reverse shoulder arthroplasty.

In 2013, Mihata et al.³ described the arthroscopic superior capsular reconstruction (SCR) as a successful procedure for treating massive, irreparable RCT. The goal of the procedure was restoring glenohumeral biomechanics and adding superior humeral head stability. In their report, arthroscopic SCR was done using a fascia lata autograft.

SCR is a complex arthroscopic technique but highly useful in treating selected patients with irreparable

RCT.⁴ Recent biomechanical studies have described that the superior capsule is critical to keep the glenohumeral joint reduced, allowing the surrounding muscles, especially the deltoid, to function properly. The SCR is an anatomic reconstruction of the superior capsule that allows restoration of the normal restraint to superior translation that occurs with a deficient rotator cuff.⁵

In this article, we describe an arthroscopic SCR (Table 1) in which the medial side of the graft is introduced into the shoulder with lasso-loop traction sutures through the cannula, and the lateral side lasso-loops of the graft are fixed laterally by means of transosseous equivalent anchors.

Surgical Technique

The main indications to use this SCR technique are patients with intolerable pain, massive and irreparable RCT without degenerative glenohumeral joint changes, and appropriate function of the deltoid muscle. Also, it must be taken into account that the best clinical

From the Alai Sports Medicine Clinic, Madrid, Spain (M.A.-G., G.T.-D'O.); Hospital Quironsalud, Toledo, Spain (D.G.-C.); Hospital Laboral Solimat, Toledo, Spain (D.G.-C.); Hospital Universitari I Politènic La Fe, Valencia, Spain (J.-M.A.-C.); Human Anatomy and Embriology, Faculty of Medicine, Complutense University of Madrid, Spain (J.A.M.-G.); and Hospital Universitario de Basurto, Bilbao, Spain (I.M.-A.).

The authors report the following potential conflicts of interest or sources of funding: M.A.-G. reports other from Stryker. Full ICMJE author disclosure forms are available for this article online, as supplementary material.

Received April 2, 2020; accepted June 5, 2020.

Address correspondence to Mikel Aramberri Gutiérrez, M.D., Ph.D., Alai Sports Medicine Clinic, C/Arturo Soria, 342, Madrid, Spain 28033. E-mail: aramberri@centroalai.es

© 2020 by the Arthroscopy Association of North America. Published by Elsevier. This is an open access article under the CC BY-NC-ND license (<http://creativecommons.org/licenses/by-nc-nd/4.0/>).

2212-6287/20550

<https://doi.org/10.1016/j.eats.2020.06.002>

Table 1. Summary of Superior Capsular Reconstruction Steps

Step 1: Intra-articular approach and complete subacromial debridement
Step 2: Upper glenoid-lateral tuberosity measurement
Step 3: Placement of medial glenoid anchors
Step 4: Preparation of the graft with lasso-loop configuration on both sides
Step 5: Graft insertion and fixation, first medially, then laterally

outcomes are obtained in patients with an intact subscapularis tendon.

Under general anesthesia and previous interescalenic plexus block, the patient is placed in the beach-chair position with a 3-kg arm traction. The bone references and standard arthroscopic portals are marked on the skin (A, posterior standard portal; B, posterolateral portal; C, lateral portal; D, anterolateral portal; E, anterior portal; and Neviaser portal) (Fig 1).

Step 1: Intra-articular Approach and Debridement

A right human cadaveric shoulder was chosen for demonstration purposes (Video 1). Through the standard posterior portal (A) with a 4.0-mm 30° arthroscope, the joint is visualized, and the massive rotator cuff tear is confirmed. An anterior portal (E) is created to introduce a radiofrequency device (90-SMAX Energy Probe; Stryker, Denver, CO) to start cleaning the subacromial space (Table 2). Then, the arthroscope is placed in the lateral portal (C). The whole subacromial space from posterior to anterior and from medial to lateral must be debrided and cleaned. Special attention should be paid to make room where the anchors will be placed (Video 1). The footprint and laterally to the greater tuberosity of the humeral head are debrided to have a clear view of the lateral side where the graft will be fixed.

Step 2: Measure

To measure the size of the graft, the arthroscope is inserted into the lateral portal (C). Supraglenoid distance is measured from posterior to anterior side through the anterior portal (E). Next, the distance between the supraglenoid tubercle and the lateral part of the footprint on the humeral head should be measured with the blunt probe with measuring guide markings through the anterolateral portal (D) (Fig 2).

Step 3: Medial Glenoid Anchor Placement

The location for the medial glenoid anchors is approximately at 11 and 1 o'clock (Fig 3) viewing from the lateral portal (C). Through the superior portal (Neviaser) the posterior all suture anchor (ICONIX 2, 2.3 mm, Stryker, San Jose, CA) is introduced. The anterior anchor is better inserted through the anterior portal (E). Subsequently, 1 suture limb of each anchor is retrieved from the C portal through the lateral cannula. The other limb from each medial anchor is shortened to act as a traction suture from N and E portals.

Step 4: Graft Preparation

In this technique, a ProLayer Acellular Dermal Matrix is used (Stryker, Centennial, CO) as the graft for the clinical demonstration.⁶ The graft must be prepared externally with the measures taken in step 2. On the lateral side of the graft, 2 holes are made on the table with the Straight Penetrating Grasper (Stryker). A free suture is fixed using a lasso loop stitch⁷ through each of the holes (white arrow, Fig 4).

On the medial graft side, after retrieving a long limb from each of the medial anchors laterally through the cannula in the lateral C portal (see step 3), 2 medial lasso-loop traction sutures are performed outside the cannula before introducing the graft.

Step 5: Introduction and Fixation of the Graft

Cannula

The cannula should be ~1.5-cm diameter to be able to pass both the sutures and the graft rolled over itself.

Graft Introduction

The graft is folded and introduced through the cannula being pushed by the suture manipulator pincer (white arrow), and simultaneously each suture of the supraglenoid anchors is pulled up from N and E portals (Fig 5). Viewing from portal B, the graft is unfolded and located from the supraglenoid area to the footprint.

Graft Fixation

Before medial knot tying, both anterior sutures (lasso-loop and free limb) must be retrieved through the E anterior portal. This gesture must be repeated for

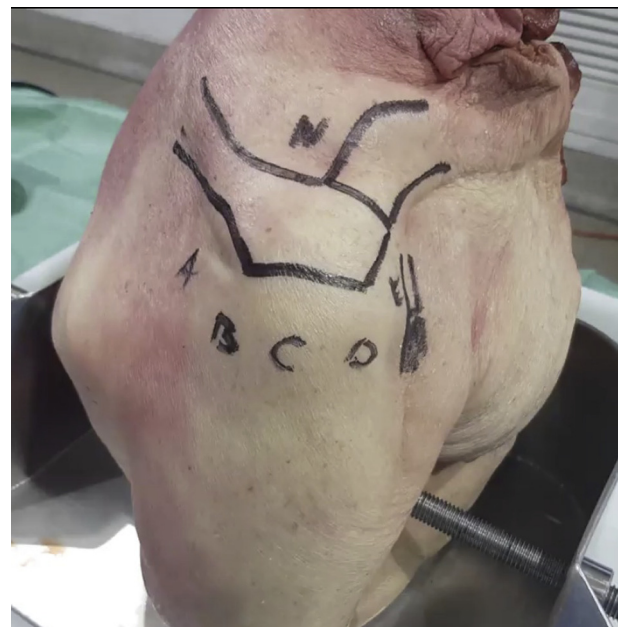

Fig 1. Right human cadaveric shoulder in beach chair position showing arthroscopic portals used for superior capsular reconstruction technique. Viewing portals are both B and C.

Table 2. Pearls and Pitfalls

Pearls	Pitfalls
1. Proper cleaning and bursectomy in the whole sub-acromial space, with clear visualization of the superior glenoid rim and lateral footprint	1. Improper cleaning makes the procedure more difficult in terms of visualization and suture management
2. Correct visualization and measuring of the length of the graft	2. Improper measurement may lead to overconstrained or loose superior capsular reconstruction (SCR)
3. Proper anteromedial (AM) and posteromedial (PM) portal placement to allow a correct implant insertion at the glenoid rim, and therefore proper traction suture management	3. Not choosing the appropriate portal placement may lead to incorrect traction and a more difficult procedure
4. One medial suture is retrieved from each anchor through the cannula, necessitating suture individualization	4. Failure to individualize sutures means the lasso-loop traction technique will fail, as 1 limb must be left in place medially to pull the SCR into the shoulder
5. Correct graft size and lasso-loop preparation outside the cannula; use AM and PM traction sutures simultaneously	5. Failure to prepare the graft outside the cannula with proper suture management may increase procedure time
6. Use of transosseous equivalent anchors laterally through the cannula to prevent soft tissue complications	

the posterior sutures through the N portal. The graft is fixed in the supraglenoid area with arthroscopic non-sliding knots on the posteromedial and anteromedial

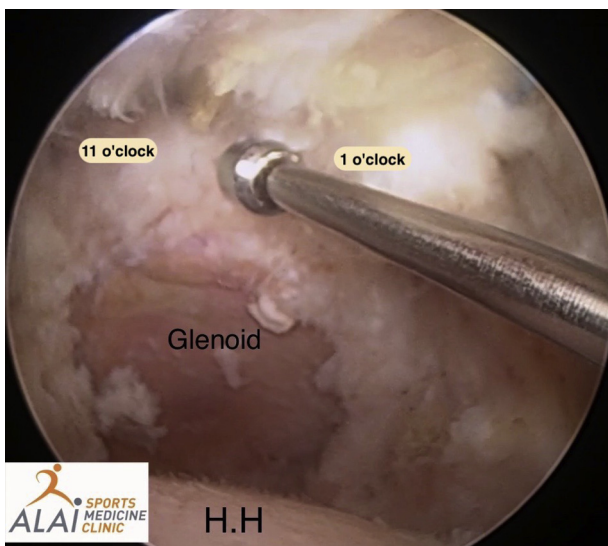


Fig 2. Viewing from the arthroscopic posterolateral portal (B) in the subacromial area, the space from the supraglenoid border to the footprint is measured by the blunt probe (with measuring guide markings) through the lateral portal (C).

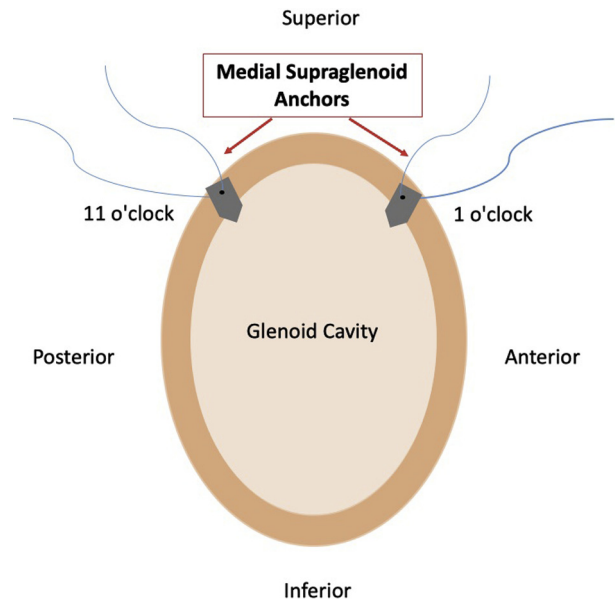


Fig 3. Illustration of the lateral view of the glenoid cavity showing that the location for the medial supraglenoid anchors is approximately at 11 and 1 o'clock.

anchors (Fig 6). To fix the lateral side of the graft ReelX STT, knotless anchors are used (Stryker). These anchors are placed on the posterolateral and anterolateral border of the humeral head (greater tuberosity) to provide progressive graft tension (Fig 6). Then, with a view through the lateral portal (C), the superior capsular reconstruction is checked (Fig 7). At this stage, additional sutures may be added to the infraspinatus tendon.

Discussion

Arthroscopic SCR is a recent technique to treat irreparable and massive RCT. This procedure remains

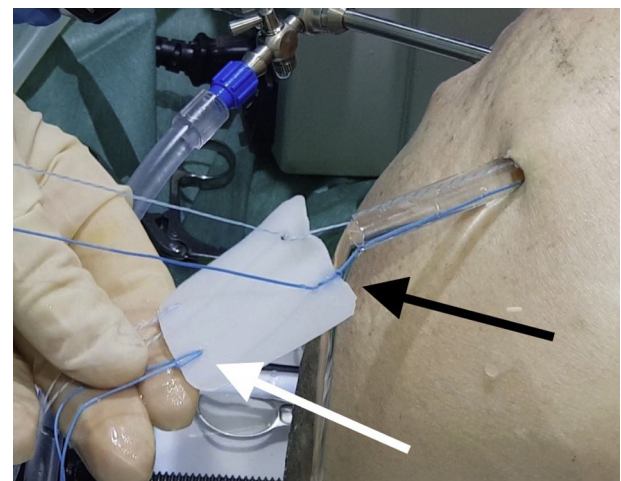


Fig 4. The sutures are fixed in the graft using the lasso loop stitch. The black arrow indicates the medial side lasso-loops, and the white arrow indicates the lateral lasso-loops of the graft.

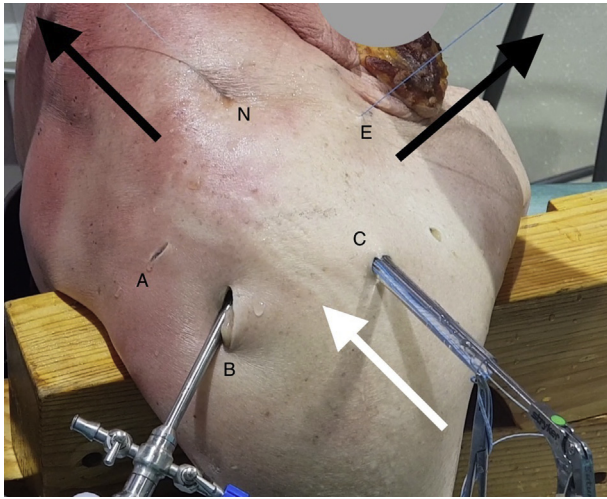


Fig 5. Graft introduction. Pushing the graft (white arrow) and simultaneously pulling out the sutures (black arrows).

technically challenging and difficult to reproduce (Table 3). Many studies on modified arthroscopic techniques have been published since the original technique described by Mihata et al.³ was published. They described attaching a fascia lata autograft medially to the glenoid using 2 anchors, and then attaching the graft laterally to the greater tuberosity of the humerus with a suture bridge.³

Many surgical options are available to treat massive and irreparable RCT when patients do not respond to conservative management. Partial repair was first described by Burkhart et al.,⁸ and several studies found a statistically significant improvement in functional outcome scores versus preoperatively.⁹ However, Burkhart and Hartzler¹⁰ found that pseudoparalysis can be more reliably reversed after superior capsular reconstruction (90%) than with partial repair (44%).

Tendon transfer is another surgical technique for irreparable RCT. Latissimus dorsi transfer (LDT) was described by Gerber et al.¹¹ to treat active patients with an irreparable rotator cuff tear. More recently, Elhassan et al.¹² reported lower trapezius transfer for irreparable RCT, in which the lower trapezius is transferred to the humeral head after its tendon is augmented with an Achilles tendon allograft.

SCR shows a significant improvement in function, including the American Shoulder and Elbow Surgeons (ASES) score, UCLA score, and forward flexion, in comparison with latissimus dorsi transfer.¹³ No studies have yet compared SCR with LDT. Elhassan et al.¹² reported good clinical outcomes at a mean follow-up of 47 months with significantly increased mean scores of Subjective Shoulder Value from 54% preoperatively to 78% postoperatively.

Reverse shoulder arthroplasty (RSA) is a very good option to treat massive and irreparable RCT with and without osteoarthritis. Similar functional outcomes in ASES score and improvements in range of motion (ROM) have been reported between SCR and RSA, except for external rotation, which seems better in patients receiving SCR.¹³ Although these procedures tend to produce similar outcome scores in terms of function and ROM, RSA may carry a much higher complication rate (39%) compared with SCR (7%).¹³ In the short and medium term, RSA shows good survival and functional results, but there is not much research to prove this for the long term in young patients. Therefore, RSA should be indicated with caution for patients <65 years old. Ernstbrunner et al.¹⁴ reported the outcome after RSA in 23 shoulders of patients <60 years (mean age 57) with a follow-up of 12 years. The failure rate was 9%, the revision rate was 17%, and the complication rate was 39%, although the

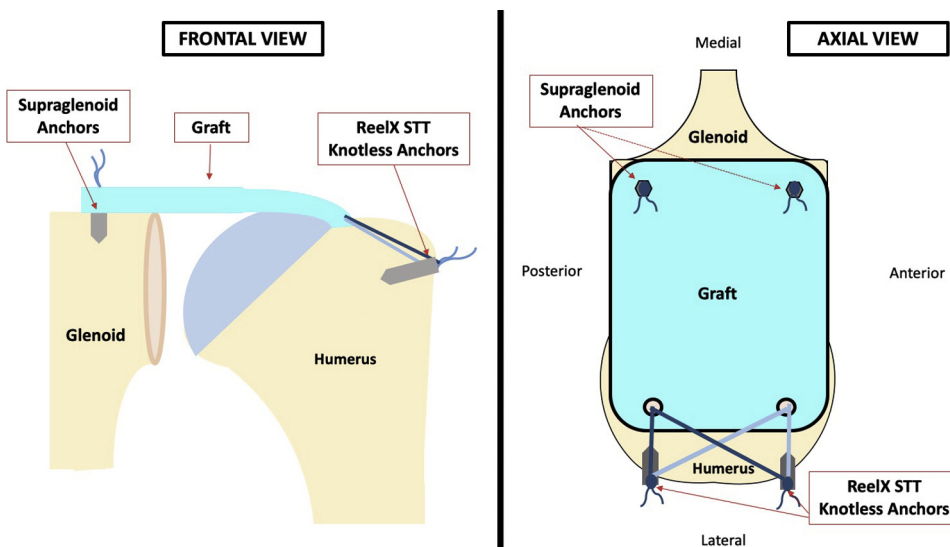


Fig 6. Illustration of a frontal view and axial view showing the position of the anchors in the glenoid rim and the final configuration of the graft fixation onto the greater tuberosity with ReelX anchors (final result).

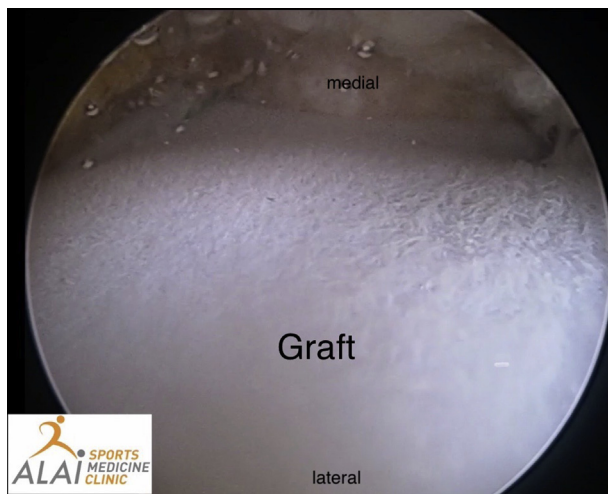

Fig 7. Superior capsular reconstruction view from the arthroscopic lateral portal (C). The graft for the superior capsular reconstruction is checked.

objective and subjective outcomes were much better after the RSA compared with preoperative status. Similar outcomes have been reported by Sershon et al.,¹⁵ with 25% failure rate at 3 years of follow-up in patients <65 years old with RSA.

Different SCR techniques have been described varying in the type and number of anchors, the great tuberosity fixation techniques, and the type of graft. Two glenoid anchors can be enough, although if the graft is >35 mm in the anterior-posterior dimension or the distance between the 2 glenoid anchors is >20 mm, a third anchor can be placed in the glenoid without increasing the risk of suprascapular nerve injury.^{16,17}

Since the original technique of Mihata et al.³ using a fascia lata, different grafts have been described for SCR. Dermal allograft has gained popularity for their theoretical advantage of reducing donor site morbidity, shorter operative times, and easy preparation, although no clinical studies have confirmed the equivalence of the 2 grafts.

One cadaveric study directly compared the use of human dermal allografts with fascia lata allografts for SCR.¹⁸ Superior translation of the humeral head was completely restored with fascia lata allograft, but only partially with dermal allograft.¹⁸ Current systematic

Table 3. Risks and Limitations

Risks	Limitations
1. Damage to the suprascapular nerve if a too-medial glenoid anchors insertion is performed.	1. Too far superiorly migrated humeral head.
2. Tangle of the sutures if not individualizing every suture carefully.	2. Pseudoparalytic shoulders.

Table 4. Advantages and Disadvantages

Advantages	Disadvantages
1. Step-by-step technique to facilitate superior capsular reconstruction (SCR) and make it reproducible	1. Nonsliding knot-tying is required to complete the SCR reduction at the glenoid rim
2. Less surgical time to complete the SCR	
3. All-arthroscopic procedure, with less comorbidity	
4. Knot-tying is not necessary at the lateral row	
5. Although this technique is described in beach chair position, it can also be performed in lateral decubitus	

reviews show that both autografts and allografts (dermal allografts) improved clinical outcomes.¹⁹

Differences in the thickness of the graft is also important. The superior capsule of the native shoulder is ~4.4 to 9.1 mm thick.²⁰ Although a graft thicker than 8 mm is needed to decrease superior translation, and a 4- to 8-mm-thick fascia lata allograft can reduce subacromial peak pressure after SCR.²¹

The appropriate graft tension is also important. Undertensioned grafts may not restore the superior stability of the glenohumeral joint, and overtensioned grafts may be at increased risk of tearing.¹⁷ Biomechanical studies have investigated the appropriate tension of the graft and suggest that 45° of abduction is the best position to attach the graft, although more studies are required to know the best position for graft fixation and tension.

A recent clinical and radiological study revealed that SCR with acellular dermal matrix was successful in decreasing pain and improving shoulder function. In addition, it showed a decrease in superior displacement of the humeral head, indicating that it maintains superior capsular stability.²²

We believe that this lasso-loop traction technique will reduce the complexity of this technically challenging and difficult procedure, allowing surgeons to operate in a more efficient and reproducible way (Table 4). The authors believe that SCR is a reliable procedure to treat irreparable and massive RCT in young patients.

References

1. Frank RM, Cvetanovich G, Savin D, Romeo AA. Superior capsular reconstruction: Indications, techniques, and clinical outcomes. *JBJS Rev* 2018;6:e10.
2. Le BTN, Wu XL, Lam PH, Murrell GAC. Factors predicting rotator cuff retears: An analysis of 1000 consecutive rotator cuff repairs. *Am J Sports Med* 2014;42:1134-1142.
3. Mihata T, Lee TQ, Watanabe C, et al. Clinical results of arthroscopic superior capsule reconstruction for irreparable rotator cuff tears. *Arthroscopy* 2013;29:459-470.

4. Hartzler RU, Burkhart SS. Superior capsular reconstruction. *Orthopedics* 2017;40:271-280.
5. Hirahara AM, Adams CR. Arthroscopic superior capsular reconstruction for treatment of massive irreparable rotator cuff tears. *Arthrosc Tech* 2015;4:e637-e641.
6. Stilwell R, Delaney R. The biomechanics of ProLayer™ acellular dermal matrix: Biocompatibility study. Mahway, NJ: Stryker Corp., 2016.
7. Lafosse L, Van Raebroeckx A, Brzoska R. A new technique to improve tissue grip: "The lasso-loop stitch." *Arthroscopy* 2006;22:1246.e1-1246.e3.
8. Burkhart SS, Nottage WM, Ogilvie-Harris DJ, Kohn HS, Pachelli A. Partial repair of irreparable rotator cuff tears. *Arthroscopy* 1994;10:363-370.
9. Carver TJ, Kraeutler MJ, Smith JR, Bravman JT, McCarty EC. Nonarthroplasty surgical treatment options for massive, irreparable rotator cuff tears. *Orthop J Sport Med* 2018;6. 2325967118805385.
10. Burkhart SS, Hartzler RU. Superior capsular reconstruction reverses profound pseudoparalysis in patients with irreparable rotator cuff tears and minimal or no glenohumeral arthritis. *Arthroscopy* 2019;35:22-28.
11. Gerber C, Vinh TS, Hertel R, Hess CW. Latissimus dorsi transfer for the treatment of massive tears of the rotator cuff. A preliminary report. *Clin Orthop Relat Res* 1988;(232):51-61.
12. Elhassan BT, Wagner ER, Werthel JD. Outcome of lower trapezius transfer to reconstruct massive irreparable posterior-superior rotator cuff tear. *J Shoulder Elb Surg* 2016;25:1346-1353.
13. Catapano M, de SA D, Ekhtiari S, Lin A, Bedi A, Lesniak BP. Arthroscopic superior capsular reconstruction for massive, irreparable rotator cuff tears: A systematic review of modern literature. *Arthroscopy* 2019;35:1243-1253.
14. Ernstbrunner L, Suter A, Catanzaro S, Rahm S, Gerber C. Reverse total shoulder arthroplasty for massive, irreparable rotator cuff tears before the age of 60 years: Long-term results. *J Bone Joint Surg Am* 2017;99:1721-1729.
15. Sershon RA, Van Thiel GS, Lin EC, et al. Clinical outcomes of reverse total shoulder arthroplasty in patients aged younger than 60 years. *J Shoulder Elb Surg* 2014;23:395-400.
16. Tom JA, Mesfin A, Shah MP, et al. Anatomical considerations of the suprascapular nerve in rotator cuff repairs. *Anat Res Int* 2014;2014:674179. <https://doi.org/10.1155/2014/674179>.
17. Laskovski JR, Boyd JA, Peterson EE, Abrams JS. Simplified technique for superior capsular reconstruction using an acellular dermal allograft. *Arthrosc Tech* 2018;7:e1089-e1095.
18. Mihata T, Bui CNH, Akeda M, et al. A biomechanical cadaveric study comparing superior capsule reconstruction using fascia lata allograft with human dermal allograft for irreparable rotator cuff tear. *J Shoulder Elb Surg* 2017;26:2158-2166.
19. Kim DM, Shin MJ, Kim H, Park D. Comparison between autografts and allografts in superior capsular reconstruction: A systematic review of outcomes. *Orthop J Sports Med* 2020;8. 23259671209049372020.
20. Nimura A, Kato A, Yamaguchi K, et al. The superior capsule of the shoulder joint complements the insertion of the rotator cuff. *J Shoulder Elb Surg* 2012;21:867-872.
21. Mihata T, McGarry MH, Kahn T, Goldberg I, Neo M, Lee TQ. Biomechanical effect of thickness and tension of fascia lata graft on glenohumeral stability for superior capsule reconstruction in irreparable supraspinatus tears. *Arthroscopy* 2016;32:418-426.
22. Pennington WT, Bartz BA, Pauli JM, Walker CE, Schmidt W. Arthroscopic superior capsular reconstruction with acellular dermal allograft for the treatment of massive irreparable rotator cuff tears: Short-term clinical outcomes and the radiographic parameter of superior capsular distance. *Arthroscopy* 2018;34:1764-1773.