


A CASE REPORT of Lichen Nitidus on the Penis: Tiny but Annoying Eruptions

Jingying Wang, Yinghao Pan, Guangmin Wei, Hanxiao Mao, Rulan Liu, Xia Xiong , Jixiang Xu, Yuanmin He

Department of Dermatology, The Affiliated Hospital of Southwest Medical University, Luzhou, Sichuan, People's Republic of China

Correspondence: Yuanmin He, Department of Dermatology, The Affiliated Hospital of Southwest Medical University, No. 25 of Taiping Road, Luzhou, Sichuan, 646000, People's Republic of China, Email heym88@163.com

Abstract: Most patients are anxious about the skin lesions on the penis. This study reports a case of lichen nitidus on the penis and reviews related literature. A 40-year-old male has presented with small papules with skin color on the penis for one year. The patient was diagnosed with lichen nitidus, and tacrolimus cream and humectant were topically administered after diagnosis. The symptoms were alleviated after treatment. We first report a series of the cases with lichen nitidus on the penis, knowing the clinical and pathological manifestations of this disease can reduce misdiagnosis and unnecessary treatment.

Keywords: Lichen nitidus, penis, pathological feature, treatment, prognosis

Introduction

Lichen nitidus is a rare, benign inflammatory disease. It is clinically characterized by the presence of multiple discrete papules that are tiny, shiny, flat-topped, and of varied colors.¹ Histopathologically, lichen nitidus presents as a well-circumscribed lymphohistiocytic infiltrate in a “claw clutching a ball” pattern in the papillary dermis.² The clinical manifestations, histopathology, and immunohistochemistry showed that the disease was different from lichen planus. The current view considers it unnecessary to treat circumscribed forms of lichen nitidus as the symptoms subside within a period. However, patients are still distressed and anxious about the disease, especially when there are many lesions on the penis. In our article, the referred patients have previously been considered a sexually transmitted disease in other hospitals, which severely affected the marital relationship. So counseling and reassurance should be in a critical position for patients. This article summarizes the characteristics and treatment outcomes of a group of cases with lichen nitidus on the penis.

Case Series

The characteristics and treatment outcomes of 7 patients with lichen nitidus on the penis were analyzed retrospectively according to the previous case reports and typical patients we diagnosed.

Representative Patient I

A 40-year-old man found small papules with skin color on the penis for one year without pruritus or pain. In the past two months, the skin lesions gradually progressed. His past medical history was diagnosed as a viral infection and treated with topical antiviral ointment for one month without much improvement. Before onset, the patient had no apparent cause, no history of risky sexual behavior, and no other systemic diseases. Dermatological examination revealed shiny, polygonal, 1–2 mm sized papules on the penis. The papules did not tend to coalesce (Figure 1A). A skin biopsy sample from the penis was taken for histopathological examination to confirm the clinical diagnosis (Figure 1B). Tacrolimus cream and humectant were used topically, and the skin lesions of the patient significantly reduced after one year (Figure 1C). The cases of the other six patients are shown in Table 1.

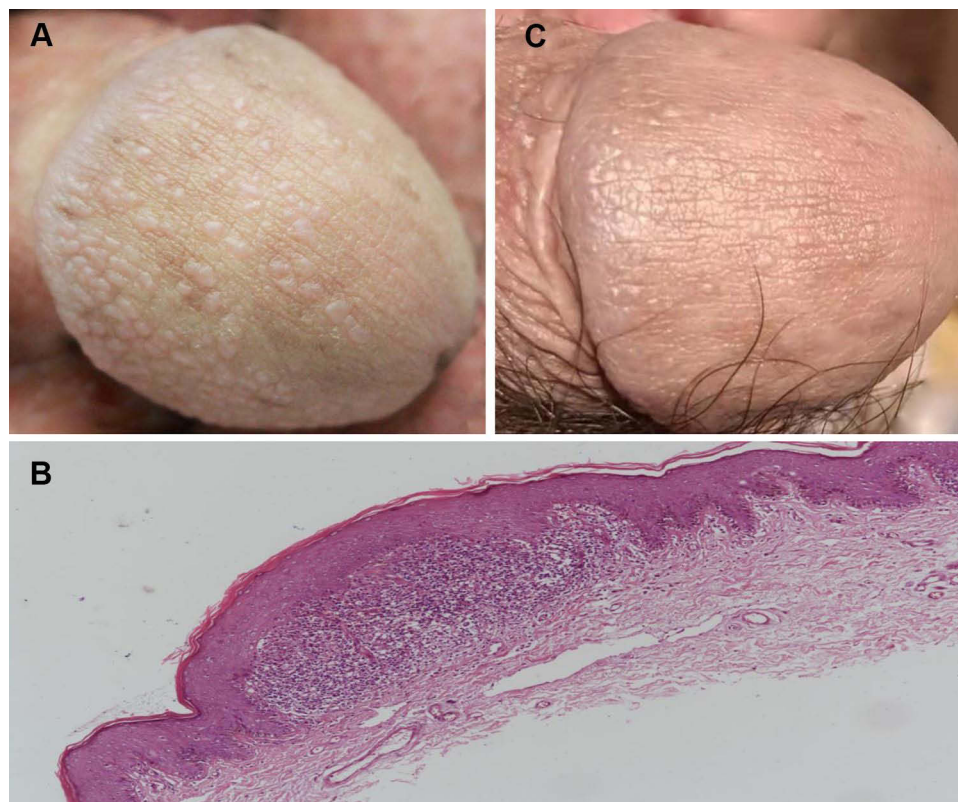


Figure 1 Small glistening and skin-colored papules on the penis (A). Skin biopsy from lesion showed the characteristic feature of ball and claw configuration of the epidermis, inflammatory infiltrate is composed of lymphocytes. Hematoxylin-eosin stain, 40× (B). Most of these papules subsided after 1 year (C).

Discussion

Lichen nitidus, first named by Pinkus, is a rare chronic inflammatory disease. The cause of its pathogenesis is unknown so far.³ The typical skin lesions of lichen nitidus are shiny, flat-topped, skin-colored, pinhead-sized

Table 1 The Characteristics and Treatment Outcomes of 6 Previously Published Patients with Lichen Nitidus on the Penis

Case	Age	Disease Duration	Misdiagnosis	Clinical Features	Histopathology	Treatment and Follow-Up
Case 1	28	4y	Condyloma acuminatum	Widely scattered papules, glistening, skin-colored to slight pink	Ball and claw configuration of the epidermis	Hydrocortisone Butyrate Cream, the follow-up is not mentioned
Case 2	7	3y	Pearly penile papules			Compound Glycyrrhizin Tablets, Tretinoin Cream, no new skin eruptions
Case 3	16	6m	Without diagnosis			Pimecrolimus, the follow-up is not mentioned
Case 4	12	2y	Without diagnosis			Traditional Chinese medicine ointment, improve 50% after 20 days
Case 5	13	1m	Viral infection			The number of lesions decreased without treatment
Case 6	31	Several weeks	Contagious disease			Topical glucocorticoid, the follow-up is not mentioned

papules, which are usually arranged in groups on the chest, abdomen, genitalia, and upper extremities. There are usually no obvious symptoms of discomfort with this disease.⁴ However, when it occurs in the male genital area, it seriously affects patients' mental health. Clinically, inexperienced dermatologists may misdiagnose the disease as penile pearl papules, condylomata acuminata, etc. Compared with condylomata acuminata, lichen nitidus is more fat-topped and does not have a cauliflower-like surface. Commonly, penile pearl papules occur in a single or double row on the corona of the glans, and lichen nitidus tends to occur on the shaft of the penis. Many patients have been misdiagnosed, even misdiagnosed as sexually transmitted diseases, and experienced wrong and unnecessary treatment.⁵ Generally speaking, lichen nitidus often resolves spontaneously in a few years without treatment. If the patient's disease is prolonged or accompanied by pruritus, topical glucocorticoids or pimecrolimus may be helpful, and calcineurin inhibitors may be preferred given the side effects of prolonged steroid use.⁶ There are few reports about the treatment and prognosis of lichen nitidus on the penis. The patients reported in these cases have typical clinical and pathological manifestations. In addition, we also tracked the patient's skin lesions for one year, which has guiding value for the diagnosis and treatment of the disease. However, due to the small number of objects and particularity of case studies, they are often not universal and cannot effectively represent the disease.

Conclusion

Skin lesions on the penis can cause panic and mental stress. Under the circumstances, a correct diagnosis by a dermatologist is essential. However, lichen nitidus on the genitalia is commonly misdiagnosed. This case report describes the characteristics and outcomes of lichen nitidus occurring on the penis, which may help increase awareness of this condition.

Ethics Statement

The authors certify that they have obtained all appropriate patient consent forms. The patient gave written informed consent for the publication of clinical information and photographs. Institutional approval was not required for this case details.

Disclosure

The authors declare no potential conflicts of interest in this work.

References

1. Chiu HY, Chiu HC. A florid, tiny, discrete eruption on the penis. *JAMA*. 2012;308(12):1264–1265.
2. Taneja N, Mehta N, Arava S, et al. An unusual variant of lichen nitidus: generalized follicular spinous with perifollicular granulomas. *J Cutan Pathol*. 2020;47(9):834–839. doi:10.1111/cup.13712
3. Polcari IC, Mancini AJ, Stein SL. Facial hypopigmentation in skin of color: an atypical presentation of lichen nitidus. *Pediatr Dermatol*. 2021;38 (Suppl 2):110–112. doi:10.1111/pde.14692
4. Jakhar D, Grover C, Kaur I, et al. Dermatoscopic features of lichen nitidus. *Pediatr Dermatol*. 2018;35(6):866–867. doi:10.1111/pde.13576
5. Thibaudeau A, Maillard H, Croué A, et al. Lichen nitidus palmoplantaire. [Palmoplantar lichen nitidus: a rare cause of palmoplantar hyperkeratosis]. *Ann Dermatol Venerol*. 2004;131(8–9):822–824. French. doi:10.1016/S0151-9638(04)93769-6
6. Kundak S, Cakir Y. Pediatric lichen nitidus: a single-center experience. *Pediatr Dermatol*. 2019;36(2):189–192. doi:10.1111/pde.13749

Clinical, Cosmetic and Investigational Dermatology

Dovepress

Publish your work in this journal

Clinical, Cosmetic and Investigational Dermatology is an international, peer-reviewed, open access, online journal that focuses on the latest clinical and experimental research in all aspects of skin disease and cosmetic interventions. This journal is indexed on CAS. The manuscript management system is completely online and includes a very quick and fair peer-review system, which is all easy to use. Visit <http://www.dovepress.com/testimonials.php> to read real quotes from published authors.

Submit your manuscript here: <https://www.dovepress.com/clinical-cosmetic-and-investigational-dermatology-journal>