

# Comparison of Cervical Detachment Using Monopolar Lap Loop Ligature and Conventional Methods in Laparoscopic Supracervical Hysterectomy

Resad Pasic, MD, PhD, Allam Abdelmonem, MD, Ronald Levine, MD

## ABSTRACT

**Objectives:** Our aim was to evaluate a new electro-surgical instrument (Lap Loop device) that amputates the uterine corpus from the cervix during a laparoscopic supracervical hysterectomy (LSH) and to compare the time required for cervical amputation with traditional methods.

**Methods:** This comparative trial was conducted at the University of Louisville and Norton Healthcare Hospitals, Louisville, KY. The patients comprised 29 women scheduled for hysterectomy for benign conditions. All patients underwent laparoscopic supracervical hysterectomy. The Lap Loop device was used in 17 patients to section the cervix. Conventional methods with either laparoscopic monopolar scissors or Harmonic scalpel were used in 12 patients.

**Results:** In the control group, the mean cervical cutting time with laparoscopic scissors or Harmonic scalpel was 14.4 minutes. The mean time for the application of the loop electrode and cutting time was 6.6 minutes and was significantly shorter than the cutting time of conventional methods. Two minor complications (7.4% of cases) and one relatively major complication (3.7%), an incisional hernia, occurred in the study patients. None of the complications were related to the new device.

**Conclusion:** An electro-surgical loop decreased the time required for resection of the uterine cervix during LSH for benign uterine conditions. This device facilitates and increases the safety of this procedure.

**Key Words:** Laparoscopic supracervical hysterectomy, Lap Loop, Electro-surgical transection.

## INTRODUCTION

Supracervical hysterectomy is considered controversial. However, according to the latest American Association of Gynecologic Laparoscopists (AAGL) survey, the performance of laparoscopic supracervical hysterectomies (LSH) is apparently increasing.<sup>1</sup> LSH has several advantages but is admittedly only for a subset of patients who meet the following criteria<sup>1</sup>: The patient must have a history of negative Pap smears.<sup>2</sup> The patient should have normal endometrial biopsy results.<sup>3</sup> The reasons for the hysterectomy should be for a benign pathology.<sup>4</sup> The patient must be compliant and dependable when it comes to undergoing annual pap smears.

Recently, a new instrument, the Lap Loop (Medsys, Gembloux, Belgium) monopolar electrode for resection and detachment of the uterine corpus from the cervix has been developed by Dequesne<sup>2</sup> (**Figure 1**). We are the first center in the United States to try this new device in laparoscopic supracervical hysterectomy. Herein, we describe this new technique and compare it with the traditional methods of detachment of the uterine corpus in laparoscopic supracervical hysterectomy.

## METHODS


Patients undergoing laparoscopic supracervical hysterectomy were assigned to 2 groups. Seventeen patients signed consent forms to participate in this study of the experimental device (Lap Loop system) for fundal detachment in laparoscopic supracervical hysterectomy. The Institutional Review Board at the University of Louisville School of Medicine and Norton Healthcare Hospitals approved this study. Study patients were compared with a control group of 12 patients with similar characteristics who underwent supracervical hysterectomy using the conventional methods of uterine detachment with either laparoscopic monopolar scissors or Harmonic scalpel. All patients fulfilled the following inclusion criteria<sup>1</sup>: Patients with a clear indication for hysterectomy with benign gynecologic conditions<sup>2</sup>; Patients with a healthy cervix with a negative Pap smear and normal endometrial biopsy<sup>3</sup>; Patients who agreed to a follow-up schedule of annual Pap smears.

Department of Obstetrics, Gynecology & Women's Health, University of Louisville School of Medicine, Louisville, Kentucky, USA (Drs Pasic, Levine).

Department of Obstetrics and Gynecology, Sohag Faculty of Medicine, South Valley University, Sohag, Egypt (Dr Abdelmonem).

Address reprint requests to: Resad Pasic, MD, PhD, Associate Professor, Department of Obstetrics, Gynecology & Women's Health, University of Louisville School of Medicine, Louisville, Kentucky, USA 40292. Telephone: 502 561 7463, Fax: 502 561 7413, E-mail: paya@louisville.edu

© 2006 by JSLs, *Journal of the Society of Laparoendoscopic Surgeons*. Published by the Society of Laparoendoscopic Surgeons, Inc.



**Figure 1.** The loop electrode consists of 3 parts: The 10-mm introducer, electrode shaft, and disposable cutting wire electrode. The wire electrode is insulated at the ends and has only a 2-cm area in the middle of the wire that maintains contact with the cervix. The screw end of the wire electrode is screwed into the tip of the electrode shaft, and the wire is placed around the cervix. The ball on the other end of the electrode is inserted and locked into the slit on the tip of the electrode shaft completing the loop and the circuit.

Residents under faculty supervision performed all surgeries. The operative time was calculated in minutes from the time of the first incision to the time of the last dressing. Loop application time was calculated from the beginning of its insertion through the trocar until the complete positioning of the loop around the cervix. Cervical cutting time was calculated from the activation of the monopolar current indicating actual beginning of cutting until the body of the uterus became freely detached from the cervix. Cervical cutting in the control group was measured from the beginning to the completion of the cervical transection. The loop application and actual cutting time were compared with the cutting time by conventional methods.

All patients were discharged as soon as they were able to tolerate food, not in need of parenteral pain medications, able to ambulate, able to void without a catheter, and with stable hemoglobin/hematocrit values.

### Operative Procedures

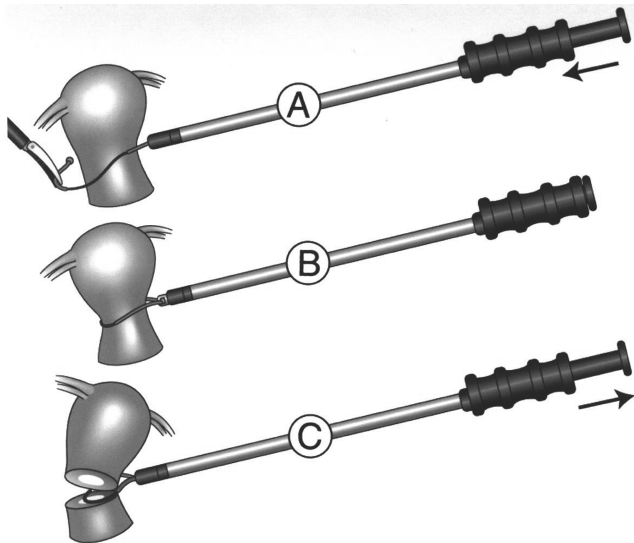
Standard trocar placements and laparoscopic methods for laparoscopic hysterectomy were used. After both uterine

arteries were coagulated using either the Harmonic scalpel or bipolar forceps and the bladder dissection was completed, the cervix was transected at the level of the internal ostium. Pushing the uterus from below with a uterine manipulator moved the cervix away from the ureters facilitating the safer amputation of the uterine corpus. The ureters are about 2 cm lateral to the point at which the uterus is separated from the cervix; therefore, visualization of the ureters during the operation is helpful.

The Lap Loop electrode consists of 3 parts (**Figure 1**): the 10-mm introducer, electrode shaft, and disposable cutting wire electrode. The wire electrode has a small screw at one end and a ball at the other end. The screw end of the wire electrode is screwed into the tip of the electrode shaft. The shaft with the wire is inserted into the abdomen through the 10-mm introducer via a lateral 10-mm trocar. The wire is insulated at the ends and has only a 2-cm area in the middle of the wire that is in contact with the cervix.

The wire electrode at the tip of the Lap Loop device is grasped with a grasper and manipulated around the cervix so that the ball is placed into the slit at the tip of the shaft electrode to form a loop (**Figure 2A**). Once the ball is placed into the slit of the electrode shaft, it is pulled back into the introducer therefore locking the loop in place around the cervix. The position of the wire loop is checked to guarantee it is snug around the cervix without compressing the tissue and to ensure that the loop is not in contact with any other structures, such as bowel or the pelvic sidewall (**Figure 2B**). Once the bare part of the wire is directly applied to the cervix, it ensures that the energy is directed to the uterine isthmus and not randomly to other tissues. The uterine manipulator is removed before the application of energy to the monopolar electrode. Conversely, as with any electrocautery, avoiding excessive pressure against the tissue ensures timely spark creation for efficient cutting action. A 100-W unipolar cutting current is applied, and the loop electrode is pulled back into the introducer slicing the wire loop through the cervix and detaching the uterine corpus from the cervix (**Figure 2C**). Passage of the wire electrode leaves a perfectly clean and hemostatic cut on the cervical stump.

After detachment from the cervix, the corpus of the uterus is removed with morcellation by using either the Gynecare X-tract Tissue Morcellator (Gynecare, Somerville, New Jersey, USA) or the Storz Morcellator (Storz, Tuttingen Germany). Cautery of the endocervical canal is performed using bipolar forceps at the completion of the operation. This step is intended to reduce the chance of developing subsequent cervical stump cancer and to elim-



**Figure 2.** The wire electrode at the tip of the Lap Loop device is grasped with a grasper and manipulated around the cervix. The ball at the end of the wire electrode is placed into the slit at the tip of the shaft electrode to form a loop (2A, B). Once the ball has been placed into the slit, the electrode shaft is pulled back into the introducer locking the loop in place around the cervix, ensuring the shielding of the noninsulated part of the wire other than that in direct contact with the cervix. A unipolar cutting current is applied, and the loop electrode is slowly pulled back into the introducer permitting the wire to slice through the cervix and detaching the uterine corpus from the cervix (2C).

inate possible menstrual bleeding that may occur from endometrium remaining in the cervical canal. After irrigation and final inspection of the peritoneal cavity, laparoscopic incisions are closed. Cystoscopy was performed on all study patients to make sure that both ureters were intact after the hysterectomy was completed and patients were taken to the recovery and floor units. All patients attended a follow-up clinic visit 2 weeks after surgery.

### Statistical Analysis

Statistical analysis was performed using SPSS software (version 11.0), and with consultation and the recommendations of our statistician, statistical significance was calculated using the Student *t* test for real numbers, and a *P* value of <0.05 was considered statistically significant.

### RESULTS

This case series included 29 patients fulfilling the inclusion criteria of the study. The patients were divided into 2 groups. The loop electrode was used in 17 patients and the conventional method of cervical detachment with unipolar scissors or Harmonic scalpel was used in 12 patients. The cervical detachment times were recorded and compared between the 2 groups.

The patient characteristics were similar in both groups (**Table 1**). Operative time among Lap Loop patients ranged from 90 minutes to 206 minutes (mean, 140.1). Operative time among control patients ranged from 69 minutes to 180 minutes (mean, 131.5). The estimated blood loss (EBL) in the Lap Loop group ranged from 50 mL to 600 mL (mean, 205). The EBL for the control group ranged from 20 mL to 200 mL (mean, 76 mL). The loop application time ranged from 3.5 minutes to 12 minutes (mean, 6.1). The actual cervical cutting time that was measured after the loop was placed around the cervix and the monopolar current was activated ranged from 15 seconds to 100 seconds (mean, 33.5). The total loop application and cutting time ranged from 4.3 minutes to 12.8 minutes (mean, 6.6). The cervical cutting time in the control group ranged from 6.5 minutes to 22 minutes (mean, 14.4). When comparing the total of the application and cutting time for the loop electrode with the cutting time in the control group, a statistically significant difference was observed in the amount of time required for amputation of the uterine corpus from the cervix. Thus, cervical cutting time was reduced even though total time

**Table 1.**  
Patient Characteristics

	L. Loop Min-Max	L. Loop Mean	L. Loop Standard Deviation	Control Min-Max	Control Mean	Control Standard Deviation
Age (yrs)	30-57	43.6	6.03	31-46	41.6	4.9
Parity	0-5	1.7	1.44	0-2	1.57	0.9
BMI (kg/m <sup>2</sup> )	19-44	29.83	7.13	20.5-48	31.6	0.1
Uterine weight (g)	57-290	148.3	80.81	60-475	174	121.8

may or may not have been shorter for the entire surgical procedure.

The average postoperative pain score for both groups, according to the VAS (Visual analog scale),<sup>0-10</sup> was 3.2. The mean hospital stay for the study patients was 32 hours (range, 23 to 120). The mean hospital stay for the control group was 29 hours (range, 23 to 48).

Complications were encountered in 3 patients (11%). However, only 1 patient had a relatively major complication, incisional hernia (3.7%). On postoperative day 4, this patient was reoperated on and left the hospital the next day. Two patients (7.4%) had minor complications. One case of liver puncture by a Veress needle secondary to left upper quadrant entry was treated expectantly. This injury was the result of a seldom seen, very rare occurrence in some patients where enlargement of the left lobe of the liver may cause it to be just below the point of needle insertion. Also, one case of urinary tract infection occurred. None of these complications were related to the use of the loop device.

## DISCUSSION

It has been shown in other studies<sup>3,4</sup> that supracervical hysterectomy performed by laparoscopy (LSH) results in a reduction in blood loss, operative time, and surgical complications compared with total laparoscopic hysterectomies and abdominal hysterectomies. There is also less risk of postoperative pain and infection, vault prolapse, enterocele, and painful vaginal scarring in addition to shorter hospital stay and convalescence, and lower overall cost. Dequesne et al<sup>2</sup> reported that a further decrease in operating time can be achieved with the loop technique for uterine corpus amputation.

Safety has always been an important consideration when choosing a supracervical procedure over total hysterectomy. Amputation of the uterine corpus at the level of the internal ostium is the crucial and technically most challenging part of the supracervical hysterectomy. Even in the case of a small uterus, it is sometimes difficult to perform a quick, safe resection. Traditionally, the resection is performed with unipolar scissors or the Harmonic scalpel. Both methods produce a great amount of smoke and charring. Precise dissection is difficult to perform because bowel is often in the way and attention should be paid to not injure the pelvic sidewall and the ureters. This risk seems to be reduced considerably with the use of the electro-surgical loop electrode. The loop electrode can be relatively easily placed around the cervix. Because a large

portion of the loop is electrically insulated, the electrode can safely be used for cervical transection without fear of collateral damage. The main advantages of the loop electrode are safety, precision of the cut, and reduced operating time. The advantage of laparoscopic supracervical hysterectomy is reduced operating time.<sup>3,5,6</sup> We believe that further reduction in the operative time can be achieved with the use of the Lap Loop electrode.

Total operative time in this study was approximately 140 minutes. This relatively lengthy time may be explained by the fact that all of the procedures were performed by residents in a training setting and that cystoscopy was performed routinely on all patients to ensure ureteral integrity. Although not statistically significant, we achieved shorter operative times in the control group. Surgical times with the Loop were longer because we first used it when we began performing LSH and then started using other techniques on subsequent patients. Perhaps our longer surgical times resulted from our learning curve. The length of the entire hysterectomy in this study is not relevant because we have clearly demonstrated that the cervical cutting time is much shorter with the Loop compared with cutting time in other conventional methods. The Loop applies only to that particular step of this procedure that is also the most complex and requires the greatest surgical skill.

The statistically significant difference was observed in the time required to amputate the uterine corpus in the Lap Loop group compared with that in the control. The mean application and cutting time for the Lap Loop electrode in this study was 6.6 minutes. The mean cutting time with laparoscopic scissors or Harmonic scalpel was 14.4 minutes.

The use of the Lap Loop electrode considerably simplified cervical amputation and decreased the time required for the detachment of the uterine corpus, which many consider the more difficult part of laparoscopic subtotal hysterectomy. As experience in performing these procedures increased, operative times and blood loss improved. This may explain the fact that although not statistically significant, operating time and blood loss were smaller in the control group than in the Lap Loop group.

Two minor complications and only one relatively major complication, an incisional hernia, occurred in the study. The hernia occurred in an open laparoscopy case. The hernia patient was taken to the operating room on postoperative day 4 and was discharged home the next day. The minor complication was puncture to the left lobe of the liver with the Veress needle during left upper quadrant

insufflation that was treated expectantly. This injury resulted from the rare occurrence of a patient with an enlarged left lobe of the liver. Another patient had a urinary tract infection. There were no complications related to the new device. One patient from the Lap Loop group developed an ectopic pregnancy 4 months after hysterectomy and was treated by laparoscopic salpingectomy.<sup>7</sup> We do not believe that this unusual incident was related to the use of the device at the time of the hysterectomy. Dequesne et al<sup>2</sup> reported no complications in their 127 patients operated on with this new device.

The mean estimated blood loss in the study patients was 205 mL, and no patients required a blood transfusion. The estimated blood loss in the control group was not statistically different from blood loss in the study group. The average postoperative pain score was 3.2 on a visual assessment (VAS) pain scale of 1 to 10. The mean hospital stay was 32 hours, which means that most of the patients were able to leave the hospital the day after surgery without problems. The majority of the patients were discharged home within the 23-hour admit policy fulfilling the criteria for the outpatient procedure. The main advantages of the new electro-surgical loop system is the simplicity of use combined with increased safety, reduced time required for cervical amputation, and the precision of the cervical cut.

## CONCLUSION

The benefits of laparoscopic supracervical hysterectomy clearly outweigh the risks. An electro-surgical loop has

been designed and successfully used to decrease the time required and to facilitate safer, quicker transection of the uterine cervix during LSH for benign uterine conditions.

## References:

1. Kives SL, Levy BS, Levine RL. Laparoscopic-assisted vaginal hysterectomy: American Association of Gynecologic Laparoscopist 2000 Member Survey. *J Am Assoc Gynecol Laparosc.* 2003; 10(2):135–128.
2. Dequesne J, Schmidt N, Fryman R. A new electro-surgical loop technique for laparoscopic supracervical hysterectomy. *Gynaecol Endosc.* 1998;7:29–32.
3. Lyons TL. Laparoscopic supracervical hysterectomy: a comparison of morbidity and mortality results with laparoscopically assisted vaginal hysterectomy. *J Reprod Med.* 1993;38:763–767.
4. Donnez I, Nisolle M, Smets M, Polet R, Bassil S. Laparoscopic supracervical (subtotal) hysterectomy: a first series of 500 cases. *Gynaecol Endosc.* 1997;6:73–76.
5. Lalonde CJ, Daniell JF. Early outcomes of laparoscopic-assisted vaginal hysterectomy versus laparoscopic supracervical hysterectomy. *J Am Assoc Gynecol Laparosc.* 1996;3:251–256.
6. Richards SR, Simpkins S. Laparoscopic supracervical hysterectomy versus laparoscopic-assisted vaginal hysterectomy. *J Am Assoc Gynecol Laparosc.* 1995;2:431–435.
7. Pasic R, Tolar B, Scobie J. Ectopic pregnancy months after laparoscopic supracervical hysterectomy. *J Am Assoc Gyn Laparosc.* 2004;11(1):67–68.