



Case report

Surgically managed acute Page kidney following renal biopsy-A case report

Niroshan V.^a, Balagobi B.^{a,*}, Brammah T.^b, Weerasinghe N.^c, Gowribahan T.^c^a University Surgical Unit, Teaching Hospital of Jaffna, Sri Lanka^b University Medical Unit, Teaching Hospital of Jaffna, Sri Lanka^c Urology Unit, Teaching Hospital of Jaffna, Sri Lanka

ARTICLE INFO

Keywords:

Acute Page kidney
Renal biopsy
Urological surgery
RAAS activation
Hypertension
Case report

ABSTRACT

Introduction and importance: Renal biopsy performed in native or transplanted kidney is considered a safe procedure. However, as it is an invasive procedure bleeding related complications do occur. Bleeding complications such as macroscopic hematuria, renal hematoma, blood transfusion, and rarely nephrectomy and death have been reported in various studies. Acute Page kidney (APK) is a rare complication of post renal biopsy bleeding. **Case presentation:** In this case report we present a case history of a 46-year-old patient complicated with APK, following a native kidney biopsy. Early surgical exploration and evacuation of large hematoma resulted in a favorable outcome.

Clinical discussion: APK results from external compression of kidney and compression of the parenchyma can compromise the intra renal blood flow and cause renal impairment, activation of Renin-Angiotensin-Aldosterone System (RAAS) leads to systemic hypertension.

Conclusion: Awareness, early recognition and timely intervention in APK, in a post renal biopsy bleeding is necessary to prevent poorer outcomes, especially progressively large hematoma is present and response to medical management inadequate.

1. Introduction

Renal biopsy is a diagnostic procedure performed in native and transplanted kidneys. It is performed percutaneously usually with real time ultrasonographic guidance under local anesthesia. It is considered a safe procedure with minimum complications when strict biopsy protocols are observed [1]. In this procedure bleeding is the most common complication and it can occur in three sites: into the collecting system, underneath the renal capsule and in perinephric spaces [2]. APK or Page phenomenon (PP) is a treatable cause of secondary hypertension which results from external compression of kidney [3]. This paper is aimed to bring awareness of this uncommon complication following native kidney renal biopsy; we present a case report of a patient with APK, its acute presentation, management with timely surgical intervention and prevention. This case report has been reported in line with the SCARE 2020 criteria [4].

2. Case presentation

A 46-year-old apparently healthy female, on routine health check-up

in Well Women Clinic was found to have nephrotic range of proteinuria. She also had moderate hepatosplenomegaly with normocytic normochromic anemia. Real time ultrasound guided renal biopsy was performed for diagnostic purpose. It was performed by an experienced nephrologist on the left side, as per the standard protocol and there were no immediate post procedural complications. On the following day of procedure, she developed painless visible hematuria. Ultra-sonographic study carried out on the day failed to show any significant perinephric hematoma. But her hemoglobin dropped and continued to drop over next 48 h from 9.4 to 6.8 mg/dl requiring three units of blood transfusion. Bleeding tendencies and coagulation defects were extensively investigated and turned out to be negative. As rescue therapy tranexamic acid was started along with three pints of fresh frozen plasma. On the 4th day following the procedure, she developed worsening ipsilateral loin pain on the side of the renal biopsy, and her blood pressure became elevated. Serum creatinine rose continually at the same time from 124 $\mu\text{mol/l}$ to 240 $\mu\text{mol/l}$.

Computed tomography (CT) multi-phase protocol study performed on the 5th day of post procedure revealed a large left perinephric hemotoma with lower pole contrast leak at the venous phase (Fig. 1).

* Corresponding author.

E-mail address: b.balagobi@yahoo.com (B. Balagobi).<https://doi.org/10.1016/j.ijscr.2022.107641>

Received 2 August 2022; Received in revised form 30 August 2022; Accepted 30 August 2022

Available online 13 September 2022

2210-2612/© 2022 The Authors. Published by Elsevier Ltd on behalf of IJS Publishing Group Ltd. This is an open access article under the CC BY-NC-ND license (<http://creativecommons.org/licenses/by-nc-nd/4.0/>).

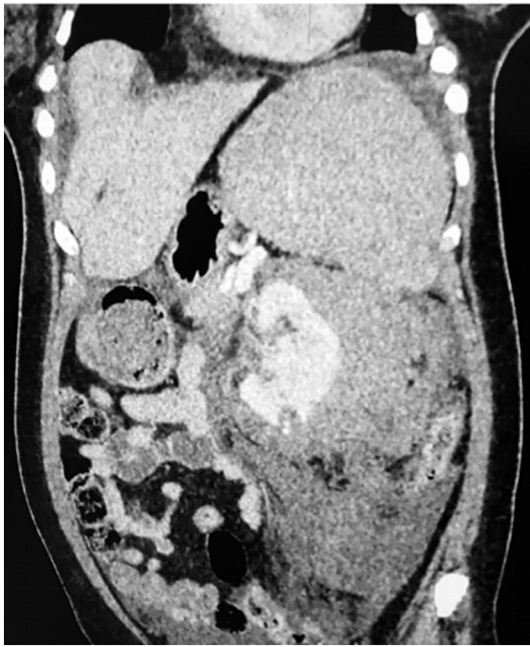

Fig. 1. Contrast computed tomography (CT) (coronal section) shows large left perinephric hematoma with compressed, medially displaced kidney with small renal infarction and contrast leak at biopsy site (marked with a pointer).

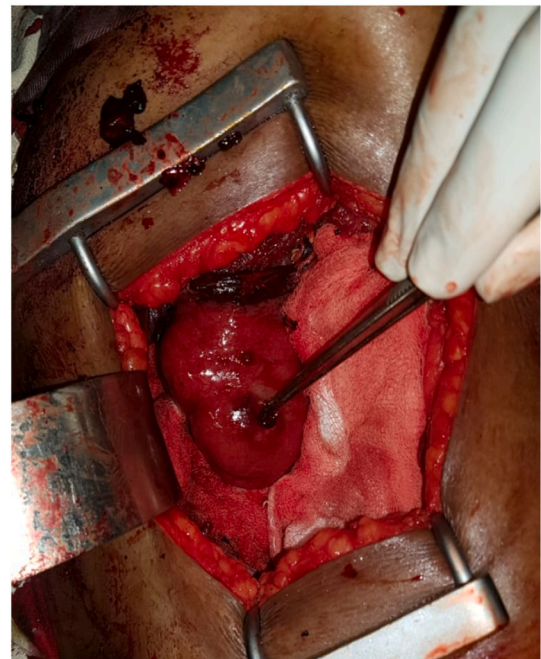


Fig. 2. Oedematous left kidney after clearance of massive perinephric hematoma via left loin incision (retroperitoneal approach), forceps pointing the biopsy site with visible small area of infarction and active bleeding.

The following day, the patient developed hypertensive emergency and acute pulmonary oedema with a blood pressure of 180/110 mm Hg. Her troponin I value was elevated as well, though there were no significant changes in the electrocardiography (ECG) or transthoracic echocardiography. A decision was made to proceed with left side renal exploration in multidisciplinary team meeting consisted of two nephrologists, three urologists and an interventional radiologist: considering the severity of the bleeding and inadequate response to medical treatment. Interventional radiological option was considered limited due to possible distal site of bleeding and institutional limitations. Surgical intervention was carried out by three experienced and trainer level urologists, revealed a large left side perinephric hematoma (Fig. 2) within Gerota's fascia with active bleeding from the biopsy site. Hematoma evacuation nearing a volume of two liters (Fig. 3) was performed and suturing of bleeding site was successfully done via left side loin and retroperitoneal approach. Following surgery, ICU care was given, and subsequently renal function and blood pressure normalized. Patient was discharged home on post-operative day 3. She had not developed any further complications in the three months follow up and the patient was quite pleased with the outcome and effort, though she was anxious and understandably frustrated in the initial period.

3. Discussion

Page kidney or Page phenomenon results from external compression of kidney. The kidney is surrounded by smooth and tough fibrous capsule that has limited space, and fluid under the capsule or under the Gerota's fascia can cause compression of kidney resulting in Page kidney. Gerota's fascia has a larger space and can accommodate considerable amount blood or fluid before kidney parenchyma is compressed rather than sub renal capsular space [5]. Compression of the parenchyma can compromise the intra renal blood flow which activates Renin-Angiotensin-Aldosterone System (RAAS) leading to systemic hypertension. In most cases, Page kidney compression causing hypertension is extra capsular in origin as it was in our patient [6]. Post procedural bleeding following renal biopsy is one of the causes for Page kidney [7]. Age, platelet count, pre-procedure hemoglobin, lower BMI, and smaller kidney size on ultrasound; all contribute to the risk of

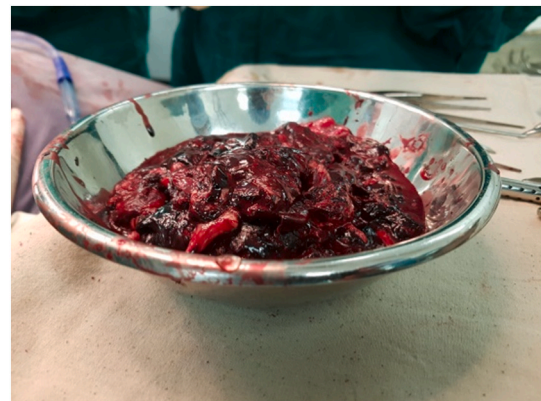

Fig. 3. Evacuated perinephric hematoma around 2 l.

bleeding. Although none of these factors are statistically significant on its own, their combination improves predictions [4]. One study showed that the perinephric hematoma was the commonest complication with an incidence of 11 %. Gross hematuria developed in 3.5 % of patients. The need for red blood cell transfusion was 1.6 % and pain developed in 4.3 % of the patients [9]. Also, Schorr et al. findings showed that post-biopsy bleeding was common, occurring in 12.8 % of the patients, but most of these events are of no clinical significance. Only 1.6 % required blood transfusion and only 0.3 % required invasive management [8].

Page kidney is an unusual complication of native renal biopsy. Hypertension is the main clinical presentation of Page kidney with refractory hypertension developing immediately after causative event [9]. It may also present with acute pain over the biopsy site, reduced urine output (mostly in single kidney or diseased contralateral kidney) and features of disseminated intravascular coagulation [6]. Ultrasound doppler may reveal reduction of blood flow in the renal artery and parenchyma of the affected kidney. Angiogram may be beneficial in the acute onset of Page kidney to visualize the bleeding artery and guide embolization. Medical management of Page kidney centers around

pharmacologic inhibition of the RAAS cascade with angiotensin converting enzyme (ACE) inhibitors or angiotensin receptor blockers (ARB). Large hematomas or expanding hematomas may not respond to medical management and they would need definitive treatment. The goal of the treatment is to relieve compression, arrest active bleeding and to restore the blood flow to the kidney.

Surgical management may involve capsulotomy, hematoma evacuation, or nephrectomy. Successful management of Page kidney refractory to medical therapy using percutaneous image-guided drainage of acute subcapsular collections has been described as well [10]. But in this case scenario minimally invasive approach was not an option as large well-formed sub Gerota's fascia hematoma compressed displaced the kidney, which needed an open surgery to evacuate hematoma and arrest bleeding. It was noted sticky, rubbery blood clots were well adhered to renal and perinephric tissue, likely contributed by tranexamic acid given to the patient before the surgical intervention. This hematoma was removed with much difficulty, and this validated the advantage of open surgical approach than minimally invasive procedures in this patient.

4. Conclusion

Though, Page kidney is one of the unusual complications of minimally invasive renal biopsy, it can present with life threatening complications. This case scenario gives some learning points to the readers to suspect Page kidney; in patients with progressively renal hematomas and post procedural hemoglobin drop, and when there is an uncontrolled hypertension developing following renal biopsy. Early imaging combined with surgical or minimally invasive interventions with a low threshold for early exploration may improve the outcome of such patients, especially when unresponsive to medical management.

Statement of informed consent

Written informed consent was obtained from the patient for publication of this case report and accompanying images. A copy of the written consent is available for review by the Editor-in-Chief of this journal on request.

Ethical approval

N/A.

Funding

None.

Guarantor

Dr. B. Balagobi, corresponding author.

Research registration number

N/A.

CRedit authorship contribution statement

Study concept - Balagobi. B

Data collection - Niroshan.V, Gowribahan. T and Weerasinghe N

Data analysis – Brammah RT.

Declaration of competing interest

There is no conflict of interest between the authors as everybody is aware of the work and participated actively and equally.

Acknowledgment

The authors wish to thank, S. Thiruvarangan, Research Assistant who assisted to this manuscript preparation and submission process in the final stage of this article.

References

- [1] K.M. Corapi, J.L. Chen, E.M. Balk, C.E. Gordon, Bleeding complications of native kidney biopsy: a systematic review and meta-analysis, *Am. J. Kidney Dis.* 60 (1) (2012) 62–73.
- [2] E.D. Poggio, R.L. McClelland, K.N. Blank, S. Hansen, S. Bansal, A.S. Bomback, P. A. Canetta, P. Khairallah, K. Kiryluk, S.H. Lecker, G.M. McMahon, P.M. Palevsky, S. Parikh, S.E. Rosas, K. Tuttle, M.A. Vazquez, A. Vijayan, B.H. Rovin, Systematic review and meta-analysis of native kidney biopsy complications, *Clin. J. Am. Soc. Nephrol.* 15 (11) (2020) 1595–1602.
- [3] K. Bakdash, K.M. Schramm, A. Annam, M. Brown, K. Kondo, J.D. Lindquist, Complications of percutaneous renal biopsy, *Semin. Interv. Radiol.* 36 (2) (2019) 97–103.
- [4] R.A. Agha, T. Franchi, C. Sohrabi, G. Mathew, The SCARE 2020 guideline: updating consensus Surgical Case Report (SCARE) guidelines, *Int. J. Surg.* 84 (2020) 226–230.
- [5] M. Sivashankar, B. Balagobi, N.D. Perera, P.G.N. Ruvinda, A case report of post-surgical page kidney due to extensive renal hematoma following percutaneous nephrolithotomy, *Int. J. Surg. Case Rep.* 86 (27) (2021), 106382.
- [6] J.D. McFadden, J.S. Hawksworth, Page kidney: an unusual complication of a renal transplant biopsy, *Case Rep. Urol.* 2018 (2018) 1–3.
- [7] T.D. Atwell, J.C. Spanbauer, B.P. McMenemy, A.H. Stockland, G.K. Hesley, C. D. Schleck, W.S. Harmsen, T.J. Welch, The timing and presentation of major hemorrhage after 18,947 image-guided percutaneous biopsies, *Am. J. Roentgenol.* 205 (1) (2015) 190–195.
- [8] W. Xie, J. Xu, Y. Xie, Z. Lin, X. Xu, X. Zhang, Y. Zhang, Adequacy and complication rates of percutaneous renal biopsy with 18- vs. 16-gauge needles in native kidneys in Chinese individuals, *BMC Nephrol.* 21 (1) (2020) 1–7.
- [9] T.R. McCune, W.J. Stone, J.A. Breyer, Page kidney: case report and review of the literature, *Am. J. Kidney Dis.* 18 (5) (1991) 593–599.
- [10] M. Schorr, P.S. Roshanov, M.A. Weir, A.A. House, Frequency, timing, and prediction of major bleeding complications from percutaneous renal biopsy, *Can. J. Kidney Health Dis.* 7 (2020).