

Remission of Prurigo Pigmentosa after Breaking Ketogenic Diet and Resuming Regular Diet

Abstract

Prurigo pigmentosa (PP) is a rare skin disorder presenting as erythematous urticarial papules on the chest and leaving reticulated pigmentation. Although the etiology of PP is unknown, conditions associated with ketosis such as diabetes mellitus, ketogenic diet (KD), and anorexia nervosa are implicated. Herein, we report a 21-year-old woman who developed PP after adhering to a KD and responded to resuming a regular diet.

Keywords: *Ketogenic diet, prurigo pigmentosa, treatment*

Introduction

Prurigo pigmentosa (PP) is a rare pruritic inflammatory dermatosis characterized by erythematous urticarial papules. It was first reported in Japan by Nagashima *et al.* In 1971^[1] PP was later coined in 1978.^[2] It typically occurs in Asian women of childbearing age, although it has also been documented in other regions and ethnicities as well as in men.^[3] The etiology of PP is largely unknown, however, various mechanical, inflammatory, and metabolic factors have been assigned to this condition. Importantly, PP has been strongly associated with conditions that commonly induce ketosis, such as restrictive diets, fasting, and uncontrolled diabetes mellitus. Resolution of PP after resuming a regular diet supported the causative role of the ketogenic state in this disease. In addition, certain systemic conditions including adult-onset Still's disease, atopy, *Helicobacter pylori* infection, and Sjogren's syndrome have also been reported in association with PP.^[4]

The ketogenic diet (KD), a well-established treatment for childhood epilepsy has been increasingly used for the management of obesity and diabetes mellitus. KD is a very low carbohydrate, moderate protein, and high-fat diet that induces hepatic production of ketone bodies through activation of hepatic ketogenesis. During this process, fat is broken down into fatty acids and ketone bodies.^[5]

This is an open access journal, and articles are distributed under the terms of the Creative Commons Attribution-NonCommercial-ShareAlike 4.0 License, which allows others to remix, tweak, and build upon the work non-commercially, as long as appropriate credit is given and the new creations are licensed under the identical terms.

For reprints contact: WKHLRPMedknow_reprints@wolterskluwer.com

PP goes through three stages; in the early stage, the disease presents as pruritic urticarial plaques or papules clinically and superficial perivascular neutrophilic infiltration in pathology. The next stage manifests as crusted erythematous papules and papulovesicles with spongiosis and necrotic keratinocytes. In the last stage, pigmented macules are seen with lymphocytic infiltrate and melanophages in the papillary dermis.^[6]

In this report, we describe a 21-year-old woman who developed PP after adhering to a KD and responded to resuming a regular diet.

Case Report

An otherwise healthy 21-year-old woman presented with itchy skin lesions over the chest and neck evolving for 2 weeks. The rash occurred 1 week after starting a carbohydrate-restricted KD.

The skin examination showed symmetrically distributed erythematous papules interspersed with dark brown pigmentation in a reticulated pattern in the intermammary and submammary regions, and the neck [Figure 1a and b].

A punch biopsy was performed; histopathological examination of hematoxylin and eosin-stained tissue revealed acanthotic epidermis with prominent spongiotic vesicles containing lymphocytes and few neutrophils. Papillary dermis revealed superficial perivascular

How to cite this article: Daneshpazhooh M, Nikyar Z, Kamyab Hesari K, Rostami E, Taraz Jamshidi S, Mohaghegh F. Remission of prurigo pigmentosa after breaking ketogenic diet and resuming regular diet. *Adv Biomed Res* 2022;11:70.

Maryam Daneshpazhooh¹, Zahra Nikyar^{1,2}, Kambiz Kamyab Hesari¹, Ehsan Rostami¹, Shirin Taraz Jamshidi³, Fatemeh Mohaghegh²

¹Department of Dermatology, Razi Hospital, Tehran University of Medical Sciences (TUMS), Tehran, ²Department of Dermatology, Skin Diseases and Leishmaniasis Research Center, School of Medicine, Isfahan University of Medical Sciences, Isfahan, ³Cutaneous Leishmaniasis Research Center, Mashhad University of Medical Sciences, Mashhad, Iran

Address for correspondence:

Dr. Zahra Nikyar,
Department of Dermatology,
Razi Hospital, Tehran University
of Medical Sciences, Tehran,
Iran.
E-mail: zahranikyar@
yahoo.com

Received: 26 May 2021

Revised: 10 June 2021

Accepted: 15 June 2021

Published: 30 August 2022

Access this article online

Website: www.advbiores.net

DOI: 10.4103/abr.abr_138_21

Quick Response Code:



infiltrate of lymphocytes and scattered eosinophils [Figure 2a and b]. Dyskeratotic cells were noted in higher levels of epidermis and exocytosis of lymphocytes and red blood cells were evident.

A diagnosis of PP was made based on clinical and pathological findings. The patient was advised to discontinue the KD and take minocycline.

However, she opted to resume a regular diet without taking the drug. She came to her follow-up appointment after 2 months while all of her lesions were resolved, leaving only light-brown postinflammatory pigmentation on her chest and neck [Figure 3a and b].

After 12 months of follow-up since she resumed a higher carbohydrate diet, there has been no recurrence.

Discussion

The term “PP” was first mentioned in the literature in 1978, 7 years after its first description by Nagashima *et al.*^[1,2]

PP typically affects Japanese women aged 20–30, however, there are increasing reports of the disease in Middle Eastern and Western countries. Less than 300 cases of PP have been published so far.^[7,8]

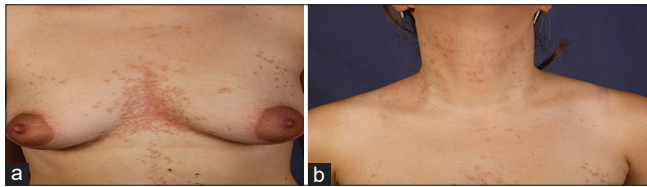


Figure 1: (a) Prurigo pimentosa: Erythematous papules and plaques on the chest. (b) Prurigo pigmentosa: Erythematous papules on the neck

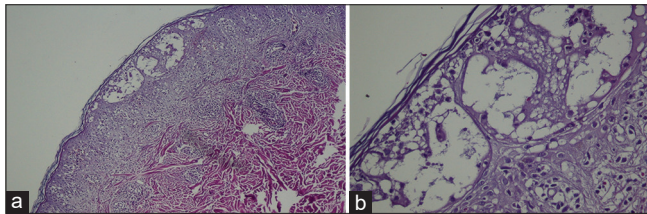


Figure 2: (a): ×10: Low power examination reveals an acanthotic epidermis with some spongiotic vesicles. Superficial dermis is infiltrated by lymphocytes and few eosinophils. (b) ×100: An acanthotic epidermis with prominent spongiotic vesicles containing lymphocytes and few neutrophils. Papillary dermis reveals superficial perivascular infiltrate of lymphocytes as well as few eosinophils

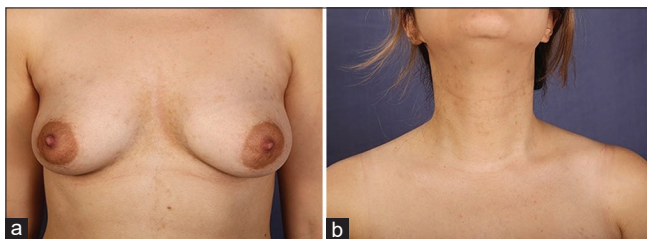


Figure 3: (a) Her lesions resolved leaving only multiple post-inflammatory hyperpigmentation (PIH) on her chest. (b) Her lesions resolved leaving only multiple PIH on her neck

PP is characterized by erythematous pruritic coalescing papules arranged in a reticulate pattern resolving with postinflammatory hyperpigmentation. Pustular, vesicular, and bullous variants have been reported.^[4,9,10]

Each stage of PP has distinct histopathological features. The early stage is characterized by a superficial and perivascular dermal neutrophilic infiltration along with papillary dermal edema and slight spongiosis. In the fully developed lesions, a heavier dermal infiltration of lymphocytes, neutrophils, and eosinophils in a lichenoid pattern, reticular degeneration of basal cell layer, and a variable degree of spongiosis and necrotic keratinocytes are seen. In the resolved lesions, a sparse lymphocytic dermal infiltration exists along with upper dermal melanophages.^[11]

Although the pathogenesis is incompletely understood, several factors have been strongly associated with the condition, which may be grouped as metabolic (diabetes and ketosis), hormonal (pregnancy and menstruation), and physical factors (skin friction, trauma, and acupuncture).^[4]

Ketosis has frequently been linked to PP development in various reports. This occurs with diabetes mellitus, fasting, dieting, anorexia nervosa, hyperemesis gravidarum of pregnancy, and following bariatric surgery, all of which are associated with PP.^[7]

It has been hypothesized that ketone bodies play a role in inducing perivascular inflammation, primarily through neutrophils, thus explaining the positive response to medications suppressing neutrophil-mediated processes such as dapsone and tetracyclines. Furthermore, ketone bodies can directly affect cells by causing intracellular damage.^[12] Reduced insulin levels, which have been reported to occur after bariatric surgery, may also contribute to the development of PP.^[13]

KD is one of the main risk factors for PP. It consists of reducing the carbohydrate content in the diet usually to <50 g/d while increasing the fraction of fat and protein intake. The popularity of this dietary regimen is growing worldwide.^[14] As a result, the reports of PP following KD, also known as “keto-rash” have increased on social media. KD is also used for epilepsy, Alzheimer’s dementia, Parkinson’s disease, brain, and other cancers, obesity, autism spectrum disorder, and endurance athletics.^[5]

Bariatric surgeries have been linked to PP in some recent studies.^[12,15] It is conceivable that underestimation or underdiagnosis in bariatric surgery could explain the low numbers of cases of PP. Since such procedures are becoming increasingly popular, physicians should be informed about this complication.

The treatment of PP following KD consists of the resumption of a balanced diet and the adjunction of antibiotics that inhibit neutrophil chemotaxis, such as

minocycline, doxycycline, and dapsona.^[4,5,12] Isotretinoin has also been used successfully in PP.^[16]

This case report emphasizes the etiologic role of KD in PP and demonstrates that diet modification alone can be curative for KD-induced PP without the need for any other intervention as reported in a few other studies.

Conclusion

KD and bariatric surgery are currently growing in popularity. When dealing with patients who present with reticulated red papular lesions leaving hyperpigmentation compatible with PP, it is important to inquire about recent diet, bariatric surgery, or other conditions that may cause ketosis. Resuming a regular carbohydrate-rich diet may be recommended as the first step of treatment without an immediate antibiotic prescription. In other words, antibiotics should be kept as a second step or in noncompliant patients, and withdrawal of the KD is sufficient to resolve symptoms with no other intervention.

Declaration of patient consent

The authors certify that they have obtained all appropriate patient consent forms. In the form, the patient has given her consent for her images and other clinical information to be reported in the journal. The patient understands that his name and initials will not be published and due efforts will be made to conceal identity, but anonymity cannot be guaranteed.

Financial support and sponsorship

Nil.

Conflicts of interest

There are no conflicts of interest.

References

1. Nagashima M, Ohshiro A, Shimizu N. A peculiar pruriginous dermatosis with gross reticular pigmentation [in Japanese]. *Jpn J Dermatol* 1971; 81:78-91.

2. Nagashima M. Prurigo pigmentosa: Clinical observations of our 14 cases. *J Dermatol* 1978;5:61-7.
3. Michaels JD, Hoss E, Dicaudo DJ, Price H. Prurigo pigmentosa after a strict ketogenic diet. *Pediatr Dermatol* 2015;32:248-51.
4. Almaani N, Al-Tarawneh AH, Msallam H. Prurigo pigmentosa: A clinicopathological report of three middle eastern patients. *Case Rep Dermatol Med* 2018;2018:9406797.
5. Maco MW, Lee E, Wu Y, Lee R. Treatment of prurigo pigmentosa with diet modification: A medical case study. *Hawaii J Med Public Health* 2018;77:114-7.
6. Oh YJ, Lee MH. Prurigo pigmentosa: A clinicopathologic study of 16 cases. *J Eur Acad Dermatol Venereol* 2012;26:1149-53.
7. Hartman M, Fuller B, Heaphy MR. Prurigo pigmentosa induced by ketosis: Resolution through dietary modification. *Cutis* 2019;103:E10-3.
8. Asgari M, Daneshpazhooh M, Chams Davatchi C, Böer A. Prurigo pigmentosa: An underdiagnosed disease in patients of Iranian descent? *J Am Acad Dermatol* 2006;55:131-6.
9. Kim TI, Choi JW, Jeong KH, Shin MK, Lee MH. Pustular prurigo pigmentosa treated with doxycycline. *J Dermatol* 2016;43:965-6.
10. Daneshpazhooh M, Safar F, Barikbin B, Safee-naraghi Z, Asgari M, Chams-Davatchi C. Vesicular prurigo pigmentosa in a 16-year-old girl. *Nouv Dermatol* 2004;23:599-603.
11. Böer A, Misago N, Wolter M, Kiryu H, Wang XD, Ackerman AB. Prurigo pigmentosa: A distinctive inflammatory disease of the skin. *Am J Dermatopathol* 2003;25:117-29.
12. Alshaya MA, Turkmani MG, Alissa AM. Prurigo pigmentosa following ketogenic diet and bariatric surgery: A growing association. *JAAD Case Rep* 2019;5:504-7.
13. Abbass M, Abiad F, Abbas O. Prurigo pigmentosa after bariatric surgery. *JAMA Dermatol* 2015;151:796-7.
14. Paoli A, Rubini A, Volek JS, Grimaldi KA. Beyond weight loss: A review of the therapeutic uses of very-low-carbohydrate (ketogenic) diets. *Eur J Clin Nutr* 2013;67:789-96.
15. Alsebayel MM, Ghobara YA, Al-Issa A. Facial prurigo pigmentosa after bariatric surgery. *Cureus* 2020;12:e6909.
16. Akoglu G, Boztepe G, Karaduman A. Prurigo pigmentosa successfully treated with low-dose isotretinoin. *Dermatology* 2006;213:331-3.