

Atypical Manifestations in Classic Kaposi Sarcoma: Case Series of Two Patients HIV - Negative

Tiziana Peduto, Francesco Cillo, Paola Nappa, Mario Delfino, Gabriella Fabbrocini, Maria Ferrillo*

Department of Dermatology, University of Naples Federico II, Via Pansini 5, 80131 Napoli, Italy

Abstract

Citation: Peduto T, Cillo F, Nappa P, Delfino M, Fabbrocini G, Ferrillo M. Atypical Manifestations in Classic Kaposi Sarcoma: Case Series of Two Patients HIV - Negative. Open Access Maced J Med Sci. 2019 Mar 30; 7(6):1021-1024. https://doi.org/10.3889/oamjms.2019.162

Keywords: Eye; Classic Kaposi sarcoma; Chemotherapy; Vinblastine

***Correspondence:** Maria Ferrillo, Department of Dermatology - University of Naples Federico II, Via Pansini 5, 80131 Napoli, Italy. E-mail: mariaferrillo11@gmail.com

Received: 27-Dec-2018; **Revised:** 20-Mar-2019; **Accepted:** 21-Mar-2019; **Online first:** 27-Mar-2019

Copyright: © 2019 Tiziana Peduto, Francesco Cillo, Paola Nappa, Mario Delfino, Gabriella Fabbrocini, Maria Ferrillo. This is an open-access article distributed under the terms of the Creative Commons Attribution-NonCommercial 4.0 International License (CC BY-NC 4.0)

Funding: This research did not receive any financial support

Competing Interests: The authors have declared that no competing interests exist

BACKGROUND: Kaposi's sarcoma (KS) is a tumour of endothelial, blood and lymphatic cells, caused by an infection with human herpesvirus-8 (HHV-8). The skin lesions of KS, especially of the classical or Mediterranean variant (CKS), are represented by red-purple macules, plaques and nodules, localised mainly on the extremities.

CASE REPORT: This case series intend to describe multifocal atypical kaposian manifestations in two HIV negative subjects, affected by CKS, treated with successful chemotherapy.

CONCLUSIONS: Although atypical manifestations are extremely rare events, we suggest an accurate, objective examination because a prompt diagnosis can lead to a vital intervention in the patient's health and sometimes to the identification of the disease itself.

Introduction

Kaposi sarcoma (KS) is a malignant neoplasm with multifocal diffusion, originating from endothelial cells, associated with human herpesvirus-8 (HHV-8). HHV-8 infection remains latent, and most people do not develop KS until their immune system is affected by the disease, such as human immunodeficiency virus (HIV), or by drugs are given after an organ transplant [1].

According to the literature, there is still no standard treatment of CKS. The prognosis and choice of treatment depend on the type of KS, the global assessment of the patient, in particular, the patient's immune system, whether cancer has just been diagnosed or has recurred [2].

Herein we present two cases of an HIV-

negative Mediterranean male with disseminated skin KS treated with different therapy, obtaining a remission of clinical manifestations.

Case 1

A 78-year-old Italian man attended our attention in January 2018 for a 2-years history of red lesions on his lower legs, treated incorrectly for chronic stasis dermatitis. His medical history was relevant for compensated type 2 diabetes mellitus and hypertension. Clinical examination showed multiple blue and purplish red nodules varying in size from 1-3 cm, affecting the lower legs and forefoot, abdomen, neck, oral mucosa, tongue and genital region (Figure 1). A sample of the skin biopsy showed proliferation of

fusiform cells and endothelial cells with extravasation of red blood cells and intervening slit-like spaces. Endothelial cells were positive HHV-8 by immunohistochemistry.

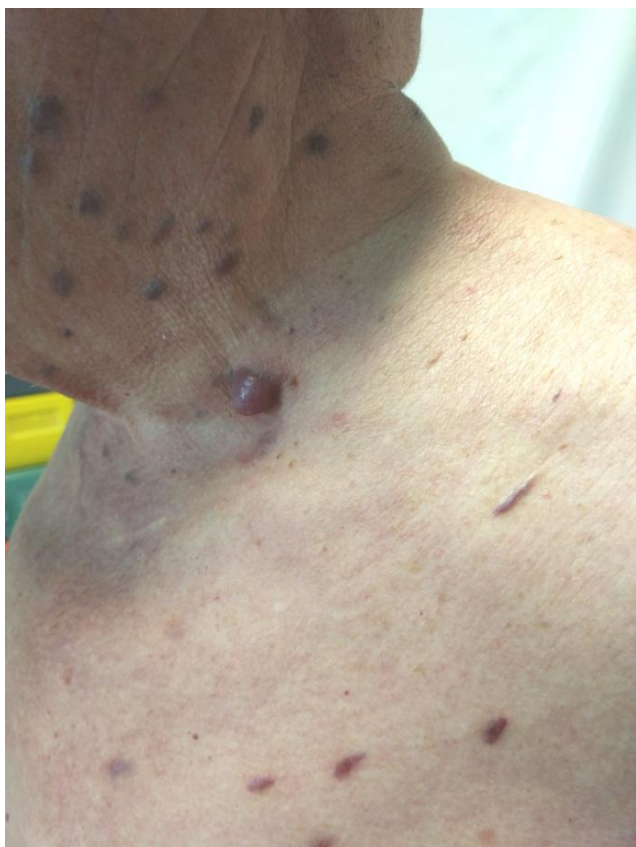

Figure 1: Multiple blue and purplish red nodules varying in size from 1-3 cm affecting the neck

These findings were consistent with Kaposi Sarcoma diagnosis, nodular stage. Laboratory investigations showed HIV test negativity (antibodies anti HIV1/2-antigen p24), White Blood Cells $10.57 \times 10^3/\mu\text{L}$ (normal range 4.8-10.8), Red Blood Cells $4.16 \times 10^6/\mu\text{L}$ (4.2-5.6), Platelets $234 \times 10^3/\mu\text{L}$ (130-400); Hb 15 g/dL (12-17.5), liver function [ALT 21 U/L (0 – 55); AST 22 U/L (0 – 34)] and renal function [creatinine 0.7 mg/dL (0.7-1.2)] tests within the normal limit. Chest X-ray, abdominal and lymph node ultrasound and low gastrointestinal endoscopy were normal. Faecal occult blood test and video-laryngoscopy were performed, and no abnormalities were documented. Considering widespread skin involvement (> 25 lesions) and oral lesions, he was put on monthly chemotherapy with vinblastine dose of 10 mg. White blood count was normal, and patient-reported only nausea. The clinical examination nine months after starting therapy showed clinical improvement with reduction of nodules dimension (Figure 2). After one year, no recurrence was observed.

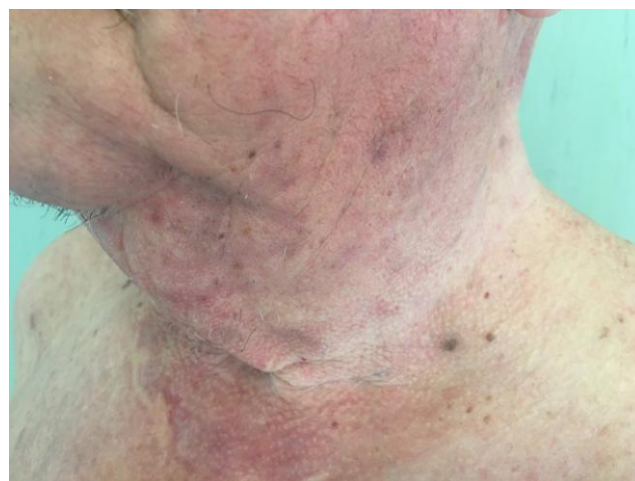

Figure 2: Clinical improvement with reduction/absence of nodules dimension

Case 2

An 82-year-old Italian man HCV-positive (HCV antibodies positive) and HIV negative (antibodies anti-HIV1/2-antigen p24), with a 5-year history of KS, presented to our attention in March 2015. Clinical examination showed a red-brownish nodular lesion on the left nostril, about 1 cm in diameter, without systemic symptoms. Excisional biopsy and histological examination were performed with confirmation of KS' diagnosis: the lesion presents angiomatous areas surrounded by spindle cells (HHV-8 positive by immunohistochemistry), perivascular inflammatory infiltrate with T and B cells. Almost simultaneously, nodular lesions confluent into plaques in the lower limbs appeared, for which cycles of chemotherapy with vinblastine (10 mg) began one time a month, with improvement of manifestations without side effects (white blood cells [$7.87 \times 10^3/\mu\text{L}$ (4.8-10.8)], transaminases [ALT 11 U/L (0 – 55); AST 18 U/L (0 – 34)]).

In August 2017, chemotherapy was discontinued due to an acute myocardial infarction. In November of the same year, for the improvement of the cardiac clinical conditions and previous oncological counselling, therapy with vinblastine resumed under strict cardiological control. After 7 months, the patient reported the appearance of two adjacent intraorbital nodules, the medial area of the left tear chamber, of a brownish red colour from the diameter of about 5 mm, indicative of kaposian lesions (Figure 3).

Being the lesion particularly proliferative and not responsive to vinblastine, we proceeded with the removal of the same to restore the visual features and avoid the further increase.

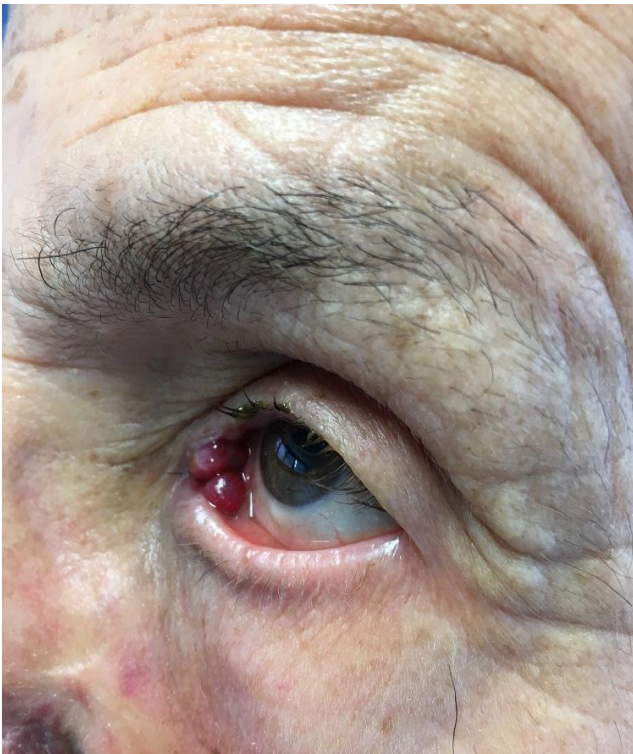

Figure 3: Two adjacent intraorbital nodules, the medial area of the left tear chamber, of a brownish red colour from the diameter of about 5 mm

The operation, performed at the eye clinic (May 2018), and the subsequent histological examination confirmed KS. Currently, the patient practices cycles of liposomal doxorubicin, finding a containment of the manifestations. After six months, there are no other ocular manifestations (Figure 4).

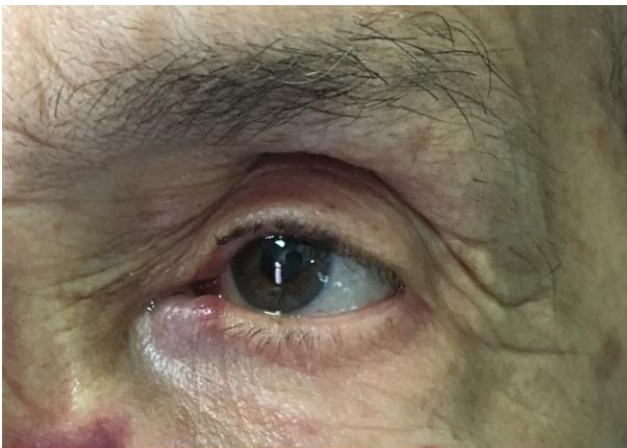


Figure 4: Complete resolution after surgical treatment

Discussion

KS is an angioproliferating skin cancer can involving mucosa and viscera, like a respiratory and gastrointestinal system [3].

KS is one of the most common sarcomas in patients with AIDS, but in its classical form (CKS) it is found widespread especially in the Mediterranean area [4]. The epidemiology of KS partially reflects the seroprevalence of HHV-8 infection. HHV-8 infection has a low incidence, less than 5%, in Asia, Northern Europe, Australia and America, while it increases in Mediterranean countries (with diffusion in southern Italy) and in Africa sub-Saharan, with the preferential non-sexual transmission as determined by the high incidence of seropositive children [5]. The CKS prevails in the Mediterranean basin. In America, the percentage is higher in AIDS patients. The highly active antiretroviral therapy in the treatment of HIV disease showed a reduction of AIDS-associated sarcoma Kaposi [6].

Head and neck involvement in HIV-negative patients is uncommon, reported in less than 5% of classical forms. Classical skin lesions generally consist of angioedematous plaques and nodules located on the limbs, on the contrary, HIV-related form is characterised by disseminated cutaneous manifestations, with oral and craniofacial involvement in about 95% of patients [7], [8]. However, in our cases, chemotherapy with vinblastine seems to be effective, with control of atypical manifestations without evidence of skin recurrence or visceral involvement. Ocular involvement, although atypical, is more frequent in the HIV-related form where it may even represent the first clinical sign [9]. Our experience proves the importance of accurately identifying the ocular involvement of Kaposi's sarcoma, which can be confused with simple angiomatous lesions. Although it is an extremely rare event, a prompt diagnosis can lead to a vital intervention in the patient's health and sometimes to the identification of the disease itself. Our cases show that the cutaneous manifestations of CKS do not always follow the trend of the Mediterranean variant, can take the typical manifestations of an HIV sarcoma preserving responsiveness to the therapy with vinblastine.

References

1. Dittmer DP, Damania B. Kaposi sarcoma-associated herpesvirus: immunobiology, oncogenesis, and therapy. *J Clin Invest.* 2016; 126(9):3165-75. <https://doi.org/10.1172/JCI84418> PMID:27584730 PMCID:PMC5004954
2. Cattelan A, Trevenzoli M, Aversa S. Recent advances in the treatment of AIDS-related Kaposi's sarcoma. *Am J Clin Dermatol.* 2002; 3(7):451-62. <https://doi.org/10.2165/00128071-200203070-00002> PMID:12180893
3. Meduri GU, Stover DE, Lee M, Myskowski PL, Caravelli JF, Zaman MB. Pulmonary Kaposi's sarcoma in the acquired immune deficiency syndrome. Clinical, radiographic, and pathologic manifestations. *Am J Med.* 1986; 81(1):11-8. [https://doi.org/10.1016/0002-9343\(86\)90175-0](https://doi.org/10.1016/0002-9343(86)90175-0)

4. Stiller CA, Trama A, Brewster DH, Verne J, Bouchardy C, Navarro C, et al. Descriptive epidemiology of Kaposi sarcoma in Europe. Report from the RARECARE project. *Cancer Epidemiol*. 2014; 38(6):670-8. <https://doi.org/10.1016/j.canep.2014.09.009> PMID:25454979
5. Schulz TF. The pleiotropic effects of Kaposi's sarcoma herpesvirus. *J Pathol*. 2006; 208(2):187-98. <https://doi.org/10.1002/path.1904> PMID:16362980
6. Jones JL, Hanson DL, Dworkin MS, Ward JW, Jaffe HW. Effect of antiretroviral therapy on recent trends in selected cancers among HIV-infected persons. Adult/Adolescent Spectrum of HIV Disease Project Group. *J Acquir Immune Defic Syndr*. 1999; 21:S11-7. PMID:10430212
7. Friedman-Kien AE, Saltzman BR. Clinical manifestations of classical, endemic African, and epidemic AIDS-associated Kaposi's sarcoma. *J Am Acad Dermatol*. 1990; 22(6 Pt 2):1237-50. [https://doi.org/10.1016/0190-9622\(90\)70169-I](https://doi.org/10.1016/0190-9622(90)70169-I)
8. Agaimy A, Mueller SK, Harrer T, Bauer S, Thompson LDR. Head and neck Kaposi sarcoma: clinicopathological analysis of 11 cases. *Head Neck Pathol*. 2018; 12(4): 511–516. <https://doi.org/10.1007/s12105-018-0902-x> PMID:29508130 PMCid:PMC6232196
9. Teixeira AI, Neno M, Badura R, Borges-Costa J, Filipe PL. Kaposi sarcoma of the eyelid as initial manifestation of AIDS. *Dermatol Online J*. 2016; 15(22):7.