





5. Barton LM, Duval EJ, Stroberg E, Ghosh S, Mukhopadhyay S. COVID-19 Autopsies, Oklahoma, USA. *Am J Clin Pathol*. 2020;153:725–33.

Luciana Botinelly Mendonça Fujimoto ^a,
 Silvana de Albuquerque Damasceno Ferreira ^b,
 Fabiane Braga dos Santos ^c, Carolina Talhari ^{b,d,*}
^a Department of Pathology and Legal Medicine,
 Universidade Federal do Amazonas, Manaus, AM, Brazil
^b Department of Dermatopathology, Fundação Alfredo da
 Matta de Dermatologia e Venereologia, Manaus, AM, Brazil

^c Private Clinic, Manaus, AM, Brazil

^d Department of Dermatology, Universidade do Estado do Amazonas, Manaus, AM, Brazil

*Corresponding author.

E-mail: carolinatalhari@gmail.com (C. Talhari).

Received 28 May 2020; accepted 13 August 2020

Available online 26 November 2020

<https://doi.org/10.1016/j.abd.2020.08.007>

0365-0596/ © 2020 Sociedade Brasileira de Dermatologia.

Published by Elsevier España, S.L.U. This is an open access article under the CC BY license (<http://creativecommons.org/licenses/by/4.0/>).

Eruptive lentiginosis confined to areas of regressing psoriatic plaques after adalimumab treatment^{☆,☆☆}



Dear Editor,

Eruptive lentiginosis confined to areas of regressing psoriatic plaques is a rare phenomenon. Initially described after phototherapy, several other treatment regimens used in psoriasis including topical and systemic biologic agents, have been reported to induce lentiginosis.¹ The author reports a new case of eruptive lentiginosis following treatment with adalimumab.

A 45-year-old female with no relevant medical history presented to this department with multiple brownish lesions in areas previously occupied by psoriatic plaques seven months after initiating adalimumab. She denied having applied any topical treatment or having received any sun exposure. Physical examination revealed grouped brown macules over previously affected areas (Fig. 1). The patient had suffered from chronic plaque psoriasis since adolescence, proven to be refractory to topical therapies, methotrexate, and cyclosporine. Phototherapy was not performed in this patient. She was not taking any other medications. A punch skin biopsy showed hyperpigmentation of the basal layer, consistent with lentigo. No treatment was initiated due to patient refusal. The lesions remained stable throughout one year of follow-up.

Lentigos confined to resolved psoriatic plaques have been rarely mentioned in the literature. The literature features reports following topical treatments and biological therapies used in psoriasis. Among biological therapies, eruptive lentiginosis has been reported in relation to infliximab, adalimumab, etanercept, ustekinumab and secukinumab. To the best of the author's knowledge, to date there is only one case reported associated with classic systemic therapies.²

The pathophysiology is not well documented. Some cytokines produced in psoriatic skin are known to stimulate melanogenesis and might be responsible for the lentiginosis.³ In addition, Wang et al. reported that IL-17 and TNF can affect both the growth and pigment production of melanocytes, which may contribute to the pigmentation changes associated with psoriasis.⁴ In turn, it has been suggested that eruptive lentiginosis is an exaggerated recovery in pigment production, associated with greater disease severity or greater inhibition of cytokines with treatment.¹

To date, no effective therapy has been reported. Lentiginosis appear within the first months of treatment and may persist with no or little improvement.¹ Although it does not require an interruption of the treatment, close follow-up is recommended.

In conclusion, the author presents a new case of eruptive lentiginosis confined to areas of regressing psoriatic plaques after adalimumab. Given the development of novel biological treatments and new therapeutic targets, new cases of eruptive lentiginosis are likely to appear. Clinicians need to be aware of the potential side effects of biological therapies due to their increasing use.

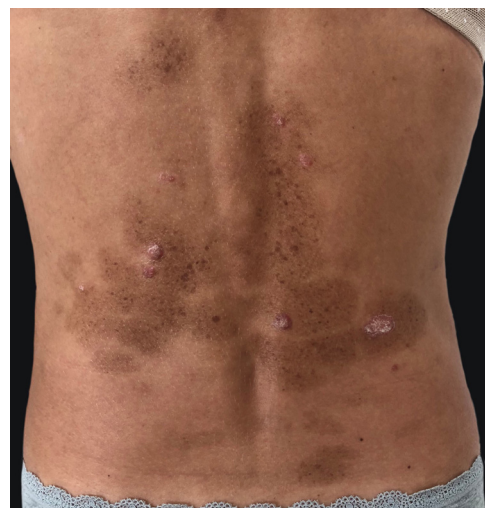

Figure 1 Multiple brownish macules in areas previously occupied by psoriatic plaques.

[☆] How to cite this article: Garcia-Souto F. Eruptive lentiginosis confined to areas of regressing psoriatic plaques after adalimumab treatment. *An Bras Dermatol*. 2021;96:113–4.

^{☆☆} Study conducted at the Department of Dermatology, Hospital Universitario de Valme, Seville, Spain.

Financial support

None declared.

Author's contributions

Fernando Garcia-Souto: Approval of the final version of the manuscript; design and planning of the study; drafting and editing of the manuscript; critical review of the literature; critical review of the manuscript.

Conflicts of interest

None declared.

References

- Micieli R, Alavi A. Eruptive lentiginosis in resolving psoriatic plaques. *JAAD Case Reports*. 2018;4:322–6.
- Singh S, Beniwal R. Methotrexate-induced eruptive lentiginosis in resolving psoriasis: a phenomenon possibly dependent on cytokine modulation. *Clin Exp Dermatol*. 2019;44:e212–3.

- Sfecci A, Khemis A, Lacour JP, Montaudié H, Passeron T. Appearance of lentiginosis in psoriasis patients treated with apremilast. *J Am Acad Dermatol*. 2016;75:1251–2.
- Wang CQF, Akalu YT, Suarez-Farinas M, Gonzalez J, Mitsui H, Lowes MA, et al. IL-17 and TNF synergistically modulate cytokine expression while suppressing melanogenesis: potential relevance to psoriasis. *J Invest Dermatol*. 2013;133:2741–52.

Fernando Garcia-Souto  *

Department of Dermatology, Valme University Hospital, Seville, Spain

* Corresponding author.

E-mail: fernandogarciasouto@gmail.com

Received 11 February 2020; accepted 2 May 2020

Available online 18 November 2020

<https://doi.org/10.1016/j.abd.2020.05.011>

0365-0596/ © 2020 Sociedade Brasileira de Dermatologia.

Published by Elsevier España, S.L.U. This is an open access article under the CC BY license (<http://creativecommons.org/licenses/by/4.0/>).

Erythema annulare centrifugum associated with chronic amitriptyline intake ^{☆,☆☆}



Dear Editor,

A 41-year-old woman presented to the hospital with a mildly pruritic exanthem which had appeared two months before. She had been presenting similar episodes for the past five years, treated with topical corticosteroids and short courses of methylprednisolone. Each episode lasted longer and was more widespread than the previous one. She denied fever or any systemic symptoms. The patient reported a history of migraines, treated with amitriptyline for the past five years and occasional anti-inflammatories. Amitriptyline was started two weeks before the first appearance of skin lesions, but the patient did not associate both events. Physical examination revealed annular and polycyclic plaques, with a trailing scale and central clearing, predominantly in lower limbs (Fig. 1). A skin biopsy from the edge of a lesion was performed, showing mild papillary edema, spongiosis, lymphocyte exocytosis and a perivascular lymphohistiocytic infiltrate in a “coat sleeve” appearance (Fig. 2). Periodic acid-Schiff staining did not show fungal forms. Fungal culture was negative. Laboratory tests including complete blood count, liver and kidney function tests, serological tests for HBV, HCV, HIVH, borrelia and syphilis,

ANA, ASLO titer, rheumatoid factor, complement, IgE levels, proteinogram, β -2 microglobulin, and thyroid function test were normal. Chest radiograph, Mantoux skin test, and abdominopelvic ultrasonography were unremarkable. These findings were consistent with erythema annulare centrifugum (EAC), superficial type.

Administration of amitriptyline was suspended and mometasone furoate 0.1% cream was prescribed, showing moderate improvement at the one-month follow-up visit. Fluconazole 100 mg/day was prescribed for four weeks. Due to inefficacy, it was changed to erythromycin 250 mg four times a day for four weeks. After this treatment, the patient showed nearly complete response. At the one-year follow-up, some minor recurrences were noted, which only required short courses of topical corticosteroids. Amitriptyline oral rechallenge was refused by the patient.

EAC is classified as a reactive erythema, along with erythema chronicum migrans, erythema marginatum, and erythema gyratum repens. Each entity is separated by clinical and histopathologic correlation. EAC is divided in superficial and deep forms.¹ The superficial form often has scaly borders tending to form on the trailing edge of the annular lesion. The deep form has non-scaly indurated borders without marked epidermal changes. The superficial type is associated with recurrences and a shorter duration of skin lesions when compared with the deep type.¹ Common differential diagnosis includes other annular erythemas such as erythema chronicum migrans, mycosis fungoides, urticaria, psoriasis, tinea corporis, and annular sarcoidosis. Histopathology shows a lymphohistiocytic perivascular infiltrate in both superficial and deep types of EAC. In the superficial type, a perivascular infiltrate and dermal edema are located in the upper dermis. Epidermal changes such as acanthosis, spongiosis and even vesiculation can be seen. In the deep type, the perivascular infiltrate is found in

[☆] How to cite this article: Fernandez-Nieto D, Ortega-Quijano D, Jmenez-Cauhe J, Bea-Ardebol S. Erythema annulare centrifugum associated to chronic amitriptyline intake. *An Bras Dermatol*. 2021;96:114–6.

^{☆☆} Study conducted at the Hospital Universitario Ramón y Cajal, Madrid, Spain.