

Mucin-producing hepatocellular carcinoma without morphological features of biliary differentiation

A case report

Masayuki Ueno, MD*, Hiroyuki Takabatake, MD, Takahisa Kayahara, MD, Youichi Morimoto, MD, Hiroshi Yamamoto, MD, Motowo Mizuno, MD

Abstract

Rationale: Hepatocellular carcinoma has been believed not to produce mucin unless it has biliary differentiation. However, some cases of hepatocellular carcinoma with extracellular myxoid change have been reported recently, raising the possibility that, in rare cases, hepatocellular carcinoma cells produce mucin.

Patient concerns: Here we report a case of hepatocellular carcinoma that contained intracellular and extracellular myxoid matrix without morphological evidence of biliary differentiation, although cells in a portion of the tumor were positive for the epithelial markers cytokeratin 7 and 19. She was brought to our hospital due to abnormal liver tests and a large liver tumor found by ultrasound examination.

Diagnoses: The liver tumor showed typical imaging findings of hepatocellular carcinoma.

Interventions: The tumor was resected with negative margins, and pathologically diagnosed as hepatocellular carcinoma with mucin production.

Outcomes: The patient has been free from recurrence of cancer during two-years' follow-up.

Lessons: Our case suggests that hepatocellular carcinoma cells can produce mucin without or before morphological differentiation to biliary phenotypes, an observation that may help elucidate the mechanism for the development of combined hepatocellular and cholangiocarcinoma.

Abbreviations: CCC = cholangiocellular carcinoma, CK = cytokeratin, HCC = hepatocellular carcinoma.

Keywords: cancer-associated mucin, cholangiocarcinoma, combined hepatocellular and cholangiocarcinoma, hepatic malignancy, transdifferentiation

1. Introduction

It has been believed that hepatocellular carcinoma (HCC) does not produce mucin, whereas cholangiocellular carcinoma (CCC) or combined hepatocellular-cholangiocarcinoma may produce

mucin.^[1,2] However, cases of extracellular myxoid change in hepatocellular carcinoma without biliary differentiation have been reported recently.^[3] That observation raises the possibility of mucin production by HCC cells in rare cases. In support of this possibility, we report here a case of HCC that contained intracellular and extracellular myxoid matrix without evidence of biliary differentiation.

Editor: N/A.

Consent to publish: Informed consent was obtained from the patient for publication of this case report and accompanying images.

Ethics approval: The Independent Ethics Committee of Kurashiki Central Hospital approves publication of case reports under the following conditions: the number of patients <5, patients' anonymity maintained and appropriate informed consent provided. This case report meets all these conditions.

The authors have no conflicts of interest to disclose.

Department of Gastroenterology and Hepatology, Kurashiki Central Hospital, Kurashiki, Okayama, Japan.

* Correspondence: Masayuki Ueno, Department of Gastroenterology and Hepatology, Kurashiki Central Hospital, 1-1-1 Miwa, Kurashiki, Okayama 710-8602, Japan (e-mail: mu13951@kchnet.or.jp).

Copyright © 2018 the Author(s). Published by Wolters Kluwer Health, Inc. This is an open access article distributed under the terms of the Creative Commons Attribution-Non Commercial-No Derivatives License 4.0 (CCBY-NC-ND), where it is permissible to download and share the work provided it is properly cited. The work cannot be changed in any way or used commercially without permission from the journal.

Medicine (2018) 97:36(e12159)

Received: 7 May 2018 / Accepted: 8 August 2018

<http://dx.doi.org/10.1097/MD.00000000000012159>

2. Case report

A 76-year-old woman with no remarkable medical history had abnormal liver tests and a large liver tumor found by ultrasound examination. The liver was palpable below the costal margin but no tenderness was identified. She had no features suggesting a cause of chronic liver disease other than slight obesity. She did not consume alcohol excessively. The initial laboratory findings were: aspartate aminotransferase 161 U/L (normal range, 10–35 U/L), alanine aminotransferase 75 U/L (normal range, 7–42 U/L), γ -glutamyl transpeptidase 53 U/L (normal range, 5–40 U/L), alkaline phosphatase 257 U/L (normal range, 110–360 U/L), and total bilirubin 0.5 mg/dL (normal range, 0.2–1.2 mg/dL). The tumor markers carbohydrate antigen 19-9, carcinoembryonic antigen, alpha-fetoprotein, and des- γ -carboxy prothrombin were within reference range. The tests for hepatitis B and C virus were negative. Ultrasound examination revealed a well-defined, hypoechoic 12-cm mass in the right lobe of the liver.

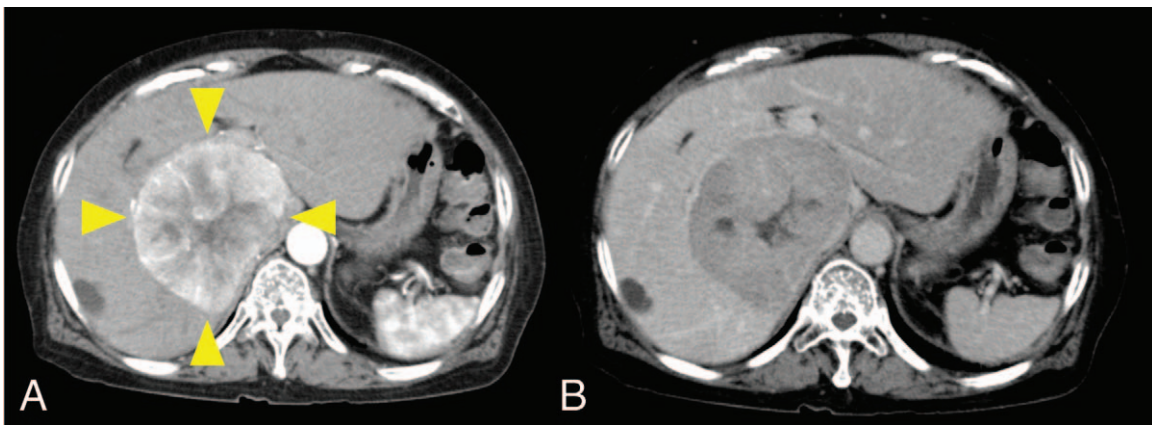


Figure 1. Contrast-enhanced computed tomography. (A) Arterial phase. (B) Delayed phase. A large tumor with early arterial enhancement and delayed phase washout is present in the right lobe of the liver (arrowheads).

Contrast-enhanced computed tomography revealed early arterial enhancement with early washout pattern (Fig. 1). Magnetic resonance imaging also showed typical findings of HCC: hyperintensity on the T2- and diffusion-weighted images, and

hypointensity on the T1-weighted image. On the basis of these image findings, HCC was diagnosed, and she underwent percutaneous transhepatic portal vein embolization followed by right hepatic trisegmentectomy.

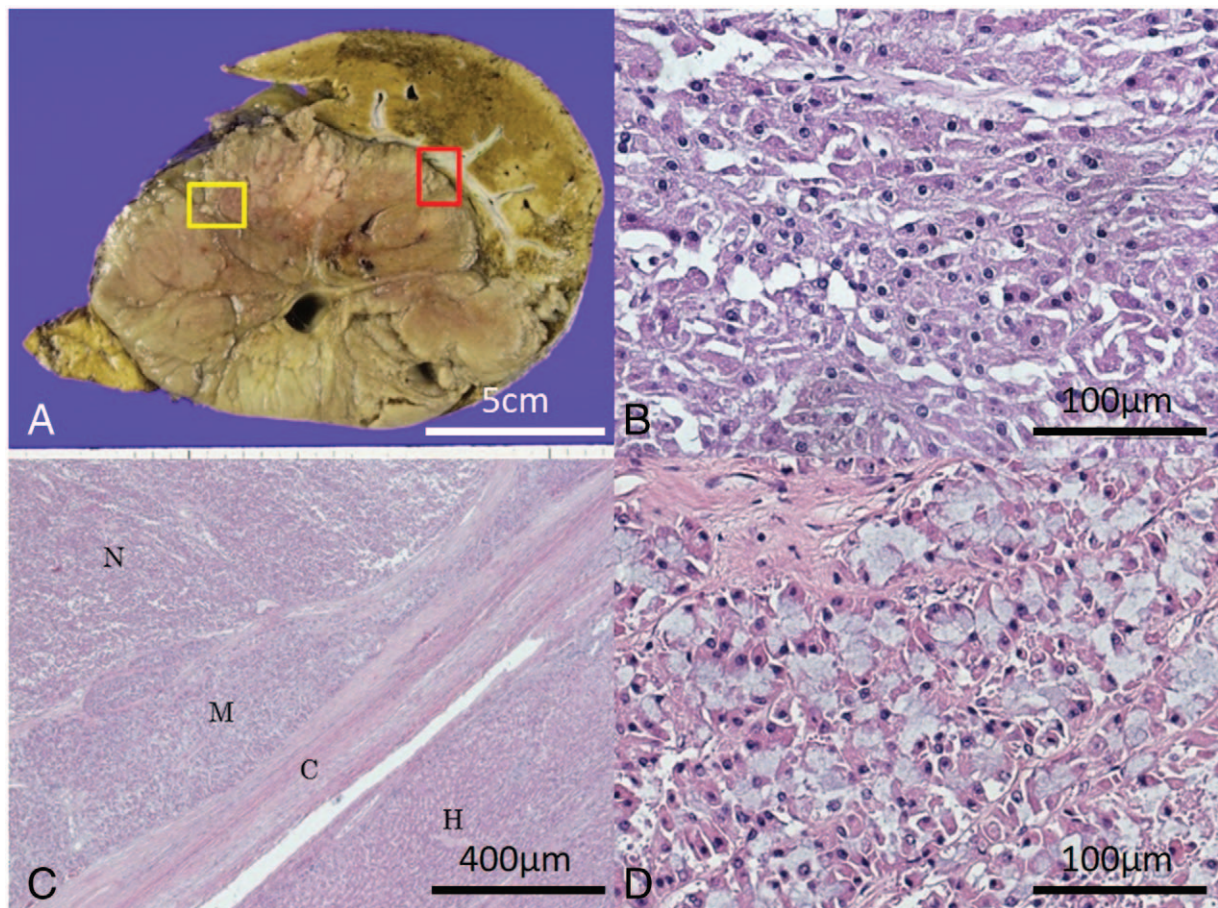


Figure 2. Gross and microscopic findings of the resected hepatic tumor. (A) In the gross specimen, the tumor is gray-brown, solid and well-defined, measuring 12.5 × 12.0 × 8.5 cm. Yellow and red boxes indicate the area of (B) and (C), respectively. (B) The microscopic findings of the tumor corresponding to the yellow box shown in (A) show moderately differentiated HCC with irregular trabecular pattern (hematoxylin and eosin staining, ×400). (C) In the microscopic findings of the edge of the tumor, corresponding to the red box in (A), myxoid change is present in a distinct area of the tumor between typical HCC and fibrotic capsule. N, tumor with no myxoid change; M, tumor with myxoid change; C, capsule of the tumor; and H, normal hepatic tissue (hematoxylin and eosin staining, ×100). (D) The magnified image of the mucin-producing area of the tumor (M). Myxoid matrix is seen inside and outside of the tumor cells. The cytoplasm contains eosinophilic globules. No gland formation is present (hematoxylin and eosin staining, ×400).

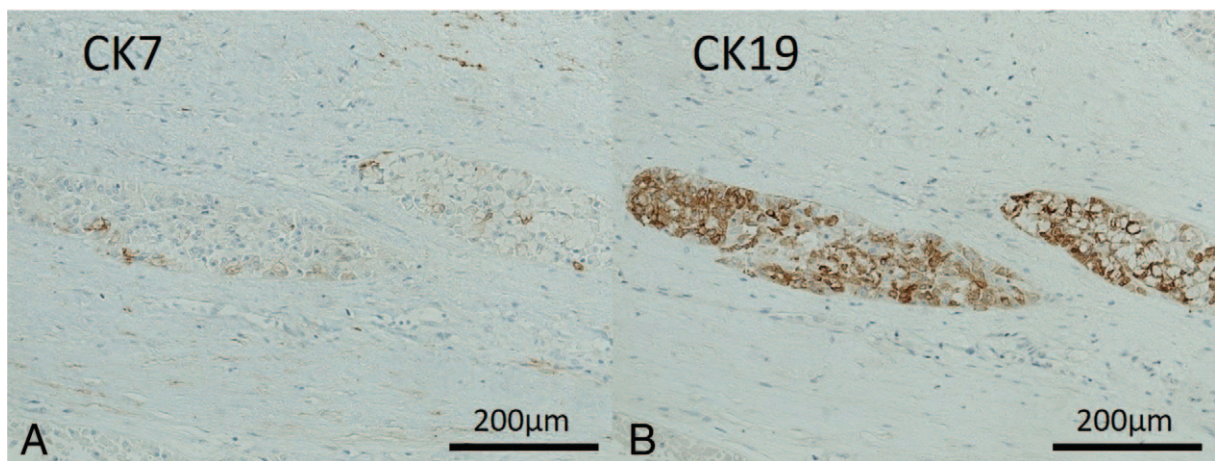


Figure 3. Immunohistochemical staining of CK7 and CK19. The tumor cells with mucin are weakly positive for CK7 (A) and diffusely positive for CK19 (B), whereas the tumor cells without mucin are negative for both CK7 and 19 (A, B $\times 200$).

In the resected tissue, the tumor was a well-defined, brown-gray solid mass (Fig. 2A). Microscopically, most of the tumor consisted of typical moderately to poorly differentiated HCC (Fig. 2B). However, in a narrow area at the edge of the tumor, the neoplastic hepatocytes had basophilic mucus in their cytoplasm (Fig. 2C and D). Immunohistochemically, the HCC cells in this area were positive for cytokeratin (CK) 7 and 19, whereas tumor cells in the remaining areas were negative for these epithelial markers (Fig. 3). Myxoid matrix was also present in the extracellular stroma. No glands or other morphological findings for biliary differentiation were present. The cells were positive for glutamine synthase, mucin 5AC and mucin 6, and negative for Hep Par1, mucin 1, and mucin 2 throughout the tumor. The details of antibodies used in immunohistochemistry are summarized in Table 1. On the basis of these findings, HCC with mucin production was the diagnosis. The resected tumor had negative margins. The patient has been free from recurrence of cancer during 2-years' follow-up.

3. Discussion

This report describes a case of HCC that had the unique pathological characteristics of mucinous matrix inside and outside of the neoplastic hepatocytes in a distinct area of the tumor. Such findings are common in biliary tumors such as CCC but are rare in HCC. When mucin is produced in primary liver tumors, it is usually reliable evidence of CCC or combined hepatocellular cholangiocarcinoma.^[4] In 2015, however, Salaria

et al^[3] reported 4 hepatic adenomas and 5 HCCs that had myxoid changes. Extracellular myxoid materials were present even though there was no evidence of biliary differentiation, either morphologically or immunohistochemically. Those findings contradicted the belief that HCC does not produce mucin. Interestingly, the initial diagnosis in all these cases was CCC or combined hepatocellular cholangiocarcinoma, and the authors' review revealed the true diagnosis, HCC. If liver tumor specimens are examined carefully for the presence of mucins, mucin-producing HCCs may be more common than usually believed, but to our knowledge no reports similar to those of Salaria et al^[3] have appeared.

In contrast to the cases of Salaria et al, where myxoid material was found only extracellularly, most mucin in our case was present intracellularly, which is strong evidence of mucin production by the HCC cells. Our case documents that HCC can have mucinous change without morphological biliary differentiation, though rarely. Other differences between our case and the cases of Salaria et al are these: In our case, mucin production was present only within a limited area, whereas 3 of their 5 cases had diffusely distributed mucin. We suggest that the tumor cells in our patient acquired the ability to produce mucin in the course of tumor progression, perhaps because of gene mutations. In other tumors, such as lung cancer, gene mutations have been suggested as leading to mucin production.^[5,6] The HCC cells with mucoid changes in our patient were immunohistochemically positive for the biliary markers CK 7 and CK 19, whereas the cases of Salaria et al were negative for CK19. The explanation for these differences might be differences in genetic makeup in the mucin production by HCC cells, but this is not proven.

Recently, it has been shown that matured HCC cells can dedifferentiate to liver progenitor cells, or transdifferentiate into biliary cells; some combined hepatocellular cholangiocarcinomas are thought to develop in this way.^[7-9] It is also known that this kind of transdifferentiation can be caused by acquired gene mutations. Sasaki et al have reported that mutations in the telomerase reverse transcriptase promoter might induce transdifferentiation of HCCs and lead to the development of intermediate-cell subtype of combined hepatocellular cholangiocarcinoma.^[10] Considering that mucin production and the expression of CK7/19 are markers of biliary-cell differentiation,

Table 1

Antibodies used in immunohistochemistry.

Antibody name	Source	Company	Dilution
Cytokeratin 7	Mouse	DAKO	1:250
Cytokeratin 19	Mouse	Leica	1:150
Hep Par 1	Mouse	DAKO	1:250
Glutamine synthase	Mouse	Merck	1:600
Mucin 1	Mouse	Leica	1:500
Mucin 2	Mouse	Leica	1:500
Mucin 5AC	Mouse	Leica	1:500
Mucin 6	Mouse	Leica	1:500

HCC cells producing mucin could be cells on the way to transdifferentiation to combined hepatocellular cholangiocarcinoma from mature HCC.

In summary, we have described a case of HCC with the unique pathological characteristic of intracellular and extracellular mucinous matrix in a part of the tumor without morphological evidence of biliary differentiation. Our case supports the hypothesis that mutations of a gene or genes enable HCC cells to produce mucin without or before morphological differentiation to biliary cells, and may help elucidate the mechanism for the development of combined hepatocellular cholangiocarcinoma.

Author contributions

Data curation: Hiroyuki Takabatake, Takahisa Kayahara, Youichi Morimoto.

Supervision: Hiroshi Yamamoto, Motowo Mizuno.

Writing – original draft: Masayuki Ueno.

Masayuki Ueno: 0000-0002-2497-9327

References

- [1] Chen MF, Jan YY, Chen TC. Clinical studies of mucin-producing cholangiocellular carcinoma: a study of 22 histopathology-proven cases. *Ann Surg* 1998;227:63–9.
- [2] Ng IO, Shek TW, Nicholls J, et al. Combined hepatocellular-cholangiocarcinoma: a clinicopathological study. *J Gastroenterol Hepatol* 1998;13:34–40.
- [3] Salaria SN, Graham RP, Aishima S, et al. Primary hepatic tumors with myxoid change: morphologically unique hepatic adenomas and hepatocellular carcinomas. *Am J Surg Pathol* 2015;39:318–24.
- [4] Schlageter M, Terracciano LM, D’Angelo S, et al. Histopathology of hepatocellular carcinoma. *World J Gastroenterol* 2014;20:15955–64.
- [5] Tsai JH, Liao JY, Yuan CT, et al. RNF43 mutation frequently occurs with GNAS mutation and mucin hypersecretion in intrahepatic papillary neoplasms of the bile duct. *Histopathology* 2017;70:756–65.
- [6] Sonzogni A, Bianchi F, Fabbri A, et al. Pulmonary adenocarcinoma with mucin production modulates phenotype according to common genetic traits: a reappraisal of mucinous adenocarcinoma and colloid adenocarcinoma. *J Pathol Clin Res* 2017;3:139–52.
- [7] Chen Y, Wong PP, Sjeklocha L, et al. Mature hepatocytes exhibit unexpected plasticity by direct dedifferentiation into liver progenitor cells in culture. *Hepatology* 2012;55:563–74.
- [8] Tarlow BD, Pelz C, Naugler WE, et al. Bipotential adult liver progenitors are derived from chronically injured mature hepatocytes. *Cell Stem Cell* 2014;15:605–18.
- [9] Sasaki M, Sato H, Kakuda Y, et al. Clinicopathological significance of ‘subtypes with stem-cell feature’ in combined hepatocellular-cholangiocarcinoma. *Liver Int* 2015;35:1024–35.
- [10] Sasaki M, Sato Y, Nakanuma Y. Mutational landscape of combined hepatocellular carcinoma and cholangiocarcinoma, and its clinicopathological significance. *Histopathology* 2017;70:423–34.