

## C A S E R E P O R T

# Thrombocytosis in a male patient with acute promyelocytic leukaemia during all-trans retinoic (ATRA) acid treatment

*Mahmood B. Aldapt<sup>1</sup>, Nancy Kassem<sup>2</sup>, Randa Al-Okka<sup>2</sup>, Rula Ghasoub<sup>2</sup>, Dina Soliman<sup>3</sup>, Mohammad A. Abdulla<sup>4</sup>, Deena Mudawi<sup>4</sup>, Feryal Ibrahim<sup>5</sup>, Mohamed A. Yassin<sup>6</sup>*

<sup>1</sup> Resident, Internal Medicine, Hamad Medical Corporation (HMC), Doha, Qatar; <sup>2</sup> Clinical Pharmacist, National Center for Cancer Care and Research, Hamad Medical Corporation (HMC), Doha, Qatar; <sup>3</sup> Specialist, Hematopathology, Laboratory Medicine, Hamad Medical Corporation (HMC) and National Cancer Institute Cairo University, Cairo, Egypt; <sup>4</sup> Clinical Fellow, Hematology, National Center for Cancer Care and Research, Hamad Medical Corporation (HMC), Doha; <sup>5</sup> Consultant Hematopathologist Department of Laboratory Medicine and Pathology, National Center for Cancer Care and Research, Hamad Medical Corporation (HMC), Doha, Qatar; <sup>6</sup> Consultant, Hematology, National Center for Cancer Care and Research, Hamad Medical Corporation, (HMC), Doha, Qatar

**Summary.** We present a rather uncommon side effect observed in a 20-year-old man with acute promyelocytic leukemia during treatment with ATRA. He developed a high platelet counts reaching up to  $1655 \times 10^9/L$  on day 29 of ATRA treatment, and started to recover spontaneously on day 33 of treatment, without any change in ATRA, or adding any cyto-reduction therapy. No complications associated with thrombocytosis were observed. IL-6 seems to play an important role in the pathogenesis of the thrombocytosis induced by ATRA. However, it is unclear what are the precipitating factors for this rare phenomenon and whether it is caused by certain predisposing factors that might be related to patient's, disease pathogenesis or other unknown factors. ([www.actabiomedica.it](http://www.actabiomedica.it))

**Key words:** thrombocytosis, all-trans retinoic (ATRA) acid, promyelocytic leukaemia

## Introduction

All-*trans*-retinoic acid given (ATRA) as induction or maintenance therapy results in improved disease-free survival and overall survival, as compared with chemotherapy alone, in patients with newly diagnosed acute promyelocytic leukemia (1).

In addition to this therapeutical effect, ATRA has been shown to affect cellular hemostatic properties. Several studies demonstrate that ATRA affects the hemostatic balance of the endothelium. Particularly, ATRA induces the expression of endothelial cell thrombomodulin, the membrane receptor that binds and inactivates thrombin. Intriguingly, thrombotic events have been reported in some series during ATRA therapy, including fatal myocardial infarction and cerebral thrombosis (2-4).

Here we present a rather uncommon side effect observed in a patient with acute promyelocytic leukemia during treatment with ATRA.

## Case study

A 20-year-old man, presented to the emergency department with easy fatigability, for almost one month, ecchymosis on the arms and legs, occasional epistaxis, and gum bleeding for the last 2 weeks.

On clinical examination he was found to have multiple bruises and ecchymosis on the upper and lower limbs, and on the abdomen. The other clinical parameters to the physical examination were unremarkable.

Initial lab. Tests showed white blood counts (WBC) of  $5.6 \times 10^9/L$  (normal values:  $4-10 \times 10^9$ ),

hemoglobin 12.4 gm/dl (normal values: 13.0-17.0), platelet counts  $17 \times 10^9/L$  (normal values:  $150-400 \times 10^9$ ), prothrombin time (PT) 12.8 seconds (normal values: 9.4-12.5), activated partial thromboplastin time (aPTT) 24.3 seconds (normal values: 25.1-36.5), D-Dimer 3.6 mg/L (normal values: 0.0-0.49), fibrinogen 0.9 gm/l (normal values: 2.0-4.1 mg/L), and International Normalized Ratio (INR) 1.1 (normal values: 0.8-1.2).

Peripheral smear showed a 20% of abnormal leukemic promyelocytes and 2% of circulating blasts, substantially the picture was suggestive of acute promyelocytic leukemia (APL) a subtype of acute myeloid leukemia (AML). Therefore, ATRA was started at a dose of  $45 \text{ mg/m}^2$  and PETHEMA protocol was started because of the confirmed diagnosis of APL intermediate risk, after bone marrow (BM) examination.

His admission in the hospital was uneventful, apart from headache. The curve of platelet counts from day 1 till day 46 of ATRA treatment is shown in figure 1. During the treatment the patient developed a marked thrombocytosis, up to  $1650 \times 10^9/L$ . The peripheral blood showed a moderate anemia, monocytosis, 1% of circulating blast and remarkable thrombocytosis.

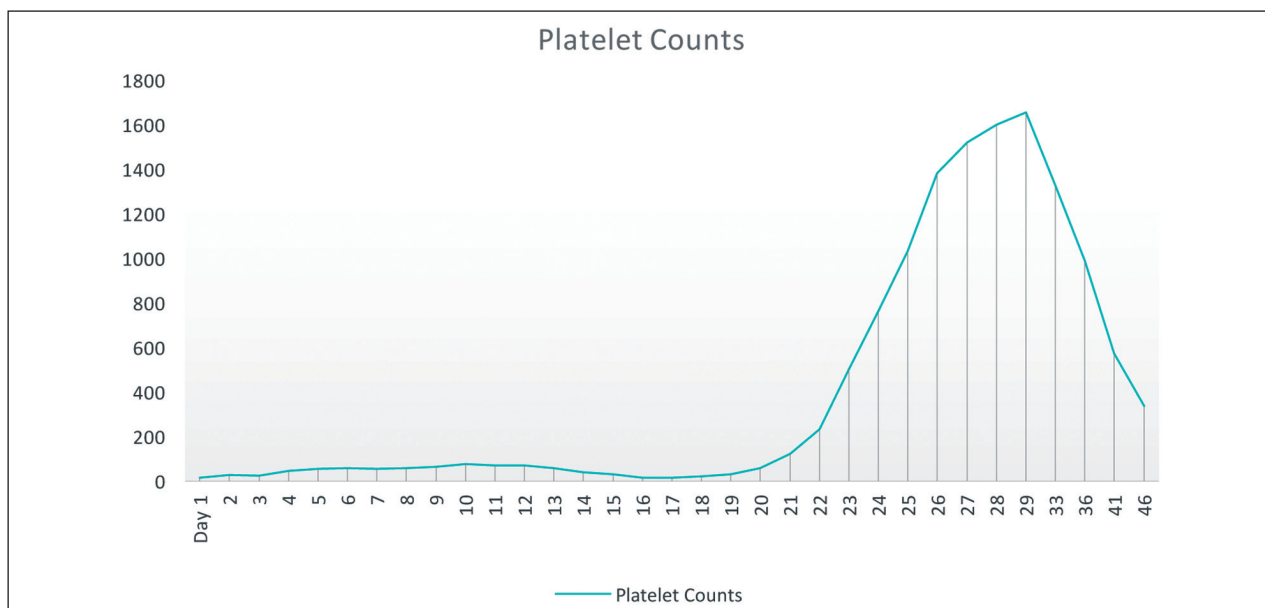
The BM aspirate, repeated on day 29, showed a trilineal hematopoiesis with 1% of blasts (Figure 2 A) and the BM biopsy section showed a mild hypercellularity for age (~85%) with erythroid and megakaryocytic hyperplasia, and adequate granulopoiesis (Figures 2 B and C).

CD34 highlighted some scattered positivity with few adjacent cells, roughly estimated by ~4-5% (Figure 2D). FISH analysis revealed abnormal hybridization signal pattern indicating *PML/RARA* rearrangement, t(15;17), in 2% of the cells analyzed indicating residual disease.

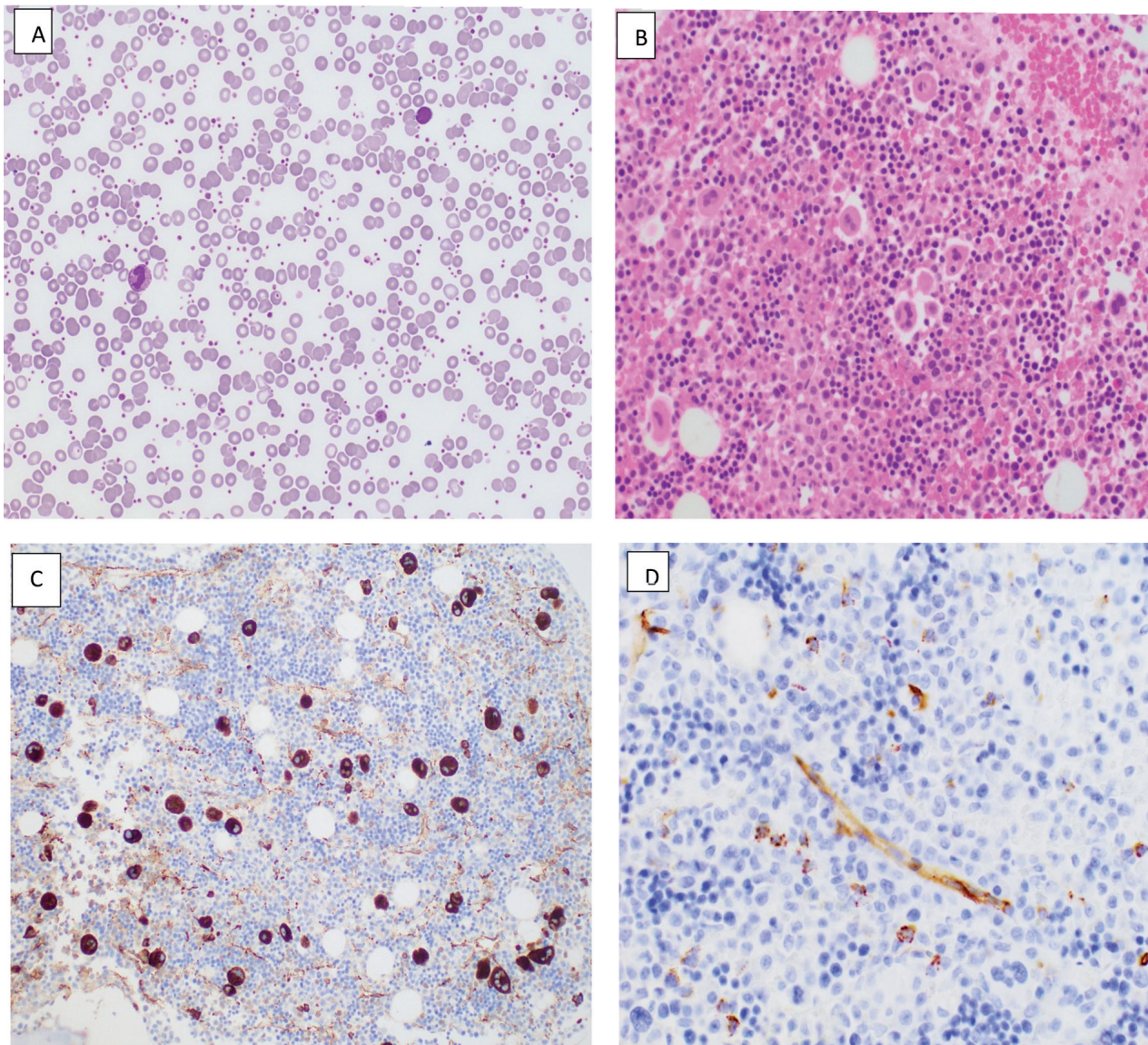
Because he was asymptomatic ATRA dosage was not modified. His platelet counts declined progressively (46<sup>th</sup> day of hospitalisation) as shown in figure 1.

## Discussion

The platelets production is regulated by thrombopoietin (TPO), a hormone usually produced by the liver and kidneys. Normal physiology of platelet production involves the clearance of TPO by high-affinity TPO receptors on platelets and formation of a steady TPO concentration, thereby providing a basal stimula-



**Figure 1.** Platelet counts curve from day 1 till day 46 of ATRA treatment. Vertical line: platelet values are expressed in  $\times 10^9/L$



**Figure 2.** Peripheral blood smear showing marked thrombocytosis, 50x (A). Bone marrow biopsy (H&E) showing mild hypercellularity with megakaryocytic hyperplasia and prominent erythroid islands, 50x (B). Vwf immunostain highlighted megakaryocytic proliferation; scattered with no clusters and no significant atypia noted, 50x (C). CD34 immunostain highlighted mild increase in CD34 positivity with few adjacent cells, roughly estimated by ~4-5%, 50x (D)

tion of bone marrow megakaryocytes and normal rate of platelet production. Old platelets are destroyed by phagocytosis in the spleen and by Kupffer cells in the liver (5, 6).

On a clinical level, thrombocytosis is classified “mild” at a platelet count between  $>500 \times 10^9/L$  and  $<700 \times 10^9/L$ ; “moderate” at a platelet count between  $>700 \times 10^9/L$  and  $<900 \times 10^9/L$ ; “severe” at a platelet count  $>900 \times 10^9/L$ ; and “extreme” at a platelet count

$>1,000 \times 10^9/L$  (7). Thrombocytosis can be classified as primary or secondary. Primary thrombocytosis is divided into familial and essential. Generally, it is a reactive process caused by infection, chronic inflammation, iron deficiency, tissue damage, cancer, drugs and surgical or functional splenectomy.

Reactive or secondary thrombocytosis associated with malignancies has been established since the early 1870s, with an incidence of 10-57% (8). Possible



**Table 1.** Thrombocytosis in patients with acute promyelocytic leukaemia during all-trans retinoic acid treatment (Ref. 15)

| Case | Gender | Age  | Number of platelets               | Treatment given | Time till recovery | Complications (Thrombosis/Bleeding) |
|------|--------|------|-----------------------------------|-----------------|--------------------|-------------------------------------|
| 1    | male   | 23 y | 1500×10 <sup>9</sup> /l on day 30 | rIFN-α*         | 18 d               | None                                |
| 2    | female | 16 y | 1200×10 <sup>9</sup> /l on day 38 | rIFN-α*         | 3 d                | None                                |

\*recombinant interferon alpha was administered at a dose of 3 million units intramuscularly every other day

mechanisms include an overproduction of cytokines/growth factors stimulating megakaryocytes and their precursors. However, in secondary thrombocytosis that can occur with malignancies, there can be up-regulation of TPO production by the liver causing enhanced thrombopoiesis. Plasma TPO levels have also been shown to correlate with IL-6 (9).

Essential thrombocytosis or thrombocythemia (ET) in adults is well known as a member of the family of myeloproliferative neoplasms (MPN), also including polycythemia vera (PV) and primary myelofibrosis (PMF). These disorders share several features, such as splenomegaly, growth factor independent hematopoiesis, and the potential to transform to acute myeloid leukemia (AML). Since identification of the *JAK2 V617F* mutation in 2005, and subsequently of mutations in relevant JAK-STAT pathway genes, these MPN are now relatively well-understood entities in adults (10).

Regardless of the cause of thrombocytosis, a high platelet count can be associated with vasomotor phenomena (headache, visual symptoms, nausea, chest pain, dysaesthesia, aphasia, dysarthria, vertigo, instability, shivering or erythromelalgia), thrombotic phenomena or haemorrhagic complications (11).

The occurrence of thrombosis during induction treatment with ATRA combined with aprotinin and chemotherapy was described in a young patient who was homozygous for factor VQ 506 mutation (12). Cases of acute renal failure, due to occlusion of renal vessels in a patient with APL treated with ATRA and tranexamic acid and with ATRA alone (13) have also been described. A patient with APL had fatal thromboembolism after receiving ATRA and tranexamic acid therapy (14).

In our patient thrombocytosis was probably caused by the excess production of cytokines mainly

IL-6 induced by APL cells under the influence of ATRA.

Similar results were reported by Losada et al. (15) in two APL cases with platelet counts >1000×10<sup>9</sup>/L during ATRA therapy who were treated with recombinant interferon alpha. In both cases ATRA doses were not modified, no complications secondary to thrombocytosis were seen, and they subsequently achieved complete remission.

Escudier et al. (16) noted that thrombotic events were more common in patients suspected of having ATRA syndrome. ATRA syndrome is the most severe side effect occurring in about a quarter of patients, usually between the second day and the third week of treatment. It is a protean syndrome of fever, respiratory distress, pulmonary infiltrates, pleuropericardial effusions, and edema, more common among patients who present with a high white blood cell count or develop rapid leukocytosis. If not promptly recognized and treated, the ATRA syndrome can lead to death from progressive hypoxemia and multiorgan failure.

Our patient did not develop any thrombosis or bleeding complications, and his platelet counts started to recover on day 33 of ATRA treatment, indicating that in such type of thrombocytosis specific anti-platelet or cytoreduction therapy is not strictly required. Interestingly, the decrease in platelet counts seemed to be spontaneous rather than the effect of IFN-α which typically needs a median of 6 weeks to start its effect (17).

In summary, IL-6 seems to play an important role in the pathogenesis of the thrombocytosis induced by ATRA. However, it is unclear what are the precipitating factors for this rare phenomenon and whether it is caused by certain predisposing factors that might be related to patient's, disease pathogenesis or other unknown factors.

## References

1. Wiernik PH, Gallagher RE, Tallman MS. Diagnosis and treatment of acute promyelocytic leukemia. In: Wiernik PH, Canellos GP, Dutcher JP, Kyle RA, eds. *Neoplastic diseases of the blood*. 3rd ed. New York: Churchill Livingstone, 1996: 353-380.
2. Tallman MS, Andersen JW, Schiffer CA, Appelbaum FR, Feusner JH, Ogden A, Shepherd L, Rowe JM, François C, Larson RS, Wiernik PH. A prospective randomized study of all-trans retinoic acid induction and maintenance therapy for patients with acute promyelocytic leukemia. *N Engl J Med* 1997; 337: 1021-1028.
3. Mandelli F, Diverio D, Avisati G, Luciano A, Barbui T, Bernasconi C, Brocchia G, Cerri R, Falda M, Fioritoni G, Leoni F, Liso V, Petti MC, Rodeghiero F, Saglio G, Vegna ML, Visani G, Jehn U, Willemze R, Muus P, Pelicci PG, Biondi A, Lo Coco F. Molecular remission in PML/RAR alpha-positive acute promyelocytic leukemia by combined all-trans retinoic acid and idarubicin (AIDA) therapy. Gruppo Italiano-Malattie Ematologiche Maligne dell'Adulto and Associazione Italiana di Ematologia ed Oncologia Pediatrica Cooperative Groups. *Blood* 1997; 90: 1014-1021.
4. De Lacerda JF, do Carmo JA, Guerra ML, Gerales J, de Lacerda JM. Multiple thrombosis in acute promyelocytic leukaemia after tretinoin. *Lancet* 1993; 342: 114-115.
5. Burstein SA, Harker LA. Control of platelet production. *Clin Haematol* 1983; 12: 3-22.
6. Qian S, Fu F, Li W, Chen Q, de Sauvage FJ. Primary role of the liver in thrombopoietin production shown by tissue-specific knockout. *Blood* 1998; 92: 2189-2191.
7. Dame C. Thrombocytosis. In: Arceci RJ, Hahn IM, Smith OP, eds. *Pediatric Hematology*. 3rd Ed. Oxford, UK: Blackwell Publishing Ltd; 2006, p. 548-561.
8. Levin J, Conley CL. Thrombocytosis associated with malignant disease. *Arch Intern Med* 1964; 114: 497-500.
9. Hollen CW, Henthorn J, Koziol JA, Burstein SA. Elevated serum interleukin-6 levels in patients with reactive thrombocytosis. *Br J Haematol* 1991; 79: 286-290.
10. Chuzi S, Stein BL. Essential thrombocythemia: a review of the clinical features, diagnostic challenges, and treatment modalities in the era of molecular discovery. *Leuk Lymphoma*. 2017; 58: 2786-2798.
11. Yadav D, Chandra J, Sharma S, Singh V. Clinicohematological study of thrombocytosis. *Indian J Pediatr* 2010; 77: 643-647.
12. Kocak U, Gursel T, Ozturk G, Kantarci S. Thrombosis during all-trans-retinoic acid therapy in a child with acute promyelocytic leukemia and factor VQ 506 mutation. *Pediatr Hematol Oncol* 2000; 17: 177-180.
13. Pogliani EM, Rossini F, Casaroli I, Maffe P, Corneo G. Thrombotic complications in acute promyelocytic leukemia during all-trans-retinoic acid therapy. *Acta Haematol* 1997; 97: 228-230.
14. Hashimoto S, Koike T, Tatewaki W, Seki Y, Sato N, Azegami T, Tsukada N, Takahashi H, Kimura H, Ueno M. Fatal thromboembolism in acute promyelocytic leukemia during all-trans retinoic acid therapy combined with antifibrinolytic therapy for prophylaxis of hemorrhage. *Leukemia* 1994; 8: 1113-1115.
15. Losada R, Espinosa E, Hernández C, Dorticos E, Hernández P. Thrombocytosis in patients with acute promyelocytic leukaemia during all-trans retinoic acid treatment. *Br J Haematol* 1996; 95: 704-705.
16. Escudier SM, Kantarjian HM, Estey EH. Thrombosis in patients with acute promyelocytic leukemia treated with and without all-trans retinoic acid. *Leuk Lymphoma* 1996; 20: 435-439.
17. Lengfelder E, Griesshammer M, Hehlmann R. Interferon-alpha in the treatment of essential thrombocythemia. *Leuk Lymphoma* 1996; 22 (Suppl 1): 135-142.

Received: 15 March 2018

Accepted: 22 March 2018

Correspondence:

Mohamed A Yassin, MD

Department of Medical Oncology, Hematology Section

National Center for Cancer Care and Research

Hamad Medical Corporation, Doha, Qatar

Tel. 55037393

E-mail: yassinmoha@gmail.com