

This is an Open Access article licensed under the terms of the Creative Commons Attribution-NonCommercial-NoDerivs 3.0 License (www.karger.com/OA-license), applicable to the online version of the article only. Distribution for non-commercial purposes only.

Stereotypic Movements in Case of Sporadic Creutzfeldt-Jakob Disease: Possible Role of Anti-NMDA Receptor Antibodies

Michelle Molina Robert Fekete

Department of Neurology, New York Medical College, Valhalla, N.Y., USA

Key Words

NMDA · Anti-NMDA receptor antibody encephalitis · Akinetic mutism · Catatonia · Orofacial dyskinesia · Stereotypies · Tics · Creutzfeldt-Jakob disease · Sporadic Creutzfeldt-Jakob disease

Abstract

Sporadic Creutzfeldt-Jakob disease (sCJD) and anti-NMDA receptor antibody encephalitis (NMDAE) can both produce a rapidly progressive dementia with resulting state of catatonia or akinetic mutism. Both are associated with movement disorders. In published case series, myoclonus appears to be the most frequent movement disorder in sCJD, while stereotypic, synchronized, one-cycle-per-second movements such as arm or leg elevation, jaw opening, grimacing, head turning, and eye deviation are seen in NMDAE. We report a case of a 59-year-old woman with rapidly worsening cognitive disturbance leading to a nearly catatonic state interrupted by stereotypic movements. sCJD was diagnosed via periodic sharp wave complexes on EEG as well as cerebrospinal fluid (CSF) 14-3-3 and tau protein elevation. Characteristic movement disorder of NMDAE was present in absence of ovarian mass or CSF pleiocytosis. Given prior case reports of presence of anti-NMDA receptor antibodies in sCJD, we propose that the movement disorder in this case was caused by anti-NMDA receptor antibodies whose formation was secondary to neuronal damage from prion disease. It is important to consider sCJD even in cases that have some clinical features suggestive of NMDAE.

Introduction

Sporadic Creutzfeldt-Jakob disease (sCJD) is a prion disease presenting as rapidly progressive dementia that may lead to akinetic mutism [1, 2]. Movement disorder, including chorea, may be present in sCJD. Anti-NMDA receptor antibody encephalitis (NMDAE) can also have a similar clinical course, but presents with a distinct movement disorder. Here we present a case of rapidly progressive dementia with vocalizations and stereotypic movements.

Case Presentation

The patient is a 59-year-old right-handed female who presented with personality and cognitive changes rapidly progressing to akinetic mutism interrupted by stereotypic movements as described below. Past medical history included non-Hodgkin's lymphoma diagnosed two years prior to onset of neurological disorder via wedge biopsy of a right mandibular mass. She received rituximab together with cyclophosphamide, vincristine, and prednisolone (R-CVP) chemotherapy. Her regimen was followed by four extra doses of rituximab. Subsequent ¹⁸F-fluorodeoxyglucose positron emission tomography (FDG-PET) scans were negative for any neoplastic activity. There was no history in the patient or her relatives of psychiatric disease, dementia, or any other neurological disease including Tourette syndrome.

Her family noted progressively unsteady gait, but she was able to ambulate without a cane. Her behavior became more impulsive and at times socially inappropriate. She also became more somnolent and withdrawn. She stopped being able to attend to her own finances and began to forget ages of her close relatives. About three and a half months later, she had a generalized tonic-clonic seizure and was started on lacosamide.

On initial evaluation 4 months after onset, she appeared somnolent, arousable to voice, and followed one-step commands. She was oriented to self, place, and month. She was able to say the names of her family members. Her speech was perseverative. She kept her eyes closed and resisted eye opening. She moved all extremities with at least 4/5 power and localized pain sensation in all extremities. Deep tendon reflexes were symmetric, 2+ throughout with absent plantar reflexes.

Over the next month, she progressively lost motor and verbal ability to the point that she became bedbound and stopped following commands. She developed bilateral ankle clonus. There was normal muscle tone. She continued to be able to breathe without ventilatory assistance. At 5 months after onset, she became mute except for occasional vocalizations. These vocalizations initially consisted of vocal tics, with grunting and 'barking' sounds identical to those heard in Tourette syndrome patients. At this time, abnormal involuntary movements developed which consisted of about 1-Hertz-frequency stereotypic, synchronized bilateral arm and leg contraction, head turning, mouth opening, and periodic eye deviation upward or sideways (see online supplementary video 1, available at www.karger.com/doi/10.1159/000346298). Bilateral grimacing due to episodic frontalis contraction was also present. These movements are nearly pathognomonic for NMDAE [3].

The case fit an intra vitam diagnosis of probable sCJD according to criteria of Zerr et al. and February 1998 WHO guidelines [1, 2]. Clinical diagnostic features included presence of cerebellar disease leading to gait instability, rapidly progressive dementia leading to akinetic mutism, and extrapyramidal symptoms. 14-3-3 protein enzyme-linked immunosorbent assay (ELISA) was positive, which fulfilled the laboratory test requirement of the diagnostic guidelines for sCJD. The movement disorder in sCJD is typically myoclonus, but may include dystonia, chorea, and tremor [4]. Initial electroencephalography (EEG) in our patient showed nonspecific background slowing, but repeat EEG at 5 months after onset did show periodic sharp wave complexes typical of sCJD (fig. 1). MRI imaging did not demonstrate cortical ribbon or caudate and putamen T2 hyperintensities characteristic of prion disease.

Erythrocyte sedimentation rate was elevated to 75 mm/h. Blood cultures, urinalysis and urine culture were negative. Initial chest X-ray was clear. Ceruloplasmin was normal at 27 mg/dl. Serum rapid plasma reagin test (RPR) was nonreactive. Serum anti-JC virus antibody was normal.

Cerebrospinal fluid (CSF) glucose and protein were normal at 43 and 36 mg/dl, respectively. CSF WBC count was 1 per mm³ and CSF RBC count was zero. 48-hour CSF viral culture was negative. CSF oligoclonal bands were negative. CSF herpesvirus 1 and 2 DNA was absent. CSF bacterial culture was negative after seven days of incubation. A prior lumbar puncture at a different institution showed CSF 6 WBC per mm³ and protein of 48 mg/dl.

CSF tau protein ELISA was elevated at 2,646 pg/ml, which supports the diagnosis of CJD in the absence of Alzheimer's disease, vascular dementia, multi-infarct dementia with acute infarct, brain neoplasm (such as glioma), or paraneoplastic disorder [5]. In our case, there was no atrophy, mass, acute or remote infarct on MRI brain with and without contrast. Both 14-3-3 and tau protein elevation can serve as a general marker of nerve cell damage. Paraneoplastic antibody panel (anti-amphiphysin, anti-Ma2, and anti-CV2) was negative. Otto et al. [5] report one case of 14-3-3-positive listeriosis with tau protein of 3,461 pg/ml, but our patient had no CSF pleiocytosis and her blood cultures as well as CSF cultures were negative. CT scan of abdomen and pelvis revealed a simple right kidney cyst but no ovarian masses to suggest anti-NMDAE. In addition, most patients (95/100) in Dalmau's case series of NMDAE had CSF abnormalities [6]. Serum anti-NMDA receptor antibodies were negative at a titer less than 1:10.

Discussion

Probable sCJD was diagnosed with periodic sharp wave complexes on repeated EEG as well as tau and 14-3-3 protein elevation. The patient's hyperkinetic movements may appear to fit chorea reported in sCJD, but more detailed analysis of the movement disorder reveals a periodicity of about once a second and synchronicity which instead conforms to the characteristic movement disorder of NMDAE. In retrospect, clinical features such as resistance to eye opening and seizures fit the clinical description of NMDAE [6]. Periodic sharp waves are not typically seen in NMDAE and seizures and orofacial dyskinesia are not reported in sCJD [7].

We are intrigued by case reports from Mackay et al. [7] and Dalmau et al. [8] regarding presence of anti-NMDA receptor autoantibodies in patients with sCJD. We propose that the characteristic movement disorder in this case was caused by anti-NMDA receptor antibodies whose formation was secondary to neuronal damage from prion disease. Anti-NMDA receptor antibodies formed via intrathecal synthesis [9] may not necessarily be present in serum, as was the case here. It is important to consider sCJD even in cases that have some clinical features suggestive of NMDAE.

Disclosure Statement

Dr. Fekete received honoraria from Medlink, Inc., and serves as consultant for Teva Neuroscience, Inc., and Lundbeck, LLC.

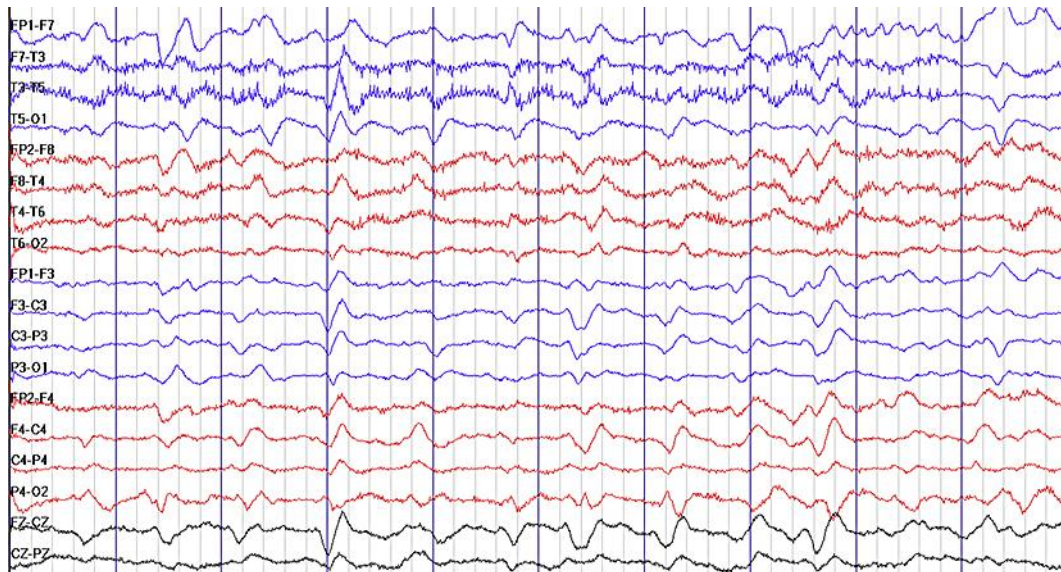


Fig. 1. Periodic sharp wave complexes seen on EEG at 5 months after onset. Each segment delineated by a blue bar represents one second.

References

- 1 Zerr I, Kallenberg K, Summers DM, et al: Updated clinical diagnostic criteria for sporadic Creutzfeldt-Jakob disease. *Brain* 2009;132:2659–2668.
- 2 World Health Organization: Report of a WHO consultation on global surveillance, diagnosis and therapy of human transmissible spongiform encephalopathies. Geneva, Switzerland: WHO; 9–11 February 1998. WHO/EMC/ZDI/98.9
- 3 Kleinig TJ, Thompson PD, Matar W, et al: The distinctive movement disorder of ovarian teratoma-associated encephalitis. *Mov Disord* 2008;23:1256–1261.
- 4 Edler J, Mollenhauer B, Heinemann U, et al: Movement disturbances in the differential diagnosis of Creutzfeldt-Jakob disease. *Mov Disord* 2009;24:350–356.
- 5 Otto M, Wiltfang J, Cepek L, et al: Tau protein and 14-3-3 protein in the differential diagnosis of Creutzfeldt-Jakob disease. *Neurology* 2002;58:192–197.
- 6 Dalmau J, Gleichman AJ, Hughes EG, et al: Anti-NMDA-receptor encephalitis: case series and analysis of the effects of antibodies. *Lancet Neurol* 2008;7:1091–1098.
- 7 Mackay G, Ahmad K, Stone J, et al: NMDA receptor autoantibodies in sporadic Creutzfeldt-Jakob disease. *J Neurol* 2012;259:1979–1981.
- 8 Dalmau J, Lancaster E, Martinez-Hernandez E, Rosenfeld M, Balice-Gordon R: Clinical experience and laboratory investigations in patients with anti-NMDAR encephalitis. *Lancet Neurol* 2011;10:63–74.
- 9 Martinez-Hernandez E, Horvath J, Shiloh-Malawsky Y, et al: Analysis of complement and plasma cells in the brain of patients with anti-NMDAR encephalitis. *Neurology* 2011;77:589–593.