

Access this article online

Quick Response Code:



Website:

www.e-tjo.org

DOI:

10.4103/tjo.tjo_108_18

Step-by-step Descemet's membrane endothelial keratoplasty surgery

Shin-Yi Chen^{1,2}, Mark A. Terry^{2,3}

Abstract:

With the success of Descemet's stripping automated endothelial keratoplasty (DSAEK) technique providing better outcomes in visual prognosis and theoretically lower rejection rate than penetrating keratoplasty, DSAEK dominated the realm of endothelial keratoplasty for the past decade. However, Descemet's membrane endothelial keratoplasty (DMEK) has become more and more popular worldwide due to its even lower rejection rate, faster visual recovery, better visual outcome, and lower long-term endothelial loss. In this article, we demonstrate the techniques and nuances of DMEK surgery in detail for corneal specialists who are beginning their DMEK surgeries.

Keywords:

Corneal transplantation, Descemet membrane endothelial keratoplasty, endothelial keratoplasty

Introduction

Penetrating keratoplasty (PK) dominated the treatment of corneal disease for about a century since the first case was done by Zirm in 1905.^[1] In the past two decades, lamellar corneal transplantation has progressed by leaps and bounds. Due to better visual outcome and lower rejection rate, endothelial keratoplasty (EK) is gaining popularity for treating endothelial disease. In this article, we will introduce the history of EK and attempt to describe in detail the techniques in DMEK surgery.

History of Endothelial Keratoplasty

Although modern endothelial keratoplasty (EK) was initiated by Melles, there are other pioneers who have also made significant contributions to its development. In 1956, the first successful human EK was performed by Tillett, which included a hand dissection-created anterior lamellar flap of the recipient cornea, trephination of the recipient posterior lamellar bed, and

then replacement of the posterior tissue by suturing of the donor tissue and the flap.^[2] The "flap" technique was also described by Barraquer, but with creation of the flap with a microkeratome. Decades later, this was performed by Culbertson, Busin, and Azar, reporting separately. It was a relatively easy surgery for the surgeons familiar with the microkeratome. However, this surgery not only has the same possible complications from creating a corneal flap by microkeratome as LASIK, such as incomplete flap, free cap, button hole flap or torn flap, but also has additional drawbacks of unstable wound and irregular astigmatism from sutured surface similar to PK.

To achieve the goal of an intact corneal surface, the first concept of a scleral-limbal approach for lamellar EK was described in 1993 by Ko *et al.*,^[3] but this also involved sutures to attach the donor tissue. In 2000, Mark Terry performed the first successful deep lamellar EK (DLEK) in the United States and strived to popularize it.^[4] The technique of DLEK included manual dissection using a scleral-limbal incision and formation of a deep lamellar pocket over the entire area

¹Department of Ophthalmology, Chang Gung Memorial Hospital, Keelung, Taiwan, ²Cornea Services, Devers Eye Institute, ³Vision Research Laboratory, Lions VisionGift, Portland, OR, USA

Address for correspondence:

Prof. Mark A. Terry,
Devers Eye Institute,
1040 N.W. 22nd Ave.,
Suite 200, Portland,
OR 97210, USA.
E-mail: mterry@
deverseye.org

Submission: 12-09-2018

Accepted: 26-12-2018

This is an open access journal, and articles are distributed under the terms of the Creative Commons Attribution-NonCommercial-ShareAlike 4.0 License, which allows others to remix, tweak, and build upon the work non-commercially, as long as appropriate credit is given and the new creations are licensed under the identical terms.

For reprints contact: reprints@medknow.com

How to cite this article: Chen SY, Terry MA. Step-by-step Descemet's membrane endothelial keratoplasty surgery. Taiwan J Ophthalmol 2019;9:18-26.

of the cornea. Through this pocket, removal of recipient posterior lamellae and implantation of a manually dissected donor posterior stroma and endothelium were accomplished using no sutures to attach the donor tissue and only an air bubble to support the donor until it self-adhered. This technique eliminated the PK problem of a large open globe during surgery and eliminated any sutures that would cause an irregular corneal surface. However, the technically demanding and time-consuming aspects of manual dissection along with the corneal stromal interface limited the popularity of this procedure, despite the visual outcomes of DLEK being far superior to those of PK.

In 2003, Melles further advanced EK surgery by eliminating the posterior lamellar dissection of recipient cornea and only removing the Descemet's membrane. He called this advance descemetorhexis.^[5] After that breakthrough in surgical technique, this form of EK was popularized first in the United States by Price as Descemet's stripping EK.^[6] Gorovoy then described the use of an automated microkeratome to create the donor posterior lamella and renamed the procedure Descemet's stripping automated EK(DSAEK).^[7] Finally, Mark Terry reduced the complication rate of DSAEK by introducing peripheral recipient bed scraping to promote donor adherence and he eliminated primary graft failure from upside-down grafts by advising a "taco-" shaped donor insertion.^[8] The final iteration of EK came with pure anatomic replacement: Descemet's membrane was removed from the recipient and replaced with only donor Descemet's membrane and no stromal carrier tissue. The first case of this was performed by Melles *et al.* in 2006 and he named it Descemet's membrane EK(DMEK).^[9]

Is it Worth Doing Descemet's Membrane Endothelial Keratoplasty?

While DSAEK has been performed for nearly two decades with better results compared to PK, why then should we perform DMEK?

1. To preserve the lens. When you have a young patient who has Fuchs' dystrophy, viral endotheliitis, or other reasons for a cloudy edematous cornea, it is often

better if you can leave the crystalline lens intact while doing EK. It is easier to perform DMEK in phakic eyes than in pseudophakic eyes. On the contrary, DSAEK is more difficult in the phakic eye, especially in small eyes or eyes with a shorter axial length, which is common in Asian people

2. Better visual outcome. If you have a patient who had received a DSAEK in one eye, you will be pleasantly surprised if you choose to perform DMEK in the other eye. You can get good results with DSAEK. You may often get 20/25 vision, and in a quarter of the patients, you get 20/20 vision. However, with DMEK, you can achieve 20/20 vision much more quickly than DSAEK, and a higher proportion of patients achieve 20/20 than with DSAEK. A study by Paul Phillips which included the first 100 DMEK eyes after the 3-day training course of Devers Eye Institute showed an excellent comparison to his prior 100 cases of DSAEK surgery. Most of the patients achieved 20/40 or better vision regardless of they had DSAEK or DMEK. However, a much higher percentage of patients achieved 20/20 or better vision with DMEK than with DSAEK.^[10] In our review of the literature, if you want 20/20 vision or better, the DMEK eyes achieve that level of vision more often than the reports using ultra-thin DSAEK or standard DSAEK thickness tissue
3. Lower rejection rate. The rejection rate of DSAEK and PK is between 10% and 22% with no conclusion of which rejection rate is lower due to different results from different studies. However, with DMEK, the rejection rate is significantly lower, down to 0%–7% [Table 1]^[11-16]
4. Lower endothelial cell loss. In the study examining 5-year endothelial cell loss after DSAEK and PK, DSAEK had 48.7% cell loss and PK was worse (60.9%).^[17,18] Although the extent of endothelial loss is more significant in EK than in PK in the first few months in most studies, EK is preferred to achieve long-term endothelial cell survival. Initial studies show that the cell loss from DMEK is higher than that of DSAEK in the first 6 months postoperatively, but the long-term (5 years) endothelial cell loss after DMEK appears to be comparable to that of DSAEK.^[19-21]

Table 1: Graft rejection rate of Descemet membrane endothelial keratoplasty, Descemet stripping automated endothelial keratoplasty, and penetrating keratoplasty

Article	Duration of follow-up	DMEK	DSAEK	PK
Deng, S. X.M., <i>et al.</i> (2018), mean (range)	5.7-68 months	1.9% (0%-5.9%)	10% (0%-45%)	
Sepsakos, L., <i>et al.</i> (2016), <i>n</i> (%)	3 years		400 (4.8)	
Heinzelmann, S., <i>et al.</i> (2016), <i>n</i> (%)		450 (7)	89 (21)	329 (18)
Price, M. O., <i>et al.</i> (2013), <i>n</i> (%)	3 years		173 (9)	1101 (20)
Li, J.Y., Terry, M.A., <i>et al.</i> (2012), <i>n</i> (%)	≥6 months		615 (7.3)	
Wu, E. I., <i>et al.</i> (2012), <i>n</i> (%)	3 years		353 (22)	

DMEK=Descemet membrane endothelial keratoplasty, DSAEK=Descemet stripping automated endothelial keratoplasty, PK=Penetrating keratoplasty

The Basic Laws in Descemet's Membrane Endothelial Keratoplasty Surgery

1. DMEK requires a totally different skill set than DSAEK
2. The Descemet's membrane always rolls up with the endothelium on the outside surface of the scroll. Therefore, you kill the endothelial cells every time you touch the tissue with a metal instrument and also when the tissue touches hard surfaces like an intraocular lens (IOL). Remarkably, very little damage, if any, occurs when the endothelium momentarily touches the soft surface of the iris
3. Use fluid waves to manipulate the tissue. Always be aware of how can I manipulate the wave inside the anterior chamber (A/C) to make the tissue move, like a jellyfish flowing in the currents of the ocean. If you release the fluid from the A/C, the tissue will follow and exit out of the A/C. Hence, you need to be very careful about the fluid wave and manipulate it to your advantage
4. Every tissue has a different style of scrolling. Thus the technique to unscroll it will be slightly different for every case. You have to be very patient with the tissue. Always think about what kind of fluid wave will assist the tissue in unscrolling itself. The detail of technique will be described below
5. The older the donor age, the thicker the Descemet's membrane tend to be, making it unlikely to roll upon itself and easier to unscroll it. Choose donors over 50 or 60 years old in order to have the membrane easier to unscroll. As you get better and better, you can ease up your criteria to allow younger donors
6. An orientation mark on the tissue can verify the correct orientation of the graft and prevent upside-down tissue. We use an "S" or "F" ink mark placed directly on the Descemet's membrane side of the graft right after stripping the donor and prior to allowing the tissue to scroll. The correct orientation of the donor tissue after it has been unscrolled in surgery is always verified prior to lifting the tissue up into place with the bubble.

Dr. Terry's Preferred Descemet's Membrane Endothelial Keratoplasty Surgical Technique

1. Dr. Terry started DMEK in 2009 with self-prepared tissue using a variety of injectors from that time. He and his associate, Dr. Michael Straiko, found that the instrumentation could be improved and so they modified the injector. They also recognized that the main cause of primary graft failures in the literature was from upside-down tissue and so they modified the staining procedure to also include the placement

of an orientation mark of "S" on the Descemet's side of the tissue.^[22] During January 2013 to March 2017, they instructed the Lions VisionGift (LVG) eye bank in Oregon to provide tissue that was prestripped and premarked with S stamp, which would be provided to the surgeon within 48 h. Since March 2017, LVG eye bank has provided tissue that is completely prepared for the surgeon: prestripped, pretrephined, premarked, prestained, and even preloaded donor DMEK tissue [Figure 1a]. The extensive preparation removes a lot of stress from the surgeon. The surgeon does not have to worry about tearing the tissue or any step like loading the tissue into the injector device. All you need to do is tell the eye bank what size of the graft you want because the tissue is pretrephined. If no specific request is made by the surgeon, then LVG eye bank in Oregon provides a tissue that is cut with a 7.5-mm trephine which fits perfectly into an 8.0 mm-stripped area of the recipient

2. In most of the cases, Dr. Terry uses a 7.50-mm tissue with 8.0-mm recipient stripped area. In small eyes, he very rarely uses a 7.0 mm-sized graft tissue and a 7.5-mm stripped area
3. If you do the triple procedure (with cataract surgery), do not use any cycloplegic drops, use phenylephrine 2% only. Three sets of the phenylephrine are applied to dilate the pupil. With a retrobulbar block, additional pupillary dilation can be attained
4. In 2009, they initially used a 3.5 mm corneal incision, and the incision size has become smaller with experience and modification of the injector. Note that if you use the preloaded tissue placed in the modified Jones tube, the size of the external orifice of the tube is 3.0 mm

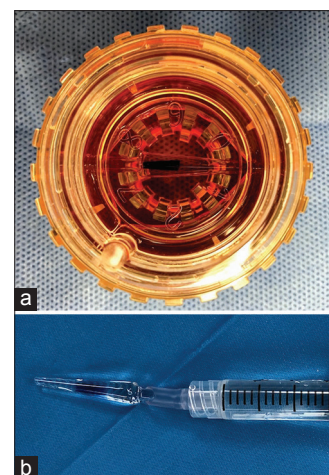


Figure 1: Straiko modified Jones tube. (a) Prestripped, pretrephined, premarked, prestained, and even preloaded donor Descemet's membrane endothelial keratoplasty tissue is stored in viewing chamber. (b) Straiko Descemet's membrane endothelial keratoplasty Jones tube inserter, which consists of modified Jones tube for Descemet's membrane endothelial keratoplasty, 14 Fr suction catheter with cutting 15 mm, and 3 cc syringe

5. Tap technique to open the scroll (see below)
6. Use 20% SF6 instead of room air because it lasts longer in the A/C. The air bubble will be dissipated in 3–4 days, and the 20% SF6 gas can last from 6 to 8 days, providing a longer time for the tissue to be supported. The tissue has been through a lot of trauma during the entire eye bank processing steps, and when you unscroll the tissue, that is an additional trauma. The endothelium needs time to recover. It is the recovery of the endothelial pump mechanism that allows long-term self-adherence of the tissue
7. Modified Jones tube for DMEK + 14 Fr suction catheter with cutting 15 mm +3 cc syringe → Straiko DMEK Jones tube inserter [Figure 1b]. This glass tube can be sterilized easily with an autoclave and then can be used several times. The original Jones glass tube was modified with an outpouching in the middle. In this configuration, the fluid goes slower in this proximal area and allows more controlled tissue movement within the injector. In a straight configuration, the tissue will move quickly and unpredictably with syringe plunger compression.

Details of the Descemet's Membrane Endothelial Keratoplasty Technique

Special notes to the surgical technique are indicated below with an asterisk*.

1. It is usually performed with a temporal approach under retrobulbar anesthesia
2. Mark the entry sites of the two paracenteses and 3.0-mm main wound. Two paracenteses will be four clock hours away from each other, with the main wound in the center of them [Figure 2a]
3. Mark an 8.0-mm circle of the corneal surface. This will guide the DM stripping of the recipient cornea. Interrupted dot marks are used; this allows us to see the DM clearly between the marks. To begin, we press an 8.0-mm circle ring on the corneal epithelium without ink. Make sure that this mark does not overlap the internal openings of your main wound or paracentesis wound. Dry the dimple edge with a swab. Use a fine-tip mark pen to mark several dots on it, usually 8–10 dots. Spare one dot at the inferior area to allow better visualization for making the peripheral iridectomy (PI) [Figure 2a]
*The goal of the DMEK graft position is to stay within the stripped area. If the stripped area involves the inner orifice of the wounds, then the elevation of the posterior stroma at the wound from postoperative stromal edema may cause the graft edge lifting and subsequent graft detachment postoperatively
4. Perform two self-sealing paracenteses. Fill the A/C with cohesive viscoelastic
5. Make the first plane of main wound

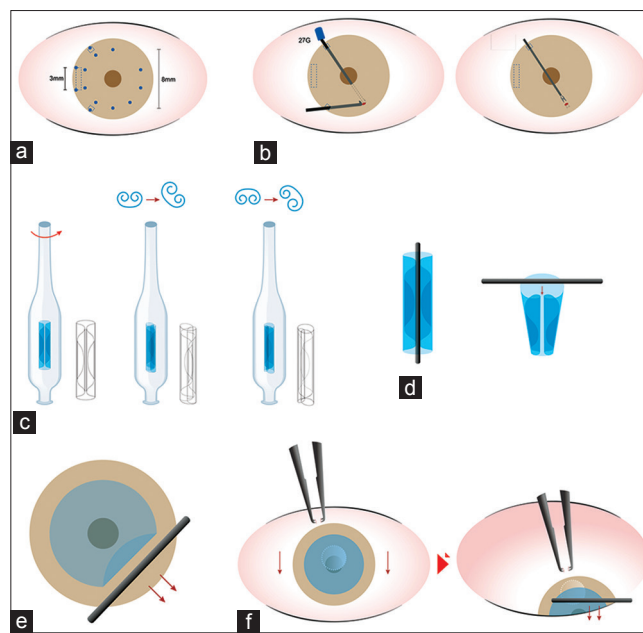


Figure 2: The schematic diagram of surgical procedures. (a) The markings of wound and descemetorhexis. (b) Performing inferior peripheral iridectomy. (c) Reveals how to determine right side up of tissue. While turning of the Straiko modified Jones tube clockwise, the left fold of the double-folded tissue becomes wider if it is right side up (c middle). The right fold of the tissue becomes wider if it is upside down (c right). (d) The position of tapping to open the scroll. (e) The "compress and release" technique. (f) How to center the tissue with small bubble beneath the graft. Please see the article for the detail

The main wound will be of three planes. We perform the first vertical plane with a diamond knife which is set at 300 μ m in depth. The second and third planes will be done after DM stripping

6. DM stripping with a reverse Terry–Sinskey hook from the right paracentesis:
Start with the location diagonally across the paracentesis with a tiny left and right motion to score an opening of the DM. After opening the DM, score the DM following the path of the 8-mm surface mark in a continuous manner
*The depth of DM scoring should be as deep as the thickness of DM itself in order to avoid unnecessary posterior stroma damage. Do not push anteriorly too hard with the tip of the Terry–Sinskey hook. The DMEK graft may detach from the area in contact with a rough and elevated recipient posterior stroma surface and adversely increase the rebubble rate. This problem is usually not encountered in DSAEK
7. Lift the edge of DM with the reverse Terry–Sinskey hook. Gently scrape the DM from the peripheral edge toward the center. A Sales Stripper Paddle is then used to wipe the recipient Descemet's membrane from the periphery edge to the center, freeing it up entirely from the overlying stroma. We then remove the stripped DM entirely with Straiko double-ringed forceps. (All specialized instruments are available from Bausch and Lomb Surgical, St. Louis, Missouri, USA.)

*The size of DM stripping should be precisely matched to the 8-mm marked circle. This ensures that the graft attachment area is devoid of recipient DM. Preserve the recipient DM outside the 8-mm circle that will not be covered by the graft. Lifting the edge of DM with the reverse Terry–Sinsky hook before stripping can prevent inadvertent peripheral DM tearing. (The same concept as performing continuous-tear curvilinear capsulorrhexis in cataract surgery.)

8. Intraocular injection of Miochol (acetylcholine chloride)/Miostat is then done to constrict the pupil as much as possible

9. Inferior PI. To make a small but patent PI, Dr. Terry prefers using an intraocular scissors. The procedure is as follows: bend the very tip of a 30G needle perpendicularly to the bevel side. Put some cohesive viscoelastic through the pupil and behind the iris where the inferior PI will be performed. Make a small hole of inferior iris with a bended 30G needle beneath the iris and straight Sinsky hook above the iris. The iris hole can be made with rubbing the needle and Sinsky hook against each other to create the hole in the iris and remove the instruments. Inject the viscoelastic around the iris hole to enlarge it a little bit. Use intraocular scissors to make a triangular cut at the iridotomy hole and then cut the triangle out, resecting that bit of iris tissue and transforming an iridotomy into a true iridectomy [Figure 2b]

*Make sure that the removed tissue contains the dark pigment of the posterior iris, which means that the iris has been penetrated thoroughly, and there is a true hole in the peripheral iris

10. Using irrigation/aspiration tip to remove iris fragment and viscoelastic: Aspirate the iris fragment first, then the viscoelastic as thoroughly as possible by turning the I/A tip

*Remove the fragment first, or the fragment may stick to the angle or to the interface when manipulating the donor tissue with fluid waves

11. Prepare the tissue. Here, we will use a preloaded, premarked, and prestained tissue provided by LVG eye bank [Figure 1a], and all work is done under the microscope at a separate donor table. Gently grasp the Straiko modified Jones tube (S-J tube) horizontally at the neck part with hemostat forceps and make a counterforce with any forceps to take the S-J tube out of the transfer case

Then, grasp the S-J tube with the fingers of the other hand at the widest part of the tube (the stronger part of the glass). Move the S-J tube to a Petri dish filled with balanced salt solution (BSS). Connect the S-J tube to the 3-ml syringe with a 15-mm section of 14 Fr nasogastric tubing, after filling the syringe with 2–3 cc BSS in it. Remove the distal plug of the S-J tube. Now that the injector is fully assembled, put the distal tip

into the BSS in the Petri dish. Eject the optisol gently and aspirate the BSS up gently

*At the point of exchange from the optisol to BSS, movements of the syringe plunger are gentle to prevent the scroll from being ejected out or aspirated into the neck of the S-J tube

*Make sure that there are no bubbles in the injection system. If there is some air in the 3 cc syringe or 14 Fr tube, eject some BSS to fill all the tube with BSS before connecting to the S-J tube

12. Check the orientation of the scroll in the tube under the microscope, and make sure that you can identify which side is right side up [Figure 2c]. Before injecting the tissue, make sure that the A/C is free from fragment, fibrin, viscoelastics, or any other debris that may prevent graft attachment

*If the scroll sticks on to the wall of S-J tube, make a tiny burst of fluid flow with aspirating the BSS in the Petri dish into the S-J tube. If this does not work, then direct irrigation of the tissue with a burst of fluid from a cannula placed through the distal tube opening and directed at the tissue will always free the tissue up

13. Inject the scroll into the A/C. With a deep A/C and normal pressure, enter the main wound quickly with the S-J tube bevel down first, and then rotate the tube to allow for the correct orientation of the scroll. If the chamber is not shallow after entrance of the tip of the injector, shallow the chamber from the paracentesis site. Inject the tissue. There are four key points to remember in order to prevent the tissue from being ejected accidentally from the wound when withdrawing the S-J tube. First is to inject the tissue a little bit further and make the alignment of the scroll perpendicular to the S-J tube. Second is to make the chamber shallow and eyeball soft before removing the S-J tube. Third is turning the bevel of the S-J tube down to the iris completely before coming out; this will stretch the wound opening less and allow for a more controlled exit of the injector from the eye. Fourth is using a second instrument to press the main wound immediately while the S-J tube comes out, to further insure that the wound is closed and to prevent the donor tissue from exiting

14. Suture the main wound with a loose stitch

*If a tight or normal tension suture is placed, then in a soft eye, it can cause a crease to form across the central cornea, distorting the dome shape of the cornea and making unscrolling of the donor tissue more difficult

15. Open the scroll and center it. We try to place the “F” mark at a superior location, but it is not essential. Please see below for the details on centering

*Graft centration is more important in DMEK because graft overlap with the recipient DM may increase the rebubble rate. Overlap of the donor and recipient tissue edges does not seem to affect rebubble rate with DSAEK

16. Inject 20% SF₆ gas into the A/C. When the tissue is centered with 90% or more of the scroll opened, put a small bubble using a 1.0 cc syringe at the center of the graft to lock in its position. Check the orientation (not upside down) and centration first. If these are all correct, enlarge the bubble to cover the edge of the entire graft. Minimal rolling edge of tissue will usually be smoothed out when the gas bubble is enlarged

*When injecting the gas bubble, keep the eyeball in primary gaze without tilting, or the position of the graft may shift and become eccentric

*When enlarging the bubble, inject gas only when the tip of cannula is within the bubble, or you can create two independent bubbles

*When the bubble edge has covered the inner orifice of the paracentesis wound, inject more gas at the outer orifice of the wounds. Do not enter the tunnel of the cornea wound, or else the gas will leak out easily, making it more difficult to enlarge the bubble and maintain the pressure

17. Check the following: First, is the "F" in the correct orientation showing that the graft is definitely right side up? Second, are all edges of the graft opened fully?

18. Increase the intraocular pressure (IOP) with more gas injection. Wait for 2–3 min with an elevated IOP

19. Put some BSS directly into the center of the bubble; this will release the bubble a little bit to 70%–80% of its original size, which should easily cover the edge of graft in the primary position. Grab the conjunctiva and move the eyeball around to make sure the air bubble is freely movable

*When the gas bubble is in the A/C only, it can move freely. If the gas bubble is stuck and immobile, it means that the bubble may be connected to another bubble behind the iris. The goal is to have the IOP normal, the iris-lens diaphragm in a horizontal position, and the gas bubble inside the eye filling about 90% of the chamber, but small enough that the inferior paracentesis site is fully uncovered in the simulated sitting position. (By rotating the eye inferiorly while the patient is still supine, you can determine if the inferior PI will be uncovered by the bubble in the upright position.)

20. Check the tension of the main wound suture and replace the suture if needed

21. Check the IOP. Check the wound and make sure it is watertight.

Opening the scroll: Use "water wave" to manipulate the scroll

1. All unscrolling maneuvers should be done in a very shallow chamber, but not a flat chamber
2. First try to assess if the tissue is right side up (the edges of the graft are scrolling up toward you) or upside down (the edges of the graft are scrolling down toward the iris)

3. Tap the scroll at the relatively opened tip first. While it is semi-opened, tap the central scroll to make it open more [Figure 2d]

4. If the graft edge remains folded when it is unscrolled, there are two ways to unfold it. First is to gently tap the area ahead of the fold to generate a fluid wave to push it open. Second is the "compress and release" technique

5. "Compress and release" technique [Figure 2e]

Compress the cornea peripherally to the graft fold, and then quickly release the compression peripherally. This will generate a fluid wave traveling from the center to the periphery and spread out the folded graft edge. In fact, there will be two effects of "compress and release" technique. One is open the edge of folding. Another is creating a vacuum and sucking the tissue peripherally, so this maneuver can also be used for centering the tissue.

6. Quick release of fluid. The tissue will move toward any point where fluid is released from the A/C. Therefore, a cannula can be placed in a paracentesis site and, with quick compression of the site, fluid is released and the edge of the tissue (or the entire tissue scroll) will move toward that location. This quick release of fluid can also be done at the main wound, but is of higher risk that the tissue will move too quickly and exit from the eye.

The following link is the YouTube video "DMEK Tips and Tricks" done by Dr. Michael D. Straiko from Devers Eye Institute, in which there is very nice demonstration of tricks for opening the graft (<https://www.youtube.com/watch?v=NuC7ZjHGICc>).

Center the tissue

1. While the scroll is still folded, we can "push" the tissue toward the other side with a water wave. Using two cannulas, alternating tapping outside of the graft with the tapping directed toward the opposite side of cornea will move the tissue in that direction

2. "Compress and release" technique can make a suction wave toward the releasing direction

3. If the tissue is almost opened, place a small bubble beneath it to move the tissue up against the recipient stromal bed and prevent it from falling posteriorly and rescrolling. If the eye is in primary gaze, the tissue should center well. If the tissue is not fully centered, fill the chamber with BSS to create a relatively deep chamber and a small bubble. Rotate the eyeball toward the direction we want to move the tissue. This rotation will then move the small bubble to the proximal edge of the tissue, to help "push" the tissue in the direction we want the tissue to move. Then, a cannula or specialized "Cindy Sweeper" (used in DSAEK surgery) is used to compress the cornea quickly in a sweeping motion, from proximal to distal limbus, sweeping the corneal surface toward the desired direction of tissue

movement. While sweeping, the bubble will be pushed posteriorly a little bit and separated from the tissue for a microsecond. Then, the tissue will be able to move slightly until it is then held in position again when the bubble floats up and contacts it. Several short sweeping movements may be necessary to achieve the desired centered position. (It is a similar technique we use in centering the DSAEK graft, but with a much smaller bubble for DMEK.) [Figure 2f].

Tips with triple surgery

1. Make paracentesis and main wound as above
2. Do the cataract surgery first, but do not remove the cohesive viscoelastic
3. Then, strip the recipient DM and remove it while the pupil is still large
4. Enlarge the main wound to a full 3 mm
5. Miochol/Miosat will be injected after the DM stripping and wound enlargement because it is easier to perform DM stripping with retroillumination when the pupil is enlarged. The pupil will constrict, even with viscoelastic in the A/C
6. Perform the inferior iridotomy after pupil constriction
7. Remove the iris fragment and viscoelastic from the capsular bag and the A/C. To ensure that all of the viscoelastic has been removed from the capsular bag, tap the IOL gently with the I/A tip to remove the viscoelastics behind the IOL.

Several things to pay attention

1. Protect the temporal iris as much as possible. Because if it gets floppy and comes out from the main wound, it will increase the difficulty of pupil constriction and gas support to the graft. The gas may seep behind the iris easily if you have created a floppy iris through surgical trauma. In addition, trauma causes iris strands on the surface or blood or fibrin, and all of these can grab the scrolled donor tissue, making unscrolling and centration very difficult
2. If you are not certain where the recipient DM stripping area is, put an air bubble in the A/C after viscoelastic removal to allow a better viewing of the DM edge.

Trouble shooting

1. Difficulty with tissue injection: Keep the injector tip inside the A/C and also release more aqueous from the A/C through the paracentesis sites to shallow the chamber more and reduce the IOP, which is preventing the delivery of the graft
2. Upside down graft: Deepen the chamber to allow the tissue to rescroll again, and then make several burst injections of BSS to flip the scroll over to the correct orientation
3. "Fish eggs" bubble:

- If there are several small bubbles peripherally without connecting to the central big bubble, tap the limbus with two cannulas to break the surface tension between the bubbles. Do not do this maneuver if the small bubbles are directly beneath the graft or you will damage the endothelium in that area
4. Postoperative pupillary block. Release the bubble from the inferior paracentesis. It will release enough gas to make a smaller bubble and expose the inferior PI to prevent pupillary block. If you release the bubble from the superior paracentesis, you may accidentally remove too much gas with nothing left to support the graft tissue.

Suggestions for the Beginner

1. In the beginning, practice the surgery in the laboratory
2. Perform the first few cases under general anesthesia to reduce the stress of the surgeon and the patient. Then, once you are familiarized with the technique, you can gradually switch to perform the surgery under peribulbar or retrobulbar anesthesia. Dr. Terry currently does most of the surgeries with a retrobulbar block because he found that it eliminates any unexpected motion of the patient while teaching the fellow. If you are completely familiar with the surgery, you may do it under topical anesthesia in patients who are cooperative, need to have the surgery done very quickly such as patients with a bleeding disorder, or if you have any concerns with the patients having a retrobulbar block
3. Start with donor tissues that are from donors 60 years of age or older. Because the Descemet's membrane gets thicker when we get older; the older the donor, the easier it is to unscroll the tissue
4. If you have problem of obtaining trypan blue for staining the donor tissue, you may use preloaded, prestained tissue. Preliminary experiments by Dr. Shin-Yi Chen also indicate that the use of Patent Blue stain may be sufficient and more readily available in some countries
5. Begin your first case with Fuchs' dystrophy or simple corneal edema where the view into the eye is not severely compromised
6. One key aspect is to have a small pupil when you put the tissue inside the eye. This prevents the tissue from being damaged by coming into contact with the plastic of an IOL, or from dropping behind the iris to the posterior chamber. If you need to perform cataract surgery and EK, as a novice DMEK surgeon, consider doing cataract surgery first and then waiting for about 3 weeks to perform the EK through the same incision wound. That way, you can make the pupil very small for the DMEK surgery. If you want to perform the triple procedure with cataract surgery

done simultaneously, avoid using cycloplegics preoperatively. If you use cycloplegics, you cannot easily make the pupil small again. Using a few drops of phenylephrine is usually enough to stimulate the dilator muscle, without paralyzing the sphincter muscle. Then, you use retrobulbar anesthesia to dilate the pupil further. This is usually more than enough to achieve a dilated pupil for safe cataract surgery. After the cataract surgery, you can give intracameral acetylcholine to constrict the pupil for safe DMEK surgery

7. Furthermore, in the triple procedure, the target power of IOL is -0.75 to -1.0 D. It is surprising that the average of post-DMEK refraction is still a hyperopic shift instead of no change. When the corneal edema goes away after the procedure, it changes the anterior and posterior curvatures of cornea. It is very important that you tell your patient it is not a refractive surgery. Forty percent of patients will get a slightly myopic shift, and 60% of patients will get a hyperopic shift. The induced refractive shifts range from -0.5 to $+2.0$ D.^[23]
8. Once you master the DMEK with simple corneal edema, you can perform more complex cases, such as cases with a failed PK, or advanced cases with pseudophakic bullous keratoplasty
9. In cases with very edematous cornea, remove the thick epithelium from the swollen cornea to improve your view. Perform DMEK in more challenging cases with a very swollen cornea when you are comfortable with the procedure
10. Avoid eyes which had previous vitrectomy, filtration surgeries, AC-IOL implantation, etc. In eyes with prior vitrectomy lacking the posterior vitreous to push the iris forward, you will have a very difficult time of shallowing the A/C. One of the key factors of the surgery is to shallow the chamber. Notably, you do not want to tap the tissue on the top of an AC-IOL. The problem in eyes that had prior filtration surgery is that when you inject air in the A/C to support the graft, it will leak out through the filter. By the next day, you will have a very small or no air bubble in the A/C. Unlike DSAEK, you need to have bubble support for as long as possible in DMEK to help the tissue adherence until the endothelium recovers and achieves self-adherence. The rebubbling rate is much higher in patients who have had filtration surgery than the rate in a standard patient.

Conclusion

The DMEK procedure is pure anatomic replacement of the patient's diseased endothelial tissue and allows better visual results and better visual quality than DSAEK. The effort to learn this new procedure is well worth the effort. Attention to the nuances of this procedure will

increase your success rate and reduce the complication rate considerably. This is an incredible time in the history of corneal transplantation, so enjoy the learning period of DMEK surgery and rejoice in the benefits that you are providing your patients!

Acknowledgment

The authors thank Dr. Jerry Chien-Chieh Huang for English editing and Miss Chao-Shien Hsu for the drawing of schematic diagram of the surgical procedures.

Financial support and sponsorship

Nil.

Conflicts of interest

The authors declare that there are no conflicts of interests of this paper.

References

1. Zirm EK. Eine erfolgreiche totale keratoplastik (A successful total keratoplasty). 1906. *Refract Corneal Surg* 1989;5:258-61.
2. Tillett CW. Posterior lamellar keratoplasty. *Am J Ophthalmol* 1956;41:530-3.
3. Ko WW, Frueh BE, Shields CK, Costello ML, Feldman ST. Experimental posterior lamellar transplantation of the rabbit cornea. (ARVO abstract) *Invest Ophthalmol Vis Sci*. 1993;34:1102.
4. Terry MA, Ousley PJ. Deep lamellar endothelial keratoplasty in the first United States patients: Early clinical results. *Cornea* 2001;20:239-43.
5. Nieuwendaal CP, Lapid-Gortzak R, van der Meulen IJ, Melles GJ. Posterior lamellar keratoplasty using descemetorhexis and organ-cultured donor corneal tissue (Melles technique). *Cornea* 2006;25:933-6.
6. Price FW Jr., Price MO. Descemet's stripping with endothelial keratoplasty in 50 eyes: A refractive neutral corneal transplant. *J Refract Surg* 2005;21:339-45.
7. Gorovoy MS. Descemet-stripping automated endothelial keratoplasty. *Cornea* 2006;25:886-9.
8. Terry MA, Shamie N, Chen ES, Hoar KL, Friend DJ. Endothelial keratoplasty a simplified technique to minimize graft dislocation, iatrogenic graft failure, and pupillary block. *Ophthalmology* 2008;115:1179-86.
9. Melles GR, Lander F, Rietveld FJ. Transplantation of descemet's membrane carrying viable endothelium through a small scleral incision. *Cornea* 2002;21:415-8.
10. Phillips PM, Phillips LJ, Muthappan V, Maloney CM, Carver CN. Experienced DSAEK surgeon's transition to DMEK: Outcomes comparing the last 100 DSAEK surgeries with the first 100 DMEK surgeries exclusively using previously published techniques. *Cornea* 2017;36:275-9.
11. Wu EI, Ritterband DC, Yu G, Shields RA, Seedor JA. Graft rejection following descemet stripping automated endothelial keratoplasty: Features, risk factors, and outcomes. *Am J Ophthalmol* 2012;153:949-570.
12. Price MO, Gorovoy M, Price FW Jr., Benetz BA, Menegay HJ, Lass JH, *et al.* Descemet's stripping automated endothelial keratoplasty: Three-year graft and endothelial cell survival compared with penetrating keratoplasty. *Ophthalmology* 2013;120:246-51.
13. Heinzelmann S, Böhlinger D, Eberwein P, Reinhard T, Maier P.

- Outcomes of descemet membrane endothelial keratoplasty, descemet stripping automated endothelial keratoplasty and penetrating keratoplasty from a single centre study. *Graefes Arch Clin Exp Ophthalmol* 2016;254:515-22.
14. Sepsakos L, Shah K, Lindquist TP, Lee WB, Holland E. Rate of rejection after descemet stripping automated endothelial keratoplasty in fuchs dystrophy: Three-year follow-up. *Cornea* 2016;35:1537-41.
 15. Deng SX, Lee WB, Hammersmith KM, Kuo AN, Li JY, Shen JF, *et al.* Descemet membrane endothelial keratoplasty: Safety and outcomes: A report by the american academy of ophthalmology. *Ophthalmology* 2018;125:295-310.
 16. Li JY, Terry MA, Goshe J, Shamie N, Davis-Boozer D. Graft rejection after descemet's stripping automated endothelial keratoplasty: Graft survival and endothelial cell loss. *Ophthalmology* 2012;119:90-4.
 17. Price MO, Calhoun P, Kollman C, Price FW Jr., Lass JH. Descemet stripping endothelial keratoplasty: Ten-year endothelial cell loss compared with penetrating keratoplasty. *Ophthalmology* 2016;123:1421-7.
 18. Ang M, Soh Y, Htoon HM, Mehta JS, Tan D. Five-year graft survival comparing descemet stripping automated endothelial keratoplasty and penetrating keratoplasty. *Ophthalmology* 2016;123:1646-52.
 19. Marques RE, Guerra PS, Sousa DC, Gonçalves AI, Quintas AM, Rodrigues W, *et al.* DMEK versus DSAEK for fuchs' endothelial dystrophy: A meta-analysis. *Eur J Ophthalmol* 2018;1120672118757431.
 20. Miron A, Bruinsma M, Ham L, Schaal SC, Baydoun L, Dapena I, *et al.* *In vivo* endothelial cell density decline in the early postoperative phase after descemet membrane endothelial keratoplasty. *Cornea* 2018;37:673-7.
 21. Price DA, Kelley M, Price FW Jr., Price MO. Five-year graft survival of descemet membrane endothelial keratoplasty (EK) versus descemet stripping EK and the effect of donor sex matching. *Ophthalmology* 2018;125:1508-14.
 22. Veldman PB, Dye PK, Holiman JD, Mayko ZM, Sáles CS, Straiko MD, *et al.* Stamping an S on DMEK donor tissue to prevent upside-down grafts: Laboratory validation and detailed preparation technique description. *Cornea* 2015;34:1175-8.
 23. Schoenberg ED, Price FW Jr., Miller J, McKee Y, Price MO. Refractive outcomes of descemet membrane endothelial keratoplasty triple procedures (combined with cataract surgery). *J Cataract Refract Surg* 2015;41:1182-9.