

# Precaution and prevention of coronavirus disease 2019 infection in the eye

Meng-Jou Chen<sup>a</sup>, Kao-Jung Chang<sup>b,c</sup>, Chih-Chien Hsu<sup>a,c,d,\*</sup>, Pei-Yu Lin,<sup>a,c</sup> Catherine Jui-Ling Liu<sup>a,c</sup>

<sup>a</sup>Department of Ophthalmology, Taipei Veterans General Hospital, Taipei, Taiwan, ROC; <sup>b</sup>Department of Medical Research, Taipei Veterans General Hospital, Taipei, Taiwan, ROC; <sup>c</sup>School of Medicine, National Yang-Ming University School of Medicine, Taipei, Taiwan, ROC; <sup>d</sup>Institute of Clinical Medicine, National Yang-Ming University, Taipei, Taiwan, ROC

**Abstract:** Although current studies suggested that conjunctivitis is not a common presentation of coronavirus disease 2019 (COVID-19), several studies have reported the presence of severe acute respiratory syndrome coronavirus-2 (SARS-CoV-2) in ocular secretions. Coronavirus had not yet been successfully cultured from tears or conjunctival swabs in humans, neither SARS-CoV-2 nor SARS-CoV. However, live feline coronavirus has been isolated from conjunctival swabs. In addition, infection of COVID-19 through unprotected eye exposure had been suspected in several articles. Reports of ophthalmologists and otolaryngologists died of COVID-19 also raised concern on ocular transmission. As a result, we strongly suggest that personal protective equipment (PPE) should cover the mouth, nose, and eyes of ophthalmologists, especially when conjunctivitis caused by SARS-CoV-2 is clinically indistinguishable from other viral follicular conjunctivitis.

**Keywords:** Coronavirus disease 2019; Ophthalmologists; Severe acute respiratory syndrome coronavirus-2

## 1. INTRODUCTION

Coronavirus disease 2019 (COVID-19) is currently a global pandemic affecting 184 countries with over 1.6 million people infected and more than 100 000 deaths. It was first noticed in China in December 2019 by an ophthalmologist, Dr. Li Wenliang, who died of the same disease unfortunately. Although the main route of virus transmission is through respiratory droplets, several studies have raised concerns about infection occurring through unprotected exposure to the eyes. Up until now, whether ocular secretions could be contagious is still controversial.<sup>1,2</sup> This review study is aimed to provide more insights regarding this issue by summarizing currently available information on severe acute respiratory syndrome coronavirus-2 (SARS-CoV-2), and previous knowledge of other coronaviruses either in human or in animals.

In addition, since conjunctivitis is one of the most common diseases in eye clinics, we would like to discuss the difference between different pathogens, such as other coronaviruses and adenoviruses. We would like to know more about the structure, characteristics, and tissue tropism of each virus. By better understanding how they infect host cells and release viral particles, hopefully, we could gain better insights on fighting and preventing this pandemic.

## 2. OCULAR INVOLVEMENT IN COVID-19

### 2.1. Incidence

The percentage of COVID-19 patients with conjunctivitis or other ocular manifestation is rather low. A large study from China consisting of 1099 laboratory-confirmed COVID-19 cases, only nine patients (0.8%) had conjunctival congestion.<sup>3</sup>

On the other hand, in another retrospective case series consisting of 38 clinically confirmed cases from China, 31.6% were found to have ocular manifestations similar to conjunctivitis, which was rather high compared with other studies.<sup>3,4</sup> Ocular symptoms in this study included conjunctival hyperemia, chemosis, epiphora, or increased secretions. Since chemosis in critically ill patients could be a consequence of third space shifting or fluid overload, rather than conjunctivitis, hence, the American Association of Ophthalmologists (AAO) disagreed with this statement. In this study, the presence of SARS-CoV-2 in both conjunctival and nasopharyngeal swabs was reported in two patients (5.2%).<sup>4,5</sup>

### 2.2. Presence of SARS-CoV-2 in ocular secretion

According to recent reports, SARS-CoV-2 can cause conjunctivitis and, possibly, it can be an early sign of infection. In a case series study published in the *Journal of Medical Virology*, Xia et al<sup>6</sup> 30 confirmed COVID-19 patients in China were studied. Only one of them had conjunctivitis, and SARS-CoV-2 RNA was detected by RT-PCR in ocular secretions of the same patient. However, the viability and disease progress of SARS-CoV-2 infection in these patients remained unclear.

In another study from Singapore, 17 laboratory-confirmed COVID-19 patients were recruited. All tear samples were negative for RT-PCR and viral isolation, even when concurrent nasopharyngeal swabs were shown positive. Tears were collected throughout 2 weeks of active infection, suggesting that ocular transmission is unlikely at any stage of infection. But the authors also mentioned limitations such as small sample size, only one patient had ocular symptoms, and unavailable sampling at earlier infection status.<sup>7</sup>

\*Address Correspondence. Dr. Chih-Chien Hsu, Department of Ophthalmology, Taipei Veterans General Hospital, 201, Section 2, Shi-Pai Road, Taipei 112, Taiwan, ROC. E-mail address: chihchienym@gmail.com (C.-C. Hsu).

Conflicts of interest: The authors declare that they have no conflicts of interest related to the subject matter or materials discussed in this article.

*Journal of Chinese Medical Association.* (2020) XXX: 00-00.

Received April 10, 2020; accepted April 10, 2020.

doi: 10.1097/JCMA.0000000000000334.

Copyright © 2020, the Chinese Medical Association. This is an open access article under the CC BY-NC-ND license (<http://creativecommons.org/licenses/by-nc-nd/4.0/>)

### 2.3. Hints from other coronavirus: SARS-CoV

Studies have shown that SARS-CoV and SARS-CoV-2 share similar receptor-binding domain.<sup>8</sup> Transmission of SARS-CoV is believed to be by contact of infectious respiratory droplets or indirect contact of fomites with mucous membrane, namely the eyes, nose, or mouth.<sup>9</sup>

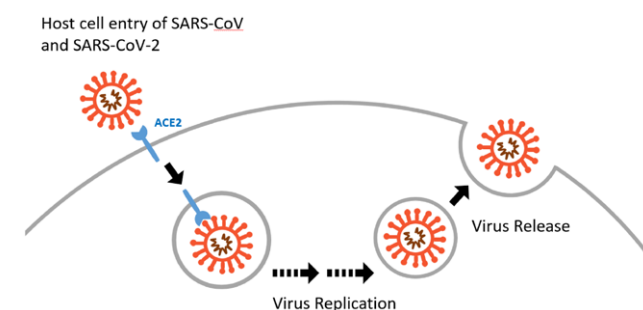
A case series report from Singapore on SARS reported the presence of SARS-CoV RNA in tear samples of three out of 36 suspected patients.<sup>10</sup> Yet in another study, the RT-PCR and viral culture were all negative for both tears and conjunctival scrapings in 17 serologically confirmed SARS patients. However, several limitations, including small sample size, one time sampling, rather low testing sensitivity, have been pointed out. Hence, the authors concluded they could not totally exclude the presence of virus in tears.<sup>10</sup>

### 2.4. Hints from coronaviruses in animals

Currently available studies on SARS-CoV-2 regarding ocular involvement are not sufficient. Previous investigation on SARS-CoV is also limited as SARS epidemic quickly retreated. Since coronavirus can also cause ocular problems in animals, such as conjunctivitis, anterior uveitis, retinitis, and optic neuritis, it is reasonable to look into the studies of coronavirus in feline and murine models. Although the viability of SARS-CoV RNA in tears remains unanswered in humans, live feline coronavirus (FCoV) has been isolated from conjunctival swabs of cats.<sup>2</sup>

## 3. COMPARISON OF CONJUNCTIVITIS ASSOCIATED WITH SARS-COV-2, SARS-COV, AND ADENOVIRUS INFECTIONS

SARS-CoV-2 can cause follicular conjunctivitis, possibly through aerosol contact with conjunctiva (Table and Figs. 1 and 2). Acute conjunctivitis is one of the most commonly encountered diseases in the clinic, with virus being the predominant pathogen. And among them, human adenoviruses (HAdVs) take up around 65% to 90% of cases.<sup>14</sup> Adenoviruses are nonenveloped viruses with broad tissue tropism, including mucous membranes such as ocular surface, respiratory, gastrointestinal (GI), and genitourinary (GU) tract. They are resistant to typical disinfection, such as 70% alcohol.<sup>15</sup> On the other hand, enveloped viruses such as



**Fig. 1** Host cell entry and virus release of SARS-CoV and SARS-CoV-2.<sup>12</sup> SARS-CoV, severe acute respiratory syndrome coronavirus.

coronavirus are more sensitive to simple disinfection, heat, dryness, or extreme pH.

Both SARS-CoV and SARS-CoV-2 belong to lineage B beta-coronaviruses and have the same host cell entry receptor, angiotensin-converting enzyme 2 (ACE2). Expression of ACE2 can be found in respiratory and intestinal tracts, renal, cardiac, and immune cells.<sup>16</sup> It has also been demonstrated in aqueous humor and retina, but not in conjunctiva or cornea. This could be the reason for low incidence of conjunctivitis in COVID-19 patients. Regarding its relative, SARS-CoV, a review article in the *New England Journal of Medicine* reported that 752 SARS patients had no ocular manifestation.<sup>9</sup> As for how SARS-CoV-2 infects people through conjunctiva, the infectious aerosols could be drained into the nasolacrimal duct and then further into the respiratory tract with tears.

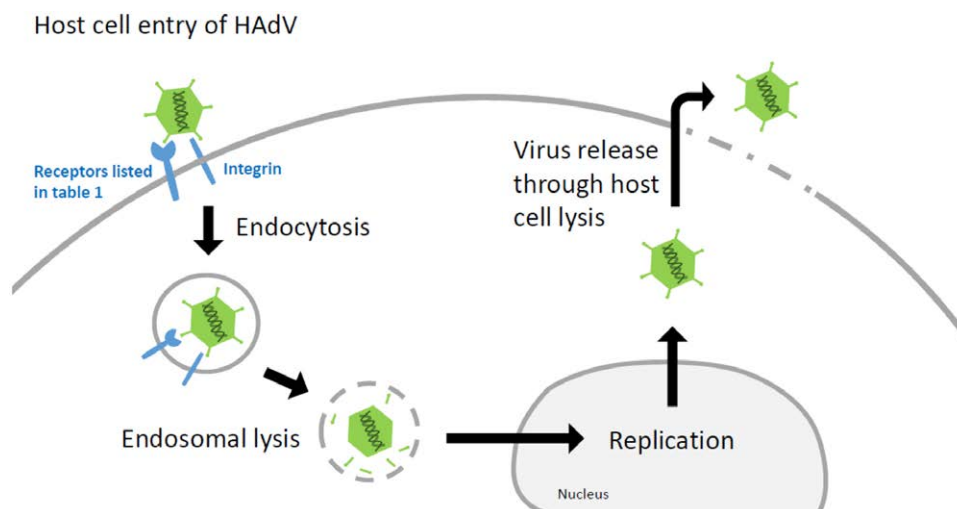
Although there is no definite evidence whether adenoviral conjunctivitis is contagious before symptoms onset, Kimura et al<sup>17</sup> examined conjunctival scraping from contralateral eyes of 32 adenoviral conjunctivitis patients for HAdV with immunochromatography and PCR. All samples were negative even in those eyes that later developed conjunctivitis with PCR-proved identical virus with the first eyes. In addition, given the characteristic of nonenveloped structure, viral spreading requires cell lysis. Hence, the possibility of viral spreading is very small before onset of symptoms. This is possibly the reason why we could not find available incidence data for HAdV in Table.

### Table

**Comparison of SARS-CoV-2, SARS-CoV, and adenovirus**

	SARS-CoV-2	SARS-CoV	HAdV <sup>11</sup>
Disease	COVID-19	SARS	Viral conjunctivitis, EKC
Conjunctivitis	Low incidence (0.8% of 1099 cases) <sup>3</sup>	Not reported (0% of 752 cases) <sup>9</sup>	Account for 65%-90% of viral conjunctivitis
Viral structure	Enveloped, single-stranded, positive-sense RNA		Nonenveloped, double-stranded DNA
Tropism	Respiratory, intestinal tracts, renal, cardiac and immune cells		Subgroup A B1 B2 C D E F Respiratory Renal Respiratory Ocular Respiratory, ocular GI tract
Host cell entry receptor	ACE2		CAR, CD46, CD80/86, receptor X, HSPG, MHC-I, VCAM-I, integrins, sialic acid (according to different subgroup)
Virus releasing	No cell lysis required		Require cell lysis
Transmission	Direct or indirect contact with respiratory droplets		Contact with ocular secretions
Typical disinfectants (70% alcohol or 3% hydrogen peroxide)	Effective		Ineffective Washing hands with soap and water is preferred

ACE2 = angiotensin-converting enzyme 2; CAR = coxsackievirus-adenovirus receptor; COVID-19 = coronavirus disease 2019; GI = gastrointestinal; HAdV = human adenovirus; HSPG = heparan sulfate proteoglycans; MHC-I = major histocompatibility complex class I; SARS-CoV = severe acute respiratory syndrome coronavirus; VCAM-I = vascular cell adhesion molecule-1.



**Fig. 2** Host cell entry and virus release of HAdV.<sup>13</sup> HAdV, human adenovirus.

Similarly to other enveloped viruses, the release of SARS-CoV-2 does not require the process of host cell lysis. This is less immunogenic compared with the disruption of the host cell. Hence, Sungnak et al<sup>18</sup> speculated this could be the mechanism of transmission in presymptomatic cases. They found the highest expression of ACE2 in nasal epithelial cells and suspected that viral release could be present before clinical symptoms developed.

In conclusion, as an emerging pandemic, the incidence of conjunctivitis in COVID-19 patients is rather low and current evidence suggested that ocular transmission is unlikely. This is contrary to the most common adenoviral conjunctivitis in clinical situations, which is highly contagious and resistant to typical disinfectants. So far, the viability of SARS-CoV-2 in human ocular secretions remains unanswered. Although neither SARS-CoV-2 nor SARS-CoV have been successfully cultured from tears or conjunctival swabs in humans, live coronavirus had been isolated from conjunctival swabs in cats.

The proposed mechanism of SARS-CoV-2 infection via conjunctiva is that respiratory droplets could be drained into the nasolacrimal duct and then further into the respiratory tract with tears. Despite the possibility of viral transmission through tears is rather low, we strongly suggest that personal protective equipment (PPE) should cover the mouth, nose, and eyes of ophthalmologists, just as the American Academy of Ophthalmology has recommended. Because of the close distance between patients and doctors during most ophthalmic exams, even the slightest risk is unbearable. The death of ophthalmologists and otolaryngologists had been reported in several countries. Therefore, extra care is required.

## REFERENCES

- Lu CW, Liu XF, Jia ZF. 2019-nCoV transmission through the ocular surface must not be ignored. *Lancet* 2020;395:e39.
- Seah I, Agrawal R. Can the coronavirus disease 2019 (COVID-19) affect the eyes? A review of coronaviruses and ocular implications in humans and animals. *Ocul Immunol Inflamm* 2020;28:391–5.
- Guan WJ, Ni ZY, Hu Y, Liang WH, Ou CQ, He JX, et al. Clinical characteristics of coronavirus disease 2019 in China. *N Engl J Med* 2020. Doi: 10.1056/NEJMoa2002032. [Epub ahead of print]
- Wu P, Duan F, Luo C, Liu Q, Qu X, Liang L, et al. Characteristics of ocular findings of patients with coronavirus disease 2019 (COVID-19) in Hubei province, China. *JAMA Ophthalmol* 2020. Doi: 10.1001/jamaophthalmol.2020.1291. [Epub ahead of print]
- American Academy of Ophthalmology. Important Coronavirus Updates for Ophthalmologists. Available at <https://www.aao.org/headline/alert-important-coronavirus-context>
- Xia J, Tong J, Liu M, Shen Y, Guo D. Evaluation of coronavirus in tears and conjunctival secretions of patients with SARS-CoV-2 infection. *J Med Virol* 2020. Doi: 10.1002/jmv.25725. [Epub ahead of print]
- Seah IY, Anderson DE, Kang AEZ, Wang L, Rao P, Young BE, et al. Assessing viral shedding and infectivity of tears in coronavirus disease 2019 (COVID-19) patients. *Ophthalmology* 2020. Doi: 10.1016/j.ophtha.2020.03.026. [Epub ahead of print]
- Wan Y, Shang J, Graham R, Baric RS, Li F. Receptor recognition by the novel coronavirus from Wuhan: an analysis based on decade-long structural studies of SARS coronavirus. *J Virol* 2020;94. Doi: 10.1128/jvi.00127-20.
- Peiris JS, Yuen KY, Osterhaus AD, Stöhr K. The severe acute respiratory syndrome. *N Engl J Med* 2003;349:2431–41.
- Chan WM, Yuen KS, Fan DS, Lam DS, Chan PK, Sung JJ. Tears and conjunctival scrapings for coronavirus in patients with SARS. *Br J Ophthalmol* 2004;88:968–9.
- Sharma A, Li X, Bangari DS, Mittal SK. Adenovirus receptors and their implications in gene delivery. *Virus Res* 2009;143:184–94.
- Song Z, Xu Y, Bao L, Zhang L, Yu P, Qu Y, et al. From SARS to MERS, thrusting coronaviruses into the spotlight. *Viruses* 2019;11. Doi: 10.3390/v11010059.
- Waye MMY, Sing CW. Anti-viral drugs for human adenoviruses. *Pharmaceuticals* 2010;3:3343–54.
- O'Brien TP, Jeng BH, McDonald M, Raizman MB. Acute conjunctivitis: truth and misconceptions. *Curr Med Res Opin* 2009;25:1953–61.
- Kuo IC. Adenoviral keratoconjunctivitis: diagnosis, management, and prevention. *Curr Ophthalmol Rep* 2019;7:118–27.
- Tikellis C, Thomas MC. Angiotensin-converting enzyme 2 (ACE2) is a key modulator of the renin-angiotensin system in health and disease. *Int J Pept* 2012;2012:256294.
- Kimura R, Migita H, Kadonosono K, Uchio E. Is it possible to detect the presence of adenovirus in conjunctiva before the onset of conjunctivitis? *Acta Ophthalmol* 2009;87:44–7.
- Sungnak W, Huang N, Bécavin C, Berg M; HCA Lung Biological Network. SARS-CoV-2 entry genes are most highly expressed in nasal goblet and ciliated cells within human airways. 2020. ArXiv200306122 Q-Bio