

# Chronic actinic dermatitis: An only presenting manifestation of human immunodeficiency virus in a young Indian male

Manoj Pawar, Vijay Zawar

Department of Dermatology, MVP's Dr. Vasantaro Pawar Medical College and Hospital and Research Center, Nashik, Maharashtra, India

## Address for correspondence:

Dr. Manoj Pawar, Flat No. 11, Manomay Apartment, Khande Mala, Savatanagar, CIDCO, Nashik - 422 008, Maharashtra, India.  
E-mail: manojpawar624@yahoo.com

## Abstract

Skin diseases often provide the first clue to diagnose human immunodeficiency virus (HIV) infection and may serve as a clinical indicator of the underlying immune status of the patient. Photodermatitis in HIV patients presents with a protean of clinical manifestations, and it usually develops after the diagnosis or during the course of HIV, especially in patients with low CD4 counts. We present the case of a young, healthy Indian male with chronic actinic dermatitis (CAD), who was later confirmed to have HIV seropositivity with CD4 count of 180/ $\mu$ l, without any systemic illness or evidence of acquired immunodeficiency syndrome (AIDS)-defining illnesses. CAD as an initial presentation of HIV is a rare finding, especially in the absence of other AIDS-defining illnesses.

**Key words:** Actinic dermatitis, chronic, human immunodeficiency virus

## INTRODUCTION

Photodermatoses are less frequent cutaneous markers of human immunodeficiency virus (HIV) infection. If present, chronic actinic dermatitis (CAD) and lichenoid photoeruptions account most of it.<sup>[1-3]</sup> The term “chronic

actinic dermatitis” encompasses persistent light reactivity, photosensitivity dermatitis, and actinic reticuloid syndrome.<sup>[2]</sup>

This is an open access journal, and articles are distributed under the terms of the Creative Commons Attribution-NonCommercial-ShareAlike 4.0 License, which allows others to remix, tweak, and build upon the work non-commercially, as long as appropriate credit is given and the new creations are licensed under the identical terms.

**For reprints contact:** WKHLRPMedknow\_reprints@wolterskluwer.com

**How to cite this article:** Pawar M, Zawar V. Chronic actinic dermatitis: An only presenting manifestation of human immunodeficiency virus in a young Indian male. Indian J Sex Transm Dis 2020;41:207-10.

**Submitted:** 31-Jan-2019

**Revised:** 07-Feb-2019

**Accepted:** 09-Jan-2020

**Published:** 11-Nov-2020

### Access this article online

Quick Response Code:



Website:

www.ijstd.org

DOI:

10.4103/ijstd.IJSTD\_8\_19

## CASE REPORT

A 26-year-old unmarried, Indian healthy male of skin Type V presented with itchy skin lesions of 1-year duration. Initially, it started as pruritic hyperpigmented papular eruptions over the dorsa of both hands and then involved the scalp, forehead, malar region of face, "V" region of the neck, nape of the neck, lateral aspect of the back, and extensor aspects of both forearms, whereas the initial lesions over hands coalesced to form plaques in 1-year duration [Figures 1 and 2]. Both skin lesions and itching used to aggravate on sun exposure. He was treated with topical steroids and oral antihistamines, resulting in temporary relief of symptoms. Due to the chronic nature of the lesions, the patient was referred to us. He had a history of promiscuous behavior. He did not have any systemic illness or history of atopy, allergy, nor did he take any medications other than the prescribed ones. There was no family history of similar illness or photosensitivity.

Cutaneous examination revealed multiple, well-defined, hyperpigmented papules and plaques of varying sizes with crust at some places, predominantly distributed over photo-exposed areas, relatively sparing covered areas. Few plaques over dorsa of both hands showed depigmentation. Rest of the nail, hair, lips, eyes, mucosae, and systemic examination did not reveal any abnormality.

Recurrent and refractory nature of these lesions and the patient's promiscuous behavior led us to do his HIV testing. Enzyme-linked immunosorbent assay for HIV-1 turned out positive, which was further confirmed by Western blot assay. Rest of all the investigations including antinuclear antibody, ds-DNA, 24-h urine protein, chest X-ray, and hepatitis B and C serology were negative or normal. The porphyrin concentrations of blood, urine, and stool were within normal limits. His CD4 T-lymphocyte count was found to be 180/ $\mu$ l. Skin biopsy from the lesion revealed changes of nonspecific chronic dermatitis, i.e., parakeratosis and mild spongiosis in epidermis and perivascular lymphocytes and fibrocollagenous and mononuclear cells in the dermis [Figure 3]. Photopatch test, phototesting, and human leukocyte antigen typing could not be done due to lack of resources. Considering the clinical and histological findings, the patient was labeled as a case of CAD.

He was advised restriction of outdoor activities; to wear full, appropriate clothing; and was started on highly active antiretroviral therapy (HAART), i.e., zidovudine 300 mg, lamivudine 150 mg, and nevirapine 200 mg once daily each, along with broad-spectrum sunscreen, topical potent steroid (clobetasol 0.05% ointment), and oral antihistamines and prednisolone 40 mg daily with antacids.

## DISCUSSION

Photodermatoses due to HIV is a rare phenomenon

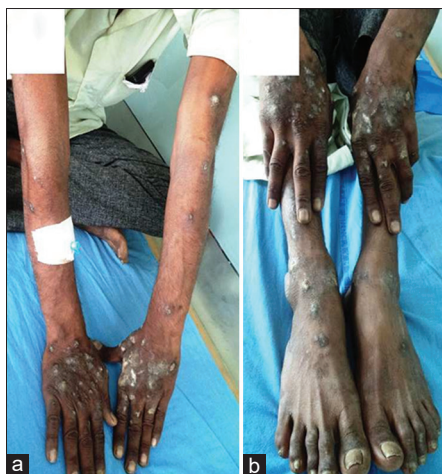and accounts for 5%.<sup>[3,4]</sup> Photosensitivity more typically occurs when CD4 T-lymphocyte counts drop below 50/ $\mu$ l and becomes chronic with the decrease in it. Actinic prurigo, polymorphic light eruption, CAD, lichenoid photo-eruption, actinic reticuloid, porphyria cutanea tarda, photosensitive granuloma annulare, photo-distributed hyperpigmentation, and vitiligo-like depigmentation are few reported photodermatoses in HIV-positive patients.<sup>[1,3-9]</sup>

CAD is an uncommon dermatosis with abnormal photosensitivity to ultraviolet (UV)-B, UV-A, and often visible wavelengths. It consists of recurrent pruritic eczematous eruptions over UV light-exposed skin, which progress to more lichenified and generalized appearance, characteristically sparing covered areas. CAD is accompanied by a reduction in the minimal erythema dose (MED) of covered skin to UV-B and a histologic picture of chronic eczema (with or without "lymphoma like" changes).<sup>[1,5]</sup> It is common in temperate climate and occurs frequently in elderly men of skin Types V–VI. Although we could not perform phototest and photopatch testing in our patient, his clinical and histological features were strongly suggestive of CAD.

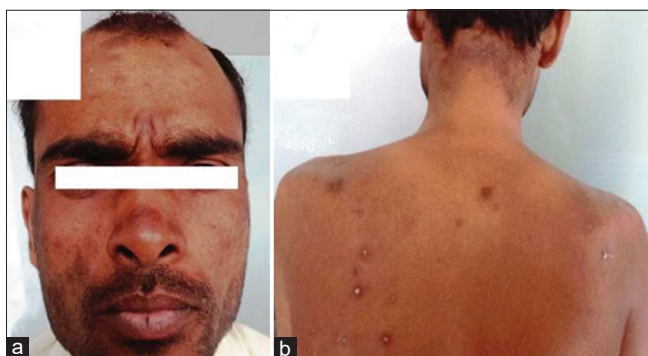Photosensitivity and CAD have been documented as presenting manifestations of HIV in certain patients.<sup>[1,7]</sup> CAD with HIV was more commonly observed in African-Americans of skin Type VI and also has been reported in Japanese, Colombian, and Chinese patients.<sup>[1,5-7]</sup> However, till date, there is no report of CAD as a presenting feature of HIV in Indian patients to the best of our knowledge. Age of onset of CAD is earlier in HIV-positive patients compared to non-HIV-infected patients.<sup>[5]</sup>

HIV-infected patients are vulnerable to photosensitive dermatoses compared to the normal population, reason for which is not well known, but altered immune modulation leading to ineffective handling and clearing of UV radiation (UVR)-induced neoantigens and tumor necrosis factor- $\alpha$  may be the culprit.<sup>[7]</sup> On the other hand, UVR induces activation and replication of HIV.<sup>[9]</sup> Photosensitivity in the context of HIV infection may not only be a presenting condition but can also occur secondary to concomitant treatment with HAART therapy (especially efavirenz), nonsteroidal anti-inflammatory drugs, and trimethoprim-sulfamethoxazole, which act as photosensitizers.<sup>[4]</sup>

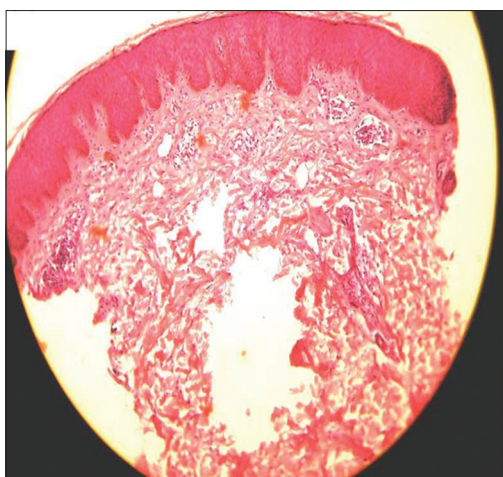
CAD pathophysiology is poorly known, but it is speculated that delayed type of hypersensitivity against UVR-induced skin photo-antigen may play role. Inflammatory infiltrates in the skin lesions of CAD mainly consist of CD8<sup>+</sup> reactive T-cells and peripheral blood of both HIV-infected and non-HIV-infected CAD patients, which show reduced CD4/8 ratio of circulating T cells. Meola *et al.* observed markedly suppressed ( $<0.2 \times 10^9/L$ ) CD4 cell count in all cases, implying photosensitivity as a late feature of HIV.<sup>[6]</sup>



**Figure 1:** Hyperpigmented papulonodular lesions with few plaques with crust and hypopigmentation at places over the extensor aspect of arms, dorsa of hands (a), similar lesions over the dorsa of both feet (b)



**Figure 2:** Hyperpigmented papulonodular lesions over the face, "V" region of the neck (a), and over the nape and upper back (b)



**Figure 3:** Histology of skin showing parakeratosis and mild spongiosis in the epidermis and perivascular lymphocytes and mononuclear cells in the dermis (H and E stain, x40)

Differential diagnoses of CAD other than photodermatoses include atopic/seborrhoeic eczema, light exacerbated air-borne contact dermatitis, cutaneous T-cell lymphoma, pruritic papular eruptions, porphyrias, lupus erythematosus, insect bites, and eosinophilic

folliculitis.<sup>[1-6]</sup> The diagnosis of CAD is confirmed by the findings of chronic photodermatitis in the absence of continued exposure to photosensitizers, abnormal MED, and histology, suggesting nonspecific photodermatoses.<sup>[6]</sup>

CAD treatment should be individualized according to the duration and extent of lesions. Rigorous sun protection using appropriate clothing, broad-brim hat, and broad-spectrum high-sun protection factor sunscreens are the basis of treatment. Topical potent steroids and tacrolimus are useful in limited disease. Short course of oral steroids can be used to control the flare. Cyclosporin, azathioprine, and mycophenolate mofetil are useful if the above treatment measures fail. HAART is the mainstay of treatment in addition to these measures if the patient is HIV positive.

## CONCLUSION

Healthy-appearing, young individuals with prolonged, treatment-refractory, and idiopathic CAD/photodermatitis should be encouraged to have HIV serotesting. It can be an early marker of HIV infection in certain, susceptible individuals.

## Declaration of patient consent

The authors certify that they have obtained all appropriate patient consent forms. In the form, the patient has given his consent for his images and other clinical information to be reported in the journal. The patient understands that his name and initials will not be published, and due efforts will be made to conceal his identity, but anonymity cannot be guaranteed.

## Financial support and sponsorship

Nil.

## Conflicts of interest

There are no conflicts of interest.

## REFERENCES

1. Pappert A, Grossman M, DeLeo V. Photosensitivity as the presenting illness in four patients with human immunodeficiency viral infection. *Arch Dermatol* 1994;130:618-23.
2. Hawk JL, Smith NP, Black MM. The photosensitivity disorders. In: Elder D, Elenitsas R, Jaworsky C, Johnson B Jr, editors. *Lever's Histopathology of the Skin*. Philadelphia: Lippincott-Raven; 1997. p. 305-10.
3. Philips RC, Motaparathi K, Krishnan B, Hsu S. HIV photodermatitis presenting with widespread vitiligo-like depigmentation. *Dermatol Online J* 2012;18:6.
4. Bilu D, Mamelak AJ, Nguyen RH, Queiroz PC, Kowalski J, Morison WL, *et al*. Clinical and epidemiologic characterization of photosensitivity in HIV-positive individuals. *Photodermatol Photoimmunol Photomed* 2004;20:175-83.
5. Wong SN, Khoo LS. Chronic actinic dermatitis as the presenting feature of HIV infection in three Chinese males. *Clin Exp Dermatol* 2003;28:265-8.

#### Case Reports

6. Meola T, Sanchez M, Lim HW, Buchness MR, Soter NA. Chronic actinic dermatitis associated with human immunodeficiency virus infection. *Br J Dermatol* 1997;137:431-6.
7. Tojo N, Yoshimura N, Yoshizawa M, Ichioka M, Chida M, Miyazato I, *et al.* Vitiligo and chronic photosensitivity in human immunodeficiency virus infection. *Jpn J Med* 1991;30:255-9.
8. Wong SN, Khoo SW. Human immunodeficiency virus infection presenting with chronic actinic dermatitis: A case report. *Ann Acad Med Singapore* 2001;30:664-7.
9. Gregory N, DeLeo VA. Clinical manifestations of photosensitivity in patients with human immunodeficiency virus infection. *Arch Dermatol* 1994;130:630-3.