

# Remission of Refractory Celiac Disease With Infliximab in a Pediatric Patient

Nidhi Rawal, MD, MPH,<sup>1</sup> William Twaddell, MD,<sup>2</sup> Alessio Fasano MD,<sup>3</sup> Samra Blanchard, MD,<sup>1</sup> and Anca Safta, MD<sup>4</sup>

<sup>1</sup>Division of Pediatric Gastroenterology, Hepatology and Nutrition, University of Maryland, Baltimore, MD

<sup>2</sup>Department of Anatomic Pathology, University of Maryland, Baltimore, MD

<sup>3</sup>Division of Pediatric Gastroenterology and Nutrition, MassGeneral Hospital for Children, Boston, MA

<sup>4</sup>Division of Pediatric Gastroenterology and Nutrition, Wake Forest Baptist Medical Center, Winston-Salem, NC

## Abstract

Refractory celiac disease (RCD) is a rare but life-threatening complication of celiac disease (CD), and only 1 pediatric case has been reported. We report a case of a 14-year-old girl with CD presenting with persistent symptoms and positive tissue celiac-specific antibodies despite a gluten-free diet. Push enteroscopy showed jejunal scalloping and partial villous atrophy on histology. She was diagnosed with RCD and treated with infliximab with subsequent complete serological and histological remission.

## Introduction

Celiac disease (CD) is an autoimmune disorder that causes intestinal inflammation in response to gluten in genetically predisposed individuals. Symptoms range from abdominal pain, bloating, and fatigue to malabsorption, diarrhea, and growth failure. Refractory celiac disease (RCD) is a rare and life-threatening complication of CD and is defined as persistence of symptoms and/or persistent villous atrophy with increased intraepithelial lymphocytes (IELs) despite adherence to a strict gluten-free diet (GFD) for more than 12 months.<sup>1,2</sup> Only 2–10% of adult patients with CD develop RCD.<sup>2</sup> Type I RCD has normal IELs and normal expression of surface CD3, CD4, CD103, with polyclonal T-cell receptor  $\gamma$ -gene rearrangement.<sup>3</sup> These IELs are indistinguishable from the infiltrate found in CD. Type II RCD is characterized by lack of surface IEL CD3, CD4, or CD8, and has a monoclonal T-cell receptor  $\gamma$ -gene rearrangement.<sup>3</sup> Type I is more likely to respond to immunosuppressive therapy and has a better 5-year survival rate, with a relatively benign course.<sup>3</sup>

## Case Report

A 14-year-old female presented with a 2-month history of intermittent abdominal pain, nausea, bloating, and diarrhea. She was diagnosed with CD, with a positive celiac serology (tissue transglutaminase [tTG] IgA 100 U/mL) and Marsh 3b duodenal histology (Figure 1). GFD resulted in mild symptomatic improvement and a drop in the tTG IgA to 11 U/mL. However, abdominal pain and poor weight gain persisted through 10 months of a strict GFD at home. Endomysial antibody titers were negative. Genetic testing was positive for HLA-DQ2 and negative for HLA-DQ8.

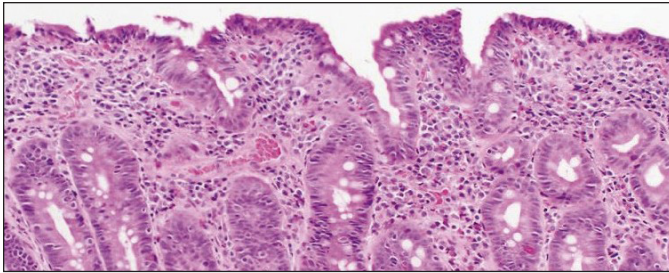
Our nutritionist performed a detailed dietary assessment, which did not reveal any gluten exposure. Under close supervision of our nutritionist, the patient tried a modified diet excluding all grains and processed foods for 3 months with no improvement. Subsequently, a diet of only elemental nutritional supplements was attempted for

ACG Case Rep J 2015;2(2):121-123. doi:10.14309/crj.2015.25. Published online: January 16, 2015.

**Correspondence:** Nidhi Rawal, MD, MPH, University of Maryland Medical Center, 22 S Greene St, Suite N5W68, Division of Pediatric Gastroenterology, Hepatology and Nutrition, Baltimore, MD 21210 (nrawal@peds.umaryland.edu).



**Copyright:** © 2015 Rawal et al. This work is licensed under a Creative Commons Attribution-NonCommercial-NoDerivatives 4.0 International License. To view a copy of this license, visit <http://creativecommons.org/licenses/by-nc-nd/4.0>.



**Figure 1.** Duodenal histology showing marked villous blunting and intraepithelial lymphocytosis.

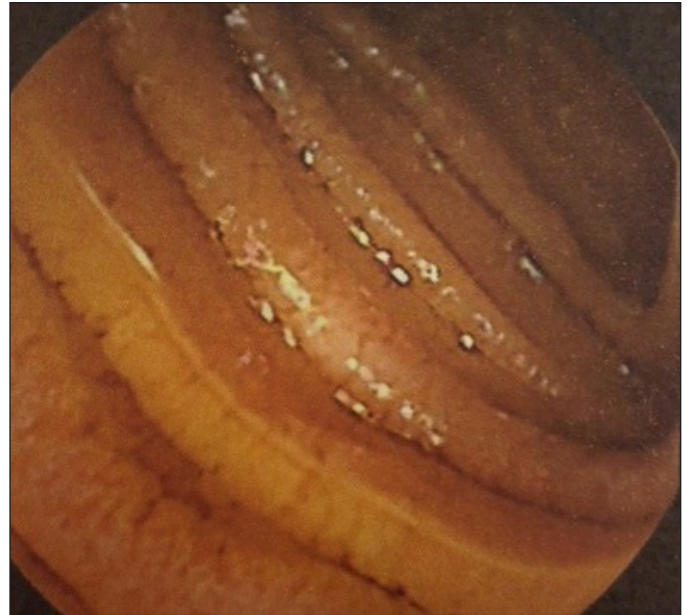4 weeks, followed by complete bowel rest with total parenteral nutrition (TPN) for 4 weeks, each with no improvement.

Repeat upper endoscopy and colonoscopy was completely normal. Tests were negative for giardiasis, tropical sprue, post-infectious enteritis, inflammatory bowel disease (including negative p-ANCA, anti-*Saccharomyces cerevisiae* antibodies, anti-OmpC, and anti-CBir serology), small intestinal bacterial overgrowth, lactase deficiency, HIV, common variable immunodeficiency, eosinophilic gastroenteritis, autoimmune enteropathy, and *Mycobacterium tuberculosis*. Video capsule endoscopy showed jejunal scalloping (Figure 2). Jejunal biopsies obtained via push enteroscopy showed active CD, Marsh 3a lesions with villous blunting and increased intraepithelial lymphocytes (50 IELs/100 enterocytes). After 20 months of GFD and persistent villous atrophy, the patient was diagnosed with RCD.

Immunostaining of the IELs showed normal CD3 and CD8-positive lymphocytes, and T-cell rearrangement (TCR) analysis showed polyclonal T-cell bands, consistent with the diagnosis of type I RCD. The patient was offered prednisone, budesonide, and azathioprine, but the patient and her family did not want corticosteroids due to the patient's high BMI (>97th percentile), severe acne, a prior diagnosis of polycystic ovarian syndrome, and a family history of hypertension. The patient was started on 5 mg/kg infliximab, and symptoms and serology improved over 8 months of treatment with normalization of mucosa on jejunal biopsy. The patient continues to be on a GFD while receiving 5 mg/kg infliximab every 8 weeks, and remains asymptomatic.

## Discussion

RCD is a rare occurrence in pediatrics, and to our knowledge, only 1 case has been reported.<sup>4</sup> The most reliable method to screen for compliance with GFD is detailed nutritional evaluation, and it is imperative to confirm strict GFD compliance for at least 12 months before considering RCD. The presence of celiac antibodies does not necessarily exclude the diagnosis of RCD, as 19–30% of patients with RCD continue to have positive celiac serology.<sup>5</sup> Not



**Figure 2.** Capsule endoscopy showing small intestinal scalloping.

all patients with ongoing gluten exposure develop celiac antibodies,<sup>6,7</sup> so serological titers are not a true reflection of gluten exposure.

Once the diagnosis of RCD is established, treatment options are limited. Prednisone and budesonide, with or without azathioprine, are used to treat type I RCD and may result in complete histological healing.<sup>6,8</sup> However, there have been case reports of complete remission of type I RCD with use of anti-tumor necrosis factor (TNF)- $\alpha$  agents,<sup>9-14</sup> and other therapeutic agents like campath,<sup>14</sup> cladribine,<sup>15</sup> and cyclosporine A.<sup>14</sup>

We report a rare occurrence of RCD in a pediatric patient, highlight the importance of a rigorous work-up before a diagnosis of RCD is considered, and show that infliximab is a potential treatment option for pediatric type I RCD. As RCD is rare and its treatment and long-term prognosis are different from CD, it is important to arrive at this diagnosis in a very careful and systematic manner.

## Disclosures

Author contributions: N. Rawal designed and drafted the manuscript, and is the article guarantor. W. Twaddell collected data and processed the histopathology specimens. A. Fasano reviewed the manuscript and advised regarding the celiac disease content. S. Blanchard designed and drafted the manuscript, and reviewed the final version of the manuscript. A. Safta initiated the case report, advised the authors, and reviewed the final version of the manuscript.

Financial disclosure: None to report.

Informed consent was obtained for this case report.

Received: July 29, 2014; Accepted: December 10, 2014

## References

1. Daum S, Cellier C, Mulder CJ. Refractory coeliac disease. *Best Pract Res Clin Gastroenterol*. 2005;19(3):413–424.
2. Trier JS, Falchuk ZM, Carey MC, Schreiber DS. Celiac sprue and refractory sprue. *Gastroenterology*. 1978;75(2):307–316.
3. Rubio-Tapia A, Kelly DG, Lahr BD, et al. Clinical staging and survival in refractory celiac disease: A single center experience. *Gastroenterology*. 2009;136(1):99–107; quiz 352–3.
4. Mubarak A, Oudshoorn JH, Kneepkens CM, et al. A child with refractory coeliac disease. *J Pediatr Gastroenterol Nutr*. 2011;53(2):216–218.
5. Rubio-Tapia A, Murray JA. Classification and management of refractory coeliac disease. *Gut*. 2010;59(4):547–557.
6. Brar P, Lee S, Lewis S, et al. Budesonide in the treatment of refractory celiac disease. *Am J Gastroenterol*. 2007;102(10):2265–2269.
7. Abdulkarim AS, Burgart LJ, See J, Murray JA. Etiology of nonresponsive celiac disease: Results of a systematic approach. *Am J Gastroenterol*. 2002;97(8):2016–2021.
8. Hamilton JD, Chambers RA, Wynn-Williams A. Role of gluten, prednisone, and azathioprine in non-responsive coeliac disease. *Lancet*. 1976;1(7971):1213–1216.
9. Turner SM, Moorghen M, Probert, CS. Refractory celiac disease: Remission with infliximab and immunomodulators. *Eur J Gastroenterol Hepatol*. 2005;17(6):667–669.
10. Chaudhary R, Ghosh S. Infliximab in refractory celiac disease. *Eur J Gastroenterol Hepatol*. 2005;17(6):603–604.
11. Gillett HR, Arnott ID, McIntyre M, et al. Successful infliximab treatment for steroid-refractory coeliac disease: A case report. *Gastroenterology*. 2002;122(3):800–805.
12. Constantino G, Della Torre A, Lo Presti MA, Caruso R, et al. Treatment of life-threatening type I refractory coeliac disease with long-term infliximab. *Dig Liver Dis*. 2008;40(1):74–77.
13. Schmidt C, Kasim E, Schlake W, et al. TNF-alpha antibody treatment in refractory collagenous sprue: A report of a case and review of the literature. *Z Gastroenterol*. 2009;47(6):575–578.
14. Malamut G, Afchain P, Verkarre V, et al. Presentation and long-term follow-up of refractory coeliac disease: Comparison of type I with type II. *Gastroenterology*. 2009;136(1):81–90.
15. Al-Toma A, Goerres MS, Meijer JW, et al. Cladribine therapy in refractory celiac disease with aberrant T cells. *Clin Gastroenterol Hepatol*. 2006;4(11):1322–1327.

## Publish your work in ACG Case Reports Journal

ACG Case Reports Journal is a peer-reviewed, open-access publication that provides GI fellows, private practice clinicians, and other members of the health care team an opportunity to share interesting case reports with their peers and with leaders in the field. Visit <http://acgcasereports.gi.org> for submission guidelines. Submit your manuscript online at <http://mc.manuscriptcentral.com/acgcr>.