

Civilian Penetrating Gunshot Injury to the Neurocranium in Enugu

Ephraim Eziechina Onyia, Mark C Chikani, Wilfred C Mezeu, Enoch O Uche, Izuchukwu Iloabachie, Matthew Mesi, Sunday Ejembi¹, Chuka Agunwa²

Department of Surgery, Neurosurgery Unit, University of Nigeria Teaching Hospital, ²Department of Community Medicine, University of Nigeria Teaching Hospital, Ituku/Ozalla, ¹Department of Surgery, Memfys Hospital for Neurosurgery, Enugu State, Nigeria

ABSTRACT

Introduction: Civilian penetrating gunshot injuries to the neurocranium are no longer uncommon in Nigeria. Such injuries are however poorly reported. They are associated with poor outcome and, at close range, are frequently fatal, especially when inflicted by high-velocity weapons. Prompt transfer to neurosurgical service and urgent intervention may improve outcome in those that are not mortally wounded. **Materials and Methods:** Fifty-two patients with civilian penetrating gunshot wounds seen over a 10-year period (2004–2014) at the University of Nigeria Teaching Hospital and Memfys Hospital for Neurosurgery Enugu were reviewed retrospectively, and their data were analyzed to evaluate factors that impacted on outcome. Only patients with clinical and imaging evidence of cranial gunshot injuries who reached hospital alive were included in the study. The overall mortality and Glasgow outcome score were analyzed. **Results:** Fifty-two patients with isolated civilian penetrating gunshot wounds were identified (M:F = 7.7:1); mean (standard deviation) age was 32.8 (11.9) years. There was a high correlation (0.983) between the sex of the patients and the outcome. The overall mortality was 30.8%, whereas the mortality for patients with postresuscitation Glasgow coma scale (GCS) score ≤ 8 was 57%, as against 12.9% in those in whom postresuscitation GCS was >8 ; meaning that 87.1% of patients in whom postresuscitation GCS was >8 survived. Thirty-one patients (59.6%) had papillary abnormalities. Majority of patients with monohemispheric lesions survived while all those with diencephalic, transventricular, and posterior fossa involvement had 100% mortality. **Conclusions:** Admitting GCS and bullet trajectory were predictive of outcome.

KEYWORDS: Glasgow coma score, Glasgow outcome score, Penetrating gunshot injury

INTRODUCTION

There has been a disturbing change in the trend of civilian penetrating gunshot injuries to the neurocranium in Nigeria in tune with global rise in incidents of gunshot injuries.^[1,2] Injuries result from crushing and stretching of tissues with the nature of the wound, thereof determined by both missile and tissue characteristics.^[3] Traditionally, the types of wounds have been described as resulting from high-velocity (>2000 feet/s, or 615 m/s) or low-velocity (<2000 feet/s) missiles, with cavitation phenomenon apparent when velocity exceeds 1000 feet/s (305 m/s).^[4] These injuries are often lethal with high early mortality that leaves

no room for possible neurosurgical intervention.^[5] The reported civilian mortality rates from gunshot wounds to the head (GSHW) in the literature range from 23% to 92%, with those series on the lower end including a number of cases without dural violation.^[6] Gressot *et al.* reported 19% favorable outcome defined as a 6-month Glasgow outcome scale (GOS) score of moderate disability or good recovery and 29% poor outcome GOS of persistent vegetative state or severe disability.^[1]

Address for correspondence: Dr. Ephraim Eziechina Onyia, Department of Surgery, Neurosurgery Unit, University of Nigeria Teaching Hospital, Ituku/Ozalla, Enugu State, Nigeria. E-mail: ephraim_onyia@yahoo.co.uk

This is an open access article distributed under the terms of the Creative Commons Attribution-NonCommercial-ShareAlike 3.0 License, which allows others to remix, tweak, and build upon the work non-commercially, as long as the author is credited and the new creations are licensed under the identical terms.

For reprints contact: reprints@medknow.com

How to cite this article: Onyia EE, Chikani MC, Mezeu WC, Uche EO, Iloabachie I, Mesi M, *et al.* Civilian penetrating gunshot injury to the neurocranium in Enugu. Niger J Surg 2017;23:47-52.

Access this article online	
Quick Response Code: 	Website: www.nigerianjsurg.com
	DOI: 10.4103/1117-6806.205751

There appears to be a rising incidence of gunshot injuries in Nigeria. Increased civil unrest, political thuggery, armed robbery, police brutality, proliferation of arms among others have been proposed as possible reasons for the rising incidence in the Nigerian setting.^[7] At the moment, there is a paucity of published data on civilian penetrating gunshot injury to the neurocranium in Nigeria. It then became imperative that the patterns and outcomes of management of this emerging cause of significant morbidity and mortality are studied.

Experience in the military setting have been well documented, but civilian pattern is believed to differ as most result from low missile injuries.^[8]

MATERIALS AND METHODS

The available literature on gunshot injuries in Nigeria was reviewed from a search of PubMed and African Index Medicus and compared with data from recent records of care for these patients in the University of Nigeria Teaching Hospital and Memfys Hospital for Neurosurgery Enugu between January 2004 and June 2014. Patients’ case notes, operation notes, and radiology records were retrieved and relevant clinical and radiological data were extracted. Only patients who had clinical and radiologic evidence of isolated civilian penetrating injuries to the neurocranium who reached hospital alive were included in the study. Those with perforating gunshot injuries to the neurocranium were excluded as are those with GSWH but without evidence of calvarial breach. Furthermore, those with additional gunshot injuries to other body regions and stab wounds were excluded. All patients had brain computerized tomography scan. None had magnetic resonance imaging. Retrieved data were analyzed using Statistical Package for the Social Sciences (SPSS) version 20.0 and test of statistical significance done. The primary outcome measure was the GOS.

RESULTS

A total of 52 patients met the inclusion criteria and were managed over the period under review (88.5% were males and 11.5% were females). The male to female

ratio was 7.7:1. The mean age was 32.8 (±11.9) years. Majority of the patients were in third and fourth decades of life [Figure 1 and Table 1].

Table 1: Clinicodemographic profile of civilian penetrating gunshot neurocranial injuries

Variable	Frequency (%)
Sex	
Male	46 (88.5)
Female	6 (11.5)
Marital status	
Single	31 (59.6)
Married	21 (40.4)
Missile ballistics	
Low velocity	36 (69.2)
High velocity	16 (30.8)
Admission GCS	
3-8	21 (40.4)
9-12	16 (30.8)
13-15	15 (28.8)
Posttraumatic seizure	
Present	34 (65.4)
Absent	18 (34.6)
Pupillary abnormality	
Present	31 (59.6)
Absent	21 (40.4)

GCS: Glasgow coma scale

Table 2: Cranial computed tomography findings

Findings	Frequency (%)
Brain edema	43 (86.3)
Subarachnoid hemorrhage	29 (55.8)
Intraventricular hemorrhage	21 (40.4)
Pneumocephalus	47 (90.4)
Posterior fossa involvement	3 (5.8)
Single hemisphere involvement	26 (50)
Bi-hemispheric involvement	17 (32.4)
Intracranial pellets	52 (100)

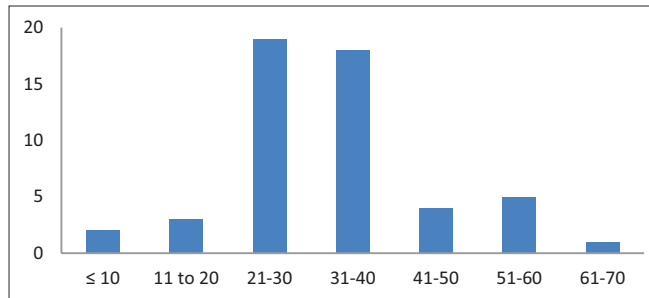


Figure 1: Age distribution of patients

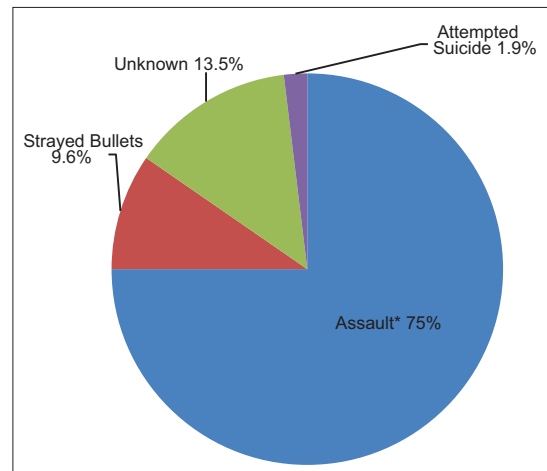


Figure 2: Etiology of penetrating gunshot injury to neurocranium (*Armed robbery, cultists, terrorism)

Table 3: Determinants of outcome after civilian penetrating gunshot injury to the neurocranium

	Frequency (%)	GOS 1	GOS 2	GOS 3	GOS 4	GOS 5	χ^2	P
Age								
1-10	2 (3.8)	0	0	1	1	0	25.908	0.358
11-20	3 (5.8)	1	1	0	1	0		
21-30	19 (36.5)	4	3	5	3	4		
31-40	18 (34.6)	5	1	2	6	4		
41-50	4 (7.7)	2	0	0	2	0		
51-60	5 (9.6)	3	1	0	1	0		
61-70	1 (1.9)	1	0	0	0	0		
Total	52 (100)	16	6	8	14	8		
Sex								
Male	46 (88.5)	14	6	7	11	8	3.189	0.527
Female	6 (11.5)	2	0	1	3	0		
Total	52 (100)	16	6	8	14	8		
Missile trajectory								
Bihemispheric	17 (32.7)	7	2	5	3	0	8.363	0.399
Monohemispheric	26 (50.0)	2	3	3	10	8		
Transventricular	2 (3.8)	2	0	0	0	0		
Diencephalic	1 (1.9)	1	0	0	0	0		
Posterior fossa	3 (5.8)	3	0	0	0	0		
Subdural	3 (5.8)	1	1	0	1	0		
Total	52 (100.0)	16	6	8	14	8		
Treatment modality								
Craniotomy	30 (57.7)	7	3	6	10	4	21.065	0.049
Craniectomy	3 (5.8)	0	1	0	1	1		
Debridement	29 (55.8)	6	6	8	7	1		
Conservative	22 (42.3)	8	3	4	4	3		
Intervention interval								
<24 h	17 (32.7)	3	2	3	5	4	8.363	0.399
24-48 h	10 (19.2)	3	1	1	3	2		
>48 h	3 (5.8)	1	0	1	1	0		
None	22 (42.3)	9	3	3	5	2		
Total	52 (100.0)	16	6	8	14	8		
Seizure type								
None	18 (34.6)	2	4	3	7	2	21.065	0.049
Immediate	4 (7.7)	2	0	0	2	0		
Early	22 (42.3)	10	0	3	4	5		
Late	8 (15.4)	2	2	2	1	1		
Total	52 (100.0)	16	6	8	14	8		
Ballistics								
Low velocity	36 (69.2)	6	2	7	13	8	1.588	0.811
High velocity	16 (30.8)	10	4	1	1	0		
Total	52 (100.0)	16	6	8	14	8		
GCS at presentation								
3-8	21 (40.4)	12	2	2	4	1	1.588	0.811
>8	31 (59.6)	4	4	6	10	7		
Total	52 (100.0)	16	6	8	14	8		

GOS: Glasgow outcome scale, GCS: Glasgow coma scale

More patients had severe forms of injury with 40.4% having postresuscitation Glasgow Coma Scale (GCS) of ≤ 8 . GCS was 9–12 in 30.8% and 13–15 in 28.8%. Pupillary abnormalities were found in 31 patients (59.6%).

All patients had cranial computerized tomography (CT) findings of intracranial pellets (100%), followed by pneumocephalus (90.4%), brain edema (86.3%), and subarachnoid hemorrhages (55.8%) [Table 2].

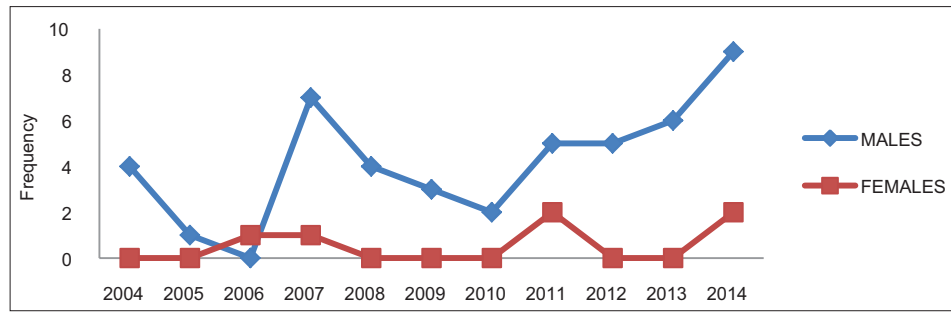


Figure 3: Number of patients seen per year

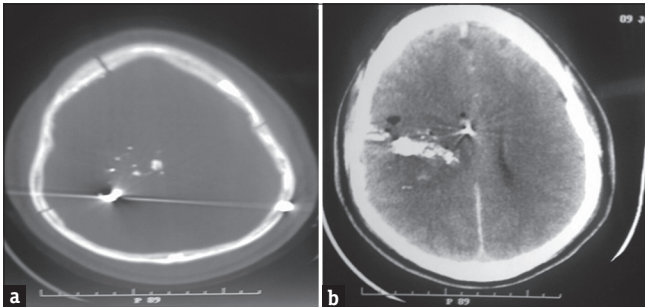


Figure 4: (a) Cranial computerized tomography scan (bone window) showing intracranial pellets. (b) Cranial computerized tomography scan (brain window) showing bullet trajectory

In 13.5% of cases, the circumstances surrounding the gunshot injuries could not be verified [Figure 2]. Seventeen patients (32.4%) presented within 24 h of the injury. Ten patients (19.2%) presented within 24–48 h, and 3 (5.8%) presented after 48 h. Thirty patients (57.7%) had a form of surgical intervention as part of their management protocol. The remaining 22 patients (42.3%) were managed conservatively [Table 3].

DISCUSSION

Penetrating gunshot injury, the most lethal of all firearm injuries is an emerging leading cause of death among Nigerians. It has been reported to account for 7.2% of gunshots in North-Central Nigeria.^[9] We found a male preponderance, most of whom are in the third and fourth decades of life consistent with other findings within and outside Nigeria.^[7,9,10] This depicts the potential catastrophic sequel of these injuries as patients are in the productive age group with far-reaching consequences to their families and the nation at large.

Majority of the injuries (75%) resulted from assault involving activities such as armed robbery attack, cultic rivalry, communal clashes, and terror raids. Strayed bullets were the cause in 9.6% and attempted suicide in 1.9%. The three most common causes of gunshot injuries in an earlier review in the same region as ours (Umuahia) were armed robbery (31.6%),

kidnapping (21.3%), and police brutality (17.9%).^[11] Armed robbery attack has been reported as the most common etiology in Abeokuta and Sokoto, Southwest and Northwestern Nigeria, respectively.^[7,12] It is however worth noting that while suicidal tendencies are commonly reported in the Western world, the pattern in Nigeria is a deviation from that.

We noticed a sharp rise in incidence with peaks in 2003 and 2014 [Figure 3], coinciding with election or preelection periods. Similar findings have earlier been documented.^[7] The reason for this may not be unrelated to the violence which characterized elections in this part of the world. A focused study on this may further elucidate this trend.

Only 19.2% of the study population presented to the definitive caregivers within 24 h of the injury (80.8% presented later than 24 h), and 32.7% had definitive intervention within 24 h of presentation to our care. This late presentation may account for some of the recorded mortality. As with other forms of gunshot injuries, this gap in emergency response services has been noted in other studies.^[13] Aggressive management with blood products and hyperosmolar therapy was independently associated with survival.^[14] This stresses the need for initiation of resuscitative measures early.

It was noteworthy that none of the patients opted for discharge against medical advice. The probably perceived danger when the neurocranium is involved precluded patronage of nonorthodox care commonly observed in the country with no patients leaving against medical advice as often seen in gunshot to other body parts.^[15,16]

The overall mortality in our study was 30.8%. This is consistent with findings by Tsuei *et al.*, who documented overall mortality of 31.3%.^[17] However, for the subset of patients with postresuscitation GCS ≤ 8 , the mortality was as high as 57% as against 12.9% in those, in whom postresuscitation GCS was >8 . The implication was that 87.1% of patients, in whom postresuscitation GCS was >8 survived. It can then be

inferred that the odds favored survival the higher the postresuscitation GCS. As a corollary, mortality has an inverse relationship with postresuscitation GCS. Our study did not include mortality at the scene due to nonavailability of data, but Wintemute *et al.* reported 27.7% mortality at the scene of the shooting and 84.6% on the day of the shooting for strayed bullets, representing a higher case fatality ratio compared to other forms of gunshot wounds.^[18]

A significant association ($\chi^2 = 20.475$, $P = 0.009$) was observed between the seizure type ($P = 0.049$) and patient treatment outcome.

We noted that majority of the patients who suffered high-velocity penetrating gunshot injuries succumbed (10 out of 16 patients) or were left in persistent vegetative state (4 out of 16 patients), with none having a good outcome (GOS 5). Conversely, a good number (8 out of 36) who sustained low-velocity injuries were able to make complete recovery (GOS 5).

With respect to missile trajectory, majority of the patients with monohemispheric lesions survived whereas majority of those with bihemispheric lesions died. Similarly, all the patients with diencephalic, transventricular, and posterior fossa trajectory had 100% mortality. Similar findings have been reported in the literature to be associated with poor outcome.^[10,17,19] Figure 4a and 4b is a Cranial computerized tomography scan showing intracranial pellets and bullet trajectory of a typical patient with penetrating gunshot injury to the neurocranium.

In terms of treatment protocol, majority of the patients who had craniotomy survived with complete recovery, mild disability, or severe disability, as opposed to the conservatively managed group in whom majority died, remained in vegetative state or with severe disability. It follows from the foregoing and has been noted in some studies that aggressive institution of appropriate surgical measures should be considered in patients with postresuscitation GCS >8 as it has been associated with spectacular recoveries.^[5,20]

CONCLUSIONS

Civilian penetrating gunshot injury to the neurocranium is on the rise with majority of the victims being males in their peak productive age. Deliberate injuries are the predominant etiology. Most patients still have pellets in the cranium at presentation and majority will require a form of surgical intervention. Mortality is relatively high compared to other forms of gunshot injuries with significant neurological sequel. Outcome is greatly influenced by postresuscitation GCS, anatomical trajectory on brain CT scan, seizures, and interventions.

Appropriate neurosurgical care is critical and should be made available nationwide in the wake of increased gunshot injuries in Nigeria.

There is a need to find out the mortality among those who have died at scene to have a holistic grasp of the burden of this condition.

Financial support and sponsorship

Nil.

Conflicts of interest

There are no conflicts of interest.

REFERENCES

- Gressot LV, Chamoun RB, Patel AJ, Valadka AB, Suki D, Robertson CS, *et al.* Predictors of outcome in civilians with gunshot wounds to the head upon presentation. *J Neurosurg* 2014;121:645-52.
- Okie S. Traumatic brain injury in the war zone. *N Engl J Med* 2005;352:2043-7.
- Hollerman JJ, Fackler ML, Coldwell DM, Ben-Menachem Y. Gunshot wounds: 1. Bullets, ballistics, and mechanisms of injury. *AJR Am J Roentgenol* 1990;155:685-90.
- Miclau T, Farjo LA. The antibiotic treatment of gunshot wounds. *Injury* 1997;28:1-5.
- Siccardi D, Cavaliere R, Pau A, Lubinu F, Turtas S, Viale GL. Penetrating craniocerebral missile injuries in civilians: A retrospective analysis of 314 cases. *Surg Neurol* 1991;35:455-60.
- Cirivello M, Bell RS, Armonda RA. Penetrating brain injury. In: Ellenbogen RG, Abdulrauf SI, editors. *Principles of Neurological Surgery*. 3rd ed. Philadelphia: Elsevier Saunders; 2012. p. 349-62.
- Aigoro N, Abbas G. Epidemiology of gunshot injuries in Abeokuta, Southwest Nigeria. *Internet J Orthop Surg* 2013;20:1-4.
- Alvis-Miranda HR, Rubiano MA, Agrawal A, Rojas A, Moscote-Salazar LR, Satyarthee GD, *et al.* Craniocerebral gunshot injuries; a review of the current literature. *Bull Emerg Trauma* 2016;4:65-74.
- Elachi IC, Yongu WT, Nahachi C, Odatuwa-Omagbemi DO, Mue DD. The pattern of civilian gunshot injuries at a university hospital in North Central Nigeria. *IOSR Journal of Dental and Medical Sciences* 2015;14:87-90.
- Semple PL, Domingo Z. Craniocerebral gunshot injuries in South Africa – A suggested management strategy. *S Afr Med J* 2001;91:141-5.
- Iloh PG, Chuku A, Ofoedu JN, Ugwele OH, Onyekwere JO, Amadi AN. The emerging trend in the epidemiology of gunshot injuries in the emergency department of a Nigerian tertiary hospital in a State without formal prehospital emergency medical services. *Ann Trop Med Public Health* 2013;6:435-40.
- Oboirien M, Agbo SP, Adedeji BK. Civilian gunshot injuries: Experience from Sokoto, North-West, Nigeria. *J Trauma Treat* 2016;5:285.
- Mohammed AZ, Edino ST, Ochicha O, Umar AB. Epidemiology of gunshot injuries in Kano, Nigeria. *Niger J Surg Res* 2006;7:296-9.
- Joseph B, Aziz H, Pandit V, Kulvatunyou N, O'Keeffe T, Wynne J, *et al.* Improving survival rates after civilian gunshot wounds to the brain. *J Am Coll Surg* 2014;218:58-65.
- Abbas AD, Bakari AA, Abba AM. Epidemiology of armed robbery-related gunshot injuries in Maiduguri, Nigeria. *Niger J*

- Clin Pract 2012;15:19-22.
16. Osime OC, Elusoji SO. Outcome of management of gunshot injuries by Nigerian traditional doctors. *Pak J Med Sci* 2006;22:316-9.
 17. Tsuei YS, Sun MH, Lee HD, Chiang MZ, Leu CH, Cheng WY, *et al.* Civilian gunshot wounds to the brain. *J Chin Med Assoc* 2005;68:126-30.
 18. Wintemute GJ, Claire BE, McHenry V, Wright MA. Epidemiology and clinical aspects of stray bullet shootings in the United States. *J Trauma Acute Care Surg* 2012;73:215-23.
 19. Andrade AF, Paiva WS, Luiz R, De Amorim DO, Brock RS. Management of gunshot injuries to the head and brain. *Rev Chil Neurocir* 2010;34:39-45.
 20. Martins RS, Siqueira MG, Santos MT, Zanon-Collange N, Moraes OJ. Prognostic factors and treatment of penetrating gunshot wounds to the head. *Surg Neurol* 2003;60:98-104.