

Review Article

Nursing review section of surgical neurology international: Evaluation of cervical disc disease and when surgery is warranted

Nancy E. Epstein, Renee D. Hollingsworth

Neurosurgical Spine/Education, Department of NeuroScience, NYU Winthrop Hospital, Mineola, New York, USA

E-mail: *Nancy E. Epstein - nancy.epsteinmd@gmail.com; Renee D. Hollingsworth - RHollingsworth@nyuwinthrop.org

*Corresponding author

Received: 16 May 17 Accepted: 16 May 17 Published: 07 July 17

Abstract

Background: Patients with cervical disc disease may present with radiculopathy (root compression), myelopathy (cord compression), or myeloradiculopathy. These complaints must be correlated with x-ray, magnetic resonance (MR) imaging, and computed tomographic (CT) scans. Although most patients can be managed nonsurgically, those with significant neurological deficits and larger disc herniations may require surgery.

Methods: The symptoms of cervical radiculopathy include pain radiating down one or both arms, while myelopathy may result in more diffuse numbness tingling or weakness in the upper and/or lower extremities. The neurological signs for cervical discs include; focal or diffuse loss of motor strength changes in reflexes (hyporeflexic, normal reflexes, or hyperreflexia), a loss of sensation (e.g., to pin, vibration, touch, and position), and cerebellar dysfunction (e.g., loss of coordination). Patients' symptoms and signs must correlate with focal nerve root and/or spinal cord compression seen on MR and/or CT studies.

Results: MR examinations best document soft disc herniations, while CT scans most readily demonstrate calcification/ossification of cervical discs and accompanying arthritic changes. Bulging/protruding can typically be managed nonsurgically. Alternatively, significantly extruded or sequestered discs, resulting in moderate/marked spinal cord and/or nerve root compression may warrant surgery. Most operations from front of the neck for cervical discs are called anterior cervical discectomy/fusion (ACDF), while those performed from the back of the neck are called laminoforaminotomies.

Conclusion: Patients with cervical radiculopathy (root compression) and/or myelopathy (cord compression) with disc herniations on MR/CT studies may or may not require surgery.

Key Words: Anterior cervical discectomy/fusion, cervical discs, extruded, laminoforaminotomy, myelopathy, nonsurgical, radiculopathy, sequestered, surgical

Access this article online

Website:www.surgicalneurologyint.com**DOI:**

10.4103/sni.sni_182_17

Quick Response Code:

This is an open access article distributed under the terms of the Creative Commons Attribution-NonCommercial-ShareAlike 3.0 License, which allows others to remix, tweak, and build upon the work non-commercially, as long as the author is credited and the new creations are licensed under the identical terms.

For reprints contact: reprints@medknow.com

How to cite this article: Epstein NE, Hollingsworth RD. Nursing review section of surgical neurology international: Evaluation of cervical disc disease and when surgery is warranted. *Surg Neurol Int* 2017;8:136.

<http://surgicalneurologyint.com/Nursing-review-section-of-surgical-neurology-international:-Evaluation-of-cervical-disc-disease-and-when-surgery-is-warranted/>

INTRODUCTION

Evaluation of patients for cervical disc disease starts with assessment of neurological symptoms (complaints) and signs (examination/neurological deficits). These findings are then closely correlated with radiographic pathology, documented utilizing a combination of X-rays [anteroposterior (AP), lateral, flexion, and extension], magnetic resonance (MR) images, and computed tomographic (CT) scans [Figures 1-9].

The majority of patients, who have just minimal bulging/protruding discs on MR and/or CT studies without significant spinal cord or nerve root, may be managed without surgery. Nevertheless, too many of these patients are presently offered and too many are undergoing “unnecessary” surgery. Alternatively, surgery is appropriate for patients with severe focal neurological deficits (root and/or cord compression) and MR and/or CT studies documenting large extruded/sequestered soft or calcified discs resulting in “significant” spinal cord and/or nerve root compression.

ANATOMY OF THE CERVICAL SPINE

Bony anatomy of seven cervical vertebral bodies

In the cervical spine, there are seven vertebrae anteriorly (in the front), a central canal (e.g., where the spinal cord is located with the facet joints on each side), and the posterior elements (e.g., the laminae and spinous processes). At the C1 level, there is just an arch. Here, the odontoid process from C2 extends cephalad and is “lashed” in the front (anteriorly with ligaments) to the C1 arch.

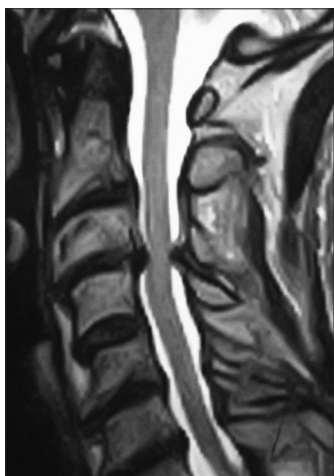


Figure 1: This is a sagittal (lateral or side view) T2-weighted cervical magnetic resonance (MR) scan (note the spinal fluid is hyperintense or white). There is an anterior central disc herniation at the C3-C4 level (in the front) accompanied by posterolateral laminar shingling (the C4 lamina is pushed under the lamina of C3) plus ossification of the yellow ligament

Cervical cord and nerve roots

The spinal cord extends from the base of the brain through the cervical spinal canal to the thoracic spine below. Exiting from either side are the cervical nerve roots: C1-C8. The C1 root exits above the C1 arch, while the remaining roots exit inferior to the designated levels; e.g., at the C5-C6 level, the C6 root exits the canal.

Cervical discs

Discs are like shock absorbers facilitating flexibility/cushioning between the vertebral bodies. There is no disc at the C1-C2 level; but rather, they are located between the C2-C3 down through C7-T1 levels. The disc itself is comprised of an outer annulus fibrosus (firm capsule), while the center contains the nucleus pulposus (more hydrated in younger patients, more desiccated in older patients). Between the discs and the vertebral bodies themselves are the cartilaginous end plates.

Yellow ligament

In the back of the cervical spine, on each side (not in the middle), the yellow ligament (ligamentum flavum) attaches to the mid portion of the lamina above and extends to the leading edge of the lamina below. Arthritic changes of this ligament (calcification/ossification) may contribute to significant spinal stenosis/cord compression/myelopathy.

Vertebral arteries of the cervical spine

In the cervical spine, the vertebral arteries travel through the foramen transversaria and exit at C2 crossing over through the ponticulus posticus. During anterior cervical and posterior cervical surgery, the vertebral arteries may be directly injured. Furthermore, with posterior surgery, lateral mass and pedicle screws may directly compromise the vertebral foramina, resulting potentially in vertebral artery perforation, brain stem infarction, and death.

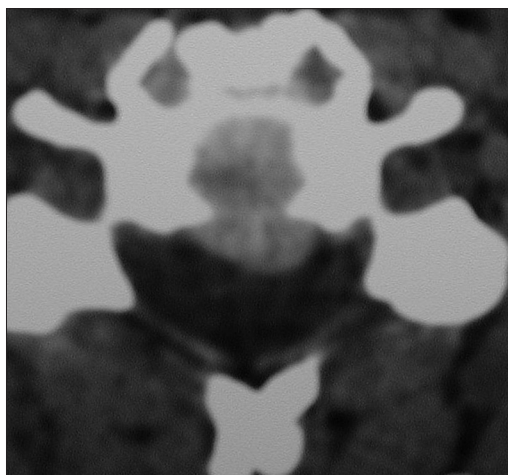


Figure 2: This axial noncontrast computed tomography (CT) soft tissue window shows a central soft disc (not calcified) compressing the anterior (ventral or front of) spinal cord

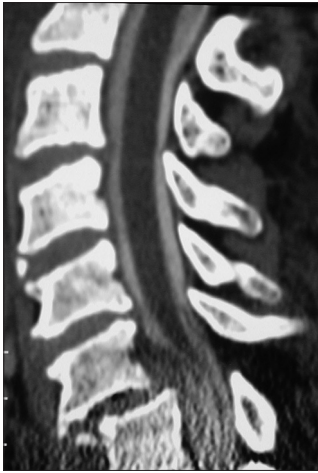

Figure 3: This midline sagittal 2D myelogram-computed tomography (CT) study documents C6/C7 fracture/dislocation, subluxation (resulting in slippage to the front/anteriorly), and massive central disc herniation compressing the ventral spinal cord

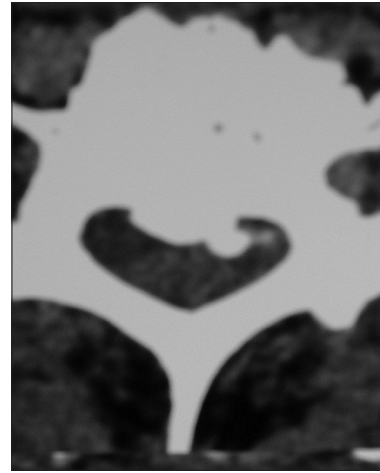


Figure 4: This axial computed tomography (CT) obtained at the mid pedicle level documents ventral/anterior calcification/ossification. This is often misinterpreted as a calcified disc, but is in fact ossification of the posterior longitudinal ligament



Figure 5: This patient underwent a two-level anterior cervical discectomy and fusion utilizing a dynamic ABC plate (Aesculap, Tuttlingen, Germany). This was performed for anterior cervical disc herniations at the C4-C5 and C6-C7 levels. The intervening level did not have to be fused as the patient had a prior multilevel posterior fusion

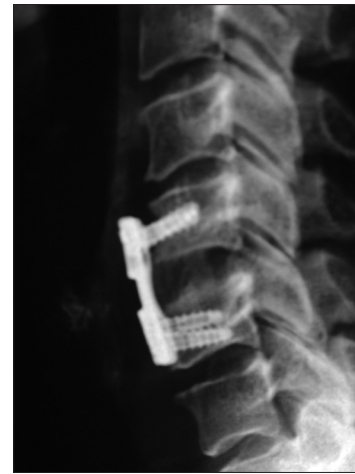

Figure 6: On this lateral x-ray (taken from the side), a one-level anterior cervical discectomy and fusion (ACDF) was performed using iliac crest autograft and a dynamic ABC plate. Note the graft between the vertebrae can be visualized, but the subsequent CT [Figure 8] better documents fusion at the graft/vertebral body interface (no lucency and bony trabeculation across the graft/vertebral junction)

Neurological symptoms of cervical discs

The most common complaints for cervical disc disease include neck pain, focal burning/numbness, tingling, or weakness in the arms or hands. Patients with radiculopathy have compression of a single or multiple nerve roots. Those with myelopathy, defined as cord compression, may experience these symptoms involving entire extremities (arms/hands/legs); rarely do they develop sphincter (bowel/bladder) dysfunction.

Gait evaluation

Pathological changes to the patient's gait may reflect different diseases in addition to cord compression. For example, a wide based gait and loss of balance may be seen with cervical myelopathy (e.g., large disc herniations/calcified discs with stenosis). Other changes in gait may

be attributed to peripheral neuropathy (e.g., due to diabetes, B12 deficiency (combined systems disease), or even Parkinson's disease (e.g., magnetic-shuffling gait).

NEUROLOGICAL SIGNS

Motor deficits in the upper extremities with radiculopathy/myelopathy

When discussing motor weakness, it is defined from 0 (no motor function) to 5 (normal function) [Table 1]. The motor exam has to be evaluated in every nerve root distribution (see below). The distributions for motor weakness in the upper extremities typically include; deltoid (C5), biceps (C5/C6), extensor of the wrist (C6),

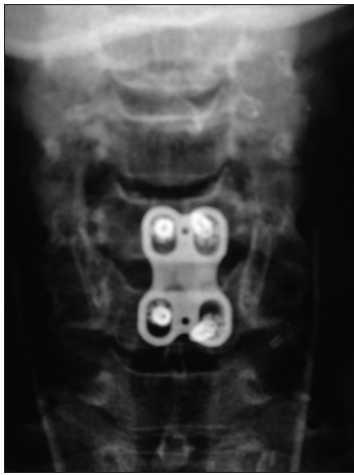

Figure 7: On this anteroposterior (AP) X-ray (taken from the front), you can see the anterior ABC plate (spanning two vertebral bodies) with the vertebral screws placed within the mid aspect of the vertebrae

apposition thumb/index finger (C6), apposition thumb/pinky (C6/C7), extensor of the phalanges (C7), triceps (C7), and intrinsic (C8).

Motor deficits in the lower extremities with cervical myelopathy

If patients have significant spinal cord compression/myelopathy, they may also demonstrate increased weakness involving the lower extremities; iliopsoas (elevator of the hip), quadriceps (straightening out the knee), extensor hallucis longus/dorsiflexors (holding the foot up in extension), or plantar flexor weakness (pushing the foot down).

Reflex deficits in the upper extremities with radiculopathy and myelopathy

The reflexes in the upper and lower extremities are graded 0–4 [Table 2]. Grade 0 indicates no function, while grade 4 is sustained ankle clonus/hyperactivity (e.g., multiple continuous beats). The reflexes evaluated in the upper extremities include; biceps (C5/C6), brachioradialis (C6/C7), and triceps (C7).

Reflex deficits in the lower extremities with radiculopathy and myelopathy

Hyperactive reflexes in the lower extremities may also reflect compression of the spinal cord. These include evaluation of the patellar (knee reflex) and Achilles responses (ankle reflex) (e.g., with myelopathy these may be increased to the 3-4+ to 5 levels) along with assessment of Babinski signs (stimulate the bottom of the foot and the toes go up/extensor) [Table 2].

SENSORY EXAMINATION

Pin appreciation and light touch (anterolateral spinothalamic tract)

Deficits to pin appreciation indicate compression of the anterior spinothalamic tract located in the front/

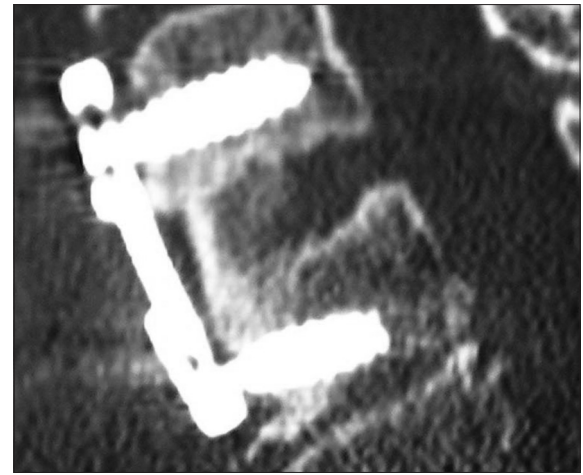


Figure 8: This lateral (side view) two dimensional computed tomography (CT) study best documents fusion across the graft/vertebral body junctions both superiorly (above) and inferiorly (below). Fusion is confirmed by the absence of lucency (no dark line), and the presence of bony trabeculation spanning the graft/body interfaces. Also observe how well you can see the graft, screws, and plate

Table 1: Motor, reflex, sensory deficits in the cervical spine

Motor Deficit	Motion
0	No motion
1	Minimal contraction
2	Motion when gravity is removed
3	Motion against gravity
4	Motion with resistance
5	Full strength

Table 2: Grading of reflex changes

Grade	Description
0	Absent
1	Hyporeflexia (decreased)
2	Normal reflexes
3	Mildly hyperactive
4	Clonus

sides of the spinal cord (anterolaterally). The sensory examination is performed using a pin (new one per patient) to determine whether the patient can feel a pinprick and light touch in the different cervical nerve root distributions. The major sensory deficits to pin appreciation are found in the following distributions. For C5 there is a loss of pin appreciation in a silver dollar over the upper arm. A C6 deficit to pin extends down the arm over the thumb and index finger, a C7 deficit involves mostly the third digit (often with some of the index finger mixed in). C8 root deficits involve the lateral aspect of the 4th digit and 5th digit. One must differentiate loss of pin appreciation in the hands from carpal tunnel (median nerve) or cubital tunnel (ulnar nerve) syndromes.

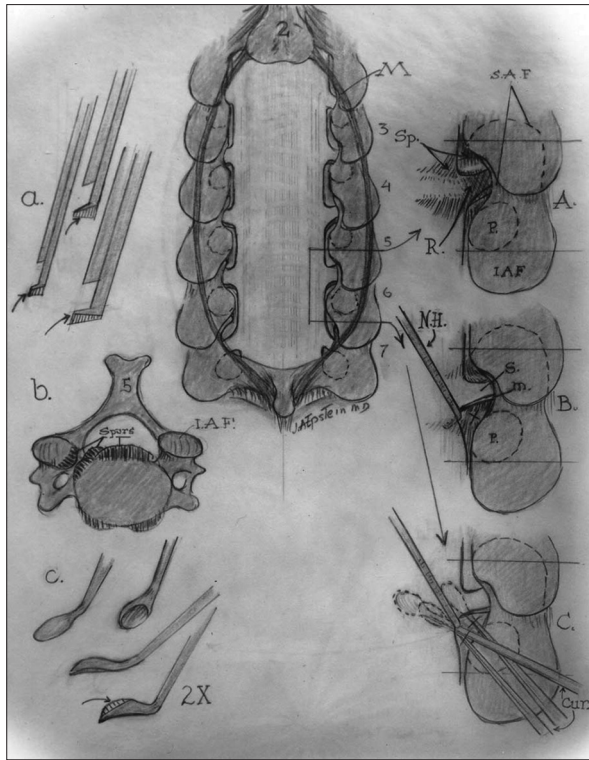


Figure 9: This illustration (Joseph A. Epstein MD, Copyright Nancy E. Epstein MD) demonstrates posterior cervical surgery, including a laminectomy and laminotomy. In Figure 9a you have a shaved-down Kerrison rongeur. In Figure 9b you have a across section of the cervical vertebral body. In Figure 9c these are down-biting curettes used to remove posterolateral discs [shown in images A-C]

Vibration and position appreciation (posterior columns)

The posterior columns, located at the back of the spinal cord in the center, control vibration and position appreciation. Vibration is tested with a tuning fork placed over the bony prominences of the hands, knees, and ankles. Position testing involves elevation/lowering of the fingers/wrists and toes/ankles. Patients with severe cervical myelopathy (cord compression) may demonstrate a loss of vibration/position appreciation in the upper compared with the lower extremities.

Cerebellar examination

Patients with cervical disease and myelopathy may have “balance” problems.

Finger-Nose-Finger: The cerebellar exam includes assessment of the ability to put your finger to your nose-then touch the examiner’s finger-and touch your nose again.

Heel to Shin: You ask the patient to run down with one ankle over the shin on the opposite side; if there is a lot of tremor/flailing, etc. this indicates dysfunction.

Tandem Gait Testing: This is tested by asking patients to walk on an imaginary line heel to toe to heel to toe. If they veer to one side or the other, or are off-balance, you have your answer.

SYMPTOMS AND SIGNS FOR SURGICAL CERVICAL DISCS

C5 nerve root deficits arising from pathology at the C4-C5 level

If a patient has unilateral (off to one side) compression of a C5 nerve root, they may exhibit weakness upon elevating the shoulder (deltoid deficit), a loss/diminution of the biceps reflex, and sensory loss of pin appreciation in the C5 distribution (silver dollar over the upper shoulder). If there is bilateral nerve root compression the deficit may be present on both sides. In the presence of marked cord compression, you may have both the C5 root deficits and cord findings.

C6 root deficits arising from pathology at the C5-C6 level

In a patient with unilateral C6 root compromise, the patient’s motor deficit is characterized by trouble extending the wrist, opposing the thumb and index finger, and opposing the thumb (C6) and pinky (C7). The sensory deficit will be a loss of pin appreciation over the thumb and index finger (sometimes also over the middle digit). The reflex loss involves to some degree the biceps reflex response, but more so the brachioradialis (over the forearm). Cerebellar dysfunction may be characterized by the inability to perform finger-nose-finger without a tremor. If there is pathology bilaterally, the deficits will appear on both sides and may additionally include cord findings.

C7 root deficits from pathology at the C6-C7 level

A C7 motor deficit is characterized by weakness of apposition of the thumb (C6) and pinky (C7), marked focal weakness of extensors of the phalanges (C7), and triceps. This may be accompanied by a loss of the triceps reflex. Additionally, decreased pin appreciation may be noted over the third digit (sometimes there is “overflow” over to the index and 4th finger). If this deficit is bilateral, there may also be cord compressive symptoms/signs.

C8 root deficits from pathology at the C7-T1 level

A C8 root deficit is defined by weakness of the intrinsic demonstrated by spreading the fingers apart. There is no specific reflex loss. The sensory deficit is over the upper arm.

Diagnostic testing

After a complete neurological examination, diagnostic testing identifies the location of cervical disc disease (e.g., soft tissue or calcified). Noninvasive studies include x-rays, MR, and CT studies. Invasive modalities such as myelograms and myelogram-CT studies are only rarely utilized.

X-rays

Plain radiographs of the cervical spine are taken from the front (anterior/posterior or AP), from the side (lateral

views), and also include flexion (bending forward) and extension studies (bending backward) to document stability. They may show normal alignment, or document vertebral body slippage, fractures, and dislocations. X-rays are still used to “clear” the cervical spine following trauma, but CT studies are more accurate. Following surgery (e.g., ACDF: anterior cervical discectomy and fusion) plain and dynamic x-rays may document graft/plate locale, and fusion [Figures 7 and 8].

Magnetic resonance scans

MR scans utilize magnetic fields and radio waves to create images of the soft tissue and bony structures (showing the water content) of the cervical spine. MR best shows the soft tissues including the spinal cord, nerve roots, soft disc herniations, tumors, synovial cysts, enlarged yellow ligament, and other pathology on lateral (sagittal images), coronal (from the front), and axial (cross section) images [Figure 1]. Because there is no radiation involved, these are usually the first studies obtained in patients suspected of having cervical discs. Soft discs may be located centrally or laterally at single or multiple levels; they may be hypointense (dark often reflecting ossification/calcification), isointense (gray), or hyperintense (white) depending upon the degree of hydration. MR is very useful to determine both root and/or cord compression; a high cord signal (white) may indicate cord swelling (edema) or myelomalacia (cord damage). Cervical MR studies may also show slippage/instability, identify ligamentous injuries, and show fracture/dislocations at the C7-T1 cervicothoracic junction.

Computed tomography scans

Computerized tomography (CT) scans utilize x-ray images obtained from different angles and a computer to create a three-dimensional image of the spine. CT scans directly show the ossified/calcific changes of the discs, vertebral bodies, ligaments, and facet joints, [Figures 2 and 4]. The sagittal image demonstrates alignment, and can rule out subluxation and/or fracture dislocation. A myelogram CT scan, now only rarely performed by placing a water-based iodine dye in the spinal fluid with a lumbar puncture, may provide additional useful information [Figure 3]. CT studies are also useful postoperatively; for example, they may readily confirm ACDF fusion [Figure 8].

Conservative therapy

Why can most patients (e.g., up to 80%) with cervical disc herniations may be managed conservatively? First, many MR and CT studies are “overread,” meaning there is no significant spinal cord or nerve root compression, but those reading them exaggerate the findings to avoid “missing” something. Second, many patients with pain alone have no neurological deficits, and nonsurgical management should be considered. Conservative

treatment includes: antiinflammatory medications, steroids, nerve transmitters, and muscle relaxants. Physical therapy, although sometimes helpful, if too rigorous may result in worsening of disc herniations. Typically, their efficacy simply coincides with the normal improvement of symptoms that would spontaneously over several successive months.

Contraindications to cervical epidural injections

The use of epidural steroid in the cervical spine is not approved by the Food and Drug Administration (FDA). More critically, they pose severe risks/complications that include: inadvertent injections into the cord itself resulting in quadriplegia, injection into the vertebral arteries resulting in stroke/death, injection directly into nerve roots resulting in focal paralysis, infection, abscess, and meningitis. Furthermore, they have no documented long-term efficacy.

Surgical options

There are various surgical options to deal with cervical disc herniations. If the discs are centrally located or anterolateral (somewhat off to the side), then an anterior approach (from the front) is typically warranted. For those that are extremely lateral or foraminal (way off to the side), a posterior approach may be utilized.

Neuroanesthesia for cervical spine surgery

Patients undergoing cervical surgery require physiological monitoring. This is initiated by placing electrodes over the brain, arms, wrists, legs, and ankles. Baseline recordings should be obtained prior to intubation, final positioning, and induction. They must then be recorded throughout the duration of surgery. Somatosensory evoked potentials (SSEP) monitor the back of the spinal cord, motor evoked potentials evaluate the anterior cord (e.g., anterior horns), while the electromyographs directly reflect irritation to the roots/muscles. To monitor these potentials successfully, anesthesia needs to utilize total intravenous anesthesia (TIVA) (e.g., without inhalant agents).

Anterior discectomy/fusion

For disc herniations located anteriorly/anterolaterally, an ACDF may be necessary [Figures 5-8]. The best approach is from the left side of the neck to minimize the risk of recurrent laryngeal nerve injury (the nerve to the vocal cords). Once the incision is made, the anterior border of the sternocleidomastoid is located, and with blunt dissection the prevertebral compartment is exposed. Hand held retractors are next replaced with self-retaining retractors (e.g., side/side and above/below). A vertebral body screw is then placed in the mid aspect of the superior (one on top) vertebral body; a lateral x-rays is taken. If correct, a second screw is placed in the mid portion of the inferior vertebral body below. Next, a spreader is placed over the two screw heads to distract

the disc space (this must be carefully done watching the SEPs, MEPs: if changes occur, distraction is immediately released). Under the microscope, the disc is incised, and disc is removed with biting instruments (pituitary rongeurs). In addition, up-biting curettes are used to remove cartilage and any disc from the superior and inferior end plates. Disc is removed down to the posterior longitudinal ligament (PLL) that is then incised looking for more disc tissue. Next, 2/3 of the anterior-mid vertebral body end plates superiorly and inferiorly are removed to expose cancellous bone (bone marrow). Next an iliac crest autograft is harvested and placed between the vertebrae, followed by application of a plate (e.g., dynamic plates work the best). Although, there are other methods for “fusion,” iliac autograft remains the gold standard and fuses the best (e.g., highest fusion rates).

Posterior discectomy; laminoforaminotomy

For the disc that is very posterior and lateral/foraminal, performing disc removal from behind the neck can be accomplished by removing a portion of the lateral lamina above and below the level in question [Figure 9]. A major advantage of this procedure is the avoidance of a fusion. With the patient prone (use of awake positioning), an x-ray localizes the correct disc level. An incision is made in the midline (middle), followed by muscle and soft tissues dissection. Once retractors are placed, a small portion of the lamina above/below the disc level is removed with a filed-down Kerrison Rongeur and a diamond drill under the operating microscope [Figures 9; a, A, B, C]. Next, the yellow ligament is

removed to expose the compressed nerve root. Small down-biting curettes introduced in the “armpit” of the nerve root then facilitate disc removal [Figure 9c]. Typically the volume is extremely small as only the offending disc fragment is removed posteriorly as opposed to the anterior procedure that requires a complete discectomy. No fusion is typically warranted unless the disc is at the C7/T1 level (cervicothoracic junction) where there is an increased risk of instability.

SUMMARY

Cervical disc disease needs to be appropriately diagnosed and treated. Patients may present with radiculopathy and/or myelopathy and neurological deficits that correlate with MR and/or CT findings of soft or calcified disc herniations. Most patients with cervical discs (e.g., 80%) respond to nonsurgical treatment; this should, however, not include epidural cervical injections that risk quadriplegia, stroke, and death. When surgery is warranted it may be performed from the front (ACDF) or behind (laminotomy). Notably, too many patients are subjected to unnecessary surgery, so the decision to have an operation should carefully considered, and other opinions obtained.

Financial support and sponsorship

Nil.

Conflicts of interest

There are no conflicts of interest.