

# Successful Treatment of Lower Eyelid Melanoma in Situ

Andrew A. Gassman, MD\*

Joyce Yuan, MD†

Justin Koh, BA†

Timothy A. Miller, MD, FACS\*

**Summary:** We present a brief literature review of the topical immunomodulating medication Imiquimod. The treatment of periorbital melanoma in situ typically requires surgical resection. Here we discuss a case of lower eyelid melanoma in situ successfully treated non-operatively with Imiquimod. (*Plast Reconstr Surg Glob Open* 2014;2:e154; doi: 10.1097/GOX.0000000000000041; Published online 15 May 2014.)

The National Comprehensive Cancer Network currently recommends that intraepidermal melanoma known as either *melanoma in situ* or *lentigo maligna* undergo local resection.<sup>1</sup> The smallest acceptable surgical excision margin for these lesions is 0.5 cm.<sup>2</sup> Removal of a melanoma in situ of any substantial size specifically in the lower eyelid would therefore create a defect that poses formidable reconstructive challenges. Some authors have supported micrographic surgery to minimize the surgical defect and<sup>3,4</sup> those same authors indicate that the standard 0.5 cm surgical margins may be, in fact, inadequate. We agree.

Imiquimod (R-837, S-26308) is a topical cream used clinically approved to treat genital warts, actinic keratosis, and superficial basal cell carcinoma. Imiquimod was developed in the 1980s for herpes virus treatment, and its ability to increase proinflammatory cytokine synthesis and nonspecific B cell production was later characterized during clinical trials.<sup>5</sup> It is the leading member of the imidazoquinoline

family (eg, Resiquimod), low-molecular-weight compounds with immunopotentiatory effects. Subsequent studies have noted Imiquimod's immunomodulating and antitumor effects on a myriad of dermatologic disorders.

Imiquimod has been examined in the management of lentigo maligna through several studies in the past decade, examining its effects before staged excision, after complete excision, and in isolation for histologically confirmed cases of lentigo maligna. These studies reported clearance rates ranging from 77% to over 90%, depending on the specific cohorts involved. The study with the highest reported success was based on daily applications at least 2 cm beyond suspected tumor margins.<sup>6,7</sup> Most of these small trials reported a 0% incidence of recurrence following Imiquimod treatment—1 patient who showed a recurrent lesion was successfully retreated with Imiquimod.<sup>8</sup> Recently there has been rapidly increasing interest in using this medication to treat both premalignant and malignant lesions in critical areas where excision would result in formidable challenges for surgical reconstruction.

Reconstruction for the lower eyelid is a particularly daunting task as the surgeon must reconstruct highly visible and functional tissue comprised of the body's thinnest skin. Compared with tarsomarginal grafts (the Hübner technique involving a pentagonal full-thickness graft from the contralateral eyelid) or local tissue advancement/rearrangement,

From the \*Division of Plastic and Reconstructive Surgery, Department of Surgery, UCLA David Geffen School of Medicine, Los Angeles, Calif.; and †UCLA David Geffen School of Medicine, Los Angeles, Calif.

Received for publication October 6, 2013; accepted December 4, 2013.

Copyright © 2014 The Authors. Published by Lippincott Williams & Wilkins on behalf of The American Society of Plastic Surgeons. *PRSGO Global Open* is a publication of the American Society of Plastic Surgeons. This is an open-access article distributed under the terms of the Creative Commons Attribution-NonCommercial-NoDerivatives 3.0 License, where it is permissible to download and share the work provided it is properly cited. The work cannot be changed in any way or used commercially.

DOI: 10.1097/GOX.0000000000000041

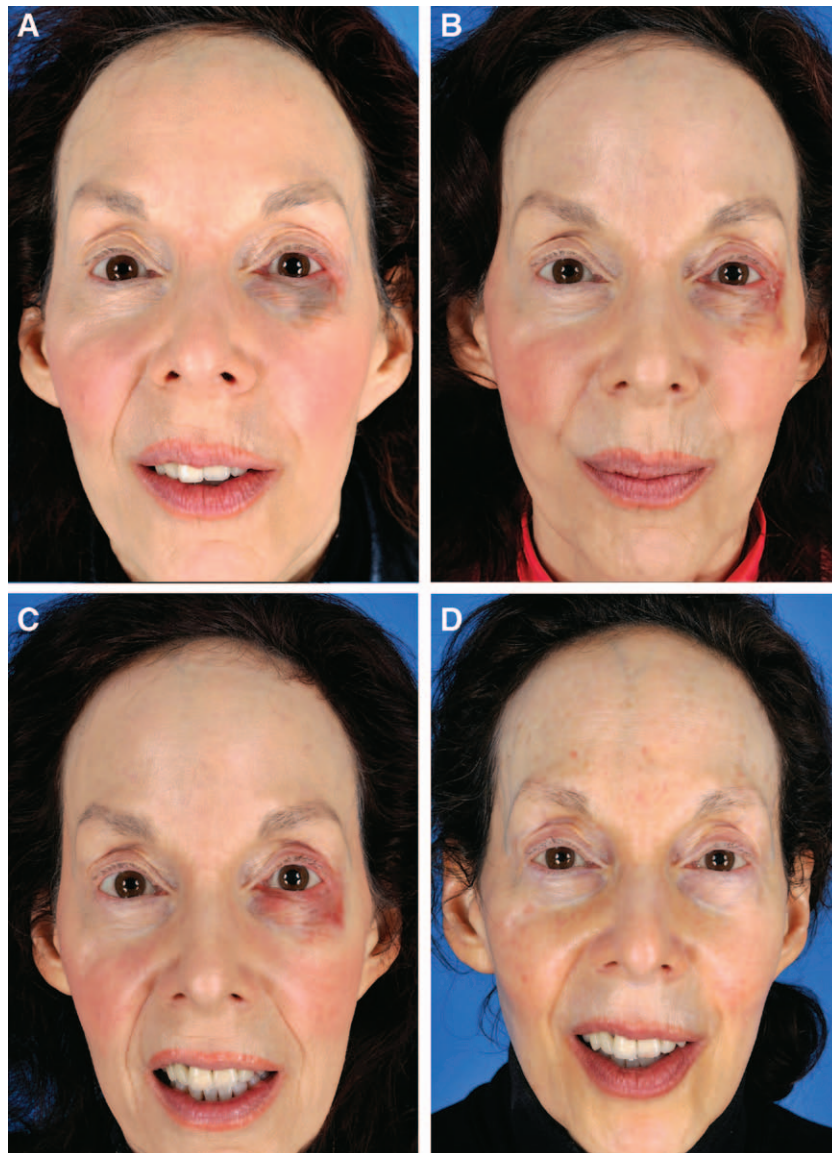
*Disclosure: The authors have no financial interest to declare in relation to the content of this article. The Article Processing Charge was paid for by the Division of Plastic and Reconstructive Surgery, Department of Surgery, UCLA David Geffen School of Medicine, Los Angeles, California.*

topical Imiquimod offers a superior cosmetic result without a single scar or tissue discoloration. This report describes a scarless, successful treatment of a lentigo maligna that occupied the majority of the lower eyelid.

**CASE REPORT**

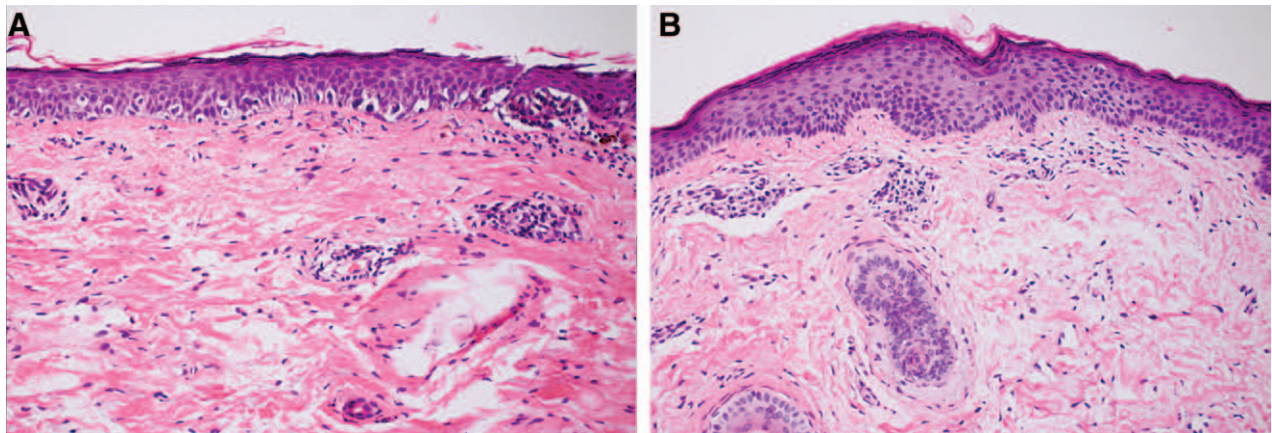
We present a 68-year-old woman with a dark lesion of varying shades of gray of her left lower eyelid (Fig. 1). She noted a gradual increase in size until the discoloration extended beyond the ciliary mar-

gin and involved over 60% of her lower lid. She denied pain and sought attention after attempting to conceal the lesion for several months with makeup. No lymphadenopathy or other clinical findings were noted. A full-thickness biopsy was performed that revealed melanoma in situ, lentigo maligna type (Fig. 2). Treatment began with modest amounts of topical Imiquimod applied every third day to the entire affected lower eyelid. By the fifth application, erythema appeared around and then within the lesion itself (Fig. 3). At approximately 3 weeks, an ulcer

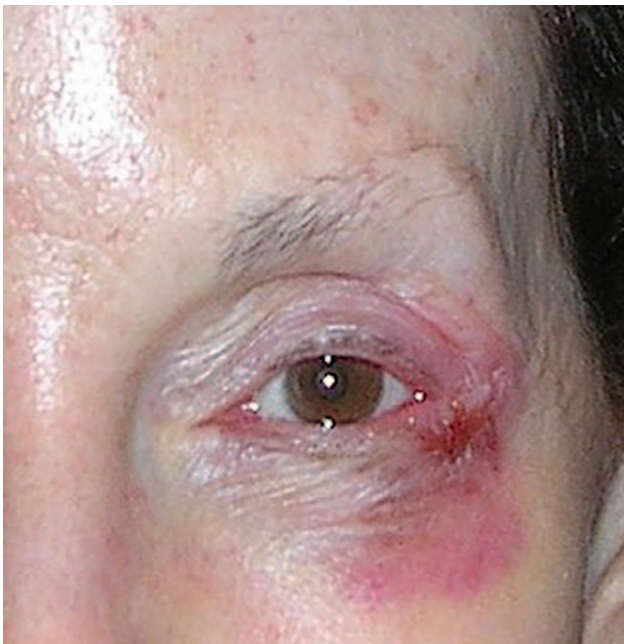

**Fig. 1.** A, The patient when she was first evaluated. B, Three weeks after Imiquimod treatment, profound inflammation can be seen to extend beyond the original lesion margins. Ulceration occurred in the areas of darkest pigmentation and a slight ectropion occurred. C, Inflammation at 2 months after treatment. The ulceration has resolved. D, Resolution of both inflammation and the original lesion approximately 6 months after treatment.





**Fig. 2.** A, Skin biopsy histology before treatment shows melanoma in situ. Nests of atypical melanocytes at the dermal-epidermal junction are also noted. The atypical melanocytes show upward scatter into the epidermis (hematoxylin & eosin, 200 $\times$ ). B, Skin biopsy after treatment with Imiquimod shows no residual melanoma (hematoxylin & eosin, 200 $\times$ ).



**Fig. 3.** A closer detail of the patient's left eyelid 3 weeks after the commencement of Imiquimod treatment resulting in profound inflammation of lower eyelid extending beyond original.

formed in the area of darkest pigmentation (lateral lower eyelid) and a slight ectropion seemed (Fig. 1). Treatment extended for another 3 weeks and was then discontinued. As healing continued, normal skin appeared. Two months later, an excisional biopsy taken from the same site as the first biopsy in the most lateral extent of the eyelid showed no tumor present (Fig. 1). Six weeks later, the eyelid seemed entirely normal with pigmentation matching the contralateral side, no ectropion, no ulceration, and no erythema (Fig. 1).

## DISCUSSION

We are not the first to describe this application. The use of Imiquimod in the treatment of periorbital lentigo maligna has been cited several times in both dermatologic and ophthalmologic literature.<sup>3,9-11</sup> However, these findings represent several case reports or small series that had large variations in treatment protocols. The only consistent finding in each of these cases and our own is that by 6 months after the initiation of topical Imiquimod therapy, all lesions underwent complete resolution. Imiquimod is a powerful tool in the treatment of dermatologic disorders.

## CONCLUSIONS

Lentigo maligna requires full-thickness skin excision. This approach creates a difficult reconstructive challenge in delicate areas such as the lower eyelid. Imiquimod, an immunomodulating Toll-like receptor agonist, has been Food and Drug Administration approved for the treatment of genital/perianal warts, actinic keratosis, and superficial basal cell carcinoma. Imiquimod's off-label use in the treatment of lentigo maligna is currently under investigation. This report and earlier case series demonstrate that it is a useful to treat the intraepidermal melanoma to resolution without the creation of secondary defect in need of subsequent reconstruction. Further study is needed to isolate a precise and treatment protocol that yields a predictable treatment course and outcome, as study reports varied based on frequency of applications and special considerations, such as the above-cited 2-cm margin past suspected lesion borders. In this patient's case, applications were every other day.

**Andrew A. Gassman, MD**  
 UCLA Department of Surgery  
 Division of Plastic & Reconstructive Surgery  
 David Geffen School of Medicine  
 200 UCLA Medical Plaza, Suite 465  
 Los Angeles  
 CA 90095-6960  
 E-mail: agassman@mednet.ucla.edu

### PATIENT CONSENT

*The patient provided written consent for the use of her images.*

### REFERENCES

1. National Comprehensive Cancer Network. *I. Melanoma: the NCCN Guidelines Version 2 2013*. Fort Washington, PA: National Comprehensive Cancer Network, Inc; 2012.
2. Diagnosis and treatment of early melanoma. NIH Consensus Development Conference. January 27-29, 1992. *Consens Statement* 1992;10:1-25.
3. Murchison AP, Washington CV, Soloman AR, et al. Ocular effects of imiquimod with treatment of eyelid melanoma in situ. *Dermatol Surg*. 2007;33:1136-1138.
4. Kunishige JH, Brodland DG, Zitelli JA. Surgical margins for melanoma in situ. *J Am Acad Dermatol*. 2012;66:438-444.
5. Rhodes J. Discovery of immunopotentiatory drugs: current and future strategies. *Clin Exp Immunol*. 2002;130:363-369.
6. Naylor MF, Crowson N, Kuwahara R, et al. Treatment of lentigo maligna with topical imiquimod. *Br J Dermatol*. 2003;149(Suppl 66):66-70.
7. Ellis LZ, Cohen JL, High W, et al. Melanoma in situ treated successfully using imiquimod after nonclearance with surgery: review of the literature. *Dermatol Surg*. 2012;38:937-946.
8. Buettiker UV, Yawalkar NY, Braathen LR, et al. Imiquimod treatment of lentigo maligna: an open-label study of 34 primary lesions in 32 patients. *Arch Dermatol*. 2008;144:943-945.
9. Demirci H, Shields CL, Bianciotto CG, et al. Topical imiquimod for periocular lentigo maligna. *Ophthalmology*. 2010;117:2424-2429.
10. O'Neill J, Ayers D, Kenealy J. Periocular lentigo maligna treated with imiquimod. *J Dermatolog Treat*. 2011;22:109-112.
11. Hopson B, Richey D, Sajben FP. Treatment of lentigo maligna with imiquimod 5% cream. *J Drugs Dermatol*. 2007;6:1037-1040.